



A NEW CONSERVATIVE AND REGENERATIVE APPROACH TO MANAGE CASES OF IRREVERSIBLE PULPITIS USING HUMAN PLACENTAL EXTRACT

Hala Fares*

ABSTRACT

Recently we have been confronted with a rapid turn over in dental conservative therapeutic approaches our study is the first study to use human placental extract (HPE), with its healing power and numerous growth factors, to manage cases of irreversible pulpitis aiming at influencing healing tissue repair mechanisms as well as influencing healthy cells to replace impaired and damaged ones. In this study two groups of patients were included. The first group "P" aged fourteen to sixteen years old while the second group "A" aged eighteen to twenty eight years old. Each group included fifteen subjects (males and females). All patients demonstrated signs and symptoms of irreversible pulpitis and all were treated using (HPE). The treated teeth were re-evaluated after three and six months and two years. Except for one case clinical and radiographic examination of cases belonging to group "A" as well as those belonging to group "P", revealed appropriate function, absence of any signs and symptoms and normal periodontium apparatus.

KEY WORDS: Irreversible pulpitis, regeneration, human placental extract.

INTRODUCTION

Recently, we have been confronted with a rapid turn over in dental conservative therapeutic approaches. As a matter of fact, conservatism is currently expanding to include other several medical fields.

Homeostasis works to create a balance using the hormonal, nervous, and immune systems. It is known that the placenta increases natural healing

through hormonal regulation, nervous regulation, and immune regulation. Also, the placenta is known to possess various physiologically powerful growth factors, which are now attracting a lot of attention. The main growth factors of the placenta are: Hepatocyte growth factor (HGF), which promotes growth of liver parenchymal cells and various tissues. Nerve growth factor (NGF), which promotes growth of nerve cells (sensory and sympathetic ganglionic cells). Epidermal growth factor (EGF), which pro-

* Lecturer, Department of Operative Dentistry, Faculty of Oral and Dental Medicine, Misr University for Science and Technology. Egypt.

motes growth of skin, lungs, cornea, and tracheal epithelial cells. Fibroblast growth factor (FGF), which promotes growth of human fibroblasts and vascular endothelial cells. Insulin-like growth factor (IGF), which promotes growth of cartilage cells, and smooth muscle cells. Growth factors which increase immune strength. Colony – Stimulating factor (CSF), which promotes growth of stem cells, interleukin – 1 (IL-1), which promotes production of immune – competent cells (T-cells, B-cells, and NK – cells), thymus cells and lymphokines. Interleukin – 2 (IL -2), which promotes growth of T-cells (helper, killer & suppressor T-cells). Interleukin – 3 (IL – 3), which promotes growth of hematopoietic cells and mast cells. Interleukin 4 (IL – 4). Which promotes growth of B-cells as well as division of antibody – producing cells. As a matter of fact, the Hepatocyte Growth factor (HGF) was reported to have a regenerative effect on cells and organs. Other active ingredients of the placenta include: DNA, RNA and metabolic products, essential amino acids including Leucine, Glycine, Valine, and Threonine, activate peptides, vitamins (B1, B2, B6, B12, C, D, E and niacin), minerals (Ca, Na, K, P, Mg, Zn & Fe), enzymes (about 100 enzymes, including ALK phosphatase, acid phosphatase, ADP) and saccharides. Various medical actions of the placenta included: Autonomous nervous system control, endocrine hormone control, liver function enhancement, improvement of basal metabolism, activation of the immune system, improvement of physical constitution, anti-inflammatory action, treatment of anemia, improvement of blood circulation, recovery of tiredness, and wound healing^(1,2).

Also, human placental extract is clinically used for the treatment of skin wrinkles because it promotes skin regeneration⁽³⁾. Human placental extract is also a component of various skin ointments because it promotes skin revitalization and melanocyte growth, and exhibits pigment inducing activities as well as for the treatment of skin hypersensitivity-like dermatitis and psoriasis⁽⁴⁾.

Subcutaneous or intra muscular injection of human placental extract (HPE), a hydrolysate of the human placenta commercially named Laennec (Japan Bio Products, Tokyo, Japan) has been recently used for the treatment of various disorders including climacteric symptoms, non-healing wounds and chronic varicose ulcers⁽⁵⁻⁸⁾.

This product was used in this study. Also, porcine placental extract (PPE) has been developed as an orally administered supplement for the same purposes as those of human placental extract (HPE). Previous studies demonstrated that oral administration of PPE to human subjects was significantly effective for the reduction of knee pain in post-menopausal women and improvement of climacteric symptoms in pre and post – menopausal women^(9,10).

Traditional endo has been described to have other additional drawbacks, e.g. the discomfort related to the anesthesia, rubber dams, especially with long periods with the mouth open, retreatments, post-op sensitivity, blowups, blocked canals, separated files, apicoectomies, hypochlorite leaks, ledges, excessive biofilms, lateral canals, anastomoses, deltas, over fills, under fills, cracks, perforations and micro surgery^(11, 12, 13, 14).

The use of placental extract, dentally is extremely limited (periodontally) or totally non existent regarding the tooth structure. The human dental pulp is capable of a regenerative procedure in certain cases, using certain procedures and materials. An ideal form of pulpal therapy may consist of regenerative approaches in which diseased or necrotic pulp tissues are removed and replaced by healthy pulp tissues for revitalization⁽¹⁵⁾.

Research on stem cells is providing advanced knowledge about how an organism develops from a single cell, and how healthy cells replace damaged ones in adult organisms. Stem cells have the ability to continuously divide to either replicate themselves (self – replication), or produce specialized cells that

can differentiate into various other types of cells or tissues (multilineage differentiation)⁽¹²⁾.

Our study is the first study that uses human placental extract to manage cases of irreversible pulpitis aiming at influencing healing, tissue repair mechanisms and inducing healthy cells to replace impaired and damaged ones.

METHODS AND MATERIALS

Cases' selection and grouping of subjects

Two groups of patients with a total of thirty subjects were included in this study. The first group (P) aged fourteen to sixteen years old while the second group (A) aged eighteen to twenty eight years old. Each group included fifteen subjects (males and females). For all patients, confirmation was made, that there were no medical contraindications for dental treatment. Also, by through clinical examination, all patients had good oral hygiene. Premolars were the selected teeth for this study. All patients demonstrated signs and symptoms of irreversible pulpitis. For the first group (P), the selected teeth demonstrated immature apices, while for group (A) teeth were examined to ensure complete apical closure. For both groups, teeth were examined to ensure pulp vitality and it was made sure that the pulp spaces were not needed for post / core, final restorations, moreover, it was made sure that the patients were not allergic to medicaments and antibiotics necessary for the clinical procedure of the study. An informed consent from each patient included in that study was obtained. The consent form included the number of appointments, the use of medicaments and antibiotics with their possible adverse effects as (pain, infection and / or lack of response to the treatment), and the possibility of resolving to traditional endodontics or even extraction if the situation was beyond salvage. The patients included in this study were family members, close friends and business associates in order to facilitate recall and follow up along the study period. This study is evidence – based, and the

decision to use human placental extract to induce regeneration of the pulp tissue for the individual patients was set according to their oral environment rather than treating all patients similarly. Also, our treatment included strategies that place the patients into a healthy balance, examples include healthy meticulous safety measures followed during manufacturing of the placental extract product (according the manufacturer) and the selection of patients who had good oral hygiene and who had no medical contraindications for dental treatment.

Safety of the human placental extract product according to the manufacturer

- The donor of placenta is checked. She should be free from syphilis, gonorrhoea, tuberculosis, HBV, HCV, HIV, HTLV (adult T cell leukemia), HPV/B19 (slap cheek).
- She should have been in only Japanese hospitals. This is to ensure that the strict standards have been adhered to.
- LAENNECs safety is ensured by the most rigid safety measures among existing scientific standards.
- Manufactured process by three different proprietary techniques.
- In order to improve safety further, performs, a sterilization operation several times during the manufacturing process to eliminate any possibility of contamination.
 - i. The placenta is hydrolyzed by hydrochloric acid, and treated by heat for 15 – 17 hours.
 - ii. At the final process, it is sterilized by steam at 121 degrees (Celsius) for 30 minutes. Through these two processes all viruses are killed, and prions are destroyed.
- Laennec is the only placenta extract product without hormone and steroid.
- No serious side effects have been reported.

TABLE (1) Materials, components, batch numbers and manufacturers

Material	Components	Batch numbers	Manufacturer
LAENNEC	Human placental extract	30472	Japan Bio Products YHB Pharma (Taiwan and Egypt) Tokio / Japan
Biodentine	<p style="text-align: center;">Powder</p> <ul style="list-style-type: none"> - Tricalcium Silicate. - Dicalcium Silicate. - Calcium carbonate. - Oxide filler. - Iron Oxide shade. - Zirconium Oxide. <p style="text-align: center;">Liquid</p> <ul style="list-style-type: none"> - Calcium chloride (accelerator). - Hydrosoluble polymer. 	B02282	Septodont
Recaldent	<p style="text-align: center;">Topical cream</p> <ul style="list-style-type: none"> - GC MI paste plus with flavors 		GC corporation Japan
3M™ESPE™ Single Bond	<p style="text-align: center;">Dental adhesive system</p> <ul style="list-style-type: none"> - Phosphoric acid etchant - A vial of adhesive 	N628066	3M ESPE Dental Products St Paul, MN, USA
3M Filtek™ Z 250 XT	<p style="text-align: center;">Nanohybrid composite</p> <p style="text-align: center;">In organic filler:</p> <p style="text-align: center;">Zirconia/Silica (60% by volume)</p> <p style="text-align: center;">Matrix: BIS-GMA, UDMA and BIS-EMA resins</p>	N535294	3M ESPE Dental Products St Paul, MN, USA
3M ESPE Ketac™ Nano	Light curing glass ionomer restorative	N457901	3M ESPE Dental Products St Paul, MN, USA

Clinical procedure

During the first visit routinely the patient was anesthetized, and the tooth was isolated using a rubber dam. Caries was removed using high speed burs and the access opening was performed. Any further decay was then removed. That was followed by copious gentle irrigation with saline. Sterile cotton pellets were used to stop any possible bleeding. An irrigation system (Endovac™) was used to minimize the possibility of extrusion of

irrigants into the periapical space and to avoid cytotoxicity to stem cells in the apical tissues.

The placental extract was delivered gently to the canals using a syringe. Then a collagen plug (resorbable) (Colla plug™) soaked with the placental extract was placed inside the access opening then Biodentin was used as a capping material and a resin modified glass ionomer (Ketac™Nano) (3M ESPE) was used as a temporary restoration.

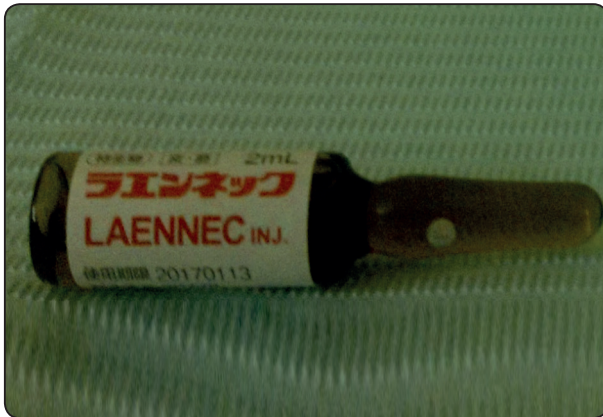

Fig. (1) The placental extract used

The patient was dismissed and recalled in three weeks' time for a second visit. During the second visit, all patients were thoroughly examined clinically, for signs and symptoms of persistent infection as pain, swelling, tenderness, tooth mobility and fistula; and radiographically to examine the following: any loss of lamina dura, widening of the periodontal ligament, any signs of pathologic external or internal root resorption and any periapical or inter-radicular radiolucency. With the absence of those signs, each patient was anesthetized and a dental dam was used for isolation. All cavity walls were, then, conditioned and bonding performed in order to strengthen the remaining tooth structure. Afterwards a composite restoration was placed, light cured and finished. For all patients, the bonding system used was Single Bond (3M ESPE) which was applied in two consecutive coats. The resin composite restorative material used was filtek Z250 XT (3M ESPE).

The treated teeth were re-evaluated after three and six month and two years for clinical signs and symptoms (pain swelling, tenderness, tooth mobility, fistula), using percussion tests, and palpation of teeth and alveolar areas, and any radiographic changes as loss of lamina dura, widening of the periodontal ligament, any signs of pathologic external or internal root resorption and any periapical or inter radicular radiolucency.

RESULTS

The degree of success is attained by achieving the following goals.

- Absence of clinical symptoms and undesirable radiographic examination.
- (for group 'P'): Increased root wall thickness and / or increased root length (desirable but not essential), the important thing is closure of the apex.
- Positive response to vitality testing: meaning that placental extract saved the vitality of the pulp.

Clinical examination

For group 'A': At all time periods (3 and 6 months and 2 years) fourteen of the treated teeth revealed appropriate function and absence of clinical signs and symptoms as pain, swelling, tenderness, tooth mobility and fistula. However one case failed over two years period and needed traditional endodontic treatment. Vitality tests showed fourteen cases to be vital.

For group 'P': At all time periods (three and six months and two years) all treated teeth revealed appropriate function and absence of clinical signs and symptoms as pain, swelling, tenderness, tooth mobility and fistula. Vitality tests showed all cases to be vital.

Radiographic examination:

For group 'A': At all time periods (three and six months and two years), fourteen of the treated teeth appeared in function with normal periapical tissues and, generally, normal periodontium and complete absence of any loss of lamina dura, widening of the periodontal ligament, signs of pathologic external or internal root resorption, or periapical or interradicular radiolucency. However, the case that demonstrated clinical failure, also showed radiographic changes indicating failure.

For group ‘P’ At all time periods (three and six months and two years), all treated teeth appeared in function with normal periapical tissues and, generally, normal periodontium and complete absence of any loss of lamina dura, widening of the periodontal ligament, signs of pathologic external or internal root resorption, or periapical or interradicular radiolucency Also all cases revealed Increased root wall thickness, increased root length (desirable but not essential), and closure of the apex.

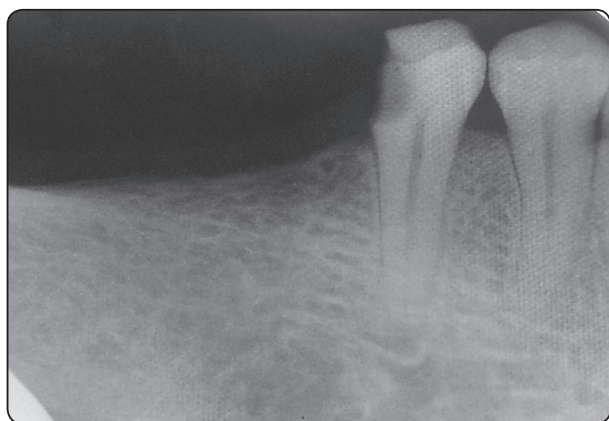


Fig. (2): A radiograph of a tooth suffering irreversible pulpitis.

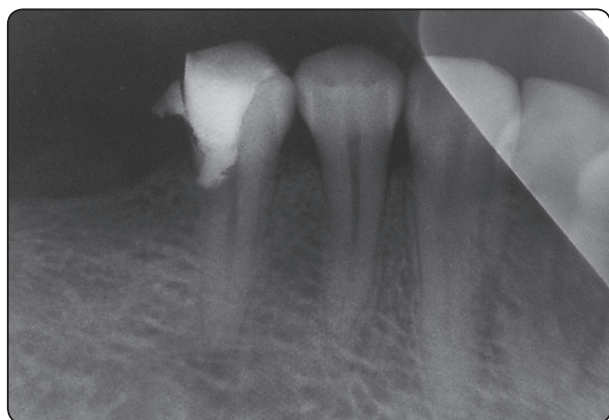


Fig. (3): A radiograph of the same tooth using placental extract as a regenerative approach (after two years).

Statistical Analysis

Data were presented as frequencies (+n) and percentages (%). Fisher’s Exact test was used to compare between the two groups.

The significance level was set at $P \leq 0.05$. Statistical analysis was performed with IBM® SPSS® Statistics Version 20 for Windows.

RESULTS

After 3 months, 6 months as well as 2 years; there was no statistically significant difference between success rates in the two groups (P-value = 1.000, 1.000 and 0.483, respectively).

TABLE (2) Frequency, percentages and results of Fisher’s Exact test for comparison between success rates in the two groups

Time	Group ‘P’ (n=15)		Group ‘A’ (n=15)		P-value
	n	%	n	%	
3 months	15	100	14	93.3	1.000
6 months	15	100	14	93.3	1.000
2 years	15	100	13	86.7	0.483

*: Significant at $P \leq 0.05$

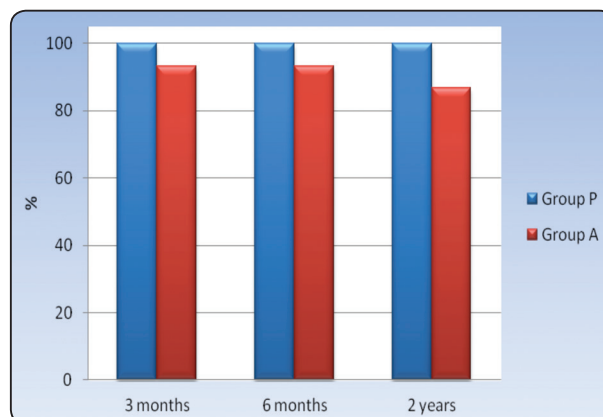


Fig. (4): Bar chart representing success rates in the two groups

DISCUSSION

Recently, regenerative approaches have proven to be more conservative in pulpal therapy in comparison to traditional ways. In this study we have used a new conservative and regenerative approach to manage cases of irreversible pulpitis using human placental extract and aiming at removal of the diseased pulp tissues and their replacement by healthy ones. Most recent medical researches have reported that the human placental extract increases natural healing and possess various physiologically powerful growth factors that promote growth of various body cells as, liver parenchymal cells, nerve cells, skin, lungs, cornea and tracheal epithelial cells, cartilage cells, smooth muscle cells, vascular endothelial cells, and most important, stem cells⁽¹⁻⁸⁾. Post natal stem cells have been found in almost all body tissues;⁽¹⁷⁾ including dental tissues. ^(18,19). To date, four types of human dental stem cells have been isolated and characterized: i- Dental pulp stem cells (DPSCs)⁽²⁰⁾; ii- Stem cells from human exfoliated deciduous teeth (SHED)⁽²¹⁾; iii- Stem cells from apical papillae (SCAP) ^(22, 23); and iv- periodontal ligament stem cells (PDLSCs)⁽²⁴⁾; Growth factors are extracellularly secreted signals governing morphogenesis / organogenesis during epithelial mesenchymal interactions. They regulate the division or specialization of stem cells to the desirable cell type and mediate key cellular events in tissue regeneration including cell proliferation chemotaxis, differentiation and matrix synthesis⁽²⁵⁾. Some growth factors are used to increase stem cell numbers, as in case of platelet – derived growth factor (PDGF), fibroblast growth factor (FGF), Insulin – like growth factor (IGF), colony – stimulating factor (CSF), and epidermal growth factor. Others modulate the humoral and cellular immune responses (interleukins 1 – 13); while others are important regulators of angiogenesis, such as vascular endothelial growth factor (VEGF)^(26, 27, 28); or are important for wound healing and tissue regeneration

/ engineering, such as transforming growth factors alpha and beta ^(25, 29, 30); One distinct family of growth factors implicated in tooth development^(31, 32) and regeneration⁽³³⁾; are bone morphogenetic proteins (BMPs) known for their ability to induce formation of bone and cartilage. The role played by BMP – 2 is reportedly crucial as a biologic tool for dentin regeneration ⁽³⁴⁾. Recombinant human BMP-2 stimulated the differentiation of adult pulp stem cells into odonto blast – like cells in culture^(35, 36, 37), increases their alkaline phosphatase activity and accelerates their alkaline phosphatase activity and accelerates expression of the dentin sialoprotein (DSPP) gene in vitro⁽³⁵⁾; and enhances hard tissue formation in vivo⁽³⁸⁾. According to all what have been mentioned above, placental extract being a unique reservoir for all these growth factors we suggested that its use in this study could greatly and marvelously influence healing, tissue repair mechanisms and induce healthy cells to replace impaired and damaged ones.

The selected subjects of this study were males and females to rule out any factors related to gender. Also, all of them happened to be family members and close friends in order to facilitate recall and follow up along such a relatively long term study. For all patients, a preliminary medical examination was required to rule out any medical contraindications for dental treatment, and a preliminary dental examination was conducted to ensure pulp vitality of the selected teeth for treatment and complete apical closure (for group ‘A’ only). Our treatment was evidence – based and the decision to perform adult pulpotomy for the individual patients was set according to their oral environment rather than treating all patients similarly. Moreover, our treatment included strategies that put the patients into a healthy balance, for example the patients did not only receive restorative treatment but also simple interventions with a remineralizing agent (CpP-Acp) (Recaldent) was used. Also most important the placental extract used in this study was

manufactured under strict health safety measures according to the manufacturer.

Except for one case; results of this study have shown that all cases demonstrated both clinical and radiographic success.

The success rate in this study was primarily attributed to the fact that the placental extract, being an extremely marvelous source of so many growth factors (as mentioned before), could induce healing, govern morphogenesis and organogenesis, regulate the division or specialization of undifferentiated mesenchymal cells and stem cells from apical papillae (SCAP) to the desirable cell type and mediate key cellular events in tissue regeneration including cell proliferation, chemotaxis, differentiation and matrix synthesis. In several previous studies it was reported that dental pulp stem cells had a striking ability to regenerate a dentin – pulp – like complex composed of mineralized matrix of tubules lined with odontoblasts, and fibrous tissue containing blood vessels in an arrangement similar to the dentin – pulp complex found in normal human teeth. It was also reported that these cells had a high proliferative capacity, a self renewal property and a multi – lineage differentiation potential^(29, 39, 40 -43).

Other additional factors related to our success were the power of placental extract to improve basal cell metabolism, activate the immune system and improve blood circulation in addition to its anti inflammatory action^(1,2). Regarding group ‘P’ where apexogenesis was successfully induced; this was attributed to the following: stem cells in the apical papilla of permanent immature teeth (SCAP) express various mesenchymal stem cell markers. SCAP are capable of forming odontoblast like cells, producing dentin *in vivo*, and are likely to be the cell source of primary odontoblasts for formation of root dentin. Therefore, under the influence of the surviving epithelial root sheath of Hertwig, these cells can generate primary odontoblasts that complete root formation.

In this study, bonded resin composite restorations were used. It was thought appropriate to make use of the strengthening effect of bonding systems and the bonding procedure to strengthen the remaining tooth structure which would, certainly, impart to the longevity of the restoration. On the other hand, regarding micro leakage; it was postulated that one of the most important causes of failure in vital pulp therapy was the presence of leakage during the healing process because of the material used for pulpotomy or the restorative material used^(44 -50). Therefore, in our study, a bonded resin composite restoration was used to reduce microleakage along the restoration tooth interface which, in turn, would impart to the longevity of the restoration. It has to be noticed that conditioning of all cavity walls was performed directly after pulpal fixation, with out resolving to the use of liners or bases, as it has been reported by several recent studies that the use of bonding systems could totally replace liner and bases⁽⁵⁰⁾.

The results of our study were found successful over a two years’ follow-up period. Further research over a comparatively longer follow-up period may be tried.

CONCLUSION

A successful conservative method of managing cases of irreversible pulpitis is making use of the regenerative power of human placental extract which has been described as an amazing reservoir of numerous growth factors.

REFERENCES

- 1- Yoshida K. Placenta power: a useful guide for those seeking placenta based remedies. 2001.
- 2- Manual of human placental extract: Laennec. YHB Pharma Taiwan and Egypt. 2013.
- 3- Yoshikawa C, Takano F, Ishigaki Y, Okada M, Kyq S, Suzuki N, Sugiura K & Koikek. Effect of porane placental extract on collagen production in human skin fibroblasts *in vitro*. *GynecolObstet* 2013; 3 (6): 1000-1086.

- 4- Pai P, Mallick S, Mandal SK, Das M, Dulta AK. A human placental extract: in vivo and in vitro assessments of its melanocyte growth and pigment inducing activities. *Int J Dermatol* 2002; 41: 760-767.
- 5- Kong MH, Lee EJ, Lee SY, Chos J & Hong YS. Effect of human placental extract on menopausal symptoms, fatigue and risk factors for cardiovascular disease in middle aged Korean women. *Menopause* 2008; 15: 296-303.
- 6- Shukia VK, Rasheed MA, Kumar M, Gupta SK & Pandey SS. Atrial to determine the role of placental extract in the treatment of chronic non-healing wounds. *J Wound Care* 2004; 13: 177- 179.
- 7- Tiwary SK, Shukia D, Tripathi AK, Agrawal S & Singh MK. Effect of placental extract gel and cream on non-healing wounds. *J Wound Care* 2006; 15: 325-328.
- 8- Burgos H, Herd A & Bennett JP. Placental angio-genic and growth factors in the treatment of chronic varicose ulcers: preliminary communication. *J R Soc Med* 1989;82: 598-599.
- 9- Koike K, Yamamoto Y, Suzuki N, Yamazaki R & Yoshikawa L. Efficacy of porcine placental extracts with hormone therapy for post-menopausal women with knee pain. *Climacteric* 2012; 15: 30-35.
- 10- Koike K, Yamamoto Y, Suzuki N, Yamazaki R & Yoshikawa L. Efficacy of porcine placental extract on climacteric symptoms in peri- and postmenopausal women. *Climacteric* 2013; 16: 28-35.
- 11- Ellis J. Neiburger. *Glidewell laboratories* 2013; Vol. 7 (1).
- 12- Hugh CL, Walton RE, Facer SR. Evaluation of intracanal sealer distribution with 5 different obturation techniques. *Quintessence Int* 2005; 36 (9): 721-729.
- 13- Lin LM, Rosenberg PA, Lin J. Do procedural errors cause endodontic treatment failure? *J Am Dent Assoc* 2005; 136 (2): 187-193.
- 14- Hollanda AC, Estrela CR, Decurico Dde A, Silva JA, Estrela C. Sealing ability of three commercial resin-based endodontic sealers. *Gen Dent* 2009; 57 (4): 368-373.
- 15- Hargreaves KM, Law AS. *Regenerative Endodontics. Pathways of The pulp* 10th ed. Eds, Hargreaves KM, Cohen S. Mosby Elsevier, St Louis, MO, 2011: 602-619.
- 16- Rao MS. Stem sense: a proposal for the classification of stem cells. *Stem Cells Dev.* 2004; 13: 452-455.
- 17- Gimble J & Guilak F. Adipose-derived adult stem cells: isolation, characterization and differentiation potential. *Cytotherapy* 2003; 5: 362-369.
- 18- Casagrande L, Mattuella LG, de Araujo FB & Eduardo J. Stem cells in dental practice: perspectives in conservative pulp therapies. *J ClinPediate Dent* 2006; 31: 25-27.
- 19- Trubiani O, D' Arcangelo C, Di Iorio D, Di Nardo Di Maio F & Caputi S. Dental pulp stem cells bio-adhesivity: evaluation on mineral-trioxide-aggregate. *Int J ImmunopatholPharmacol* 2007; 20: 81-86.
- 20- Gronthos S, Mankani M, Brahimi J, Robey PG & Shi S. Postnatal human dental pulp stem cells (SPSDs) in vitro and in vivo. *ProcNatlAcadSci USA* 2000; 97: 13625-13630.
- 21- Miura M, Gronthos S, Zhao M, Lu B, Fisher LW, Robey PG & Shi S. SHED: stem cells from human exfoliated deciduous teeth. *ProcNatlAcadSci USA* 2003; 100: 5807-5812.
- 22- Sonoyama W, Liu Y, Fang D, Yamaza T, Seo BM, Zhang C, Liu H, Gronthos S, Wang CY, Shi S, Wang S. Mesenchyme stem cell-mediated functional tooth regeneration in swine. *PLOS One* 2006; 1: e79.
- 23- Sonoyama W, Liu Y, Yamaza T, Tuan RS, Wang S & Huang GT. Characterization of the apical papilla and its residing stem cells from human immature permanent teeth: a pilot study. *J Endod* 2008; 34: 166-171.
- 24- Seo BM, Miura M, Gronthos S, Bartold PM, Batouli S, Brahimi J, Young M, Robey PG, Wang CY & Shi S. Investigation of multipotent postnatal stem cells from human periodontal ligament. *Lancet* 2004; 364: 149-155.
- 25- Giannobile WV. Periodontal tissue engineering by growth factors. *Bone* 1996; 19: Suppl, 23s- 37s.
- 26- Nakao K, Ftoh M, Tomita Y, Tomooka Y & Tsuji T. FGF-2 potently induces both proliferation and DSP expression in collagen type I gel cultures of adult incisor immature pulp cells. *BiochemBiophys Res Commun* 2004; 325: 1052-1059.
- 27- Ferrara N, Greber HP & Le Couter J. The biology of VEGF and its receptors. *Nat Med* 2003; 9: 669- 676.
- 28- Roy H, Bhardwaj S & Ylä-Herttuala S. Biology of vascular endothelial growth factors. *FEBS Lett* 2006; 580: 2879-2887.
- 29- Tai TF, Chan CP, Lin CC, Chen LI, Jeng JH & Chang MC. Transforming Growth Factor β 2 Regulates Growth and Differentiation of Pulp Cells via ALK5/Smad2/3. *J Endod* 2008; 34: 427-432.

- 30- Nie X, Jin Y & Zhang CY. Induction of transforming growth factor- beta I and dentin non- collagen proteins on tissue engineering pulp. *Chin J of Repar and ReconstSurg* 2004; 18(2):115-118.
- 31- Aberg T, Wozney J &Thesleff I. Expression pattern of bone morphogenicprotiens (Bmps) in the developing mouse tooth suggest roles in morphogenesis and cell differentiation.*DevDyn* 1997; 210: 383- 396.
- 32- Nagatoo KJ, Tompkins KA, Fong H, Zhang H, Forter BL, Chu EY, Murakami A, Stadmeyer L, Canalis E &Somerman MJ. Transgenic over expression of gremlin results in developmental defects in enamel and dentin in mice. *Connect Tissue Res* 2008; 49: 391-400.
- 33- Nakashima M &Reddi AH. The application of bone morphogenetic protiens to dental tissue engineering. *Nat Biotechnol* 2003; 21: 1025- 1032.
- 34- Nakashima M, Tohran K &Zheng L. Gene therapy for dentin regeneration with bone morphogenetic proteins. *CurrTher* 2006; 6: 551- 560.
- 35- Saito T, Ogawa M, Hata Y &Bessho K. Acceleration effect of human recombinant bone morphogenetic protein- 2 on differentiation of human pulp cells into odontoblasts. *J Endod* 2004; 30: 205-208.
- 36- Nakashima M,Nagasawa H, Yamda Y &Reddi AH. Regulatory role of transforming growth factor beta, bone morphogenetic protein- 2, and protein- 4 on gene expression of extracellular matrix proteins and differentiation of dental pulp cells. *DevBiol* 1994; 162:18-28.
- 37- Iohara K, Nakashima M, Ito M, Ishikawa M, Nakasima A&Akamine A. Dentin regeneration by dental pulp stem cell therapy with recombinant human bone morphogenetic protein- 2. *J Dent Res*; 83: 590- 595.
- 38- Yang X, Walboomers XF, Van Den Beucker JJ, Bian Z, Fan M & Jansen JA. Hard tissue formation of STRO- 1- selected rat dental pulp stem cells in vivo. *Tissue Eng Part A* 2009; 15:367-375.
- 39- Gronthos S, Brahim J, Li W, Fisher LW, Cherman N, Boyde A, Den Besten P, Robey PG & Shi S. Stem cell properties of human dental pulp stem cells. *J Dent Res* 2002; 81: 531- 535.
- 40- Yu J, Deng Z, Shi J, Zhai H, Nie X, Zhuang H, Li Y, Jin Y. Differentiation of dental pulp stem cells into regular shaped dentin- pulp complex induced by tooth germ cell conditioned medium. *Tissue Eng*. 2006; 12: 3097-3105.
- 41- Tonomura A, Sumita Y, Ando Y, Iejima D, Kagami H, Honda MJ, Ueda M. Differential inducibility of human and porcine dental pulp-derived cells into odontoblasts. *Connect Tissue Res* 48, 229-238.
- 42- D' Aquino R, De Rosa A, Laino G, Caruso F, Guida L, Rullo R, Checchi V,Laino L, Tirino V, Papaccio G. *J ExpZool* 2009; 312B: 408-415.
- 43- Graziano A, D' Aquino R, Laino G, Papaccio G. Dental pulp stem cells: a promising tool for bone regeneration. *Stem Cell Rev* 2008; 4: 21-26.
- 44- SaeedAsgary& Sara EHsani. Permanent molar pulpotomy with a new endodontic cement: A case series. *J Conserve Dent* 2009; 12 (1): 31-36.
- 45- Asgary S, Eghbal MJ, Parirokh M, Ghanavati F, Rahimi H. A comparative of histologic response to different pulp capping materials and a novel endodontic cement. *Oral surg oral med pralpathol oral radio endod* 2008; 106: 609-614, (PubMed).
- 46- Cox CF, Bergenholtz G, Heys DR, Syed SA, Fitzgerald M, Heys RJ. Pulp capping of dental pulp mechanically exposed to oral microflora: AS 1-2 year observation of wound healing in the monkey. *J Oral Pathol* 1985; 14: 156-168.
- 47- Massler M. Preserving the exposed pulp. *J Pedodont* 1978; 2: 217-227.
- 48- Caliskan MK. Clinical reliability of dentinbridge formed after pulpotomy: A case report. *IntEndod J* 1994; 27: 52-55 (PubMed).
- 49- Tobias RS, Plant CG, Browne RM. Reduction in pulpal inflammation beneath surface- sealed silicates. *IntEndod J* 1982; 15: 173- 180 (PubMed).
- 50- Asgary S, Eghbal MJ, Parirokh M. Sealing ability of a novel endodontic cement as root- end filling material. *J Biomed Mater Res A* 2008; 87: 706- 709, (PubMed).
- 51- Harald O. Heymann. *Sturvant's Art & Science of Operative Dentistry*. 6th edition. St. Louis: Mosby; 2012: 96.