
Purse string suturing of the lower uterine segment in placenta accreta spectra syndrome for control of bleeding: a prospective case series study

Maheer Elesawi¹, Hamed Yosef², Hatem AboHashem³, Khaled Samir⁴

¹ Lecturer of Obstetrics and Gynecology, Faculty of Medicine – Mansoura University

² professor of Obstetrics and Gynecology, Faculty of Medicine – Mansoura University

³ professor of Obstetrics and Gynecology, Faculty of Medicine – Mansoura University

⁴ Lecturer of Obstetrics and Gynecology, Faculty of Medicine – Mansoura University

Abstract

Background: The placenta accreta spectrum (PAS) is a worldwide health problem due to increasing cesarean section rates. A severe maternal complication can occur due to bleeding and invasion of nearby organs. Although many techniques were described to help in intraoperative management, no standard agreement on the best one, and unfortunately, in many conditions, cesarean hysterectomy can only save the mother's life. There's a must to find out new techniques that could help in preserving the uterus.

Objective: This prospective study was taken on 26 patients at Mansoura University Hospital diagnosed with PAS. There were 13 cases PAS grade 1, 7 cases grade 2, 6 cases grade 3A. All the cases were electively delivered at 37 w. Purse string suturing was done to plicate the lower uterine segment and provide natural tamponade to decrease blood loss from the placental bed and preserve the uterus.

Results: the success rate of the procedure in preserving the uterus was 96%. The average blood loss was 1557.69 ± 318.96. Massive blood loss (2500 ml) occurred in 1 case, intraoperative after the procedure. The procedure is simple, not time-consuming, and no special skills are required. A large number of patients and long term follow up are needed to ensure the efficacy of the procedure and the state of future fertility.

Conclusion: management of patients with PAS should be individualized according to PAS grade and patient wishes. The purse-string suture technique can help in reducing blood loss and decrease the cesarean hysterectomy rate.

Keywords: Placenta accrete spectra syndrome, cesarean hysterectomy, lower uterine segment, a purse-string suture.

Corresponding author:
Maheer Elesawi

Introduction

The placenta accreta spectrum (PAS) is a severe obstetric complication of placental invasion into the uterine wall (1). It is associated with serious maternal morbidities globally, and its prevalence is likely to increase due to increasing rates of cesarean sections (C.S) (2)(3)(4).

However, accurate determination of its prevalence and outcome is problematic because most reports lack histopathologic examination (5) (6).

Maternal outcomes depend mainly on diagnosing the condition before (6) or during delivery (7). Cesarean hysterectomy is still the standard of management of PAS to avoid catastrophic haemorrhage (8). However, it is associated with significant maternal morbidities from bleeding, visceral injuries, sepsis, coagulopathy, and the potential risk of mortality (9).

Successful conservative management of PAS has a good impact on a woman's social status and self-esteem (10) and preserving the women's fertility. (11).

Jauniaux et al. defined conservative management as cutting the umbilical cord short and leaving the placenta in situ with close follow-up until resorption of the placenta (12). Some surgical techniques have been described in the literature to help in the conservative management of PAS with variable degrees of success (13).

Obstetricians face a real challenge in delivering such cases without a clear consensus on the best surgical technique(s) to manage PAS. Patients who opt for uterine conservation should be counselled; they may ultimately require an urgent cesarean hysterectomy to save their lives. (14–20).

Innovative techniques to tackle this problem are desperately needed. In this study, we report on a novel purse-string suture technique of the lower uterine segment that helps with

the conservative management of PAS, reducing blood transfusion, shortening the operative time, and decreasing overall morbidity associated with cesarean hysterectomy.

Patients and methods

This prospective study was carried out in Mansoura University Hospital, Mansoura, Egypt, on 26 patients, between February 2020 and February 2021, after approval from the institutional research committee (IRB: R.20.02.736.R1), faculty of medicine, Mansoura University.

The patients included in this trial were pregnant in their late third trimester, with a history of one or more previous C.S., diagnosed with PAS by ultrasound, and confirmed intraoperatively as PAS grade 1, 2, 3(A) according to FIGO classification (20). Patients with PAS grade 3(B, C) and extensive adhesions make the lower uterine segment inaccessible; patients with medical disorders or patients with coagulopathy at the time of C.S were excluded.

The primary outcome was the number of patients with successful conservation of the uterus. The secondary outcomes were blood loss (measured directly by weight of soaked towels plus the amount in suction apparatus worked only after delivery of the baby, mean difference between pre-and postoperative haemoglobin levels), number of transfused packed RBCs, and visceral injuries.

Steps of the procedure

1. General anaesthesia was given to all patients, 1 gm cefotaxime before anaesthesia was given, and a wide lower transverse abdominal incision with complete haemostasis was done. The baby was delivered through a transverse incision of the uterus above the suspected margin of the placenta (12), followed by Cord clamping after 30 sec, exteriorization of the uterus, haemostasis of the uterine incision edges was done using many curved artery clamps as shown in figure (1).

2. The following ecbolics were given to all patients: Ergometrine 0.25 MGM + syntocinon 10 I.U., I.V, Carbeprost i.v injection to enhance uterine contraction and separation of non-adherent placental parts.
3. Sharp and/or blunt dissection of the urinary bladder from the lower uterine segment was done to the level of the internal cervical os.
4. Gentle trial of placental separation using controlled cord traction, the adherent parts will be removed by blunt and or sharp excision (8).
5. Purse string suture, using Vicryl 1(Ethicon, Johnson & Johnson international), was inserted with a large 1/2c rounded needle (48 mm) starting from the lowest accessible part on the lower uterine segment (above the level of the cervix), taking the entire thickness of the uterine wall including the decidua/placental tissues, moving in the anti-clock direction, taking bites from the most left lateral border of the anterior lower uterine segment, then 2 cm below lower uterine C.S incision edge, toward the right lateral border of the lower uterine segment, reaching near the starting point, then gentle traction on the threads to plicate the lower uterine segment and compress the whole anterior wall of the lower uterine segment including placental remnants as shown in figure (2).

All patients were followed up by telephone weekly to 6 weeks postpartum and were asked to contact us or return immediately if there is bleeding, offensive discharge, fever, or excessive lower abdominal pain.

Statistical Analysis

Statistical analysis was performed using the SPSS 19 system (SPSS Inc., Chicago, IL, United States). Continuous data were expressed as the mean \pm S.D., and categorical

variables expressed as a percentage. Means were compared using the unpaired student's t-test, while proportions were compared using the chi-squared test. A P-value of less than 0.05 was considered statistically significant.

Results

This study was carried out on 26 patients using those mentioned above purse-string suturing techniques of the lower uterine segment. Patients' demography is illustrated in table(1). The mean age of patients was 30.54 ± 5.34 ; the mean C.S number was 2.0 (1.0-5.0). According to the FIGO grading of PAS (2), there were 13 cases grade 1, 7 cases grade 2, 6 cases grade 3A using. All the cases were delivered at 37 w, in elective conditions. The estimated time to do this procedure (the suture) was 2-3 minutes.

In our study, the success rate in preserving the uterus is 96%. Massive blood loss (2500 ml) occurred in 1 case, intraoperative after the procedure, due to more placental tissue in place and over thinning of the uterine wall, urgent hysterectomy was done due to hemodynamic instability.

The average blood loss was 1557.69 ± 318.96 ; 5 patients (19.2%) reported 2000 ml or more blood loss; the mean number of packed red blood cells transfused was 2.5(1.0-4.0). The mean preoperative haemoglobin was 10.93 ± 0.67 while the postoperative one was 10.45 ± 0.91 ($t=2.01$, $p=0.06$)

Uterine artery ligation on multiple levels was needed as an extra procedure in 1 case, as the patient continues to bleed after purse-string sutures due to more placental invasion into lateral uterine walls.

The average postoperative hospital stay is 6.0 days (3.0-8.0). All patients were discharged from the hospital in good condition, and no reoperations or readmissions were required. Fortunately, the puerperia of the patients were uneventful, and patients recover well.

Discussion

Varying grades of invasion may be found in the same placenta, creating technical surgical challenges, especially if there is extrauterine invasion (13).

The purse-string suturing technique is effortless, doesn't require special surgical skills as in internal iliac artery ligation, is not time-consuming, and allows the preservation of the lower uterine segment instead of resection. Cervical lips are not a part of the procedure, so, no cervical distortion. There is no risk of obliterating the uterine cavity or hematomata, as the technique involves only the anterior wall.

Purse string suturing mostly control PPH by compressing bleeding areas of the endometrium and myometrium, as the sutures involve the whole wall thickness.

Compared to other techniques, it is a blood-saving procedure; the average blood loss is 1557.69 ± 318.96 , nearly the same as the cervical inversion technique (1572.5 mL) published by Elgelany et al. (19). Both multifaceted sutures proposed by Meng et al. (18) and multi-positional spiral sutures posted by Liu et al. (21), the average blood losses were 1327.3 ± 1244.1 mL, (1696 ± 1397) mL respectively.

The systematic review by Jauniaux et al. (22) reported an 89.7% (208/232) elective or emergent cesarean hysterectomy rate. In our study, the success rate in preserving the uterus is 96%. Meng et al. (18), using multifaceted sutures, reported no cesarean hysterectomy case, while using multi-positional spiral suture achieve uterine preservation in 94% (36/38) of patients (21), nearly the same as in the case of cervical inversion technique (95%)(19).

The mean time needed to perform cervical inversion(19) was 5.4 ± 0.6 min, nearly double the time in our procedure which helps in reducing blood loss and further blood transfusion.

The drawbacks of this study are the limited number of patients, lack of long-term follow-up, and state of future fertility. The placental remnants embedded in the uterine wall could predispose to infection, pyometra, and postpartum haemorrhage.

Uterine wall necrosis can occur due to compression of the feeding vessels and the massive dissection of the bladder from the lower uterine segment to place the suture. Finally, the technique cannot be applied to FIGO grade 3 B, C. Studies with a large number of patients are required to guarantee the technique's safety to incorporate it in the algorithm of management of PAS.

Conflict of interest

None

Aknowledgemt

I would like to thank Dr Mohamed Sayed Abdelhafez and Dr Mohamed Khairy for their kind support and helpful guidance in this work.

References

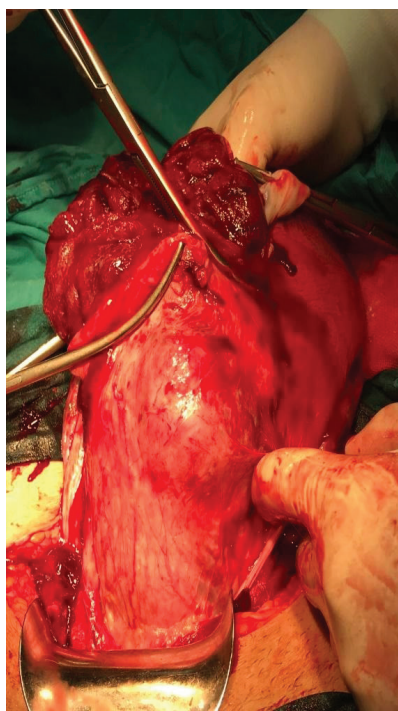
1. De Vita D, Capobianco G, Gerosolima G, Sciorio C, Coppola E, Parazzini F, Silvestri M, Caruso AP, Morlando M, Petta R, Pascarella A. Clinical and ultrasound predictors of placenta accreta in pregnant women with antepartum diagnosis of placenta previa: a multicenter study. *Gynecologic and obstetric investigation*. 2019;84(3):242-7.
2. Jauniaux E, Ayres-de-Campos D, Langhoff-Roos J, Fox KA, Collins S, FIGO Placenta Accreta Diagnosis and Management Expert Consensus Panel, Duncombe G, Klaritsch P, Chantraine F, Kingdom J, Grønbeck L. FIGO classification for the clinical diagnosis of placenta accreta spectrum disorders. *International Journal of Gynecology & Obstetrics*. 2019;146(1):20-4.
3. Jauniaux E, Moffett A, Burton GJ. Placental implantation disorders. *Obstetrics and Gynecology Clinics*. 2020;47(1):117-32.
4. Happe SK, Yule CS, Spong CY, Wells CE,

- Dashe JS, Moschos E, et al. Predicting placenta accreta spectrum: validation of the placenta accreta index. *J Ultrasound Med*. 2021;40(8):1523–32.
5. Jauniaux E, Ayres-de-Campos D, Langhoff-Roos J, Fox KA, Collins S, FIGO Placenta Accreta Diagnosis and Management Expert Consensus Panel, Duncombe G, Klaritsch P, Chantraine F, Kingdom J, Grønbeck L. FIGO classification for the clinical diagnosis of placenta accreta spectrum disorders. *International Journal of Gynecology & Obstetrics*. 2019;146(1):20-4.
6. Jauniaux E, Burton GJ. From Etiopathology to Management of Accreta Placentation. *Current Obstetrics and Gynecology Reports*. 2019;8(3):55-63.
7. Jauniaux E, Bunce C, Grønbeck L, Langhoff-Roos J. Prevalence and main outcomes of placenta accreta spectrum: a systematic review and meta-analysis. *American journal of obstetrics and gynecology*. 2019;221(3):208-18.
8. Sentilhes L, Kayem G, Chandrachan E, Palacios-Jaraquemada J, Jauniaux E. FIGO consensus guidelines on placenta accreta spectrum disorders: conservative management. *International Journal of Gynecology & Obstetrics*. 2018;140(3):291-8.
9. Collins SL, Sentilhes L, Chantraine F, Jauniaux E. Delayed hysterectomy: a laparotomy too far?. *American journal of obstetrics and gynecology*. 2020;222(2):101-2.
10. Sentilhes L, Kayem G, Chandrachan E, Palacios-Jaraquemada J, Jauniaux E. FIGO consensus guidelines on placenta accreta spectrum disorders: conservative management. *International Journal of Gynecology & Obstetrics*. 2018;140(3):291-8.
11. El Gelany S, Mosbeh MH, Ibrahim EM, Khalifa EM, Abdelhakium AK, Yousef AM, Hassan H, Goma K, Abd Alghany A, Mohammed HF, Azmy AM. Placenta Accreta Spectrum (PAS) disorders: incidence, risk factors and outcomes of different management strategies in a tertiary referral hospital in Minia, Egypt: a prospective study. *BMC pregnancy and childbirth*. 2019;19(1):1-8.
12. Jauniaux E, Chantraine FF, Silver RM, Langhoff-Roos J, Duncombe G, Klaritsch P, et al. FIGO consensus guidelines on placenta accreta spectrum disorders: Conservative management,. *International Journal of Gynecology & Obstetrics* [Internet]. 2018 [cited 2020 Jul 7];140(3):291–8.
13. Kingdom JC, Hobson SR, Murji A, Allen L, Windrim RC, Lockhart E, Collins SL, Majd HS, Alazzam M, Naaisa F, Shamshirsaz AA. Minimizing surgical blood loss at cesarean hysterectomy for placenta previa with evidence of placenta increta or placenta percreta: the state of play in 2020. *American journal of obstetrics and gynecology*. 2020;223(3):322-9.
14. Palacios-Jaraquemada JM, Fiorillo A, Hamer J, Martínez M, Bruno C. Placenta accreta spectrum: a hysterectomy can be prevented in almost 80% of cases using a resective-reconstructive technique. *The Journal of Maternal-Fetal & Neonatal Medicine*. 2020:1-8.
15. Hobson SR, Murji A, Allen L, Windrim RC, Lockhart E, Collins SL, Majd HS, Alazzam M, Naaisa F, Shamshirsaz AA, Belfort MA. Minimizing Surgical Blood Loss at Cesarean Hysterectomy for Placenta Previa With Evidence of Placenta Increta or Placenta Percreta: The State of Play in 2020. *Obstetric Anesthesia Digest*. 2021;41(2):76.
16. Chevalier G, Devisme L, Coulon C. Placenta accreta spectrum disorder: Management and morbidity in a French type-3 maternity. *Gynecol Obstet Fertil Senol*. 2020;48(6):500–5.
17. Abo-Elroose AA, Ahmed MR, Shaaban MM, Ghoneim HM, Mohamed TY. Triple P with T-shaped lower segment suture; an effective novel alternative to hysterectomy in morbidly adherent anterior placenta previa. *The Journal of Maternal-Fetal & Neonatal Medicine*. 2021;34(19):3187-91.
18. Meng Y, Wu P, Deng D, Wu J, Lin X, Beejadhursing R, Zha Y, Qiao F, Feng L, Liu H, Zeng W. Multifaceted spiral suture: a hemostatic technique in managing placenta praevia or accrete: a retrospective study. *Medicine*. 2017;96(49).
19. El Gelany SAA, Abdelraheim AR, Mohammed MM, Gad El-Rab MT, Yousef AM, Ibrahim EM, et al. The cervix as a natural tamponade in postpartum hemorrhage caused by placenta previa and placenta previa accreta: A prospective study. *BMC Pregnancy Childbirth*. 2015;15(1).

20. Jauniaux E, Hussein AM, Fox KA, Collins SL. New evidence-based diagnostic and management strategies for placenta accreta spectrum disorders. *Best Practice & Research Clinical Obstetrics & Gynaecology*. 2019;61:75-88.
21. Liu HY, Lin XG, Wu JL, Qiao FY, Deng DR, Zeng WJ. Multiposition spiral suture of the lower uterine segment: a new technique to control the intraoperative bleeding of pernicious placenta previa. *Zhonghua fu Chan ke za zhi*. 2016;51(10):754-8.
22. Jauniaux E, Bhide A. Prenatal ultrasound diagnosis and outcome of placenta previa accreta after cesarean delivery: a systematic review and meta-analysis. *American journal of obstetrics and gynecology*. 2017;217(1):27-36.

Table (1) patient demography

	n=26	%	
Age/years Mean±SD (range)		30.54±5.34 (21.0-39.0)	
<30	16		61.5
30-35	4		15.4
>35	6		23.1
Gravidity Median (Range)		4.0(2.0-6.0)	
Parity Median (Range)		2.0(1.0-5.0)	
C.S. number Median (Range)		2.0(1.0-5.0)	

Figure (1)**Figure (2)**