

Comparing Breast Tomosynthesis with Conventional Digital Mammography in the Evaluation of the Breast

Medhat M. Refat, Hesham M. El-Gazzar, Osama T. Jalal, Hazem M. Hashish

Department of radiology,
Benha faculty of medicine,
Benha University, Egypt.

Correspondence to:
Hazem M. Hashish,
Department of radiology,
Benha faculty of medicine,
Benha University, Egypt.

Email:

hazemrad@hotmail.com

Received: 31 July 2022

Accepted: 12 October 2022

Abstract

Background: Diagnostic mammography is used to investigate probable abnormalities, evaluate patients who have signs or symptoms, and offer short-term follow-up of patients with presumably benign results. The purpose of this research was to compare DBT with FFDM in the assessment of the breast asymmetries, masses, architectural distortion as well as screening recalls and cancer detection. **Methods:** This cross-sectional investigation comprised 100 females with symptoms as palpable mass, discomfort or indicators like calcifications. The period of the trial varied from 6-12 months. **Results:** DBT finding, more than one third had masses. About 1/3 had uneven form. 13% of the patients showed spiculated margins. 55% of patients had high density. According to morphology fine pleomorphic was detected in 89%. According to distribution 72% had diffuse masses, 13.0% were either clustered or segmental and 2.0% were linear. 1/3 of patients experienced Architectural distortion. The recall rates were observed in 7%. FFDM results identified that 7% had masses and most of them had irregular form (50%), while, the rest had circumscribed margins (5%). Equal densities were identified in 4%. Distribution indicated that 91.0% were diffuse, 2% were clustered and 1% were linear. 4% exhibited architectural distortion. Comparison between their results indicated statistically significant discrepancies.

Conclusion: DBT is a promising imaging modality giving improved identification and characterization of diverse breast abnormalities, particularly in young females, and those with dense breasts with an increase of sensitivity and specificity than FFDM.

Keywords: Breast Tomosynthesis; Conventional Digital Mammography; Evaluation of the Breast

Introduction

Diagnosing and following up on breast cancer symptoms and signs in women who have had a screening mammogram is done using diagnostic mammography, which is used to analyse any possible abnormalities found during the procedure (1).

It is commonly acknowledged, that mammographic screening for early diagnosis of breast cancer decreases mortality. To address mammography's known drawbacks, such as overlapping imaged tissue, researchers are looking at other imaging modalities, like ultrasound, that do not employ x-rays. These methods might be used universally or in targeted subpopulations to supplement or replace mammography (2).

The identification of cancer in women with radiographic dense breasts is the Achilles Heel of screening mammography. Only half of all malignancies will be seen in breasts that are particularly dense, even though most are visible in fatty breasts (3).

To check for any abnormalities in the breast, digital breast tomosynthesis (DBT) is a new imaging technique being developed for diagnostic purposes. For the DBT technique, compressed breast tissue is photographed in a quasi-three-dimensional way by taking many low dose radiography exposures and constructing cross-sectional in-plane pictures using the projection image dataset (4).

s2D mammography, which was authorized by the FDA in May 2013, was constructed

using slab reconstruction from the tomosynthesis collection (5).

Breast asymmetries, masses, architectural distortion, screening recalls, and cancer detection were all studied to see how well breast Tomosynthesis compared to standard Digital Mammography.

Methods and patients are the focus here.

Prospective comparative study was performed.

The approval of Benha ethical committee was obtained before starting the study.

A total of 100 patients were enrolled in this study. The research was done between the years 2018-2019. They were selected from those who were sent to the radiology department for a Mammography and tomosynthesis scan and who had previously been identified with a breast lesion by clinical means (examination and/or ultrasound) as having one of many patterns were randomly assigned to one of 50 research groups.

Inclusions and exclusions

Inclusions:

Female gender.

Screening & non-screening mammography.

Females with relatively dense breast (any density excluding ACR pattern A)

Any age females with symptoms as palpable mass, pain or signs as calcifications, etc.

Females with BI-RADS category 0 in conventional digital mammography.

Exclusions:

Male gender.

Females with totally fatty breast (ACR pattern A).

Patients who met the eligibility requirements were admitted to the study.

- The patient is clinically proven to have a breast lesion (examination and/or ultrasound).
- Mammography and/or tomosynthesis studies for the detection of structural abnormalities.
- Normal breast tomosynthesis with no structural anomalies seems to be an exclusion criterion.

Women in the radiology department had breast mammograms utilizing siemens machines that indicated anomalies and advised further examinations of the breasts.

Tomosynthesis of the breasts

Using a siemens equipment in the radiology department, all patients were scanned. We used breast tomosynthesis to scan all our patients and found structural abnormalities in most of them.

Biopsy, MRI, and/or follow-up investigations were used to confirm the final diagnosis.

Visualization Methods and their Interpretation

Full-field DM or DM plus DBT were used to do mammograms (siemens). Tomosynthesis and conventional DM mammography were used in all DBT exams, but no reconstructed DM images were used. Tomosynthesis was performed exclusively on the mediolateral oblique views of both breasts during the examinations.

BI-RADS, developed by the American College of Radiology, was used to interpret all cases (6).

Additional mammograms and/or ultrasounds were used in diagnostic tests following positive screening findings.

The fifth version of the BI-RADS atlas classifies mammograms as true positive, true negative, false positive, or false negative based on established standards (6).

If a tissue diagnosis of cancer (invasive cancer or ductal carcinoma in situ) was made within one year following a positive screening test, the mammogram was called a true-positive examination (BI-RADS category 0, 3, 4, or 5).

True-negative mammograms were defined as those in which no cancerous tissue was found within a year after a negative screening result (BI-RADS category 1 or 2).

Within one year of a positive screening result, mammograms were deemed false-positive exams if no known tissue diagnosis of cancer was found (BI-RADS category 0, 3, 4, or 5).

If a tissue diagnosis of cancer was made within one year following a negative screening test, mammograms were deemed false-negative screenings (BI-RADS category 1 or 2).

For the record, there were no BI-RADS category 3 initial assessments in our research population. A diagnostic exam with a BI-RADS category 3 evaluation is regarded as negative screening result, whereas a screening exam with a BI-RADS category 3 assessment is considered a positive screening result.

The process of collecting data:

Patients' age, breast density, family history of breast cancer, prior screening history, and modality were all gleaned from the mammography database, which also contained the following data: types of mammographic findings, BI-RADS final assessment categories, image-guided core needle biopsy results, and surgical pathology results within one year of the mammogram (DM or DBT). Anatomical histology was assessed in surgical pathology reports for cancer patients (invasive vs in situ cancer).

Data analysis using statistical methods

IBM SPSS software version 20.0 was used to analyse the data given into the computer (Armonk, NY: IBM Corp). A number and a percentage were used to describe the data in the qualitative section of the report. The normality of the distribution was confirmed using the Kolmogorov-Smirnov test. The range (minimum and maximum), the mean, and the standard deviation were used to characterize quantitative data. The

significance of the findings was evaluated at a 5% level of significance. The Chi-square test, the student t-test, and the Mann Whitney test were all used.

Results

Breast tomosynthesis results are shown in table (1) and figure (1). Masses were found in 39.0% of the participants. About one third of the specimens were shaped in an uneven manner (31.0 %). Spiculated margins were the most common kind of patient margin (13.0 percent). One quarter of the patients exhibited a high density of cells (25.0 %). The bulk of the specimens showed fine pleomorphic features, as shown by morphology (89.0 percent). Diffusion, grouping, segmentation and linearity were all found in (72.0%), (13.0%), and (2.0%) respectively. An architect's distortion was seen in one-third of the individuals we examined and the recall rates were discovered (7.0 %).

Table 2 and figure 2 demonstrate the results of conventional digital mammography on the examined group. According to traditional digital mammography findings, 7% of women have masses, 4% of which had an irregular form, with circumscribed margins in 5% of cases. The same density was seen in 4.0 %. Most people (91%), as shown by morphology, possessed fine pleomorphic. 91.0 % had diffuse distributions, 2 % were in groups, and 1% had linear distributions. 4.0% of the buildings suffered architectural distortions.

Statistically significant differences may be seen between conventional digital

mammography findings and breast tomosynthesis findings (Table 3).

Table (1): Distribution of studied sample according to breast tomosynthesis finding

	Number	Percent
Masses	39	39.0
Shape		
No	61	61.0
Irregular	31	31.0
Oval	5	5.0
Round	3	3.0
Margins		
No	61	61.0
Obscured	11	11.0
Circumscribed	6	6.0
Indistinct	8	8.0
Spiculated	13	13.0
Micro lobulated	1	1.0
Density		
High density	25	25.0
Equal density	4	4.0
Low density	10	10.0
Fat containing	61	61.0
Morphology		
Fine pleomorphic	89	89.0
Amorphous	4	4.0
Coarse heterogeneous	2	2.0
Fine linear and branching	5	5.0
Distribution		
Diffuse	72	72.0
Grouped	13	13.0
Segmental	13	13.0
Linear	2	2.0
Architectural distortion	33	33.0
The recall rates	7	7.0

Table (2): Distribution of studied sample according to conventional digital mammography finding

	Number	Percent
Masses	7	7.0
Shape		
No	93	93.0
Irregular	4	4.0
Oval	1	1.0
Round	2	2.0
Margins		
No	93	93.0
Obscured	1	1.0
Circumscribed	5	5.0
Indistinct	0	0.0
Spiculated	0	0.0
Micro lobulated	1	1.0
Density		
High density	2	2.0
Equal density	4	4.0
Low density	1	1.0
Fat containing	93	93.0
Morphology		
No	6	6.0
Fine pleomorphic	91	91.0
Amorphous	2	2.0
Coarse heterogeneous	1	1.0
Fine linear and branching	0	0
Distribution		
No	6	6.0
Diffuse	91	91.0
Grouped	2	2.0
Segmental	0	0.0
Linear	1	1.0
Architectural distortion	4	4.0

Table (3): Comparison between conventional digital mammography finding and Breast tomosynthesis finding

	Conventional digital mammography finding		Breast tomosynthesis finding		Test of Sig.	P value
	No.	%	No.	%		
Masses	7	7.0	39	39.0	----	<0.001*
Shape						
No	93	93.0	61	61.0		
Irregular	4	4.0	31	31.0	30.345	<0.001*
Oval	1	1.0	5	5.0		
Round	2	2.0	3	3.0		
Margins						
No	93	93.0	61	61.0		
Obscured	1	1.0	11	11.0		
Circumscribed	5	5.0	6	6.0	36.074	<0.001*
Indistinct	0	0.0	8	8.0		
Spiculated	0	0.0	13	13.0		
Micro lobulated	1	1.0	1	1.0		
Density						
High density	2	2.0	25	25.0		>0.001*
Equal density	4	4.0	4	4.0		
Low density	1	1.0	10	10.0	33.606	<0.001*
Fat containing	93	93.0	61	61.0		
Morphology						
No	6	6.0	0	0		
Fine pleomorphic	91	91.0	89	89.0		
Amorphous	2	2.0	4	4.0	12.022	0.017*
Coarse heterogeneous	1	1.0	2	2.0		
Fine linear and branching	0	0	5	5.0		
Distribution						
No	6	6.0	0	0		
Diffuse	91	91.0	72	72.0		
Grouped	2	2.0	13	13.0	29.615	<0.001*
Segmental	0	0.0	13	13.0		
Linear	1	1.0	2	2.0		
Architectural distortion	4	4.0	33	33.0	----	<0.001*

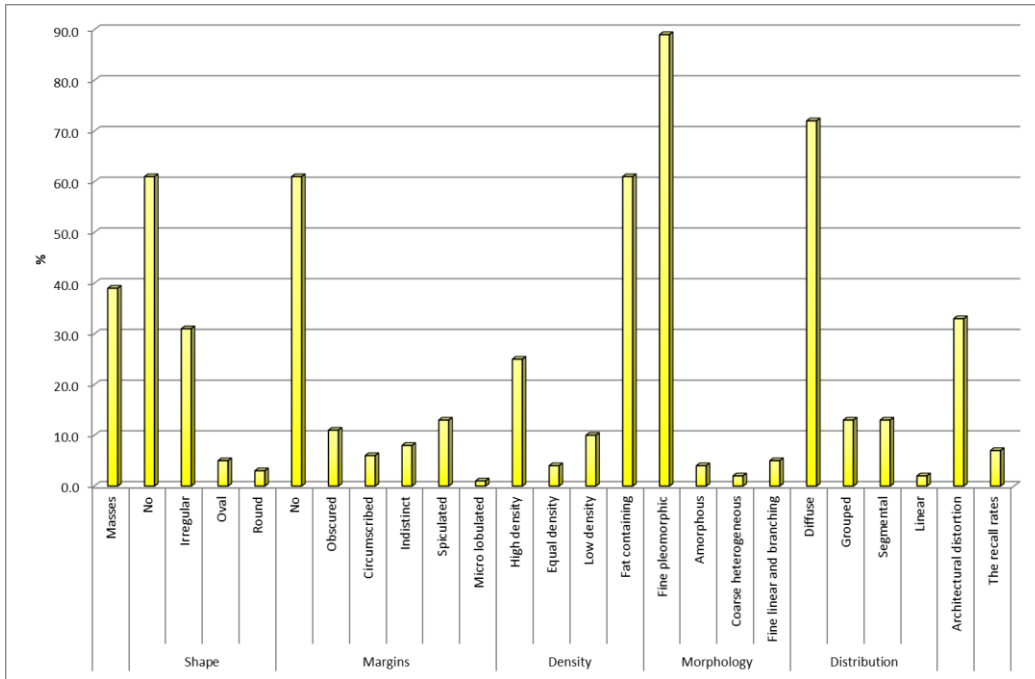


Fig. (1): Distribution of studied sample according to breast tomosynthesis finding

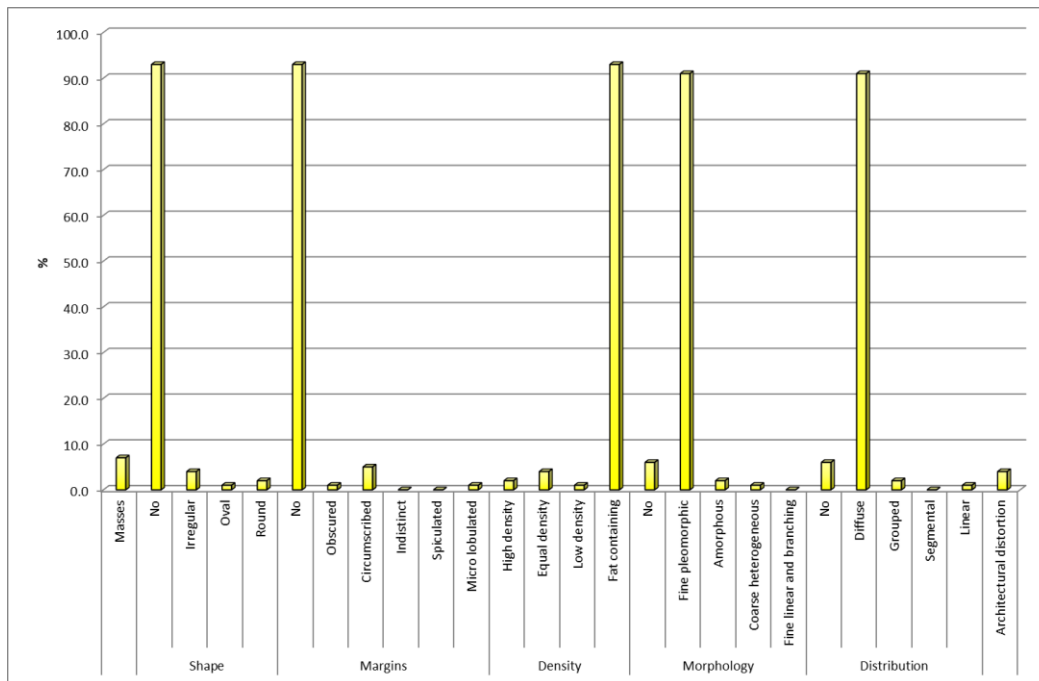


Fig. (2): Distribution of studied sample according to conventional digital mammography finding

Discussion

A far as the results of breast tomosynthesis are concerned. Masses were found in 39.0% of the participants. About one third of the specimens were shaped in an uneven manner (31.0 %). Spiculated margins were the most common kind of patient margin (13.0 percent). One quarter of the patients exhibited a high density of cells (25.0 %). The bulk of the specimens showed fine pleomorphic features, as shown by morphology (89.0 percent). Diffusion, grouping, segmentation and linearity were all found in (72.0%), (13.0%), and (2.0%) respectively. An architect's distortion was seen in one-third of the individuals we examined and the recall rates were discovered (7.0 %).

Tomosynthesis detected asymmetries in 28.5% of the cases (OR 1.3%; CI 95% 0.98-1.8; p=0.109) (7), architectural distortion in 58.8% (OR 4.8%; CI 95% 2.7-8.6; p0.001), microcalcifications in 80% (OR 14.4%; CI 95% 7.3-28.3; p0.001), and nodules in 53. There was a nodule and architectural deformation that led to a suspicion of cancer being made.

DBT detected lesions in 39% of cases opposed to 7% to conventional digital mammography due to the capabilities of overcoming the overlap of tissues (8) (81.1 percent), from which cases were classified as malignant lesions (BIRADS scores IV & V), while benign lesions were assigned to BIRADS scores II & III), and negative cases were classified as BIRADS score I).

A previous study (9) declared that, tomosynthesis may be used to analyze upgraded and downgraded lesions. The BIRADS of three lesions (5.5%) were lowered. Lesions that were elevated to a higher BIRADS, however, were seen in 27 (50%).

Only mammography screening has been shown to minimize breast cancer mortality when performed in the early stages, making it an excellent imaging method for early diagnosis of breast cancer. Mammograms may, however, be difficult to interpret because of the appearance of tissue overlap (10).

When it comes to traditional digital mammography findings, we have research in our hands. According to traditional digital mammography findings, 7 % of women had masses, 50% of which have an irregular form, with circumscribed margins in 5% of the cases. Equal numbers of masses were found in each of the four segments of either breast. Most people, as shown by morphology, possessed fine pleomorphic (91.0 percent). 91% had diffuse distributions, 2% had clusters, and 1% had linear distributions. 4.0% of the cases suffered architectural distortions.

Greater breast density had a substantial impact on mammography's capacity to detect breast cancer (11). Mammograms in these women were misread, and they were given ACR3 (48.2 %, n = 80/166) and ACR4 (20.5%, n = 34/166) breast densities.

16 patients had suspicious calcification in the form of small pleomorphic calcification and 24 patients had benign calcification in the form of popcorn, dystrophic, and arterial calcification out of 40 patients (9) . As a result, only 33 instances were categorized by DBT as having worrisome micro calcification and 21 as having benign-looking calcification, which is consistent with the findings of other diagnostic methods.

Breast density has been linked to an increased risk of breast cancer (12). There was a significant decrease in sensitivity and specificity of mammograms in dense breasts when compared to non-dense breasts, and the sensitivity was 62.8% in dense breasts and 96.5% in non-dense breasts.

Dense breast tissue has been linked to an increased risk of breast cancer on its own. Dense breast tissue varies from non-dense breast tissue in that it contains regions of increased density, which might obscure lesions on mammography. In thick breasts, up to 27% of breast cancers are undetected (13).

This study found substantial disparities between traditional digital mammography and breast tomosynthesis findings when compared side by side.

Digital breast tomosynthesis performed better than full-field digital mammography in all breast densities and across all age groups, corroborated our findings (8). When it came to the identification and characterization of various breast lesions in relation to the final diagnosis, they found

that digital breast tomosynthesis was superior to FFDM. Adding DBT to FFDM also improved the overall diagnostic capabilities, according to the researchers. FFDM's sensitivity for lesion detection was 100%, whereas DBT's was 100%, whereas DBT's specificity was 97%, whereas FFDM's was 77%, whereas DBT's predictive value for positive outcomes was 97%, whereas FFDM's was 100%, whereas DBT's negative outcomes were 100%, and the diagnostic accuracy was 97%, whereas FFDM's was 71%.

More than one study (14,15,16) revealed, higher sensitivity, specificity, and cancer detection when DBT was applied. Increased sensitivity from 54.1 to 70.5 % and modest specificity from 94% to 95% were discovered in a previous study (15) when utilizing DBT instead of digital mammography. After FFDM was included, in a study done by **Singla et al (2018)** the sensitivity test went up by 83.6 % while specificity went up by 38.7 % and positive predictive value went up by 81.67 % when DBT was added (16).

With DBT, women of all breast densities noticed an increase in the number of hypothesized masses or architectural deformities, with P values of 0.001 and more in women with dispersed fibroglandular and heterogeneous breast densities.

Additional studies have been done on thick breasts with tomosynthesis for screening or diagnosis, (18) (19). In compared to mammography alone, they found that DBT

improved sensitivity and the rate of cancer detection during screening and diagnosis.

Research was conducted on digital mammography alone and digital mammography combined with tomosynthesis for the detection of breast cancer in dense and non-dense breasts (20). They found that women with heterogeneously thick breasts had a higher incidence of cancer detection and a lower rate of recall when tomosynthesis was used into digital mammography.

Comparing the efficacy of tomosynthesis and digital mammography in community practice based on the age of the patients, number of rounds of screening performed, and the density of the breasts (21). They concluded that digital breast tomosynthesis outperformed digital mammography in terms of recall and cancer detection rates for women aged 40 to 79 with heterogeneously dense breasts and for women aged 50 to 79 with scattered fibro-glandular density; however, in women with extremely dense breasts, the performance was similar.

Conclusion

DBT is a promising imaging technique that, compared to FFDM, is more sensitive and specific in detecting and characterizing various breast abnormalities, particularly in young women and those with thick breasts.

References

1. **American College of Radiology.(2014)** ACR practice guideline for the performance of screening and diagnostic mammography. <http://www.acr.org/Quality-Safety/Standards->

Guidelines/ Practice-Guidelines-by-Modality/Breast-Imaging. Updated 2013. Accessed March 1, 2014.

2. **Sickles EA.(2010)** The use of breast imaging to screen women at high risk for cancer. *Radiol Clin North Am* 2010;48(5):859–878.
3. **Roubidoux MA, Bailey JE, Wray LA, Helvie MA.** Invasive Cancers Detected after Breast Cancer Screening Yielded a Negative Result: Relationship of Mammographic Density to Tumor Prognostic Factors. *Radiology.* 2004;230:42–48.
4. **Heather R. Peppard ,Brandi E. Nicholson, Carrie M. Rochman, Judith K. Merchant., et al (2015):** Digital Breast Tomosynthesis in the Diagnostic Setting: Indications and Clinical Applications. [RadioGraphics](#) ; [Vol. 35, No. 4](#) : Pages:975–990.
5. **Samantha P. Zuckerman, Emily F. Conant, Brad M. Keller., et al.(2016)** Implementation of Synthesized Two-dimensional Mammography in a Population-based Digital Breast Tomosynthesis Screening Program, *Radiology: Volume 281: Number 3—* December 2016.
6. **Sickles EA, D’Orsi CJ, Bassett LW. (2013):** ACR BI-RADS mammography. In: *ACR BI-RADS Atlas, Breast Imaging Reporting and Data System.* Reston, Va: **American College of Radiology.**
7. **Santos Aragon LN, Soto-Trujillo D (2021).** Effectiveness of Tomosynthesis Versus Digital Mammography in the Diagnosis of Suspicious Lesions for Breast Cancer in an Asymptomatic Population. *Cureus.* Mar 11;13(3):e13838.
8. **Rana M. Naeim, Rania A. Marouf, Merhan A. Nasr , Marwa E. Abd El-Rahman (2021).** Comparing the diagnostic efficacy of digital breast tomosynthesis with full-field digital mammography using BI-RADS scoring. *Egyptian Journal of Radiology and Nuclear Medicine,* 52(1), 1-13.
9. **Riham A.H AbdelAal Mohamed, Abd E.N Yassen, Abdullah H Ahmed (2021).** The role of tomosynthesis in evaluation of suspicious solid breast lesion in comparison with mammography and ultrasonography in patients

- over 30 years old. The Scientific Journal of Al-Azhar Medical Faculty, Girls, 5(4), 847.
10. **Si Eun Lee, Kyunghwa Han, Eun-Kyung Kim (2021).** Application of artificial intelligence-based computer-assisted diagnosis on synthetic mammograms from breast tomosynthesis: comparison with digital mammograms. *European Radiology*, 31(9), 6929-6937.
 11. **Sahar Mansour., LamiaAdel., Omina Mokhtar, Omar Sherif Omar (2014).** Comparative study between breast tomosynthesis and classic digital mammography in the evaluation of different breast lesions. *The Egyptian Journal of Radiology and Nuclear Medicine*, 45(3), 1053-1061.
 12. **Chiu SY, Duffy S, Yen AM. (2010).** Effect of baseline breast density on breast cancer incidence, stage, mortality, and screening parameters: 25-year follow-up of a Swedish mammographic screening. *Cancer Epidemiol Biomark Prev* 19(5):1219–1228.
 13. **Nazari, S. S., & Mukherjee, P (2018).** An overview of mammographic density and its association with breast cancer. *Breast cancer*, 25(3), 259-267.
 14. **Conant, E. F., Barlow, W. E., Herschorn, S. D. (2019).** Association of digital breast tomosynthesis vs digital mammography with cancer detection and recall rates by age and breast density. *JAMA Oncol*
 15. **Skaane p, Bandos AL, Niklason LT. (2019).** Digital mammography versus digital mammography plus tomosynthesis in breast cancer screening: the Oslo tomosynthesis screening trial. *Radiology* 291(1):23–30
 16. **Singla D, Chaturvedi AK, Aggarwal A, Rao SA, Hazarika D, Mahawar V. et al (2018)** Comparing the diagnostic efficacy of full field digital mammography with digital breast tomosynthesis using BIRADS score in a tertiary cancer care hospital. *Indian Journal of Radiology and Imaging*. 2018 Jan;28(01):115-22.
 17. **Østerås BH, Martinsen ACT, Gullien R. (2019).** Digital mammography versus breast tomosynthesis: impact of breast density on diagnostic performance in population-based screening. *Radiology*:190425.
 18. **Phi XA, Tagliafico A, Houssami N. (2018).** Digital breast tomosynthesis for breast cancer screening and diagnosis in women with dense breasts - a systematic review and meta-analysis. *BMC Cancer* 18(1):380.
 19. **Asbeutah A, Karmani N, Asbeutah A. (2018).** Comparison of digital breast tomosynthesis (DBT) and digital mammography (DM) for detection of breast cancer in women in Kuwait. *Med PrincPract* 28(1):10–15.
 20. **Rafferty EA, Durand MA, Conant EF, Copit DS, Friedewald SM, Plecha DM, et al. (2016).** Breast cancer screening using tomosynthesis and digital mammography in dense and nondense breasts. *JAMA* 315:1784–1786.
 21. **Lowry, K. P., Coley, R. Y., Miglioretti, D. L., et al. (2020).** Screening performance of digital breast tomosynthesis vs digital mammography in community practice by patient age, screening round, and breast density. *JAMA Network open*, 3(7), e2011792-e2011792.

To cite this article: Medhat M. Refat, Hesham M. El-Gazzar, Osama T. Jalal, Hazem M. Hashish. Comparing Breast Tomosynthesis with Conventional Digital Mammography in the Evaluation of the Breast. *BMFJ* 2024;41(7):1-12.