



International Journal of Health Sciences (Egypt)

Journal homepage: <https://ijhegy.journals.ekb.eg/>

Original article

The Use of infliximab in Treatment of Uveitis Associated with Behcet's disease

Mortada Ahmed Abozaid ^{*1}, Rana Nasser Saad-eldin²

1- Department of Ophthalmology, Faculty of Medicine, Sohag University, Sohag, Egypt.

2- Department of Rheumatology and rehabilitation, Faculty of Medicine, Sohag University, Sohag, Egypt..

ARTICLE INFO

Article history:

Received 26 March 2023

Received in revised form 7 April 2023

Accepted 7 April 2023

Keywords:

Anti-TNF

Behcet's disease

Infliximab

Steroid sparing

Uveitis

ABSTRACT

Purpose: to assess the safety and efficacy of infliximab in the treatment of uveitis associated with Behcet's disease. **Methods:** fifty patients with Behcet's related uveitis were included in this prospective comparative study. Cases were divided into 2 groups; group A(25 patients) received infliximab and group B (25 patients) received oral steroids. All cases were followed up to one year. **Results:** In group A, the mean BCVA (logMAR) improved from 0.48 ± 0.14 at baseline to 0.07 ± 0.12 three months after treatment. Also, the number of cases with grade 0 AC cells increased from 0 before starting treatment to 18 after 3 months. In group B, the mean BCVA (logMAR) improved from 0.47 ± 0.13 at baseline to 0.17 ± 0.15 three months after treatment. Also, the number of cases with grade 0 AC cells increased from 0 before starting treatment to 14 after 3 months. **Conclusion:** Infliximab is both safe and effective in treating uveitis associated with Behcet's disease. Studies with larger sample size and longer follow-up periods are needed to confirm the results.

Introduction

Behcet's disease is an inflammatory disorder of unknown cause characterized by multisystemic manifestations and a chronic, relapsing course. It is a vasculitis involving small and large blood vessels especially the veins [1, 2]. The disease is characterized by a triad of recurrent oral ulcerations, genital ulcerations and ocular inflammation in addition to neurological, gastrointestinal and articular manifestations [3]. It has a high prevalence in countries between the Mediterranean region and the eastern Asia [4]. Although its etiology is unknown; it appears to be

multifactorial with interaction between genetic and environmental factors with human leukocyte antigen (HLA) B51 being the most important genetic factor associated with Behcet's disease [5,6]. Although ocular involvement occurs usually 2–4 years after onset of the disease, it could be the initial presentation in 10–20% of cases [7] with marked impairment of vision seen in 25% of patients [8]. End-stage ocular disease from repeated attacks of uveitis is characterized by blindness with optic atrophy, attenuated vessels and diffuse retinal atrophy [9]. The prognosis of

DOI: 10.21608/ijhegy.2023.202225.1013

* Corresponding author: Mortada A Abozaid

E-mail address: mourtada_abdelaal@med.sohag.edu.eg

© 2023 The author (s). Published by Sharkia Medical Syndicate, Egypt. This is an open access article under the CC BY 4.0 license <https://creativecommons.org/licenses/by/4.0/>.

eye involvement has improved markedly in the last years thanks to new treatment options such as anti-tumour necrosis factor alpha (anti-TNF α) drugs especially for refractory or severe ocular involvement [10]. Tumor necrosis factor-alpha (TNF- α) is a pro-inflammatory cytokine associated with chronic inflammatory diseases. Infliximab is a monoclonal immunoglobulin G antibody and tumor necrosis factor alpha blocker that was first approved in 1998 as an intravenous injection produced under the name Remicade. It disrupts the interaction of TNF- α with its receptors [11]. The purpose of this study is to assess the safety and efficacy of infliximab drug in the treatment of uveitis associated with Behcet's disease.

Patients and Methods

Fifty patients with uveitis associated with Behcet's disease were included in this prospective interventional comparative study at the ophthalmology and rheumatology departments of Sohag university hospital. All procedures comply with the declaration of Helsinki and have institutional ethics committee approval from the ethics committee of Sohag faculty of medicine. Informed written consent was obtained from all patients. All patients were more than 18 year old, having bilateral uveitis associated with Behcet's disease with flare and cells $\geq +1$ according to the Standardized Uveitis Nomenclature (SUN) classification [12] and a visual acuity better than 6/60 in the more affected eye. The exclusion criteria included patients with cataract, glaucoma or phthisis and patients with history of ocular trauma or surgery. All cases had a complete ophthalmological evaluation including detailed history about the onset and course of the uveitis. Also complete examination was done including slit lamp evaluation of the AC cells and flare, visual acuity (corrected and uncorrected), intraocular pressure and fundus evaluation. In addition, fluorescein angiography and optical coherence tomography were done before and one year after treatment. Systemic work-up in the form of stool

and urine analysis, chest X-ray, CBC and ESR was done in all cases. All patients received topical eye drops in the form of prednisolone acetate 1% 5 times daily with gradual withdrawal, cyclopentolate hydrochloride 1% 3 times daily and moxifloxacin hydrochloride 0.5% 5 times daily for one week to guard against bacterial conjunctivitis.

According to systemic treatment, patients will be divided randomly into 2 groups; those who receive infliximab were included in group A while those who receive systemic steroids were included in group B. The duration of follow-up in the 2 groups was one year.

Infliximab administration:

Infliximab will be given at the expense of the state as a slow intravenous infusion of 250 ml saline solution over 2-3 hours with monitoring of vital signs. The dose is 5 mg/kg at 0, 2 and 6 week and then increased to 10 mg/kg every 4-8 weeks. Patients will be followed up after two and six weeks, then monthly during the one-year infliximab therapy, and the follow-up visits will include clinical assessment and investigations such as complete blood count (CBC) and liver function tests every 3 months. Patients who develop infusion reaction will be managed with antihistamines and slowing the rate of infusion.

Statistical analysis

Data was processed using the SPSS software. Values will be expressed as means and standard deviations for normally distributed data or median and interquartile range for non-parametric data. Correlation coefficients were calculated by Spearman's method or Pearson's method according to the normality of data. For all tests, P value of less than 0.05 will be considered significant.

Results

This study included 50 patients with uveitis associated with Behcet's disease. 28 were males and 22 were females. Cases were divided into 2 groups; group A received topical eye drops and intravenous infliximab, and group B received topical eye drops and oral steroids. The 2 groups were comparable regarding their baseline characteristics as shown in table-1. All patients were followed up for one year. Clinical remission is defined as improvement in visual acuity and reduction in AC cells that is maintained for at least 3 months after discontinuation of treatment.

In group A, the mean BCVA (logMAR) improved from 0.48 ± 0.14 at baseline to 0.29 ± 0.2 , 0.13 ± 0.11 and 0.07 ± 0.12 after 2 weeks, 1 month and 3 months, respectively after treatment ($p < 0.001$). The number of cases with grade 0 AC cells increased from 0 before starting treatment to 3, 19 and 18 after 2 weeks, 1 month and 3 months, respectively after treatment ($p < 0.001$) indicating clinical remission in 18 (72%) out of 19 cases that showed initial improvement as shown in figure-1 and table-2. The side effects of infliximab in group A included rash in 5 patients, fatigue in 5 patients, nausea in 2 patients, infusion-related reaction in 2 patients and impaired liver function in 1 patient. While in group B, the mean BCVA (logMAR) improved from 0.47 ± 0.13 at baseline to 0.28 ± 0.3 , 0.14 ± 0.13 and 0.17 ± 0.15 after 2 weeks, 1 month and 3 months, respectively after treatment ($p < 0.001$). The number of cases with grade 0 AC cells increased from 0 before starting treatment to 4, 18 and 14 after 2 weeks, 1 month and 3 months, respectively after treatment ($p < 0.001$) indicating clinical remission in only 14 (56%) out of 18 cases that showed initial improvement as shown in table-2. The side effects of systemic steroids in group B included dyspepsia in 12 patients,

electrolyte imbalance in 10 patients, hypertension in 4 patients and cushingoid state in 2 patients.

Table-1. comparison between the two study groups

Characteristics	Group A (N=25)	Group B (N=25)	P-value
Age (year)			
Mean± S.D.	33.19 ± 2.36	34.32 ± 2.12	0.623*
Gender			
Female	10 (40 %)	11 (44%)	0.92**
Male	15 (60%)	14 (56%)	
BCVA (Log MAR)			
Mean± S.D.	0.48 ± 0.14	0.47 ± 0.13	0.93***
AC cells			
1	2 (8%)	3 (12%)	0.779****
2	19 (76%)	17 (68%)	
3	4 (16%)	5(20%)	

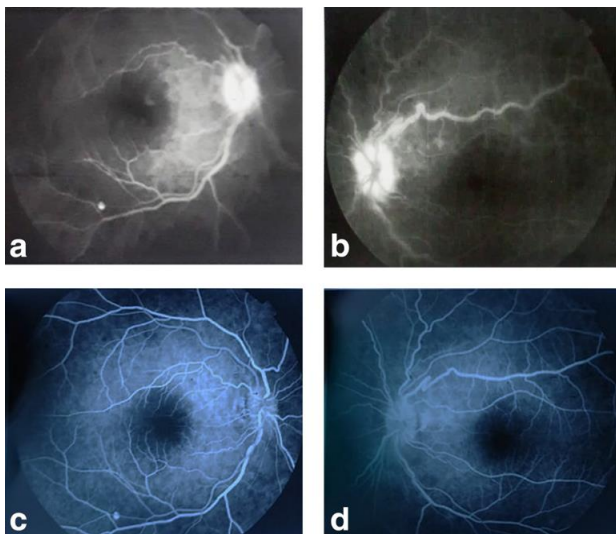
regarding their baseline measures.

P-value was calculated by *Independent Samples Test ** Fisher's Exact Test ***P Mann-Whitney U test **** Chi-Square test

Table -2. Comparison between the repeated examinations of AC cells in the 2 groups.

Characteristics	AC cells				P-value
	Baseline	Two weeks after treatment	One-month after treatment	Three months after treatment	
Group A					
0	0 (0.0%)	3 (12%)	19 (76%)	18 (72%)	<0.001*
0.5	0 (0.0%)	12 (48%)	5 (20%)	3 (12%)	
1	2 (8%)	9 (36%)	1 (4%)	4 (16%)	
2	19 (76%)	1 (4%)	0 (0.0%)	0 (0.0%)	
3	4 (16%)	0 (0.0%)	0 (0.0%)	0 (0.0%)	
Group B					
0	0 (0.0%)	4 (16%)	18 (72%)	14 (56%)	<0.001*
0.5	0 (0.0%)	6 (24%)	5 (20%)	4 (16%)	
1	3 (12%)	13 (52%)	2 (8%)	7 (28%)	
2	17 (68%)	2 (8%)	0 (0.0%)	0 (0.0%)	
3	5 (20%)	0 (0.0%)	0 (0.0%)	0 (0.0%)	

*P-value was calculated by Friedman test.

Figure-1. Fluorescein angiography in a 34 year old male patient of group A before (a and b) and one year after (c and d) receiving infliximab.

Discussion:

Behcet's disease is relatively common among Egyptian people and its associated uveitis is potentially blinding. In addition, the age group involved is the productive group thus increasing the social and economic burden of this disease. In this study, the efficacy and safety of infliximab in the treatment of uveitis associated with Behcet's disease were assessed. The study included 50 patients divided into 2 groups; group A (25 cases) received infliximab and group B (25 cases) received systemic steroids and all cases were followed up for one year. Both groups showed initial improvement in their disease regarding visual acuity and anterior chamber cells. However, such remission was maintained in the majority of cases of group A (18 out of 19) representing 72% of all cases in the group. While only 14 out of 18 cases showed persistent remission in group B representing only 56% of all cases of the group.

Ohno et al [13] evaluated the safety and efficacy of repeated infliximab in 13 patients with Behcet's disease and refractory uveoretinitis. Infliximab was given as an intravenous drip infusion at 0, 2, 6 and 10 weeks as 5mg/kg or 10mg/kg doses. They noted reduction in the mean number of uveitis attacks after administration of infliximab from 3.96 to 0.98 times in the 5mg/kg group and from 3.79 to 0.16 times in the 10 mg/kg group. Reactivation of tuberculosis was detected in one case in the 10 mg/kg group. They concluded that repeated infliximab administration is both safe and effective in reducing the frequency of uveitis attacks in patients with Behcet's disease. In their prospective noncomparative study, El-shabrawy and Hermann [14] evaluated the safety and efficacy of a single intravenous infusion of infliximab at a dose of 10mg/kg as a sole treatment in 7 patients with HLA-b27 associated acute anterior uveitis. Six patients showed complete resolution after a single

dose of infliximab and one patient required a second dose after 3 weeks because of flare-up of uveitis. In addition, relapse was detected in 4 cases. Accordingly, they concluded that infliximab could be a good alternative or supplement to steroid in acute uveitis associated with HLA-b27. Suhler et al [15] tested the benefits of infliximab in 23 patients with Behcet associated uveitis. Cases were divided into 2 groups; the first group received a dose of 3mg/kg plus other immunosuppressive drugs while the second group received a dose of 5mg/kg as a monotherapy. Infliximab was administered as 3 intravenous infusions at 0, 2 and 6 weeks duration. After 10 weeks, efficacy was detected in 18 patients as evidenced by improvement or non-exacerbation in one or more of 4 follow-up parameters; visual acuity, intraocular inflammation, fluorescein angiography or OCT and number of other supplementary drugs. Compared to these studies, the current study is prospective, comparative and included a relatively large number of cases with a longer follow-up period.

Conclusion:

Infliximab is a promising treatment for uveitis associated with Behcet's disease. It is more effective than systemic steroids in inducing and maintaining clinical remission. In addition, its side effects are not serious and manageable.

Conflict of interest: Non

References

1. **Yıldız M, Köker O, Adrovic A, et al.** Pediatric Behçet's disease—clinical aspects and current concepts. *Eur J Rheumatol.* 2019; 7(Suppl 1): 1-10.
2. **Tong B, Liu X, Xiao J, Su G.** Immunopathogenesis of Behcet's disease. *Front Immunol.* 2019; 10:665.

3. **Greco A, De Virgilio A, Ralli M, et al.** Behcet's disease: new insights into pathophysiology, clinical features and treatment options. *Autoimmun Rev.* 2018; 17(6): 567-575.
4. **Verity DH, Marr JE, Ohno S, et al.** Behcet's disease, the Silk Road and HLA-B51: Historical and geographical perspectives. *Tissue Antigens.* 1999; 54
5. **De Menthon M, LaValley MP, Maldini C, et al.** HLA-B51/B5 and the risk of Behcet's disease: A systematic review and meta-analysis of case-control genetic association studies. *Arthritis Care Res.* 2009; 61: 1287–1296.
6. **Yazici H, Seyahi E, Hatemi G, et al.** Behcet syndrome: A contemporary view. *Nat Rev Rheumatol.* 2018; 14: 107–119.
7. **Atmaca L, Boyvat A, Yalçındağ FN, et al.** Behçet disease in children. *Ocul Immunol Inflamm.* 2011; 19(2): 103-107.
8. **Hazleman BL.** Rheumatic disorders of the eye and the various structures involved. *Br J Rheumatol.* 1996; 35(3): 258-268.
9. **Kone-Paut I.** Behcet's disease in children, an overview. *Pediatr Rheumatol Online J.* 2016; 14(1): 10.
10. **Reiff A, Kadayifcilar S, Ozen S.** Rheumatic inflammatory eye diseases of childhood. *Rheum Dis Clin North Am.* 2013; 39(4): 801-832.
11. **Hamza MME, Macky TA, Sidky MK, et al.** Intravitreal Infliximab in refractory uveitis in Behcet's Disease. A safety and efficacy clinical study. *Retina.* 2016; 36:2399–2408.
12. **Jabs DA, Nussenblatt RB, Rosenbaum JT, et al.** Standardization of uveitis Nomenclature for reporting clinical data. Results of the first International workshop. *Am J Ophthalmol* 2005;140:509–16.
13. **Shigeaki Ohno, Satoshi Nakamura, Sadao Hori, et al.** Efficacy, safety, and pharmacokinetics of multiple administration of infliximab in Behçet's disease with refractory uveoretinitis. *The Journal of Rheumatology* Jul 2004, 31 (7) 1362-1368.
14. **Yosuf El-Shabrawi, Josef Hermann.** Anti-tumor necrosis factor-alpha therapy with infliximab as an alternative to corticosteroids in the treatment of human leukocyte antigen b27-associated acute anterior uveitis. *Ophthalmology* 2002; 109 (12): 342-2346.
15. **Suhler EB, Smith JR, Wertheim MS, et al.** A prospective trial of Infliximab therapy for refractory uveitis: preliminary safety and efficacy outcomes. *Arch Ophthalmol.* 2005;123(7):903–12.