



# International Journal of Health Sciences (Egypt)

Journal homepage: <https://ijhegy.journals.ekb.eg/>

## Original article

# A comparison of rotational adenomammectomy, surgery, and ultrasound-guided microwave ablation for benign breast mass

Hassan A Saad<sup>1\*</sup>, Mohamed Riad, Kamal Rabie Eid, Azza Baz, Rasha S Elsayed, Ashraf Abdelmonem Elsayed, Mohamed E Eraky, Mohamed I Farid

1- Surgical department, faculty of medicine, Zagagie university, Egypt...

## ARTICLE INFO

### Article history:

Received 5 April 2023

Received in revised form 9 April 2023

Accepted 16 April 2023

### Keywords:

Normal Breast Nodules

Rotational Adenomammectomy

Surgery

Microwave Ablation

Prognosis

## ABSTRACT

**Objective:** To explain the effect of intervention and conventional surgery, rotational adenomammectomy, ultrasound-guided microwave ablation, on the prognostic result of benign breast nodules. **Methods:** Between December 2016 and October 2020, in xxx university surgical treatment, with the invasive radiology department we had 232 situations of patients with benign breast nodules that proved benign after pathological examination and underwent intervention treatment approaches, they were split into three groups: rotational adenomammectomy group (n = 79), conventional surgery group (n = 105) and microwave ablation group (n = 48). Between the three groups, clinical measurements were evaluated and studied, and the patients' discomfort following the procedure, residual tumor, breast aesthetics, and morbidity rate were reviewed. **Results:** Microwave ablation group had lower operational time, intraoperative blood loss, recovery time, and postoperative suffering pain compared rotational adenomammectomy group and conventional surgery group (P 0.05). Additionally, the results of the rotation-assisted adenomammectomy group were inferior to those of the traditional surgery group (P 0.05). The residual lesions rates after rotational adenomammectomy and microwave ablation were 4.17% and 3.80%, respectively. Additionally, there was no statistically significant difference (P compared to 0.05). Both of them were statistically significantly different (P 0.05) from the 6.66% in the traditional surgery group. In the groups that underwent rotational adenomammectomy, microwave ablation, and conventional surgery, the successful rates of breast appeal were 91.67%, 82.28%, and 68.58%, respectively. Additionally, there was a statistically significant difference between the groups (P 0.05). **Conclusion:** benign breast tumors can be correctly dealt with famous surgery, rotational adenomammectomy, and microwave ablation. The microwave ablation better Cosmetic, less pain, less complications' but surgery still ideal because less recurrence.

## Introduction

benign breast nodules is the most popular lesion of the breast. Breast benign lesions now make up 60% to 85% [1] of all breast illnesses,

with the incidence rate rising 12 months over 12 months in last years [2]. Traditionally, surgical excision has been the most famous method of

treating benign breast tumors. Breast surgical treatment has these days increased to be a center of interest of research due to the real women's aesthetic desires are always evolving, making it reflected important subject on consideration and how to minimize postoperative complications, keep the aesthetics of the breast, and accomplish the intended treatment. Rotational adenomammectomy at McMurdo [3] is The McMurdo rotational adenomammectomy [3], which has the advantages of less discomfort, quicker healing, and favourable outcomes, is frequently used to treat benign breast nodules. However, there are still risks like tumour residual and postoperative hemorrhage [4]. Microwave ablation has been increasingly used to the treatment of tumours with optimum efficacy in recent years, along with the progress of the minimally invasive concept, although its use in the treatment of benign breast tumours is getting less attention. Based on this, a clinical control research carried out in this study to carefully analyse and assess the effects of microwave ablation, surgery, and rotational resection for the treatment of benign breast nodular tumours. The results are summarised below.

## Materials and Methods

### Clinical Data

232 cases with benign breast nodules who underwent non-obligatory breast surgical intervention at our health facility between December 2016 and October 2020. The following standards have to be met for

#### inclusion:

- 1) female, diagnosed by pathological and radiological examination proved benign nodules.
- 2) meeting the indication for surgery;
- 3) volunteering to select the surgical method and consenting to surgery;
- 4) nodules about 3cm in diameter.

5) females being cooperate with postoperative follow-up and review.

#### exclusion:

- 1-Other breast lesions and malignant tumors
- 2- coagulation disorders
- 3-liver and kidney insufficiency, 4-pregnant and lactation, and the lack of potential to give up the follow-up.

The sanatorium ethics committee gave the search for their approval. Patients divided to three groups. surgical techniques.

the surgical group: Age 21 to 53 years, average (37.5± 5.6), nodule diameter 2 to 3 cm, average (2.1±0.2), 79 single cases, and 26 multiple cases for The The microwave ablation group: 23 to 50 years, average (37.1±5.2), nodule diameter 1 to 3 cm, average (1.7±0.3), 32 single cases, and 16 multiple cases for the rotating adenomammectomy group included 51 single instances and 28 multiple cases. The age ranged from 21 to 55 years, with a mean of (38.1± 6.2) years. The nodule diameter ranged from 1 to 3 cm, with a mean of (1.9± 0.2) cm. Age, nodule diameter, and nodule count differences across the three groups weren't statistically significant ( $P > 0.05$ ).

## Methods

1) Surgical group: In this group, benign breast nodules were traditionally excised, with preoperative ultrasonography used to identify and mark the nodule's location. The broken breast's skin and gland were cut after local anaesthesia with lidocaine, and the nodules were extracted and removed layer by layer sutured.

2) Rotational adenomammectomy group: Mammotome used to be used as a minimally Invasive approach to circumcision in this group. The eight rotational Adenomammectomy knife and the micromotor minimally invasive rotational . A preoperative ultrasound examination used to be

carried out to identify the size, number, and attribute of the nodules as desirable as the site of the needle entry. The rotational Adenomammectomy (fan-shaped) used to be then carried out following the ultrasound right location until the nodule's echogenicity disappeared. It is depending on the exact inserting site of the needle into the junction of the nodule and regular tissue under ultrasound guidance.

3) Microwave ablation group: microwave ablation used to be carried out in this group. The microwave ablation instrument with a frequency of 2450 MHz, 18 G disposable microwave ablation needle, and ARIETTA 70 coloration Doppler ultrasound diagnostic instrument with a probe frequency of applied between eight and thirteen Frequencies. In the supine position, the affected breast used to be as quickly as exposed, the size, quantity, and region of the nodules have been assessed, and the puncture nearby and route have been localized and marked. 1% lidocaine local anaesthetic used to be as rapidly used, and color ultrasound with an output electrical energy of forty Wgenerating 40 W of output electricity. Each mass took 30 to 180 seconds to completely evaporate. When the mass was completely covered by heat-generated strong echo, ablation was halted, ultrasonography contrast agent was administered through the vein, and there was no perfusion in the nodal area, indicating that ablation was finished. On the contrary, ablation proceeded. In order to move the ablation and avoid the nipple during the process, the puncture needle's tip must be in the ultrasound observe- able range. 0.9% sodium chloride solution should be injected to those that are less than 0.5 cm from the skin, posterior space, and areola in order to improve tissue thickness for water isolation and minimise burning of the surrounding tissues. One should monitor their skin's temperature..fig2

## Indexes of Observations

**1- Surgery:** The two groups' operation times, intraoperative bleeding, and postoperative restoration conditions have been noted. The seen analog scale (VAS), which levels from zero to 10, used to measure each group's postoperative pain. Mild pain from 1-3 moderate pain 6-7 but severe pain 7 - 10.

**2- Swelling that is alternatively present:** Breast ultrasound analysis carried out three months that appeared in surgical operation

**3- Aesthetics of the breast:** The Harris characters had been used to decide the postoperative breast aesthetics [6] [7] [8]: no variations between the two symmetrical breasts, and the scar is barely visible; fine, there are some considered versions between the two breasts, and the scar is noticeable. fine, not apparant. It used to be determined that a scenario was as soon as remarkable if each breast had a large difference in appearing to be and had been asymmetrical.

**4-following surgery:** patients reported experiencing a variety of issues, such as breast discomfort, incision infection, liquefaction of fat, and holes and skin redness and pigmentation. breast discomfort, wound infection, decomposition of fat, etc.

## Statistics processing

The software referred to as SPSS 22.0 used to be used for processing and analysis. The LSD-t test used to be used to look at the corporations of usually disbursed dimension data, at the equal time as the chi-square take look at used to be used to learn about the corporations of commonly disbursed take into account data, with P 0.05 exhibiting the presence of statistical differences.

## Results

Practices are compared As set up in Table 1, the minimally invasive rotational adenomammectomy group used to be less invasive than the famous surgical group, and the difference used to be statistically large ( $P < 0.05$ ). The operative time, intraoperative bleeding, restoration time, and postoperative pain in the microwave ablation team had been in addition much little invasive than those in the surgical group.

### Postoperative Mass Residues

Clinical Procedure Comparison As shown in Table 1, the difference between the minimally invasive rotational adenomammectomy group and the surgical group was statistically significant ( $P < 0.05$ ), and the operating a period of time intraoperative hemorrhage repairing time, and postoperative suffering pain in the microwave ablation group were lower than those in the minimally invasive rotational adenomammectomy group and the surgical group.

Comparing Postoperative Mass Residues, in the minimally invasive rotational adenomammectomy group and the microwave ablation group, the

distinction in the residual mass rate at the 3-month postoperative review was not statistically significant ( $P > 0.05$ ), but both were lesser than the surgical group, and the difference was statistically significant ( $P < 0.05$ ), as shown in Table 2.

### 3.3. Evaluation of Aesthetics results

As shown in Table 3, at 6-month postoperative follow-up, the microwave ablation group possessed a rate of excellent breast aesthetics of 91.67%, which was higher than the minimally invasive procedures rotation group's rate of 82.28% and known as surgical group's rate of 68.58%. The difference between the groups was statistically significant ( $P < 0.05$ ). With statistically significant differences, the postoperative complication rates were 4.17% and 3.80% in the groups undergoing microwave ablation and minimally invasive rotational adenomammectomy, respectively, and 6.66% in the surgical group Table 4.

**Table 1.** compares the clinical surgical conditions of the three categories of patients (x s).

Groups	Amount of instances	Running duration (min.)	amount of intraoperative bleeding (mL)	Recovery period (d)	Acute discomfort (min)
microwaved ablation group	48	42.72 ± 11.36	2.72 ± 0.81	2.84 ± 0.7	1.74 ± 0.4
cohort for rotational adenomammoplasties	79	60.81 ± 14.53	5.29 ± 1.34	3.91 ± 0.85	2.15 ± 0.84
Surgery squad (group)	105	78.75 ± 13.06	14.05 ± 2.74	5.50 ± 1.3	5.03 ± 1.25
T		16.172	9.336	14.062	5.694
P score		0.020	0.001	0.001	0.001

**Table 2.** shows a comparison of the three groups' postpartum mass residuals (n,%).

Group	Amount of instances	surgical mass remains
Microwave elimination group	48	2(4.17)a
Rotational adenomammectomy group	79	3 (3.80)
Surgery squad(group)	105	7 (6.66)

Note: aP < 0.05 (X2 4.945) and bP < 0.05 (X2 6.021) compared with the surgical group.

**Table 3.** post operative Patients aesthetic between patients group%

Group	Number of cases	Excellent	Good	Moderate	Poor	Excellent rate
Microwaves ablation group	48	29(60.42)	15(31.25)	4(8.33)	0%	44(91.67)ab
Rational Adenomammectomy group	79	43(54.43)	22(27.82)	11(13.92)	3(3.8)	65(82.28)c
Surgical group	105	40(38.10)	32(30.40)	23(31.90)	10(9.52)	71(68.58)

Note: aP 0.05 (X2 9.164), bP 0.05 (X2 10.748), and cP 0.05 (X2 8.332) compared with the surgery group and minimally invasive rotational adenomammectomy group, respectively.

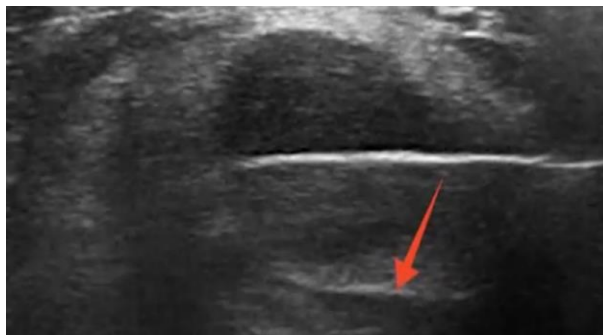
**Table 4.** compares the postoperative complications experienced by patients undergoing various surgical operations (n,%).

Group	Amount of instances of cases	Redness & swollen skin	Hyperpigmented skin	Breast ache or pain	Surgical Site infection	decomposition of fat (fat necrosis)	Number of instances overall Occurances
Total number of instances occurrences	48	2 (4.17)	0	0	0	0	2 (4.17)a
Rotational Coher adenomammectomy group	79	2 (2.53)	0	1 (1.27)	0	0	1 (1.27)
Surgical instances group	105	3 (2.86)	1(.95)	1(.95)	2(1.90)	0	7 (6.66)

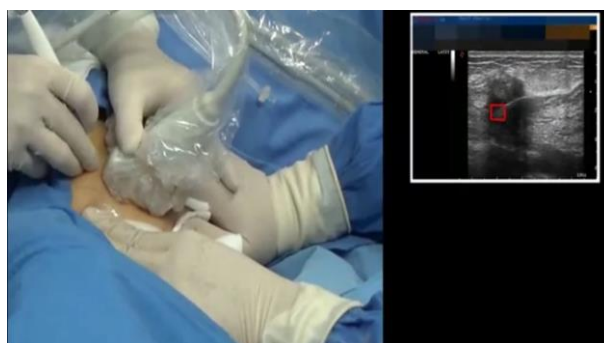The following comparisons were made with the surgery group: aP 0.05 (X2 3.362) and bP 0.05 (X2 5.704).

As shown in Figure 4, (P 0.05).

**Figure 1:** showing middle of microwaves inside the tumour mass, red arrows referred to the affected tissue by calcification.



**Figure 2 :** showing the needle introduced through the skin and appeared on the monitor, red square indicate the site of the needle



## Discussions

Currently, surgical resection is the most beneficial scientific cure for benign breast nodules. In current years, therapy techniques have been most beneficial alongside women's aesthetic wants for conserving perfect breast shape, minimizing surgical incisions, minimizing scar formation [9] [10]. With the introduction of minimally invasive technology, benign tumors can now be successfully dealt with whilst in addition great women's cosmetics needs.

It is tough to analyze the archives and draw inferences because, in general, all ablative methods produce a high-quality sized fluctuation of results in subject of whole ablation, complications, and remedy times. To attain good results after pathological examination and full investigation you must match the ideal methods with aesthetic results ,less pain,low cost ,less complications without or little recurrent [39].A rotational adenomammectomy knife and a vacuum suction pump make up the McMurdo rotational adenomammectomy, a minimally

invasive technique commonly used in breast surgery. The characteristics of this procedure—hidden incision, small scar, minimal impact on breast appearance—can greatly reduce patients' psychological stress, but there are still some drawbacks, such as bleeding and residual bulk [11] [12].

It was discovered that high temperature is the major factor in the effectiveness of ultrasound-guided microwave therapy, allowing protein denaturation and coagulative necrosis to occur in the mass group length in the least amount of time [13]. Particularly with regard to microwave ablation, ultrasound-guided minimally invasive treatment has several advantages over traditional surgery, including precise positioning, strong pertinence, local anesthetic, less trauma, effectiveness, and reliability. Not only can microwave ablation produce the same curative results as minimally invasive rotational adenomammectomy and surgery, but it can also speed up the ablation process and lessen pain [14]. Additionally, the microwave thermal action can boost local tissue metabolism, increase nutrient uptake, and speed up tissue repair capacity [13]. It can also improve blood flow in the vicinity of the ablation area.

Additionally, the microwave thermal action can boost local tissue metabolism, increase nutrient uptake, and speed up tissue repair capacity [13]. It can also improve blood flow in the vicinity of the ablation area.

The study's findings demonstrated that patients in the microwave ablation group had shorter operating times, lower intraoperative bleeding, faster healing, and less postoperative pain than patients in the minimally invasive

rotational adenomammectomy group and the surgical group, which was thought to be due to the postoperative area's gradual healing. In comparison to minimally invasive rotational adenomammectomy and traditional surgery groups, the rate of outstanding postoperative breast aesthetics was much greater in the microwave ablation group. They prove the microwave important for aesthetic breast [14]

In the minimally invasive rotational adenomammectomy and microwave ablation groups, the residual rate of masses was reduced at 3 months postoperative review (respectively, 4.0% and 3.80%), compared to the surgical group's 6.66%, and the difference was statistically significant ( $P < 0.05$ ). In the meantime, the excellent rate of breast aesthetics at 6-month postoperative follow-up was 91.67% in the microwave ablation group, 82.28% in the rotational adenomammectomy group, and 68.58% in the surgical group, with the difference between the groups statistically significant ( $P < 0.05$ ). Additionally, the rates of postoperative complications were statistically considerably lower in the surgical group (6.66%) than in the microwave ablation group (4.17%) and rotational adenomammectomy group (3.80%), respectively.

Statistical significance for the difference was determined to be  $P < 0.05$ . The excellent rate of breast aesthetics was 91.67% in the microwave ablation group, 82.28% in the rotational adenomammectomy group, and 68.58% in the surgical group at 6-month postoperative follow-up. The difference between the groups was statistically significant ( $P < 0.05$ ). Additionally, the postoperative complication rates were much lower in the rotational

adenomammectomy group (3.8%) than in the surgical group (6.6%), and the difference was statistically significant ( $P < 0.05$ ). The rates were 4.17% and 3.80%, respectively. It is abundantly obvious from the study's findings that microwave

The advantages of ablation are as follows: first, high precision and safety, which can be punctured accurately by ultrasound real-time observation and reduce the damage to surrounding tissues; second, the ability to adjust the microwave ablation needle entry position, ablation power, and ablation time in accordance with the nodule size. Second, compared to traditional adenomammectomy and surgery, microwave ablation is minimally invasive, quick to heal, and scarless. The incision made during microwave ablation is small, and no scar is left behind. Third, there are many applications that can be made. The therapy of numerous tumours is better suited to microwave ablation, which also effectively treats masses with a wider diameter [13] [14] [15] [16].

cryo-ablation has the benefit of being analgesic, and produce field anesthesia than others methods. Furthermore, tissue modifications brought on with the aid of freezing can be considered on ultrasound then as quickly as higher now no longer a mammogram after therapy [17]. A central cavity of hyaline necrosis and a peripheral rim of tissue with viable cells characterize the furnish up providing cease result microscopically, which is related to RFA and laser ablation [18-19]. High thermal efficacy is an accumulation of microwave ablation, on the other hand, it is, in addition, a draw decrease back due to the fact it makes shut with the

useful resource of the brain of workable tissues with ease ablated [20].

#### Imaging

The feasibility of RFA use in the remedy of breast most cancers will count variety usually on the persevered development of imaging. For one, imaging is critical for the localization of the tumor itself. Many research in contrast ultrasound estimates of breast tumors pre-RFA and stated extraordinary variants with respective MRI contrast [21-22-23].

Secondly, image-guidance is required while performing RFA in vivo to make sure right placement of the electrode and response of the tumor all via the procedure. Incomplete ablation has been linked to incorrect placement of the RFA electrode at some factor of ablation, which need to be at the core of the tumor [24-25]. Therefore, the effectiveness of RFA treatment is at as quickly as correlated to the use of imaging. Radiofrequency ablation makes use of immoderate temperatures, which can lead to problems such as pores and pores and skin burns. Nahirnyak et al. have decided a sturdy hyperlink between Doppler ultrasound signal adjustments and tissue boiling This examine about suggests that use of Doppler ultrasound following ablation may also additionally help to prevent issues due to RFA temperatures. Additionally, imaging is required to check out the tissue response to RFA remedy and the oncologic consequences of the treatment in long-term follow-up. In the many studies, entire ablation used to be evaluated with the use of imaging and histopathology. In Palussiere et al. no definitive surgical resection used to be as soon as performed, for this reason imaging was once the fully approach of assessing for the profitable ablation of lesions [15]. Continued



advances in imaging will be fundamental to enable correct evaluation of the ablation and for subsequent follow-up to be aware recurrence.

#### Cosmesis

Breast conserving therapy, breast conserving surgical therapy with adjuvant chemotherapy, has been observed to be equal to mastectomy, alternatively with the benefit of minimizing deformity to the breast. However, breast conserving cure however requires terrible margins and therefore, may also moreover in addition no longer produce terrific elegance outcomes in sufferers with a suitable deal much less breast tissue. A fundamental gain of RFA utilization in breast cancer treatment is the plausible for expanded cosmesis with patients who have early-staged small breast cancers. A few lookup evaluated the splendor outcomes and affected person pleasure with the gadget [16]. Oura et al. [17] noted beauty results as excellent, accurate and fair, with 43/52 victims reporting great cosmesis . The essential issue affecting the beauty consequences in this research about was once as soon as the presence of mass formation at the RFA website on-line secondary to fats necrosis. Overall cosmesis in this locate out about used to be as soon as promising, with 28/34 sufferers assessed as excellent. Cosmesis can also no longer be exactly reflected in the majority of these lookup because surgical excision used to be used to both verify the effectiveness of the RFA therapy, as acceptable as make superb the contemporary stylish of care used to be performed. Further examine about is warranted to think about affected personality pleasure and elegance outcomes in cases barring definitive surgical resection.

Second, in massive difference to rotational adenomammectomy and surgery, microwave ablation is barely invasive, has a quick recuperation period, and leaves no scars behind. Third, there is a large fluctuation in usefulness.

#### Complications/safety

Radiofrequency ablation in other cancer therapy has been shown to have a relatively low associated risk, with morbidity between 2-10% and mortality between 0.3-0.8% [18][19][20] In the above studies, complications associated with RFA included skin burns, muscle burns, ecchymosis, skin puckering and mass formation secondary to fat necrosis at the RFA site. An isolated case of wound infection, mastitis, and pneumothorax were reported in three different studies [21] [22] [23] . Distant metastases were also documented in one study.

Manenti et al. [23]. evaluated cosmesis by means of the usage of means of two surgeons now now not worried affected man or woman treatment, whom evaluated pores and pores and skin texture and pigmentation and rated as excellent, good, acceptable, and horrible[24] [25] .Overall, the safety profile of RFA therapy appears very good, with many of the common complications involving superficial injury or skin changes. In addition, many authors have developed protocols with RFA electrode use to minimize the complications noted above.

Oura et al.[17] found fewer skin burns with injection of 5% glucose, which both enlarged the distance between the tumor and skin, as well as interrupting radiofrequency to affected skin . Ice packs were applied to the skin in studies when the mass was more superficial to prevent burns .Although it appears that many

of the common complications are benign skin changes undoubtedly affect the cosmesis and patient satisfaction with the procedure. In addition, a mass formation may increase anxiety of cancer recurrence for the patient. Adequate counseling should be provided prior to RFA treatment to warn patients about these potential results. Future studies may want to optimize thermoablation methods using previous protocols which haven shown success at minimizing these outcomes. As stated previously, there is no current consensus on RFA device or technique in breast cancer masses.

The main safety issue with RFA treatment involves outcomes of breast cancer recurrence and survival rates. As of now, follow up has been largely limited. The longest follow up study is with Kinoshita with a mean of 60 months, which found no in-breast recurrence, but one axillary lymph node and hepatic metastasis [19]. In terms of oncologic outcome, there is not enough data to conclude if RFA is a safe alternative to surgery at this time.

### Conclusion

Treatment options for benign breast tumors consist of surgery, McMurdo rotational adenomammectomy, and microwave ablation. Microwave ablation, as terrible to the particular two, has many benefits, consisting of an extended absorption period, a faster procedure, thousands a lot a great deal much less blood loss, no scarring, and a magnificent deal a lot a complete lot less discomfort. However, it has some drawbacks, so we pick out the method that especially properly first-rate prerequisites of benign breast, tumors, and surgical operation still affords closing ablation.

So in our opinion the radiofrequency is fabulous for benign as pain and cosmetic appreciate but the surgical still superior for final ablation than radiofrequency.

### Limitation:

- 1- lack of availability of RF needle
- 2- little numbers of patients
- 3- incomplete follow up

### Competing Interests

No conflict interesting

### No funding found

All data base and materials available under your requesting and review Consenting for publication not applicable

**Aknowlgment:** not applicable

No animal or plants used in our study

Ethics approval from Zagagic university institute

### References

- 1- **Onstad, M. and Stuckey, A. (2013) Benign Breast Disorders.** *Obstetrics and Gynecology Clinics of North America*, 40, 459-473. <https://doi.org/10.1016/j.ogc.2013.05.004>
- 2- **Lee, M. and Soltanian, H.T. (2015) Breast Fibroadenomas in Adolescents: Current Perspectives.** *Adolescent Health, Medicine and Therapeutics*, 6, 159-163. <https://doi.org/10.2147/AHMT.S55833>
- 3- **Guo, J.B., Zhao, C.C., Wang, X.J., et al. (2019) Observation of the Effect of Vacuum-Assisted Minimally Invasive Breast Rotational Adenomammectomy System in the Diagnosis and Treatment of Breast Tumors.** *Chinese Primary Care Medicine*, 26, 198-201.
- 4- **Littrup, P.J., Freeman-Gibb, L., Andea, A., et al. (2017) Cryotherapy for Breast Fibroadenomas.** *Radiology*, 234, 631-725. <https://doi.org/10.1148/radiol.2341030931>

- 5- Zhou, W.B. and Zhang, Y.** (2018) Expert Consensus on Ultrasound-Guided Microwave (Radiofrequency) Ablation for the Treatment of Breast Fibroadenoma. *Chinese Journal of Breast Diseases (Electronic Version)*, 12, 321-323.
- 6- Wazer, D.E., Di Petrillo, T., Schmidt-Ullrich, R., et al.** (1992) 6-Factors Influencing Cosmetic Outcome and Complication Risk after Conservative Surgery and Radiotherapy for Early Stage Breast Carcinoma. *Journal of Clinical Oncology*, 10, 356-363. <https://doi.org/10.1200/JCO.1992.10.3.356>
- 7-Yu, Z.H. (2002) Breast Cancer.** In: Yin, W.B. and Gu, M.Z., Eds., *7-Radiation Therapy of Tumors*, China Union Medical University Press, Beijing, 1065-1087.
- 8- Zheng, Y., Chen, Q., Jia, M.M., et al.** (2014) Effect of Post-Breast-Conserving Radiotherapy on the Prognosis of Patients with Local Lymph Node Metastasis from Breast Cancer. *Chinese Cancer Clinics*, 8, 1394-1398.
- 9- Jiang, H.C. and Li, M.X.** (2016) The Application Value of Breast Ductoscopy in Intraductal Papilloma, Diagnosis and Treatment of Breast. *Chinese Journal of Practical Surgery*, 36, 729-733.
- 10- Zhou, Q., Ma, Y., Liang, M.D., et al.** (2017) Feasibility Study of Microwave Ablation for the Treatment of Benign Breast Nodules. *Journal of Nanjing Medical University*, 61, 1337-1338.
- 11- Luo, H.J., Chen, X., Tu, G., et al.** (2011) Therapeutic Application of Ultrasound-Guided 8 Gauge Mammotome System in Presumed Benign Breast Lesions. *The Breast Journal*, 17, 490-497. <https://doi.org/10.1111/j.1524-4741.2011.01125.x>
- 12- Chung, S.W., Kim, J.Y., Kim, M.H., et al.** (2013) Arthroscopic Repair of Massive Rotator Cuff Tears: Outcome and Analysis of Factors Associated with Healing Failure or Poor Postoperative Function. *The American Journal of Sports Medicine*, 41, 1674-1683. <https://doi.org/10.1177/0363546513485719>
- 13- Liu, Y.J., Qian, L.X., Liu, D., et al.** (2017) Ultrasound-Guided Microwave Ablation in the Treatment of Benign Thyroid Nodules in 435 Patients. *Experimental Biology and Medicine*, 242, 1515-1523. <https://doi.org/10.1177/1535370217727477>
- 14- Samir, A.E., Dhyani, M., Vij, A., et al.** (2015) Shear-Wave Elastography for the Estimation of Liver Fibrosis in Chronic Liver Disease: Determination Accuracy and Ideal Site for Measurement. *Radiology*, 274, 888-896. <https://doi.org/10.1148/radiol.14140839>
- 15- Zhang, Y.H., Xi, D.H. and Li, W.H.** (2017) Clinical Experience of Ultrasound-Guided Localized Excision of Small Breast Masses. *Chinese Journal of Clinical Physicians*, 45, 88-89.
- 16- Barr, R.G. and Zhangm Z.** (2015) Shear-Wave Elastography of the Breast: A Quality Measure and Comparison with Strain Elastography. *Radiology*, 275, 45-53.
- 17- Oura S, et al.** Radiofrequency ablation therapy in patients with breast cancers two centimeters or less in size. *Breast Cancer*. 2007;14(1):48–54. doi 10.2325/jbcs.14.48. [PubMed] [CrossRef] [Google Scholar]
- 18- Manenti G, et al.** Small breast cancers: in vivo percutaneous US-guided radiofrequency ablation with the dedicated cool-tip radiofrequency system. *Radiology*. 2009;251(2):339–346. doi 10.1148/radiol.2512080905. [PubMed] [CrossRef] [Google Scholar]
- 19- Kinoshita T, et al.** Radiofrequency ablation as local therapy for early breast carcinomas. *Breast Cancer*. 2011;18(1):10–17. doi

10.1007/s12282-009-0186-9. [PubMed]  
[CrossRef] [Google Scholar]

**20-. Manenti G, et al.** Subclinical Breast Cancer: Minimally Invasive Approaches. Our Experience with Percutaneous Radiofrequency Ablation vs. Cryotherapy. *Breast Care (Basel)* 2013;8(5):356–360. doi 10.1159/000355707. [PMC free article] [PubMed] [CrossRef] [Google Scholar]

**21-. Fleming MM, Holbrook AI, Newell MS.** Update on Image-Guided Percutaneous Ablation of Breast Cancer. *AJR Am J Roentgenol.* 2017;208(2):267–74. doi:10.2214/AJR.16.17129. [PubMed]

**22-. Gage AA.** History of cryosurgery. *Semin Surg Oncol.* 1998;14(2):99–109. doi 10.1002/(SICI)1098-2388(199803)14:2<99::AID-SSU2>3.0.CO;2-1. [PubMed] [CrossRef] [Google Scholar]

**23. Manenti IS, et al.** Cryotherapy of breast cancer under ultrasound guidance: initial results and limitations. *Eur Radiol.* 2002;12(12):3009–3014. [PubMed] [Google Scholar]

**24. Pfliederer SO, et al.** Ultrasound-guided, percutaneous cryotherapy of small (< or = 15 mm) breast cancers. *Invest Radiol.* 2005;40(7):472–477. doi: 10.1097/01.rli.0000166935.56971.ff. [PubMed] [CrossRef] [Google Scholar]

**25. Simmons RM, et al.** A Phase II Trial Exploring the Success of Cryoablation Therapy in the Treatment of Invasive Breast Carcinoma: Results from ACOSOG (Alliance) Z1072. *Ann Surg Oncol.* 2016;23(8):2438–2445. doi: 10.1245/s10434-016-5275-3. [PMC free article] [PubMed] [CrossRef] [Google Scholar]

Saad, H., Riad, M., Eid, K., Baz, A., Elsayed, R., Elsayed, A., Eraky, M., Farid, M. A Comparison of Rotational Adenomammectomy, Surgery, and Ultrasound-Guided Microwave Ablation for benign breast mass. *International Journal of Health Sciences (Egypt)*, 2023; 1(3): 84-95.