

Single Soft Tissue Support versus Dual Tooth-Tissue Support for Clasp-Less Mesial Implant Retained Mandibular Class I Rpd: Cross-Over Clinical Study

Aisha Z. Mostafa

Abstract:

Objective: To evaluate the single soft tissue support versus dual tooth-tissue support for mesial implant retained RPD. **Materials and Methods:** This clinical cross-over study included 10 partially edentulous patients with the only remaining mandibular six anterior teeth. Every patient received two mandibular implants at the 1st premolar region. Two mandibular implants' retained partial overdentures were constructed with two different support concepts, two different designs, opposing a maxillary single denture. One of the dentures was done with a design based mainly on soft tissue support but the other denture was done with a dual tooth-tissue support design. The effects of each RPD design were studied after 1, and 5 years. The following clinical parameters were evaluated: the plaque index (PI), the bleeding index (BI), and the probing depth (PD). The peri-implant bone level changes, and alveolar bone level changes of the canine and residual ridge bone level were assessed on digital radiographs using the Corel-Draw program. The SPSS program was used for statistical analysis. **Results:** After 1 and 5 years of follow-up for each supporting concept of RPD, no implant failures were noted. No significant differences in soft tissue clinical parameters BI, PI, and PIP were found between the 2 designs with regard to the canine and implant, or peri-implant bone resorption. On the other hand, there was a significant difference after 1 year regarding alveolar bone loss of the canine (P=.002) and residual ridge bone loss (P=.0001) and after 5 years for the canine alveolar bone where (P= .015). Regarding residual ridge bone loss, there was a distal descending pattern of bone resorption in the dual support design. The bone loss was increased with the dual support design (P=.0001). **Conclusions:** within the limits of this study, single soft tissue support for mesial implant retained removable partial overdenture was recommended versus dual tooth support. Single soft tissue support preserves the remaining structures.

Introduction:

Kennedy Class I and class II distal extension situations are challenging for prosthodontists to treat because they are unstable by nature. This instability may be caused by the different compressibility of the mucosa and the periodontal ligament supporting the distal-most abutment tooth. As a result, the prosthesis develops a tendency to rotate about the fulcrum line connecting its terminal abutments.¹⁻³

Distal extension RPDs are exposed to different forces (horizontal, vertical, torque) which jeopardizes the stability and retention of the prosthesis.³ A fulcrum is provided by the distal rotation of the prosthesis, which causes a levering motion and compresses the soft tissues to cause displacement in the distal extension RPD.⁴ Unfavorable horizontal forces brought on by this movement encourage undesirable bone remodeling and could lead to the loss of supporting teeth.⁵

The use of implant-supported fixed prosthodontics to successfully treat the distal extension condition has broadened the range of conventional prosthodontic treatment options.

Additionally, placing osseointegrated dental implants in the posterior edentulous regions, distal to the

Associate professor, Department of Removable Prosthodontics, Faculty of Dentistry, Mansoura University 35516, Mansoura, Egypt.
aishazakaria@mans.edu.eg

Received December, 2022; Accepted January, 2023.
DOI: 10.21608/mjd.2023.301977

terminal abutment, improves the vertical support of the distal extension removable partial denture, effectively transforming its intraoral efficiency from a Kennedy Class I to a Class III situation. This improves the stability of the prosthesis and, as a result, increases patient satisfaction.^{5, 6} The placement of implants with sufficient dimensions to support a fixed dental prosthesis or to use a distal implant, however, may be prohibited by anatomical restrictions, such as proximity to the inferior alveolar nerve or the maxillary sinus, as well as financial limitations. In these circumstances, the prosthodontist needs the RPD more than ever, and the mesial implant can help the RPD. For these partially edentulous patients, the use of a small number of implants to enhance crucial removable partial denture design and aesthetics offers a variety of options that would not be practical with traditional techniques.⁷⁻¹³

The use of distal implants to support and retain RPDs has been documented in the literature to reduce dislodgment, enhance mastication, and improve aesthetics, all of which lead to patient satisfaction in a method that is both efficient and affordable.¹⁴⁻²⁰

The implants could be utilized for retention only with attachments associated with the implants or for support only with healing caps.²¹⁻²³ Despite the denture base's supporting area, the distal implant can prevent denture rotation movement of the distal extension bases.^{24, 25} When the implants are located more medially, adjacent to the existing abutments, the unaesthetic retentive clasp on the distal abutments can be eliminated.²⁶ Restoration of extra-oral soft tissue support by the

flange of implant-assisted RPD is one of the advantages gained in addition to the improved denture retention and stability by the implant attachment.²⁷⁻²⁸

A functional and aesthetically pleasing result is provided by a removable partial overdenture retained only by implants. Mesial implant allows less difficult surgical placement. It provides suitable access for maintenance and hygiene.²⁹ When implants are used in addition to natural teeth to improve retention, stability, and support of the RPD, to enable simpler prosthesis design, and to improve patient comfort, the use of implants as retainers for the RPD is a useful adjunct.^{30,31} Additionally, implants can be inserted as an alternative to natural teeth to help retain an RPD that has been severed from the residual dentition.^{27, 32} In implant-assisted RPD, the implant receives the major occlusal load, thus decreasing the stress on the abutment and decreasing the displacement of the removable partial denture.²⁹

This study aimed to evaluate the clinical parameter of implant, peri-implant bone, alveolar bone of the last tooth, canine, and residual ridge bone. These were done for both design, single tissue support and dual tooth-tissue support, of mesial implant, retained RPD in class I Kennedy. The null hypothesis of the study involved that the RPD design based on the support of mesial implants retained mandibular RPD, either single or dual support, would not influence the clinical parameters or bone level for implant, tooth, and ridge.

Materials and methods:

Study Design: This research was a prospective clinical study with a cross-over study design to compare the clinical and radiographic changes of the two different RPD designs, based on the support-derived structure for RPD either single or dual support, on the implant, natural tooth adjacent to the implant and the alveolar ridge. The local dental research ethical committee gave this study its approval with the following number: (A22061222). Following a thorough explanation of the study's protocols to the patients, they signed an informed consent form to participate in the study.

Sample size: A sample size of 10 patients was calculated using PASS 2022 Software for paired t-test, which has an alpha (α) of 0.05 and a power of 0.80. Also, based on a previous research for sample size determination in a cross-over study.³³

Inclusion criteria: This study involved 10 partially edentulous patients with the only remaining 6 mandibular anterior teeth. The maxillary arch was completely edentulous. Patients had healthy keratinized mucosa, a class I maxillo-mandibular relationship, adequate inter-arch space, and enough quantity and quality of bone in the mandibular premolar areas to support standard implants that were 14 mm long and 3.6 mm in diameter. The patients were healthy without

any systemic disease that prevents implant insertion. Also, the patients were free of any disease that affects bone resorption.

Clinical procedures (surgical and prosthetic phases): Every patient received one mesial implant (IMTEC ENDURE Implant Internal Hex System, USA) adjacent to the canine tooth bilaterally, Figure 1, using a clear acrylic resin (Mellodont, Bayer, Leverkusen, W., Germany) surgical template that was supported by the remaining anterior teeth. The implants were inserted according to the delayed loading protocol. During the osseointegration period, the temporary RPD was relined with a soft liner to allow the patients to function. After the osseointegration period, 3 months, the second surgery was done and the implants were exposed for construction of the final prosthesis.

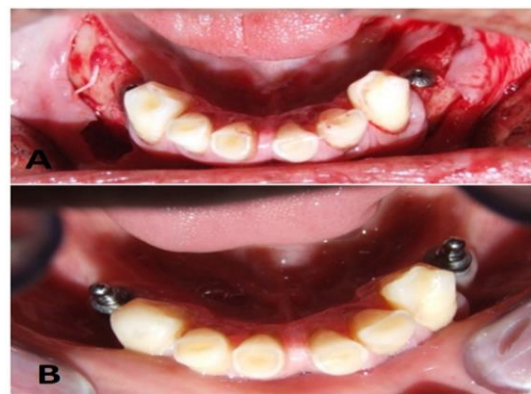

Figure 1: Mesial implant placement; (A) During first stage surgery, (B) After second stage surgery and O-ring abutment connection.

Implant level final impression was done to be used for both RPD design construction using rubber base impression material (Coltene speedex, Switzerland), Figure 2.

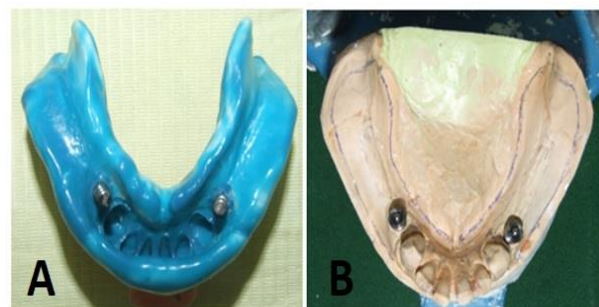


Figure 2: Final impression; (A) Implant level impression, (B) The master cast with abutment and attachment connection to the implant analog.

The master cast was duplicated for construction of both groups implant retained RPD. For the single soft tissue support, the design of the metallic framework, cobalt-chromium alloy (Pektray, lever kusen, Bayer, Germany) involve two guiding plates one on each mandibular canine. The major connector was a lingual bar and the minor connector for the denture base was

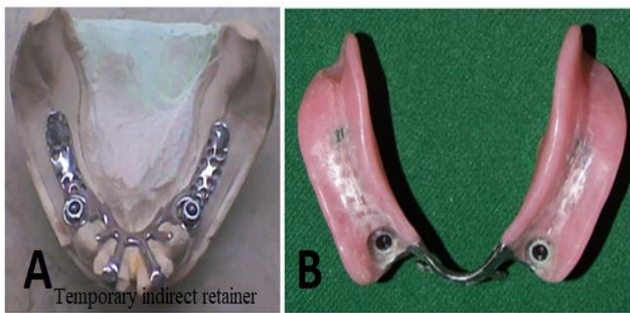


Figure 3: Single tissue support; (A) Temporary indirect retainers were used for the orientation of the metallic framework, (B) The final tissue-supported implant retained RPD (after attachment pick-up the temporary indirect retainers were sawed).

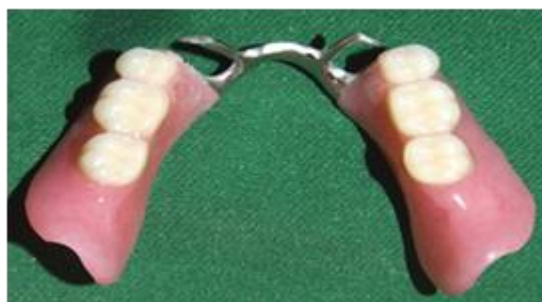

Figure 4: Dual tooth-tissue support implant assisted RPD. A meshwork type. Two temporary indirect retainers were used for the orientation of the metallic framework and the denture. These temporary indirect retainers

were removed after the intraoral pick up of the attachment Figure 3. Maxillary final impression was done using zinc oxide-Eugenol impression material (Cavex impression paste. Holland), Figure 3. Maxillary final impression was done using zinc oxide-Eugenol impression material (Cavex impression paste. Holland) For the dual tooth-tissue support, the design of the metallic framework was involve two guiding plates one on each mandibular canine and 2 mesial rests on the canines, Figure 4. The major connector was a lingual bar and the minor connector for the denture base was a meshwork type.

Maxillo-mandibular relation was recorded and the face-bow record was done using facial maxillary face-bow, Figure 5.

Balanced occlusion concept was applied for both RPD using monoplane acrylic teeth (Major, Dental Industry, Monocolieri, Italy). Clinical pick-up of the O-ring attachments on the implants was done at the time of the RPD insertion, Figure 6.

Clinical pick-up of the O-ring attachments on the implants was done with more thickness of the wax spacer that was used on the ball patrix and matrix of the O-ring of the attachments during the pick-up procedure. After this, the two temporary indirect retainers were sawed from the RPD (for the single support group). The 10 included patients were

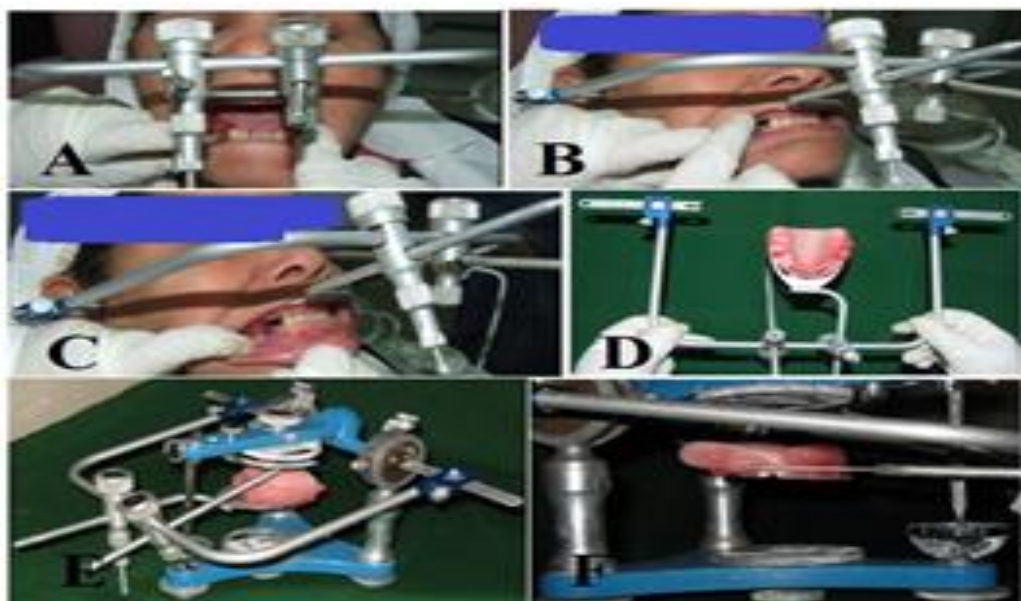


Figure 5: Face bow record; (A) intra-oral from facial view, open mouth, (B and C) lateral view, closed mouth, (D) Extra-oral record, (E and F) the record are transferred to the Dentatus Articulator

distributed equally and randomly into one of the 2 groups using an Excel spreadsheet, with no regard for the researchers' or patients' preferences. The first group includes patients who received single-tissue supported, implant-retained mandibular RPD. The second group includes patients who received dual tooth-tissue supported, implant-retained mandibular RPD. At the time of the prosthesis insertion, the

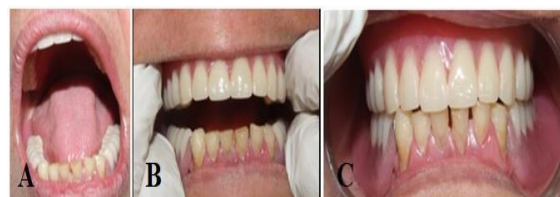

Figure 6: Mandibular mesial implant retained clasp-less RPD intraoral opposing maxillary single denture; (A) Open mouth position, (B) During mouth closing, (C) Closed in centric relation.

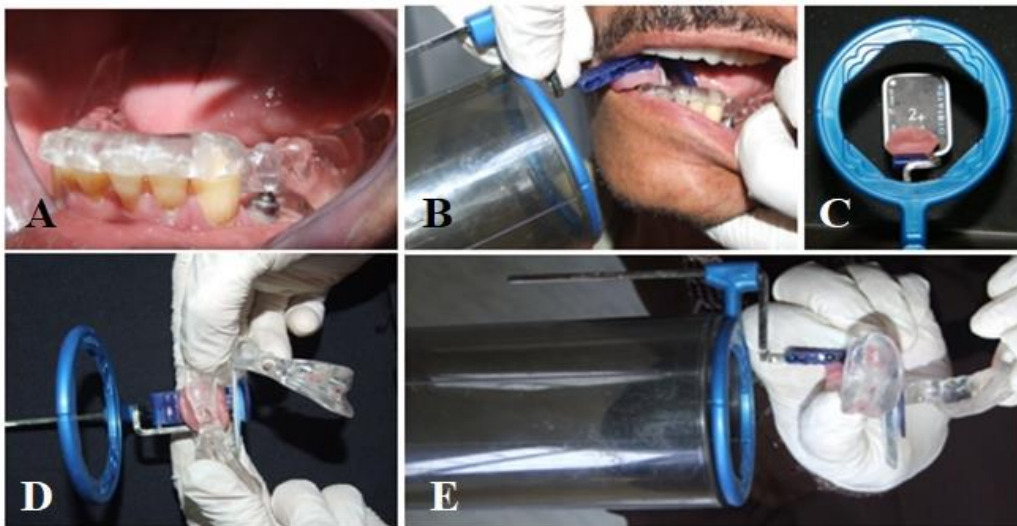


Figure 7: The surgical guide (template) (A), Positioning of plastic bite blocks of the Dentsply/Rinn XCP instruments for standardization of digital periapical radiograph after some modification (B), The Dentsply/Rinn XCP instruments allow the sensor to be centralized (C), Accurately positioned in relation to the radiographic template (D), X-ray parallel cone (E).

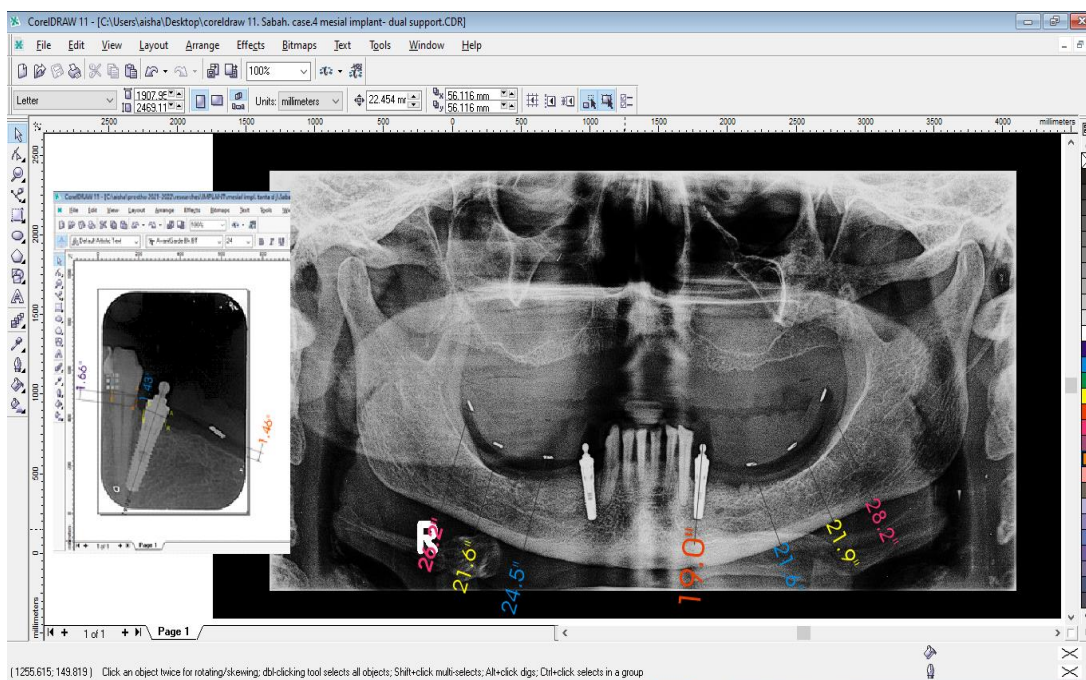


Figure 8: Measurement of the crestal alveolar bone height of implant and tooth adjacent to implant and alveolar bone height of distal extension ridge using Corel Draw-11 computer program.

clinical and radiographic evaluation was done and this was considered zero time. After the 1st year of function with the prosthesis, the clinical parameter evaluation was done and radiographic evaluation on digital periapical and panoramic radiographs was done. The patient was instructed to wear the denture for 5 years. The prosthesis was functionally relined using the tissue conditioner impression material when there is a need for fit adjustment and correction.

The follow-up for clinical and radiographic evaluation was done in 1 and 5 years. Radiographic template, with wrought wire embedded in the fitting surface (at mesial, center, distal position) of the radiographic

template to act as a reference during bone height measurement. This template was used during digital panoramic and periapical radiographs. The long cone parallel or (right angle) intraoral radiographic

technique for digital periapical radiograph was used according to Langland et al.³⁴ The Dentsply/Rinn XCP instruments (extension BID (beam indicating device) paralleling) was used for sensor locating parallel to

the long axes of the implant, teeth and directing the central ray of the x-ray beam perpendicular or at right angles to both the long axes of the teeth and the plane of the sensor ,Figure7. Corel-Draw software program

was used for measuring the alveolar bone height on each radiograph at the mesial and distal crestal bone of the implant and the tooth. Also, the bone of the ridge was measured at the radio-opaque markers of the wrought wire of the radiographic template ,Figure8. Statistical analysis: Statistical Package for the Social Sciences (SPSS) was used to describe and statistically analyze the measured values. The Shapiro-Wilk test was used to determine whether the continuous data were normal. The tooth alveolar bone change, the implant crestal bone change, and the residual ridge bone height change of the two groups of dentures were all compared using the paired-sample t-test. For the two groups of dentures, the non-parametric data, bleeding index (BI), plaque index (PI), and probing depth (PD) of the canine and implant at various times were compared using the Wilcoxon test.

Result:

Ten years passed during the study's periods. There were no pre- or post-operative dental implant fixture-related complications found. After 10 years with each of the two different denture designs, there were no lost implants in either group and as a result, both groups' cumulative survival rates (CSR) were 100%.

The complication that appear was screw loosening. This was observed in 40% of patients. This complication was managed by multiple tightening of the abutment screw. In addition to that, in one case dental resin adhesive was used to cement the O-ring abutment to the fixture. The observation was that when the patient had a long vertical lever arm , the screw loosening was exaggerated. This study found that at 1, or 5 years, the mean plaque index score values did not show any statistically significant differences between the 2 groups of dentures ,Table 1. Also at the same evaluation periods , the mean bleeding score values or probing depth values did not show any statistically noticeable differences between the 2 groups ,Table 2 and ,Table 3 respectively.

Table 1: Mean plaque score values (SD) of the canine and implant at 1, 5 years after each implant retained RPD insertion. Wilcoxon Signed Ranks test to compare the plaque score of the 2 groups of RPD (single support, dual support)

Time of evaluation	Canine tooth		Mesial implant	
	1 year	5 years	1 year	5 years
	Mean (SD)	Mean (SD)	Mean (SD)	Mean (SD)
Single support	0.4 (.52)	0.9 (.25)	0.4 (.52)	0.9 (.23)
Dual support	0.5 (.52)	0.95 (.28)	0.5 (.53)	0.9 (.25)
Wilcoxon Z	-.447-a	-1.342-b	-.447-a	-1.000-b
P value	0.655	0.180	0.655	0.317

a. Wilcoxon Signed Ranks Test ,b. Based on negative ranks. c. Based on positive ranks

Table 2: Mean bleeding score values (SD) of the canine and implant at 1, 5 years after each implant retained RPD insertion. Wilcoxon Signed Ranks test to compare the bleeding score of the 2 groups of RPD (single support, dual support)

Time of evaluation	Canine tooth		Mesial implant	
	1 year	5 years	1 year	5 years
	Mean (SD)	Mean (SD)	Mean (SD)	Mean (SD)
Single support	.4 (.52)	0.9 (.22)	.5 (.53)	.88 (21)
Dual support	.6 (.52)	.9 (.19)	.6 (.52)	.9 (.20)
Wilcoxon z	-.816-a	-1.000-b	-.447-a	-1.633-b
P value	.414	.317	.655	.102

a. Wilcoxon Signed Ranks Test b. Based on negative ranks c. Based on positive ranks.

Discussion:

For patients with partial dentition, implant-retained RPDs are one of the most important treatment options. The implant-assisted RPDs improve the prosthetic biomechanics, and esthetics and provide greater retention, and stability resulting in greater patient satisfaction.¹⁸⁻²¹ In this study, a clasp-less distal extension removable partial denture could be retained using 2 mesial positioned implants in the intra-foraminal area. The implant used was a two-piece type because it provides more esthetic positions for the implant superstructure. In addition to that: Liu, et al, 2021 found that³⁵ no statistically significant differences were founded between one-piece and two-piece types of dental implants regarding survival rate and complications. However, two-piece types of dental implants may be a better option to reduce peri-implant bone loss.

The implant placement position in this study was in the first premolar region, directly anterior to the foramen, which is regarded as a safe and successful position.^{36, 37} In addition to the biologic benefit of reducing bone resorption, the placement of dental implants in an edentulous space¹⁰ also offers a different biomechanical benefit, improving the position of the fulcrum line,¹³ in the case of an implant-retained RPD.

This clinical study began after the 1st year of implant insertion. This is because the bone resorption in the first year is more than in the next years. According to the criteria for implant success, the marginal bone loss is about 1mm in the first year after the abutment connection and then 0.2 mm per year after that.³⁸

In this study, Corel Draw 11 computer program was used for bone change measurement. For the elimination of the radiographic magnification error, the scale of Corel Draw 11 was adjusted based on the actual length of the (implant and O-ring ball abutment) as it was used as a reference device. As well, a wrought

Table 3: Mean probing depth values (SD) of the canine and implant at 1, 5 years after each implant retained RPD insertion. Wilcoxon Signed Ranks test to compare the probing depth of the 2 groups of RPD (single support, dual support)

Time of evaluation	Canine tooth		Mesial implant	
	1 year	5 years	1 year	5 years
	Mean (SD)	Mean (SD)	Mean (SD)	Mean (SD)
Single support	1.13 (.27)	1.19 (.38)	1.15 (.24)	1.25 (.37)
Dual support	1.18 (.44)	1.29 (.41)	1.20 (.26)	1.14 (.48)
Wilcoxon Z	-.333-a	-1.604-b	-.447-a	-1.342-b
P value	.739	.109	.655	.180

a. Wilcoxon Signed Ranks Test

b. Based on negative ranks.,. c. Based on positive ranks

Table 4: Mean bone change values (SD) of the canine and implant at 1, 5 years after each implant retained RPD insertion. Paired t-test for comparisons of the bone loss at different sites of the 2 groups of RPD (single support, dual support)

Time of evaluation	Canine tooth		Mesial implant		Residual ridge	
	1 year	5 years	1 year	5 years	1 year	5 years
	Mean (SD)	Mean (SD)	Mean (SD)	Mean (SD)	Mean (SD)	Mean (SD)
Single support	.087 (.012)	1.14 (.23)	.173 (.029)	1.15(.24)	.26 (.05)	1.1 (.20)
Dual support	.147 (.041)	1.28 (.22)	.167 (.019)	1.18 (.2)	.42 (.07)	1.13 (.23)
t value	4.392	-2.951-	1.032	-1.491-	5.5	-1.000-
P value	.002*	.015*	.329	.167	.0001*	.341

Table 5: Mean bone change values (SD) of the residual ridge (at the mesial, center, distal position) at 1, 5 years after each prosthesis insertion. Paired t-test for comparisons of the bone loss of the 2 groups at different sites

Time of evaluation	Residual ridge resorption after 1 year			Residual ridge resorption after 5 years		
	Mesial	center	distal	Mesial	center	distal
	Mean (SD)	Mean (SD)	Mean (SD)	Mean (SD)	Mean(SD)	Mean (SD)
Single support	.20 (.032)	.26 (.061)	.31 (.094)	1.0 (.22)	1.1 (.20)	1.18 (.20)
Dual support	.27 (.06)	.41 (.07)	.60 (.13)	.88 (.15)	1.15 (.22)	1.46 (.34)
t value	5.01	6.39	7.44	6.094	-1.000-	-4.432-
P value	.001	.0001	.0001	.0001	.341	.001

Table (6): Paired t-test for comparisons of the residual ridge bone loss at different sites within each group.

	Single support Residual ridge resorption				Dual support Residual ridge resorption			
	1 year		5 years		1 year		5 years	
	Mesial versus center	Center versus distal	Mesial versus center	Center versus distal	Mesial versus center	Center versus distal	Mesial versus center	Center versus distal
t value	3.12	2.83	1.000	1.936	7.44	6.39	-5.042-	-7.089-
P value	.12	.052	.341	.082	.0001*	.0001*	.001*	.0001*

wire was added to the radiographic stent fitting surface of the radiographic to act as a reference point for residual ridge bone height measurement at the mesial, center, and distal areas. Wyatt et al and De Smet et al. stated that a high degree of accuracy and reliability is

provided by computer-assisted measurement of bone levels in intraoral radiographs.^{39,40} During exposure to the radiographic image of the implant patient, radiographs must be calibrated using a radiopaque reference device of known dimensions to use the

software. An implant as a calibrated device can be used.⁴¹

In this study, some cases were reported with abutment screw loosening. This observation was that the abutment screw loosening was excessive when the patient had a long vertical lever arm. Zhang et al, 2021 found⁴² that the most common mechanical complication in implant-supported RPD cases was a loosening of the implant abutment.

The implant retained RPD was retained using resilient O-ring attachments. A stress-breaking ball (SBB) attachment may be able to control the meticulous pressure distribution underneath the denture base of the implant associated with RPD and protect the implant from potentially damaging forces, according to Kono et al. Between the mucosa under the denture base and the implant, there are incredibly large differences in how they settle during a chewing load.^{25,43}

Mirchandani et al, 2021 mentioned that the most widely used overdentures have a ball attachment (O-ring attachment), which has a ball shape for retention. Its benefits include a straightforward manufacturing process, a wide range of movement provided, cost-effectiveness, simplicity of use and maintenance, provision of good retention, maintenance of hygiene, and high patient satisfaction.⁴⁴

Additionally, based on the occlusal contact, location, and quantity of implants in the dental arch, horizontal forces and rotational movements might also be applied to the implants. Therefore, the implant may be subjected to excessive and damaging occlusal forces.²⁵ Resilient attachments have been used to overcompensate for the pressure displacement of the mucosa and safeguard implants from the excess force.^{45, 46} These attachments are intended to stop unnecessarily heavy occlusal forces. It can evenly distribute the occlusal force between the implant and the alveolar ridge.^{47, 48}

A spacer was added between the attachment components during the clinical pick-up of the O-ring attachment to increase the attachment's resilience. Phoenix³ stated that: To make the attachment resilient, a spacer between the attachment components within the prosthesis must be incorporated during processing or clinical pickup. In this study, the O-ring attachment enables rotational, hinge-like, and vertical display. The statistical power of the current study is constrained due to the small sample size, which is one of its limitations. However, this study is crucial because earlier studies exploring the implant in combination with RPD were either case reports or studies with smaller sample sizes.¹⁰⁻¹⁴ Despite these drawbacks, the parameters (PI, BI, and PD) used in this study to evaluate the health of the peri-implant soft tissue are typically used in clinical studies.⁴⁹⁻⁵¹ Regarding the parameters pertaining to the canine or peri-implant tissue health, there were no statistically significant differences between the single support and dual support designs (null hypothesis not

rejected). Regarding the bone changes in the two different designs, there were statistical differences so the null hypothesis was rejected. The findings of this study showed that the single support of the RPD is preferred with mesial implant retained RPD because it more effectively preserves the canine and residual ridge than the dual support of the RPD. This might be explained by the fact that the single support allows for vertical displacement in the presence of a pitting force. But fulcrum line formation and rotational movement are made possible by the dual, simultaneous, support of two very different structures with very different viscoelastic responses to forces. The rotational motions of RPDs may produce terminal torque forces against the soft tissue and the abutment teeth, according to Friel and Waia⁵². The RPD's dual support causes greater forces to be transmitted from the prosthesis to the abutment teeth than those teeth can withstand and bone resorption happened and can lead to tooth mobility.

In this study, the various types of structures shearing in denture support have different effects on the pattern of residual ridge resorption in implant-retained RPD. The dual support used in this study allows for the formation of a supportive fulcrum line at the cingulum rest during functional loading, which causes rotational movement and results in a pattern of resorption of the residual ridge that is downward-sloping. More residual ridge resorption occurs at this location due to the rotational movement of the RPD under occlusal loading, which transmits excessive force there. Unfortunately, Wyatt⁵³ noted that distal extension RPDs are still vulnerable to ongoing residual ridge resorption, particularly in the posterior region. Guedes et al,⁵⁴ discovered that distally descending free-end mandibular residual ridges predominate.

When the canine serves as the abutment teeth, the mandibular RPD tends to increase the ridge's distal inclination. This may be attributed to the presence of cingulum rest, which transfers the forces to the ridge area.⁵⁵ In distal implant RPD, Kono et al.²⁵ discovered that the pressure distribution on the alveolar ridge tended to be greater with the stress-breaking ball attachment than with the healing cap.

As an alternative, the solitary soft tissue support avoids the development of the fulcrum line and provides a stable foundation for the removable partial denture. This type of tissue support under functional loading is made possible by the shimming of a resilient O-ring attachment, which results in an equal pattern of residual ridge resorption. According to Turbyfill⁵⁶, the mucosal tissue beneath the distal extension base may not be rigid enough to prevent rotational movement around the distal abutment.

As a result, there won't be an even distribution of weight, and the distal extension base will put more stress on the ridge than it does on the mesial part. The presence of an occlusal rest with a clasp retained RPD causes the prosthesis to move in

an arc, whereas an attachment with resilient shimming can allow a single path of insertion in a vertical direction and enable the denture to move uniformly.⁵⁷⁵⁸ The occlusal rest is the part of RPD that transmit the occlusal force to the prosthesis.⁵⁵ The shimming of the attachment allows vertical movement of the prosthesis when the occlusal pressure is applied to the RPD. The denture base will rebound once the pressure is released, creating a shim or space between the male and female parts of the attachment. The most essential result of this technique is the stability of the dentures.⁵⁹

This study revealed that after 5 years, in dual support RPD design, the bone resorption of the canine was higher than that for the implant. But for the single support RPD design, the bone resorption of the canine did not differ from that for the implant. This may be attributed to the occlusal rest that transfer occlusal force to the abutment teeth. Also, the implant receives more load in the case of single support. Mousa et al, 2021 mentioned that in implant-assisted RPD, the implant carries the majority of the load, reducing stress on the abutment and minimizing prosthesis displacement.²⁹ Yoo et al, 2022 stated that:⁶⁰ In cases of Class I RPD connected to residual teeth and strategically positioned implants as surveyed crowns, the abutment teeth's bone loss was less than the MBL of the implants.

In this study the RPD with a single support, the implant considered the point of a retentive fulcrum line, so the proximal plates serve as an indirect retainer. In contrast to conventional RPD, the fulcrum line in the implant retained RPD close to the alveolar ridge. Putra Wigianto et al⁶¹ mentioned that implant-assisted RPD had successful clinical outcomes when used to replace edentulous regions in the distal extension. A simple and economical method of symmetric prosthesis support and stability, as well as increased patient satisfaction, is implant-assisted RPDs. Implant-assisted RPDs are a quick and affordable way to provide symmetric prosthesis support and stability, as well as higher patient satisfaction.⁶²⁻⁶⁴

The limitation of this study is the limited sample size. Future research may be done to observe the effects of various attachment systems, implant placement positions, and treatment regimens for implant-assisted RPD in distal extension cases on implant survival rates, clinical outcomes, and patient satisfaction. This necessitates the performance of more high-quality studies.

Conclusion:

Within the limitations of this study, mesial implant

retained tissue-supported RPD can be used to successfully manage symmetrical bilateral distal extension cases. Compared to dual tooth-tissue supported implant retained RPD, single tissue-supported implant retained RPD better protects the remaining oral structure.

References:

1. Abd El-Khalik MM, El Mekawy NH, El-Kasaby SS. Mandibular Kennedy Class I partial denture management by broad stress distribution philosophy (radiographic assessment). *J Indian Prosthodont Soc.* 2016;16(3):282-287. doi:10.4103/0972-4052.179263
2. Kim JJ. Revisiting the Removable Partial Denture. *Dent Clin North Am.* 2019;63(2):263-278. doi:10.1016/j.cden.2018.11.007
3. Phoenix RD, Cagna DR, DeFrees CF: Implant assisted removable partial Dentures in Stewart's Clinical Removable Partial Prosthodontics. fourth Edition. Quintessence Publishing Co, Inc. 2008; pp:19-22, 259-277.
4. Eom JW, Lim YJ, Kim MJ, Kwon HB. Three-dimensional finite element analysis of implant-assisted removable partial dentures. *J Prosthet Dent.* 2017;117:735-742.
5. Ramchandran A, Agrawal KK, Chand P, Ramashanker, Singh RD, Gupta A. Implant-assisted removable partial denture: An approach to switch Kennedy Class I to Kennedy Class III. *J Indian Prosthodont Soc.* 2016;16:408-411.
6. Tribst JP, de Araújo RM, Ramazine NP, et al. Mechanical behavior of implant assisted removable partial denture for Kennedy class II. *J Clin Exp Dent.* 2020;12(1):e38-e45. Published 2020 Jan 1. doi:10.4317/medoral.56533
7. Ortiz-Puigpelat O, Lázaro-Abdulkarim A, de Medrano-Reñé JM, Gargallo-Albiol J, Cabratosa-Termes J, Hernández-Alfaro F. Influence of Implant Position in Implant-Assisted Removable Partial Denture: A Three-Dimensional Finite Element Analysis. *J Prosthodont.* 2019;28(2):e675-e681. doi:10.1111/jopr.12722
8. Oh YK, Bae EB, Huh JB. Retrospective clinical evaluation of implant-assisted removable partial dentures combined with implant surveyed prostheses. *J Prosthet Dent.* 2021;126(1):76-82. doi:10.1016/j.prosdent.2020.04.018
9. Park JH, Lee JY, Shin SW, Kim HJ. Effect of conversion to implant-assisted removable partial denture in patients with mandibular Kennedy classification I : A systematic review and meta-analysis. *Clin Oral Implants Res.* 2020;31(4):360-373. doi:10.1111/clr.13574
10. Mijiritsky E, Ormianer Z, Klinger A: Use of dental implants to improve unfavorable removable partial denture design. *Compend Contin Educ Dent* 2005; 26(10): 744-750.
11. Mijiritsky E. Implants in Conjunction With Removable Partial Dentures: A Literature Review *Implant Dent* 2007;16:146–154.
12. Renato DF, Bazzan KO, Matida HM, Benchimol

- DR, Kaizer OF: Prosthetic rehabilitation of a bonedefect with a teeth-implant supported, removable partial denture. (clinical science and techniques), *Implant Dentistry* 2006;15 (3): 241-7.
13. Vogel RC: Implant overdentures: a new standard of care for edentulous patients- current concepts and techniques. *Functional esthetics and restorative dentistry*.1(2):30-36.
www.zestanchors.com/images/articles/article_86_F ERDVOGEL-RPD.pdf. Accessed in 21/11/2022.
 14. Mitrani R, Brudivik JS, Phillips KM: Posterior implants for distal extension removable prostheses: a retrospective study. *Int J Periodontics Restorative Dent* 2003; 23(4):353-359.
 15. Kuzmanovic DV, Payne AGT, Purton DG. Distal implants to modify the Kennedy classification of a removable partial denture: a clinical report. *J Prosthet Dent* 2004;92:8–11.
 16. Turkyilmaz I. Use of distal implants to support and increase retention of a removable partial denture: a case report. *J Calif Dent Assoc* 2009;75:655–8.
 17. Shahmiri RA, Atieh MA. Mandibular Kennedy Class I. implant-tooth-borne removable partial denture: a systematic review. *J Oral Rehabil* 2010;37:225–34).
 18. Ohkubo C, Kobayashi M, Suzuki Y, Toshio H. Effect of implant support on distal-extension removable partial dentures: in vivo assessment. *Int J Oral Maxillofac Implants* 2008;23:1095–101.
 19. Bortolini S, Natali A, Franchi M, Coggiola A, Consolo U. Implant-retained removable partial dentures: an 8-year retrospective study. *J Prosthodont* 2011;20:168–72.
 20. Mijiritsky E, Karas S. Removable partial denture design involving teeth and implants as an alternative to unsuccessful fixed implant therapy: a case report. *Implant Dent* 2004;13:218–22.
 21. Ohkubo C, Kurihara D, Shimpo H, Suzuki Y, Kokubo Y, Hosoi T. Effect of implant support on distal extension removable partial dentures: in vitro assessment. *J Oral Rehabilitation* 2007;34:52–6.
 22. Grossmann Y, Nissan J, and Levin L. Clinical Effectiveness of Implant-Supported Removable Dentures. A review of the literatures and retrospective case evaluation. *J Oral Maxillofac Surg* 2009 67:1941-1946.
 23. Rodrigues RCS, Macedo AP, de Mattos MGC, Ribeiro RF. Retention and stress distribution in distal extension removable partial dentures with and without implant association. *Journal of Prosthodontic Research* 57 (2013) 24–29
 24. Sato M, Suzuki Y, Kurihara D, Shimpo H, Ohkubo C. Effect of implant support on mandibular distal extension removable partial dentures: Relationship between denture supporting area and stress distribution. *Journal of Prosthodontic Research* 57 (2013) 109–112).
 25. Kono K, Kurihara D, Suzuki Y, Ohkubo C. Pressure distribution of implant-supported removable partial dentures with stress-breaking attachments. *J Prosthodont Res* 2014;1-6.
 26. Chikunov I, Doan P, Vahidi F. implant- Retained Partial Overdenture with Resilient Attachments. *Journal of Prosthodontics* 2007: 1-8.
 27. Zitzmann N. When restoring the teeth of partially edentulous patients with removable partial dentures, do you consider placing implants to enhance the retention and stability of the prosthesis? *JCDA* 2005, 71:552-553.
 28. Chee WWI: Treatment Planning: Implant-Supported Partial Overdentures. *JCDA* 2005; 33 (4): 313-316.
 29. Mousa MA, Abdullah JY, Jamayet NB, et al. Biomechanics in Removable Partial Dentures: A Literature Review of FEA-Based Studies. *Biomed Res Int*. 2021;2021:5699962.
 30. Mustafa AZH. Duplicating the implant O-ring abutment retainer for using on tooth copy in mandibular implant tooth partial overdenture: radiographic evaluation. *European Journal of Dentistry and medicine* 2012; 4(3):45-55.
 31. Mustafa AZH. Mesial implant retained mandibular removable partial overdenture: comparative study of denture connection to versus denture disconnection from the remaining teeth. *Egyptian Dental Journal*. 2014; 60(3) 3077:3087
 32. Mustafa AZH, Abd El-Khalik MM, El-Motiam HAM, El-Kennawy MH, Abd El-Latief MF. Implant Retained –Tissue Supported Mandibular Distal- Extension RPD for Tooth preservation. *Egyptian Dental Journal*. 2010;56:647-653
 33. El-Shaheed NH, Lamfon HA, Salama RA, Faramawy AMG, Mostafa AZH. Tissue Surface Adaptation and Clinical Performance of CAD-CAM Milled versus Conventional Implant-Assisted Mandibular Overdenture. *Int J Dent*. 2022;1-11.
 34. Langland OE, Langlais RP, Preece .J: Principles of dental imaging. (2nd ed.) Lippincott Williams and Wilkins 2002 p 85-113.
 35. Liu M, He L, Wang H. Clinical and radiographic performance of one-piece and two-piece implant: a systematic review and meta-analysis. *J Prosthodont Res*. 2021 Feb 24;65(1):56-66.
 36. Sener E, Onem E, Akar GC, et al. Anatomical landmarks of mandibular interforaminal region related to dental implant placement with 3D CBCT: comparison between edentulous and dental mandibles. *Surg Radiol Anat*. 2018;40(6):615-623.
 37. Mahmoudinezhad SS, AryanKia A, Shooshtari SS, Moradi K. The Effect of Mandibular Angulation on Preoperative Assessment of Dental Implant Insertion at Premolar Region: CBCT Study. *Biomed Res Int*. 2022;2022:7879239.
 38. Misch CE, Perel ML, Wang HL, et al. Implant success, survival, and failure: the International Congress of Oral Implantologists (ICOI) Pisa Consensus Conference. *Implant Dent*. 2008;17(1):5-15.
 39. Wyatt CC, Bryant SR, Avivi-Arber L, Chaytor DV, Zarb GA: A computer-assisted measurement technique to assess bone proximal to oral implants on intraoral radiographs. *Clin Oral Implants Res* 2001; 12(3):225-229.

40. De Smet E, Jacobs R, Gijbels F, Naert I: The accuracy and reliability of radiographic methods for the assessment of marginal bone level around oral implants. *Dentomaxillofac Radiol* 2002;31(3):176-181.
41. Anil S, Al-Ghamdi HS: A Method of Gauging Dental Radiographs during Treatment Planning for Dental Implants. *J Contemp Dent Pract* 2007; 8(6): 082-088.
42. Zhang H, Ramos V Jr, Bratos M, Liu PP, He W. Effect of the attachments on clinical outcomes of mandibular distal extension implant-supported removable partial dentures: A systematic review [published online ahead of print, 2021 Jul 20]. *J Prosthet Dent*. 2021;S0022-3913(21)00218-3.
43. Alan BC, David TB. McCracken's removable partial prosthodontics. In: *Principles of removable partial denture design*. Amsterdam: Elsevier Inc; 2010: 115–29.
44. Mirchandani B, Zhou T, Heboyan A, Yodmongkol S, Buranawat B. Biomechanical Aspects of Various Attachments for Implant Overdentures: A Review. *Polymers (Basel)*. 2021;13(19):3248.
45. Wim S, Gerry MR, Arjan V, James JHS, Henny JAM. A systematic review of implant-supported maxillary overdentures after a mean observation period of at least 1 year. *J Clin Periodontol* 2010;37:98–110.
46. Chen KW, Lin TM, Liu PR, Ramp LC, Lin HJ, Wu CT, et al. An analysis of the implant-supported overdenture in the edentulous mandible. *J Oral Rehabil* 2013;40:43–50.
47. Suzuki Y, Ohkubo C, Kurtz KS. Clinical application of stress-breaking ball attachment for implant overdenture. *J Prosthodont Res* 2013;57:140–4.
48. Jones JD, Turkyilmaz I, Garcia LT. Removable partial dentures--treatment now and for the future. *Tex Dent J*. 2010;127(4):365-372.
49. Levy D, Deporter DA, Watson PA, Pilliar RM. Periodontal parameters around porous-coated dental implants after 3 to 4 years supporting overdentures. *J Clin Periodontol* 1996;23:517-22.
50. Nishimura K, Itoh T, Takaki K, Hosokawa R, Naito T, Yokota M. Periodontal parameters of osseointegrated dental implants. A 4-year controlled follow-up study. *Clin Oral Implants Res* 1997;8:272-8.
51. Stephan G, Vidot F, Noharet R, Mariani P, Implant-retained mandibular overdentures: A comparative pilot study of immediate loading versus delayed loading after two years. *J Prosthet Dent* 2007; 97: S138-S145.
52. Friel T, Waia S. Removable Partial Dentures for Older Adults. *Prim Dent J*. 2020;9(3):34-39.
53. Wyatt CCL: The effect of prosthodontic treatment on alveolar bone loss: A review of the literature. *J Prosthet Dent* 1998; 80: 362-6.
54. Guedes CG, Zanetti AL, Feltrin PP. Analysis of the prevalence of different topographical characteristics of the residual ridge in mandibular free-end arches. *Braz OralRes* 2004;18(1):29-34.
55. Suenaga H, Kubo K, Hosokawa R, Kuriyagawa T, Sasaki K. Effects of occlusal rest design on pressure distribution beneath the denture base of a distal extension removable partial denture-an in vivo study. *Int J Prosthodont*. 2014;27(5):469-471.
56. Turbyfill WF. Impression techniques for removable partial dentures. *Gen Dent*. 2001;49(4):358-364.
57. Capp NJ, Kurban N. Alternative approach to the restoration of distal extension saddles. *Restorative Dent*. 1990;6(1):7-12. Omura AJ, Latthe V, Marin MM, Cagna DR. Implant-assisted removable partial dentures: practical considerations. *Gen Dent*. 2016;64(6):38-45.
58. Uludag B, Polat S, Sahin V, Tokar E, Goktug G. A technique for fabrication of an extracoronary attachment-retained removable partial denture to fit an existing fixed partial denture. *J Prosthodont*. 2012;21(2):138-140.
59. Lee K. Double impression procedure for removable partial denture retained with semiprecision attachments: A clinical report. *J Prosthet Dent* 1996;75:538-7.
60. Yoo SY, Kim SK, Heo SJ, Koak JY. Clinical and radiographic evaluations of implants as surveyed crowns for Class I removable partial dentures: A retrospective study. *J Adv Prosthodont*. 2022;14(2):108-121.
61. Putra Wigianto AY, Goto T, Iwawaki Y, Ishida Y, Watanabe M, Ichikawa T. Treatment outcomes of implant-assisted removable partial denture with distal extension based on the Kennedy classification and attachment type: a systematic review. *Int J Implant Dent*. 2021;7(1):111.
62. Bassetti RG, Bassetti MA, Kuttenger J. Implant-Assisted Removable Partial Denture Prosthesis: A Critical Review of Selected Literature. *Int J Prosthodont*. 2018;31(3):287-302.
63. Nogawa T, Takayama Y, Ishikawa M, Yokoyama A. The impact of an additional implant under the saddle of removable partial dentures in Kennedy Class II edentulism on oral health-related quality of life and oral function: a case series report. *Int J Implant Dent*. 2022;8(1):60.
64. Bandiaky ON, Lokossou DL, Soueidan A, et al. Implant-supported removable partial dentures compared to conventional dentures: A systematic review and meta-analysis of quality of life, patient satisfaction, and biomechanical complications. *Clin Exp Dent Res*. 2022;8(1):294-312.