

Evaluation of Chitosan's Potential Protective Effect Against Irinotecan-Induced Tongue Damage of Adult Male Albino Rats (Histological and Scanning Electron Microscopic Study)

Original
Article

Salwa M. Ouies¹, Ahmed T. Galal², Amal A. Mohammed¹ and Noha A. Ragab¹

Department of Human Anatomy and Embryology, Faculty of Medicine, ¹Sohag University, ²Assuit University, Egypt

ABSTRACT

Introduction: Irinotecan (IRT), a cytotoxic medication, received its initial approval for the treatment of cancer in Japan 25 years ago. IRT prodrug has made a significant contribution to the treatment of solid tumors all around the world for more than 20 years; it is a semisynthetic derivative of camptothecin. The second-most prevalent natural polysaccharide, Chitosan, is highly biocompatible and exhibits significant anticancer action. Chitosan is an extensively utilized polymer in pharmacology, particularly in oncotherapy, because to its biodegradability, biocompatibility, biodistribution, nontoxicity, and lack of immunogenicity.

Objective: To assess Chitosan's potential preventive effects on irinotecan-induced tongue damage.

Material and Methods: Experiment was performed in Sohag Animal House of the Faculty of Medicine (March 2023). 30 adult male albino rats were subdivided into three groups 10 rat/ group: (I) control group. (II) irinotecan treated group for 4 days. (III) irinotecan & Chitosan treated group for 4 days. The anterior 2/3 of the tongues were taken and prepared for light and scanned electron microscopic study.

Results: Irinotecan produced various apparent histopathological changes in tongue structure; the filiform papillae appeared atrophied with loss of their regular orientation. Abnormal shaped fungiform papillae with destruction of their covering epithelium was also observed, numerous inflammatory cells were seen in the lamina propria and in-between muscles. There was a significant decrease in both height and width in the lingual papillae in group II in comparison to control group. Improvement of these changes was detected in group III after Chitosan addition.

Conclusion: Chitosan attenuated the structural changes in the rats' tongues induced by irinotecan treatment.

Received: 31 July 2023, **Accepted:** 02 October 2023

Key Words: Chitosan; irinotecan; tongue.

Corresponding Author: Salwa M. Ouies, MD, Department of Human Anatomy and Embryology, Faculty of Medicine, Sohag University, Egypt, **Tel.:** +20 10 0207 3124, **E-mail:** salwaouies@yahoo.com

ISSN: 1110-0559, Vol. 47, No. 4

INTRODUCTION

A semi-synthetic derivative of the plant alkaloid camptothecin is irinotecan (CPT-11). It is one of the most significant anti-tumor medications created in the previous ten years. It is effective against a wide range of cancers, including malignant gliomas and colon, stomach, ovary, and lung carcinomas^[1,2].

Unfortunately, its administration is linked to a variety of gastrointestinal side effects, including nausea and vomiting brought on by chemotherapy as well as diarrhoea, abdominal pain, and decreased appetite^[3].

Chitosan, a biopolymer derived from chitin that is non-toxic and used to treat oral mucositis, is biodegradable. The fact that it contains anti-inflammatory and antioxidant qualities makes it preferable to other biopolymers^[4]. It prevents the tissue damage as it reduces the increased IL-1 and TNF- levels in rat inflammatory models^[5].

The aim of the work is to detect the possible protective effect of chitosan in irinotecan-induced tongue damage in albino rats

MATERIAL AND METHODS

Ethical approval

The work was based on the "Guide for the Care and Use of Laboratory Animals" (Institutes of Laboratory Animal Research)^[6], and in accordance with the Sohag University Animal Ethics' principles, as well as being approved by the committee's research ethics and use of laboratory animals registration number: Soh-IACUC-5-12-23-3).

Drugs

Irinotecan was purchased from Sigma Aldrich Chemical Co (ampule 100/5ml; Cat. # 1347609 USP Sigma Aldrich). Chitosan was obtained from Pfizer Company for use in the chemical and pharmaceutical sectors. (capsule =500 mg).

Animals

30 adult male rats (170-220 grams) were used, received from Sohag University in Egypt's Animal House of the Faculty of Medicine. Rats were kept in sanitary conditions. A standard diet of food and water was given to all participants.

DOI: 10.21608/ejh.2023.225198.1928

Experimental approach

Experiment was performed in Sohag Animal House of the Faculty of Medicine (March 2023). After a seven-day acclimation period, the animals were evenly divided into three groups (10 rat/ group).

1. **Group I (control):** 10 rats were given 0.5 ml of saline intraperitoneally for 4 days;
2. **Group II:** 10 rats were received Irinotecan intraperitoneally in diluted form with normal saline (50 mg/kg/day) for four consecutive days^[7].
3. **Group 3:** 10 rats were given diluted irinotecan + concomitant Chitosan (200 mg/kg) by oral gavage for the consecutive 4 days^[5].

Methods

Animals were decapitated, and the anterior 2/3 of the tongues was excised, 24 hours after the last dose.

Preparation for light microscopic examination^[8]

The samples were preserved in 10% neutral buffered formalin. Paraffin blocks were processed, cut to thin sections and stained with Hematoxylin and Eosin before being ready for light microscopic examination.

Preparation for Scanning Electron Microscopy^[9]

The specimens were first fixed with 5% glutaraldehyde, followed by a series of cold cocodylate buffer washes, and finally post-fixed with 1% osmium tetroxide. They underwent dehydration in a graduated ethanol series, drying with liquid CO₂, and surface coating with a thin layer of gold (10–15 μm) applied in a vacuum evaporator. Then, in the Assiut University Center, it was analyzed with a Jeol-JSM-5400 LV scanning electron microscope.

Morphometric Study and statistical analysis

In 10 randomly chosen fields for each H&E-stained slide (X400) from each group, the filiform and fungiform lingual papillae's height and width were measured. The height was determined by measuring distance between the papilla's tip and base. The papillae width was determined by measuring the base diameter at the broadest area extending from epithelial surface to the other surface. The locations of the papillae's height and width measurements were depicted in (Figures A and B)^[3,10].

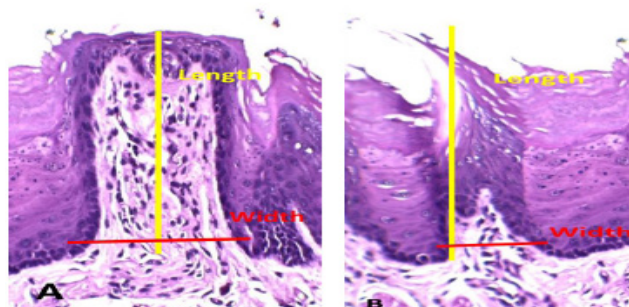


Fig. A,B:

Measurements (mean value ± Standard deviation) were analyzed using SSPS program version 16 using one-way ANOVA and a post-hoc test when ANOVA was statistically significant (P value ≤ 0.05)

RESULTS

General observations

Control group

Generally, rats receiving saline showed normal attitude, features and activity. After sacrificing the animals, dissection for the tongue revealed normal gross anatomy (Figure 1)

Irinotecan treated group: Rats showed altered attitude features and activity in the form of irritation followed by malaise, from the 2nd day after receiving the treatments, decrease activity, the fur becoming ruffled with yellowish orange discoloration of the teeth. After sacrificing the animals, dissection of tongue revealed congestion, redness with swellings in the dorsum of the anterior two thirds (Figure 2).

Irinotecan+ chitosan treated group

Rats had some sort of normal attitude, yellowish orange discoloration of the teeth. After sacrificing the animals, dissection of the tongue revealed mild congestion and redness of the dorsum of the anterior two thirds (Figure 3).

Light microscopy

Control group

The dorsal surface of the tongues appeared covered with regular oriented filiform papillae which showed pointy points and a thin, silky keratin layer, fungiform papillae appear scattered in between filiform papillae with well-defined barrel-shaped taste pore. Below, lamina propria's underlying connective tissue can be seen. Skeletal muscle fibers of the tongue were arranged differently; some appear oblique and transverse, while others had a longitudinal pattern with parallel bundles of muscle fibers (Figures 4,5).

Irinotecan treated group: The dorsal surface of the tongues showed loss of the filiform papillae's normal orientation which showed areas of atrophied papillae. The intraepithelial taste buds in fungiform papillae had destructed and keratin had separated. Infiltrations of inflammatory cells were observed between muscles and in the lamina propria (Figures 6,7).

Irinotecan+ chitosan treated group

The dorsal surface of the tongues showed in most areas showed long, pointed filiform papillae covered with stratified squamous keratinized epithelium. In other areas it showed abnormal destructed papillae, with a typical intraepithelial taste bud in a barrel shape, fungiform papilla. Infiltrations of inflammatory cells still were situated between muscles and in the lamina propria (Figures 8,9).

Electron microscope scan

Control group: the tongue's dorsal surface described long conical filiform papillae with intact, tapering, keratinized tips displayed consistent alignment in one direction.. Between filiform papillae, mushroom-like fungiform papillae with a central gustatory orifice and a smooth, flat upper surface that occasionally displayed keratinized tips developed (Figures 10,11,12).

Irinotecan treated group: tongue of this group showed many pictures of damages in the filiform papillae in the form of blunted ends in some areas, disfigured papillae in other areas and areas of desquamation of the surface also seen. Fungiform papilla appeared irregular, disorganized and showed destruction of its epithelial cells with ill-defined taste pore in most papillae (Figures 13,14,15).

Irinotecan+ chitosan treated group: normal architecture was seen in most filiform papillae with still other areas appeared affected with blunted and disfigured papillae in other areas. Normal appearance of the fungiform papillae present with well-defined taste pore in most areas was seen. (Figures 16,17,18).

Morphometric results

Height of filiform papillae (Table 1, Histogram 1)

Mean height of filiform papillae in rats treated with IRT (239.8 ± 25.4) described a significant decrease in comparison with adult control rats (320 ± 20.12).

The mean height of filiform papillae of rats treated with IRT and chitosan (254.3182 ± 38.6) showed significant decrease as compared with controls and non -significant difference as compared with IRT treated rats

Height of fungiform papillae (Table 1, Histogram 1)

Mean height of fungiform papillae in rats treated with IRT (277.8 ± 3.2) described a significant decrease in comparison with control rats (292.1 ± 6.7).

The mean height of fungiform papillae of rats treated with IRT and chitosan (286.7 ± 7.7) showed significant decrease as compared with controls and significant increase as compared with IR treated rats

Width of filiform papillae (Table 1, Histogram 2)

Mean width of filiform papillae in rats treated with IRT (72.8 ± 29.7) described a significant decrease in comparison with control rats (90.6765 ± 7.7).

The mean width of filiform papillae of rats treated with IRT and chitosan (60.7 ± 8.8) described a significant decrease as compared with controls and non -significant difference with IRT treated rats

Width of fungiform papillae (Table 1, Histogram 2)

The mean width of fungiform papillae of rats treated with IRT (112.8 ± 11.1) described a significant decrease in comparison with control rats (169.4 ± 5.8).

The mean width of fungiform papillae of rats treated with IRT and chitosan (107.5 ± 23.3) showed significant decrease as compared with controls and non -significant difference with IRT treated rats

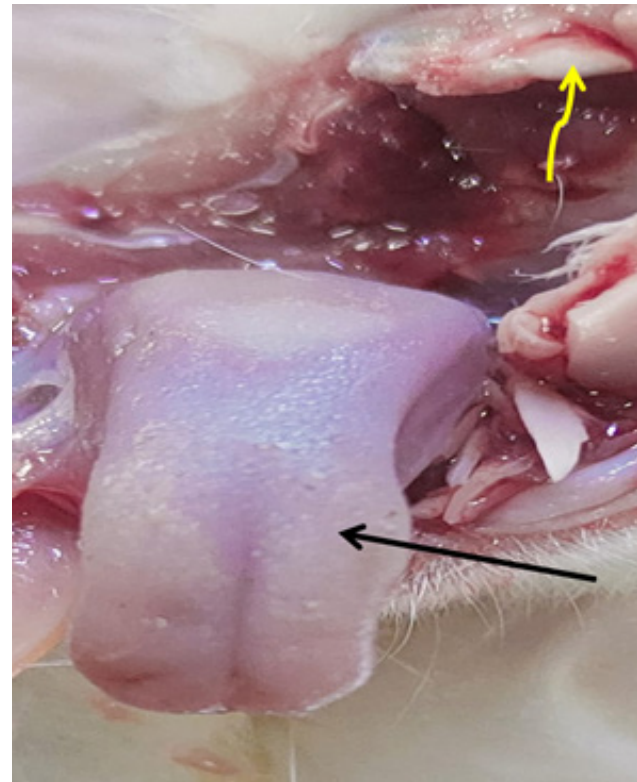


Fig. 1: a photomicrograph of control rat tongue showing normal gross anatomy of the dorsum of the anterior two thirds (arrow) and white color of the teeth (wavy yellow arrow).

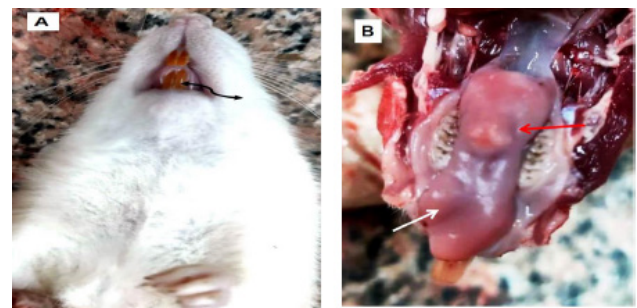


Fig. 2: a photomicrograph of rat tongue received IRT showing (A) orange discoloration of the teeth (wavy arrow), (B): redness (red arrow) and swellings (white arrow) of the tongue.

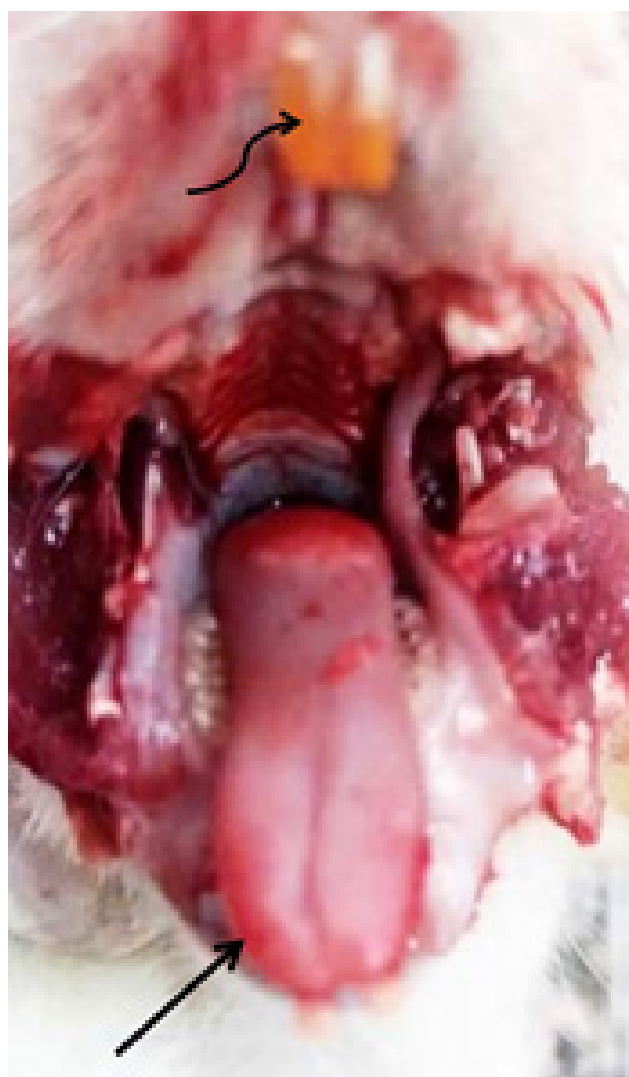


Fig. 3: a photomicrograph of IRT + Chitosan rat tongue showing yellowish discoloration of the teeth (wavy arrow) and some congestion in the dorsum of the anterior two thirds (arrow).

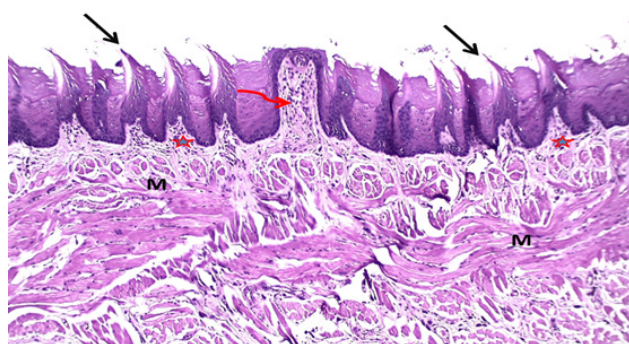


Fig. 4: A photomicrograph of tongue ' dorsal surface (Control group animal) Showing fungiform papilla (wavy arrow) appears in-between the filiform ones with muscles run in various directions (M). The filiform papillae are covered with keratinized epithelium and have a consistent orientation (arrow) with lamina propria's underlying connective tissue (asterisks). [H&E X 200].

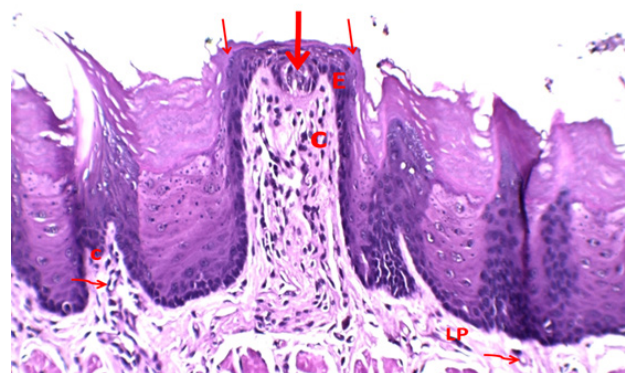


Fig. 5: Magnification of the previous picture; the fungiform papilla is elevated above the tongue's surface and appears with wide base and apex. It has a connective tissue core [C] and an epithelial cover [E] with keratinized stratified squamous epithelium covering (thin arrow). It has one distinct taste bud (thick arrow) - filiform papillae show a connective tissue core [small C] with small blood vessels [wavy arrow]-. Clearly defined connective tissue papillae make up the lamina propria (LP) (wavy arrow) [H&E X 400].

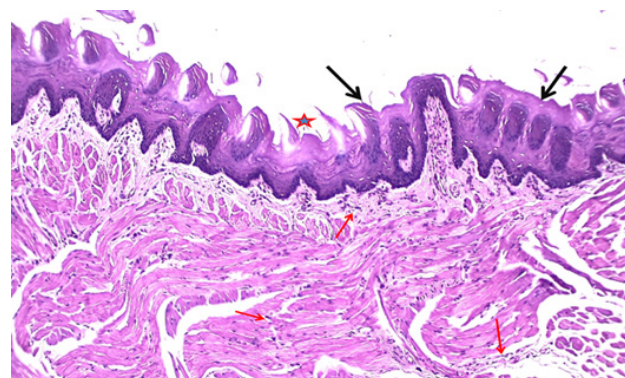


Fig. 6: A photomicrograph of tongue ' dorsal surface (Irinotecan-treated animals) describing regions of atrophied papillae (asterisks), and an altered filiform papillae orientation (black arrow). The lamina propria and the spaces between the lingual muscle fibers clearly show the infiltration of inflammatory cells (red arrow).H&E X 200].

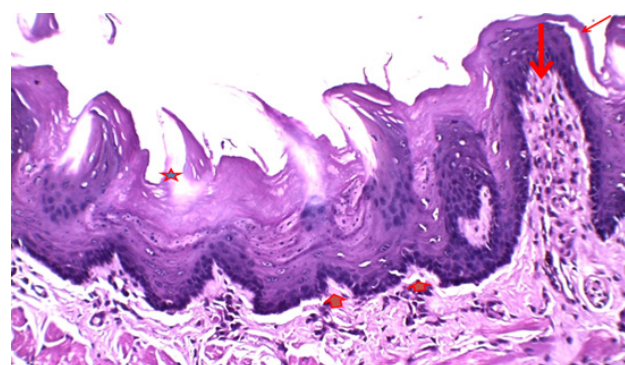


Fig. 7: Magnification of the previous picture; the fungiform papilla showing degenerated intraepithelial taste bud (thick arrow) with separation of the keratin layer from the dorsal surface's underlying epithelium (thin arrow) and shortening of the filiform papillae (short arrow) with regions of atrophied papillae (asterisks), [H&E X 400].

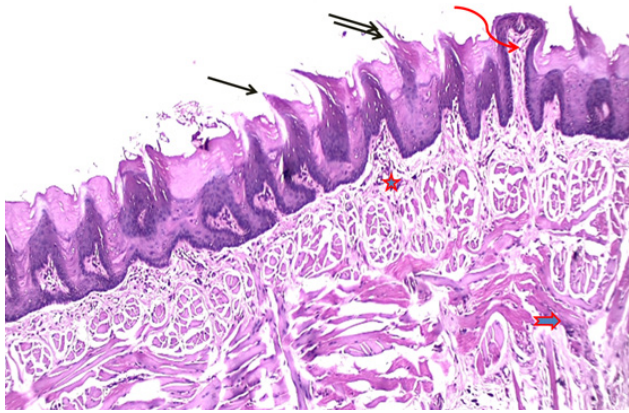


Fig. 8: A photomicrograph of tongue ' dorsal surfaces (Irinotecan+chitosan treated animals) showing some filiform papillae appear abnormal (double arrow), while others have long, pointed points and are covered in stratified squamous keratinized epithelium, fungiform papilla appeared with regular intraepithelial taste buds in a barrel form (irregular arrow) moderate inflammatory infiltration can be noticed in the lamina propria (asterisk) and in the spaces between the fibers of the lingual muscle (short arrow).[H&E X 200].

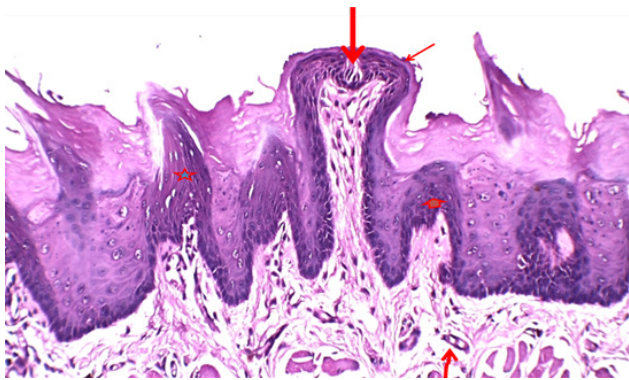


Fig. 9: Magnification of the previous picture; showing normal appearance of the fungiform papilla has typical intraepithelial taste buds in a barrel form (arrow) and covered by intact keratinized stratified squamous epithelium (thin arrow), normal filiform papillae (asterisks), with shortening of others (short arrow), inflammatory infiltration in the lamina propria with congested blood vessels (wavy arrow).[H&E X 400].




Fig. 10: Electron microscope scan of a tongue (dorsal surface) of control animals showing regular orientation of the filiform papillae and scattered numerous fungiform papillae in-between (red arrows) X 15




Fig. 11: Electron microscope scan of a tongue (dorsal surface) of control animals showing thread-like filiform papillae with regular size, shape and orientation and with tapering keratinized ends (blue arrows). Between each other, fungiform papillae with a central gustatory hole (red arrows) resemble mushrooms. X150

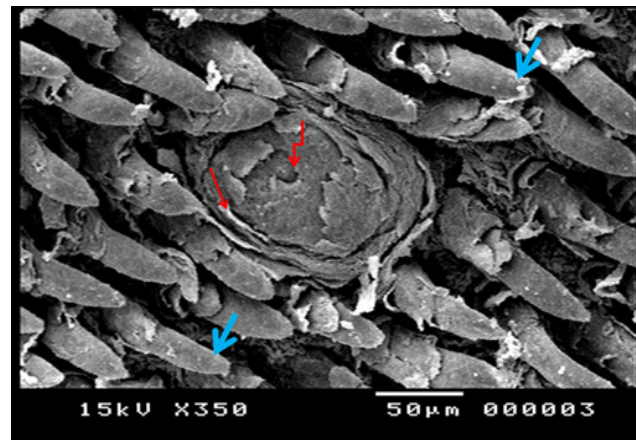


Fig. 12: Electron microscope scan of a tongue (dorsal surface) of control animals showing thread-like filiform papillae with tapering keratinized ends (blue arrows), With keratinization (red arrow) of its epithelial cells and a normal image of the gustatory pore with a shallow indentation in its center (wavy red arrow) , the fungiform papilla appears normal. X350

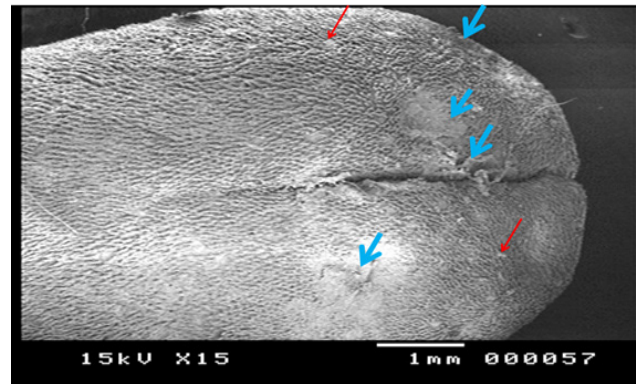


Fig. 13: Electron microscope scan of a tongue (dorsal surface) of Irinotecan treated animals showing loss of normal orientation of filiform papillae and regions of desquamation in the surface(blue arrows), scattered fungiform papillae also appear in-between (red arrows) X 15




Fig. 14: Electron microscope scan of a tongue (dorsal surface) of Irinotecan treated animals showing filiform papillae's damages; blunted (red thin arrows), disfigured (blue arrows) papillae with areas of desquamation (stars), irregular disorganized fungiform papilla also appear with unclear taste pore (wavy red arrow) X150




Fig. 16: Electron microscope scan of a tongue (dorsal surface) of Irinotecan+ chitosan treated animals showing regular orientation of filiform papillae and scattered numerous fungiform papillae in-between (red arrows), still areas of desquamation present (blue arrows) X 15




Fig. 15: Electron microscope scan of a tongue (dorsal surface) of Irinotecan treated animals describing filiform papillae's damages; thin (red thin arrow) and blunted (blue arrows). Fungiform papilla shows destruction of its epithelial cells with unclear taste pore (wavy red arrow) X350




Fig. 17: Electron microscope scan of a tongue (dorsal surface) of Irinotecan+ chitosan treated animals showing normal architecture of the filiform papillae in most areas, still blunted (red thin arrows) and disfigured (blue arrows) papillae present. Fungiform papillae appear normal and present by well-defined taste pore (wavy red arrow) X150




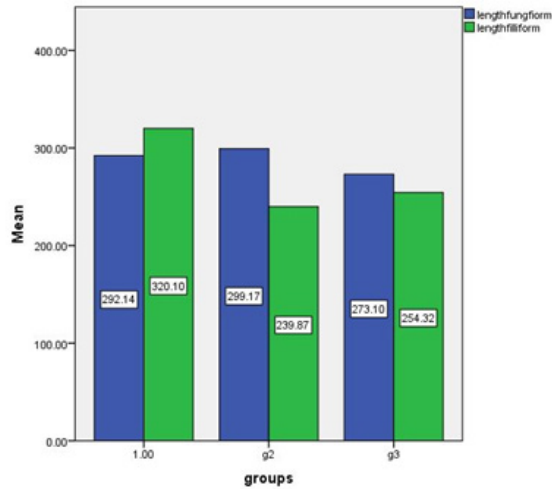
Fig. 18: Electron microscope scan of a tongue (dorsal surface) in Irinotecan+ chitosan treated animals showing normal architecture of filiform papillae in most areas, still disfigured (blue arrows) papillae present. Fungiform papillae appear normal and present by a well-defined taste pore (wavy red arrow) still some destruction of its epithelial cells present X350

Table 1: Mean Height and width of fungiform and filiform papillae at different groups control and experimental groups

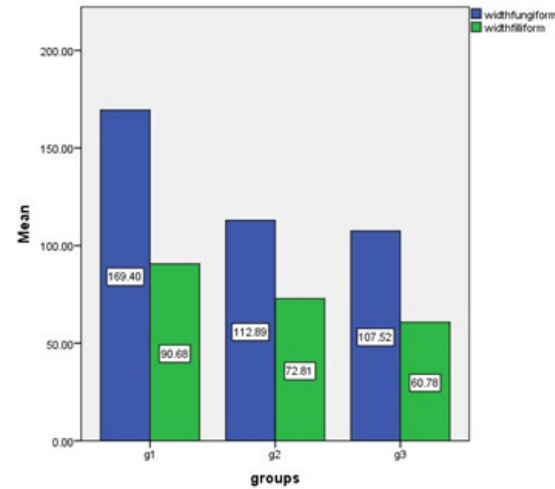
	G1	G2	G3	ANOVA	P1	P2	P3
Height of filiform	320 ± 20.1	239.8 ± 25.4	254.3 ± 38.6	.000***	.000***	.000***	.139 ^{NS}
Height of fungiform	292.1 ± 6.7	277.8 ± 3.2	286.7 ± 7.7	.000***	.000***	.003***	.000***
Width of filiform	90.6 ± 7.7	72.8 ± 29.7	60.7 ± 8.8	.000***	.000***	.000***	.139 ^{NS}
Width of fungiform	169.4 ± 5.8	112.8 ± 11.1	107.5 ± 23.3	.000***	.000***	.000***	.367 ^{NS}

P1= difference between G1 and G2
 P3= difference between G2 and G3
 NS=Non significant

P2 = difference between G1 and G3
 ***= very high significance



Histogram 1: Height (length) of fungiform and filiform papillae in different groups



Histogram 2: Width of fungiform and filiform papillae in different groups

DISCUSSION

Currently, oral mucositis, which affects 40–80% of chemotherapy patients, is thought to be the most severe side effect of anticancer therapy^[11]. Despite the availability of numerous treatment options, successful management and prevention of chemotherapy-induced mucositis remain priorities.

Light and electron microscopy examination of irinotecan treated rats showed apparent histopathological changes in tongue tissues as atrophied filiform papillae or fungiform papillae with unusual shapes and infiltration of inflammatory cells with changes in the height and width of different papillae.

Same findings were described in 2019^[10] researches found thus Irinotecan significantly changed the shape and size of the tongue mucosa, especially the filiform papillae.

Additionally, a more recent study found that rats giving irinotecan caused intestinal mucosal injury that was evident in the form of shrinkage of the villi, damaged epithelial tissue, and inflammatory cells infiltration. They proposed that the primary mechanism of irinotecan-induced mucosal damage was oxidative stress^[12].

The direct cytotoxic impact of irinotecan may be responsible for such atrophic alterations of the lingual papillae brought on by the drug's administration. Additionally, it has been hypothesized that receiving chemotherapy may result in oxidative stress and the

production of reactive oxygen species (ROS). that slows down cell proliferation^[13].

The results of the current investigation about irinotecan were consistent with those of previous researches which described similar alterations of the tongue mucosa of treated animals brought on by different cytotoxic medications, as methotrexate and 5 fluorouracil 34^[14,15].

Chitosan is a naturally occurring polysaccharide that is present in a range of shellfish, with the concentration being highest in the shell of shrimp, crab, and crayfish. Chitosan's primary qualities are that it is non-toxic, biodegradable, and biocompatible^[16,17,18].

Light and electron microscopy examination of irinotecan+ Chitosan group displayed normal architecture of the fungiform and filiform papillae at most areas with still areas of abnormal destructed papillae and inflammatory infiltration

An earlier study that demonstrated the same results revealed that chitosan protects against the harm that MTX causes to the oral mucosa. Therefore, it might be a candidate agent to treat oral mucositis brought on by MTX^[19].

Chitosan may reduce inflammation and treat oral mucositis damage, according to earlier studies that suggested this^[20].

Previous study in 2022^[21] said that the promising anticancer efficacy of chitosan-based nanoparticles has

been demonstrated both in *vitro* and in *vivo*, showing that there are numerous clinical applications. Due to its beneficial characteristics, chitosan is the perfect nanocarrier for controlled-release drugs. Additionally, it inhibits tumor cells through a variety of signaling mechanisms.

Chitosan is a suitable polysaccharide with a low level of toxicity. According to reports, taking it protect against oxidative stress brought on by cancer, while their increased penetration qualities are primarily responsible for their anti-metastatic action^[22,23].

CONCLUSION

Irinotecan produced various apparent gross, histopathological and morphological changes in tongue tissues.

Chitosan can cause protective effects on the hazards of using Irinotecan especially on the tongue.

RECOMMENDATIONS

Chitosan is recommended for Irinotecan treated patients for its beneficial effects against Irinotecan harmful sideeffects, further researches is recommended about the benefits of uses of Chitosan

CONFLICT OF INTERESTS

There are no conflicts of interest.

REFERENCES

- Friedman HS, Prados MD, Wen PY, *et al.* (2009): Bevacizumab alone and in combination with irinotecan in recurrent glioblastoma. *J Clin Oncol.*27 (28):4733-4740.
- Fuchs C, Mitchell EP, Hoff PM (2006): Irinotecan in the treatment of colorectal cancer. *Cancer Treat Rev.* 32(7):491-503.
- Ibrahim MAAH & Elwan WM. (2019): Effect of irinotecan on the tongue mucosa of juvenile male albino rat at adulthood. *Int. J. Exp.Path.* 100(4): 244–252.
- Toz, H & Değer, Y (2018): The Effect of Chitosan on the Erythrocyte Antioxidant Potential of Lead Toxicity-Induced Rats. *Biol Trace Elem Res* 184: 114–118.
- Bilginaylar, K, Aykac, A, Sayiner, S *et al.* (2022): Evaluation of the antiapoptotic and anti-inflammatory properties of chitosan in methotrexate-induced oral mucositis in rats. *Mol Biol Rep* 49, 3237–3245.
- Institute Of Laboratory Animal Resources (2011): Commission on Life Science, National Research Council of national academies. Guide for the Care and Use of Laboratory Animals. National Academy press, Washington, D.C, 8th ed., pp:11-55.
- Huang H, Wang X · Zhang X · Zhang G · Jinbo M · Wang H, YuP · and JiangW (2019) Ganciclovir reduces irinotecan-induced intestinal toxicity by inhibiting NLRP3 activation. *Cancer Chemother Pharmacol.*, 85(1):195-204.
- Bancroft J and Gamble M (2008): *Theory and Practice of Histological Techniques.*6th edition. Churchill Livingston. New York, Edinburgh, London. PP: 83-137.
- Bozzola JJ and Russell LD (1999): *Electron microscopy: principles and techniques for biologists*, 2nd edition, Boston, Jones and Bartlett Publishers, pp: 49-124.
- Takahashi Y, Takahashi H, Stern PL, Kirita T & Tsuboi A (2019): Expression of Oncofetal Antigen 5T4 in Murine Taste Papillae. *Front. Cell. Neurosci.*, 13(343):1-13
- Campos MI, Campos CN, Aarestrup FM & Aarestrup BJ (2014): Oral mucositis in cancer treatment: Natural history, prevention and treatment. *Mol Clin Oncol.* 2 (3):337-340.
- Rtibi K, Selmi S, Grami D, Sebai H, Amri M & Marzouki L. (2017): Irinotecan chemotherapy-induced intestinal oxidative stress: underlying causes of disturbed mucosal water and electrolyte transport. *Pathophys.*24(4):275-79
- Gupta SG, Hevia D, Patchva S, Park B, Koh W & Aggarwal BB.(2012) Upsides and Downsides of Reactive Oxygen Species for Cancer: the Roles of Reactive Oxygen Species in Tumorigenesis, Prevention, and Therapy. *Antioxid Redox Signal.*16 (11):1295-322.
- Al-Refai AS, Fawzi L & Khalil AK (2014): Effects of Kurdistan Honey on the Tongue of Chemotherapy Treated Albino Rats (Immunohistochemical Study). *J Cytol Histol* 5: 272.
- Kuduban O, Mazlumoglu MR, Kuduban SD, Erhan E, Cetin N, Kukula O, Yarali O, Cimen FK & Cankaya M (2016): The effect of hippophae rhamnoides extract on oral mucositis induced in rats with methotrexate. *J Appl Oral Sci*; 24(5):423-30.
- Heidari R, Khosravian P, Mirzaei S A & Elahian F (2021): siRNA Delivery Using Intelligent Chitosan-Capped Mesoporous Silica Nanoparticles for Overcoming Multidrug Resistance in Malignant Carcinoma Cells. *Sci Rep.* 11(1):205-31.
- Zhu X, Yu Z, Feng L, Deng L, Fang Z, Liu Z, Li Y, Wu X, Qin L, Guo R & Zheng Y (2021): Chitosan-based nanoparticle co-delivery of docetaxel and curcumin ameliorates anti-tumor chemoimmunotherapy in lung cancer. *Carbohydr Polym* 268: 118-237.
- Zivarpour P, Hallajzadeh J, Asemi Z, Sadoughi F & Sharifi M(2021): Chitosan as possible inhibitory agents and delivery systems in leukemia. *Cancer Cell Int.* 21(1):544.

19. Bilginaylar K, Aykac A, Sayiner S, Özkayalar H & Şehirli AÖ. (2022): Evaluation of the antiapoptotic and anti-inflammatory properties of chitosan in methotrexate-induced oral mucositis in rats. *Mol Biol Rep*; 49(4):3237-45
20. Jhundoo HD, Siefen T, Liang A, Schmidt C, Lokhnauth J, Béduneau A, Pellequer Y, Larsen CC & Lamprecht A (2020): Anti-Inflammatory Activity of Chitosan and 5-Amino Salicylic Acid Combinations in Experimental Colitis. *Pharmaceutics*; 12(11):1038.
21. Ding J & Guo Y (2022): Recent Advances in Chitosan and its Derivatives in Cancer Treatment. *Front Pharmacol* 13:888740.
22. Kadry M O, Abdel-Megeed R M, El-Meliegy E & Abdel-Hamid A Z (2018): Crosstalk between GSK-3, C-Fos, NFκB and TNF-α Signaling Pathway Play an Ambitious Role in Chitosan Nanoparticles Cancer Therapy. *Toxicol Rep* 5: 723–27.
23. Amirani E, Hallajzadeh J, Asemi Z, Mansournia M A & Yousefi B (2020): Effects of Chitosan and Oligochitosans on the Phosphatidylinositol 3-KinaseAKT Pathway in Cancer Therapy. *Int J Biol Macromol.* 164: 456–67.

الملخص العربي

تقييم التأثير الوقائي المحتمل للشيتوزان ضد تلف اللسان الناجم عن الإرينوتيكان في ذكور الجرذان البيضاء البالغة (دراسة بالميكروسكوب الضوئي والالكتروني الماسح)

سلوى محمد عويس^١، احمد طلعت جلال^٢، امل اشرف محمد^١، نهى عبد المجيد رجب^١

قسم التشريخ البشري وعلم الأجنة، كلية الطب، جامعة سوهاج،^٢ جامعة اسيوط

المقدمة: دواء ارينتوكان هو دواء سام للخلايا حصل على الموافقة المبدئية لعلاج السرطان في اليابان منذ ٢٥ عامًا وقدم العقار مساهمة كبيرة في علاج الأورام الصلبة في جميع أنحاء العالم لأكثر من ٢٠ عامًا وهو مشتق شبه اصطناعي من كامبتوتيسين. الشيتوزان، ثاني أكثر عديد السكاريد الطبيعي انتشارًا، متوافق حيويًا للغاية ويظهر تأثيرًا مهمًا مضادًا للسرطان، الشيتوزان هو بوليمر مستخدم على نطاق واسع في علم الأدوية، لا سيما في علاج الأورام بسبب قدرته على التحلل البيولوجي، والتوافق الحيوي، والتوزيع الحيوي، وعدم السمية، ونقص المناعة

الهدف من البحث: تقييم الآثار الوقائية المحتملة للشيتوزان على تلف اللسان الناجم عن مادة الأرينوتيكان

المواد والطرق: أجريت التجربة في بيت الحيوان التابع لكلية الطب بسوهاج (مارس ٢٠٢٣). تم تقسيم ثلاثين ذكور من الجرذان البالغين إلى ثلاث مجموعات (١٠ جرد / مجموعة): (١) مجموعة ضابطة. (٢) المجموعة المعالجة بـ ارينتوكان لمدة ٤ أيام. (٣) المجموعة المعالجة بالإرينوتيكان والشيتوزان لمدة ٤ أيام. تم أخذ الثلثين الأماميين من الألسنة وتحضيرها للدراسة المجهرية بالميكروسكوب الضوئي والالكتروني الماسح

النتائج: أنتج الأرينوتيكان العديد من التغيرات النسيجية الواضحة في أنسجة اللسان والتي تم وصفها بالحليمات الخيطية الضامرة وفقدان اتجاهها المنتظم، شكل غير طبيعي للحليمات الفطرية مع تدمير خلاياها الظهارية، وشوهت العديد من الخلايا الالتهابية في الصفيحة المخصصة وبين العضلات

كان هناك انخفاض واضح في كل من الطول والعرض في حليمات اللسان في المجموعة الثانية مقارنة بالمجموعة الضابطة واطهرت النتائج تحسن في هذه التغييرات في المجموعة الثالثة بعد إضافة الشيتوزان.

الخلاصة: خفف الشيتوزان التغيرات النسيجية في أسنة الفئران الناتجة عن العلاج بالأيرينوتيكان