

## Royal Jelly Enhances Spermatogenesis and Reduces Apoptosis in Diabetic Rat Testes: Histological and Immunohistochemical Study

Eman A. El Helew, Wafaa S. Hamed, Amal M. Moustafa and Zeinab A. Sakkara

Department of Histology and Cell Biology, Faculty of Medicine, Mansoura University, Egypt

### ABSTRACT

**Introduction:** Diabetes mellitus (DM) is a common endocrine illness. It has a detrimental effect on many organs including male reproductive system. Royal Jelly (RJ) has many health promoting properties such as antioxidant and antidiabetic effect.

**Aim of the Work:** The current study was conducted to study the possible ameliorative effect of RJ on the histological and immunohistochemical changes in testicular tissue induced by type I DM.

**Materials and Methods:** 30 adult male albino rats were used and classified into 3 groups. Group I (control group), Group 2 (diabetic group) that was injected intraperitoneally with single dose of streptozotocin (STZ) (40 mg/kg) and Group III (RJ treated diabetic group) that was injected with STZ as Group II and after confirmation of diabetes received royal jelly at dose of (100 mg/kg/ day) for a period of 4 weeks. For histological and immunohistochemical staining for caspase-3 and Ki-67, testicular specimens were prepared.

**Results:** The widely spaced, irregular seminiferous tubules in group II (diabetic rats) testicles were clearly involved, and their luminal spermatozoa were absent. The lining epithelium height was also significantly reduced. There were numerous vacuoles replacing spermatogenic cell layers. Congested blood vessels in interstitial tissue and Leydig cells with dark stained nuclei were noticed. The KI-67 immuno-expression was significantly reduced, while the area percent of caspase3 immuno-expression was significantly increased. The testes from group III (the diabetic group receiving RJ treatment) displayed a significantly better histological picture with the preservation of germinal epithelium in the majority of seminiferous tubules. The KI-67 immuno-expression was increased significantly while the area percent of caspase3 immuno-expression was reduced significantly.

**Conclusion:** RJ ameliorated the testicular damaging effect of type I DM on testis through reduction of apoptosis and preserving spermatogenesis.

**Received:** 12 September 2023, **Accepted:** 08 October 2023

**Key Words:** Apoptosis; caspase 3; diabetes mellitus; Ki 67; spermatogenesis.

**Corresponding Author:** Eman A. El Helew, PhD, Department of Histology and Cell Biology, Faculty of Medicine, Mansoura University, Egypt, **Tel.:** +2 0504494928, **E-mail:** emanhelew@gmail.com

**ISSN:** 1110-0559, Vol. 47, No. 4

### INTRODUCTION

One of the most common metabolic disorders is Diabetes Mellitus (DM). Several clinical studies showed that DM causes some complications in different organs including male genital system, such as sexual dysfunction and infertility<sup>[1]</sup>. Hyperglycemia associating DM is accompanied with increase in oxidative stress causing many complications in different tissues. It was found that free radicals generation, peroxidation of membrane lipid and protein oxidation are increased in diabetic patients and diabetic animals<sup>[2]</sup>.

In normal physiological process of the testes there is amount of produced reactive oxygen species (ROS). Male infertility is associated with an excess of ROS, which can harm sperm. Because of the high concentration of unsaturated fatty acids in their plasma membranes, spermatozoa are extremely vulnerable to oxidative damage<sup>[3,4]</sup>.

The worker honey bees' hypopharyngeal and mandibular glands secrete royal jelly (RJ). It is only food for the queen bee and the honeybee larvae in their

first 2-3 days of maturation and it plays a major role in caste differentiation<sup>[5]</sup>. Royal jelly is a thick, milky white, gelatinous, acidic colloid, with considerable amounts of water, sugar, protein, and fat, with different amounts of vitamins, minerals, poly phenols, and many trace elements important to RJ documented nutritional and therapeutic properties. The 10-carbon fatty acids trans-10-hydroxy-2-decenoic acid (10-HDA), which are only present in royal jelly and have antioxidant properties, make up the majority of the lipid content<sup>[6-8]</sup>.

Royal jelly has many therapeutic effects as antioxidant, anti-inflammatory, antimicrobial, and anticancer activities. Royal jelly is an effective antioxidant supplement used in many clinical trials. Therefore, it can be used in pharmaceutical products to decrease or prevent lipid oxidation and retard the formation of toxic products<sup>[6, 9-11]</sup>.

Therefore, the current research was conducted to investigate any potential protective effects of RJ on type I DM-induced histological and immunohistochemical changes in the testis of adult albino rats.

## MATERIAL AND METHODS

### Chemicals

#### a) Drugs

- Streptozotocin (Sigma Company, St. Louis, MO, USA.), It was dissolved in normal saline and given by intraperitoneal (IP) injection
- Royal jelly (MARTINEZ NIET O.S.A – CATAGENA SPAIN), Available in the form of soft gelatin capsules. It was given orally by intragastric tube.

#### b) Kits

- Anti-caspase-3 polyclonal antibody (Catalogue number: GB11532, Servicebio, China, at 1/500 dilution).
- Anti-Ki-67 polyclonal antibody (catalogue number: GTX16667, GeneTex Inc., California, USA).

### Animals

To ensure normal growth and behavior, 30 adult male albino rats (10-12 weeks old) weighing around 250g were housed in plastic cages with adequate ventilation and temperature, fed a standard rodent pellet diet, and had free access to water for two weeks prior to the experiment. The Medical Histology and Cell Biology Department of Mansoura University carried out the current experiment in accordance with international guidelines for the care and management of laboratory animals. The Mansoura University Institution Research Board gave their approval with code (MD.16.03.01).

The three groups of rats were as follows:

**Control group (Group I):** involved 10 rats that were intraperitoneally injected with single dose of normal saline only.

**Diabetic group (Group II):** included 10 rats that had received a single dose of 50 mg/kg of streptozotocin by intraperitoneal injection to induce type I DM<sup>[12]</sup>. Following STZ injection by 72 hours, blood samples were collected from tail veins and serum glucose levels were estimated with a glucometer (Elegance, Model: no: CT-X10 Germany). Rats with blood glucose levels greater than 250 mg/dl were confirmed to be diabetic and not given any medication for a period of four weeks.

**RJ treated diabetic group (Group III):** included 10 rats that were injected with STZ as Group II and after confirmation of diabetes received royal jelly orally at dose of 100 mg/kg body weight per day for a period of 4 weeks<sup>[13]</sup>.

Six diabetic animals died during this study, and their places were filled by other diabetic animals still alive. Finally, 30 rats were involved in this research

### Sampling and tissue processing

By the termination of the 4 weeks which is the duration of experiment, the rats of all groups were anaesthetized by intraperitoneal sodium pentobarbital (40 mg/kg) injection<sup>[14]</sup>. The testis, from each animal, were dissected out and fixed then processed to obtain paraffin sections for the light microscopic study.

### Histological examination

Testicular specimens were obtained and immediately fixed in bouin's fixative and manipulated with gradual dehydration, then clearing in xylol solution, followed by embedding in paraffin. Sections were obtained at 5–6 um thickness by microtome. Testicular sections were processed for staining by routine histological examination using hematoxylin and eosin (H&E) staining<sup>[15]</sup>, and the demonstration of carbohydrates using periodic acid Schiff (PAS) stain<sup>[16]</sup>.

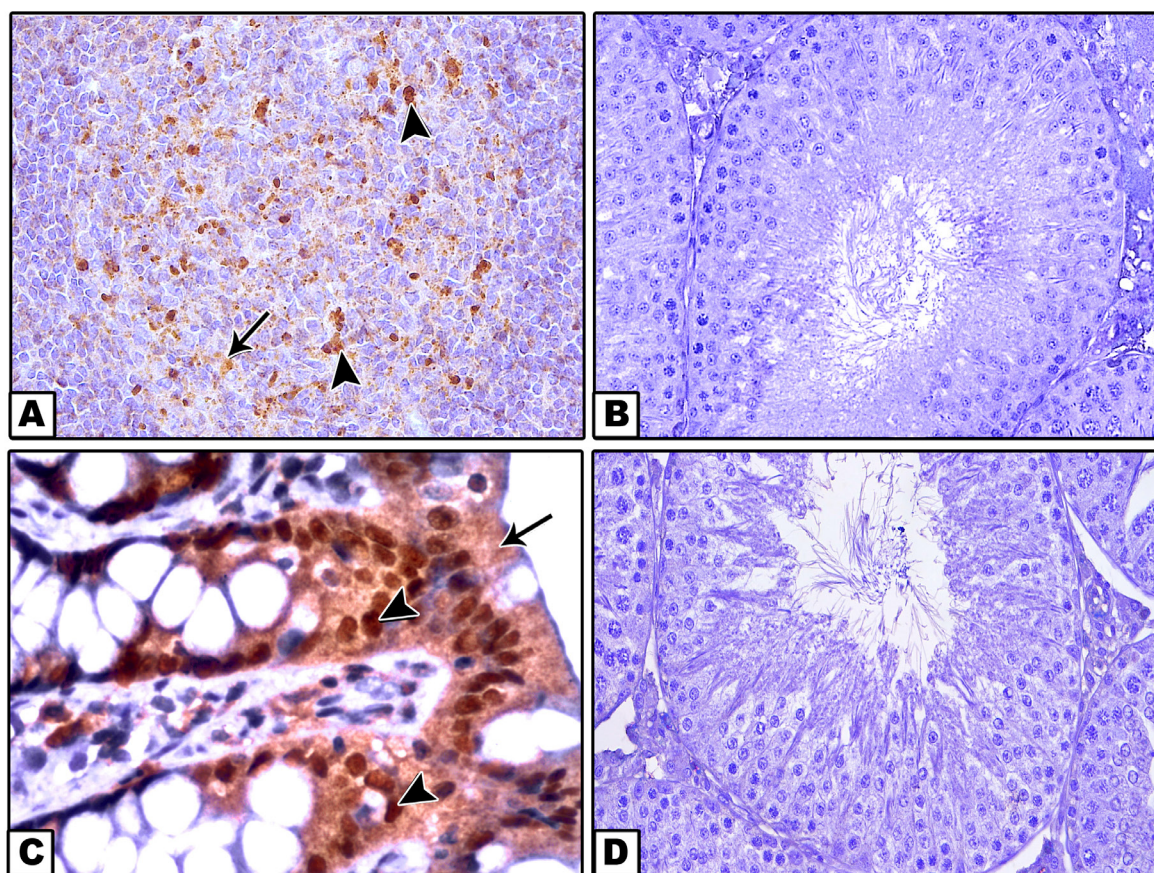
### Immunohistochemical (IHC) technique<sup>[17]</sup>

Caspase-3 antibody for detection of apoptosis and Ki-67 antibody for assessment of cell proliferation.

Deparaffinized and rehydrated testicular specimens were used. Sections were then microwaved for 15 minutes to retrieve antigen. Following a 20 minute blocking procedure, sections were incubated for 120 minutes at room temperature with the primary monoclonal antibody for KI-67 and the primary polyclonal antibody for caspase-3. Secondary antibody was then added and left on for 30 minutes. 15 minutes later, one to two drops of DAB (diaminobenzidine) were added. Finally, Mayer's hematoxylin s was used to counterstain the sections<sup>[13]</sup>.

As negative controls, some testicular slides were only stained with IgG secondary antibody. Positive controls for caspase-3 and Ki-67 were provided by tonsil<sup>[18]</sup> and colon slides<sup>[19]</sup>, respectively (photo, 1).





**Photo 1:** photomicrographs for immuno-histochemical positive and negative control tissues. (A) tonsil that served as caspase3 immuno- positive control tissue revealing positive brown reaction in the nuclei (arrow heads) and cytoplasm (arrow). (B) testis of control animal which served as caspase3 immuno- negative control tissue revealing negative caspase 3 immune reaction in all cells. (C) colon of control rat that served as Ki-67 immuno- positive control tissue revealing positive brown reaction in the nuclei (arrow head) and cytoplasm (arrow)of the intestinal surface epithelium. (D) a control rat testis that served as Ki-67 immuno- negative control tissue revealing negative Ki-67 immune reaction. (A & B Caspase 3 x400, C & D Ki-67 x400)

### Morphometric study

Slides were captured with an Olympus E420 digital camera from China mounted on an Olympus microscope with a  $0.5 \times$  photo adaptor and a  $40 \times$  objective lens (TX31 Philippines). Analysis of images were done by using a computer running ImageJ 1.52 a program (National Institutes of Health, United States) for assessment of corrected distances and percentages. Five slides from different animals in each group were used for morphometric study. Ten non-overlapping fields, in each slide from caspase 3 and Ki-67 immuno stained sections were used to measure their optical density. Area percent of caspase3 immunoprecipitation and number of Ki-67 immuno-positive cells per high power field were estimated.

### Statistic evaluation

The Statistical Package for Social Science version 22.0 (SPSS Inc., Chicago, USA) program was used to tabulate, code, and analyze the results. The ANOVA test and post-hoc Tukey test were then used to compare the results. All groups' data were presented as mean and standard deviation (SD). Differences were considered significant when the *P* (probability) value was 0.05 or lower and highly significant when the *P* value was 0.001 or higher<sup>[20]</sup>.

## RESULTS

### H&E results

Control group (group I): Showed that testis was surrounded by tunica albuginea which is formed of connective tissue fibers and fibroblasts. The tunica vasculosa was located inner to tunica albuginea and containing blood vessels. The testicular tissue revealed seminiferous tubules (STs) separated with interstitial tissue which contains blood vessels in addition to Leydig cells. The cross sections of STs were oval or rounded in shape with mature spermatozoa filling their lumina. They were lined by both spermatogenic together with Sertoli cells (Figure 1A).

The seminiferous tubules were bounded by basal lamina and myoid cells which have flattened dark nuclei. They were lined with Sertoli cells and germinal epithelium consisting of: spermatogonia, primary spermatocytes, rounded or elongated spermatids and spermatozoa. Sertoli cells were found close to basal lamina having oval pale nuclei (Figure 2A).

Diabetic group (group II): The seminiferous tubules had irregular outline with absence of spermatozoa in their lumen. There was marked reduction of the

spermatogenic cell layers. Many vacuoles appeared among the spermatogenic cells (Figure 1B). The tubules had irregular thick basement membrane and were lined mainly by degenerated Sertoli cells with loss of most of germinal epithelium layers, which were replaced by homogenous acidophilic material and vacuoles and their lumina are free from spermatozoa. Multinucleated giant cells could be seen within the seminiferous tubule. (Figure 2B). Some spermatogenic cells were exfoliated in the lumen and some of them appeared with dark stained nucleus and acidophilic cytoplasm. Blood vessels in the interstitium appeared congested with hemorrhage in the widened interstitial spaces and nuclei of Leydig cells were condensed. (Figures 2 B,C).

RJ treated diabetic group (group III): This group revealed that the tunica albuginea was thinner than that found in group II (diabetic rats). The majority of the STs showed marked preservation of their lining cells with complete germinal epithelial layers and mature spermatozoa (Figure 1C). Sertoli cells appeared nearly normal with pale oval nuclei located near the basal lamina (Figure 2d). However, few tubules showed degenerated cells and vacuoles. Interstitial spaces showed blood vessels and most of Leydig cells revealed vesicular open face nuclei with and pale cytoplasm except occasional ones that revealed dark stained nuclei (Figures 1 C, 2 d).

#### **PAS stain results**

**Group I (control group):** Sections stained with PAS stain revealed PAS +ve reaction in the basement membrane, acrosomal vesicles in both types of spermatids. Positive reaction was also noticed in the wall of blood vessels (Figure 3A).

**Group II (Streptozotocin treated group):** In comparison to the control group, PAS stain showed an increased PAS +ve reaction in the thickened basement membrane and the wall of blood vessels. Reaction of PAS in acrosomal vesicles of spermatids were invisible. Moreover, PAS +ve fluid between seminiferous tubules was detected (Figure 3B).

**Group III (Royal jelly treated group):** Similar to the control group, PAS +ve reaction was observed in the basement membrane, spermatid acrosomal vesicles, and blood vessel wall (Figure 3C).

#### **Immunohistochemical results**

##### **Caspase-3 immune reaction**

Control group (group I): Testicular sections from the

control group testes stained for Caspase-3 revealed no immunoreactions in the Leydig cells or spermatogenic cells (Figure 4A).

Diabetic group (group II): In this group, positive nuclear and cytoplasmic immune reactions for Caspase-3 were observed in spermatogenic cells. Positive cytoplasmic immune reactions were also detected in Leydig cells (Figure 4B).

RJ treated diabetic group (group III): In this group, positive nuclear and cytoplasmic immune reactions for Caspase-3 were observed in spermatogenic cells and Leydig cells (Figure 4C).

##### **Ki-67 immune reaction**

Control group (group I): Sections of testis of this group showed positive nuclear immune-reaction for ki-67 in most of spermatogonia and primary spermatocytes within seminiferous tubules and some Leydig cells (Figure 5A).

Diabetic group (group II): Sections of testis in this group showed a negative immune-reaction for ki-67 in seminiferous tubules and Leydig cells (Figure 5B).

RJ treated diabetic group (group III): In this group, positive nuclear Ki-67 immune-reactions were observed in some spermatogonia, primary spermatocytes and Leydig cells (Figure 5C).

#### **Statistical analysis of Morphometric results**

##### **The area percent of caspase-3 immuno- reaction**

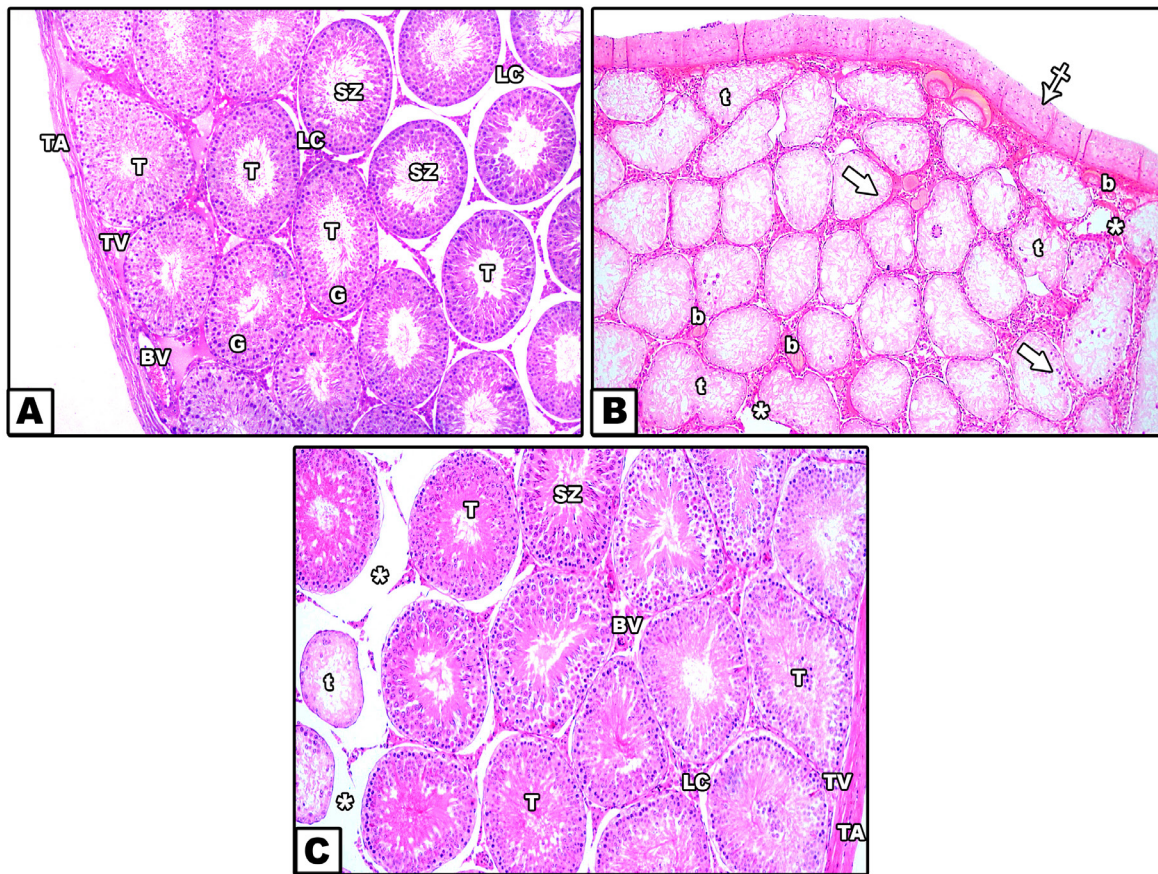
According to (Table 1): Area percent of caspase-3 immuno-reaction revealed a highly significant rise ( $P<0.001$ ) in group II versus group I. However, area percent of caspase-3 immuno-positive cells in group III revealed a nonsignificant increase ( $P=0.059$ ) in relation to group I and significant reduction ( $P<0.001$ ) in relation to group II.

##### **The number of Ki67 immuno-positive cells (proliferative cells) per high power field (HPF)**

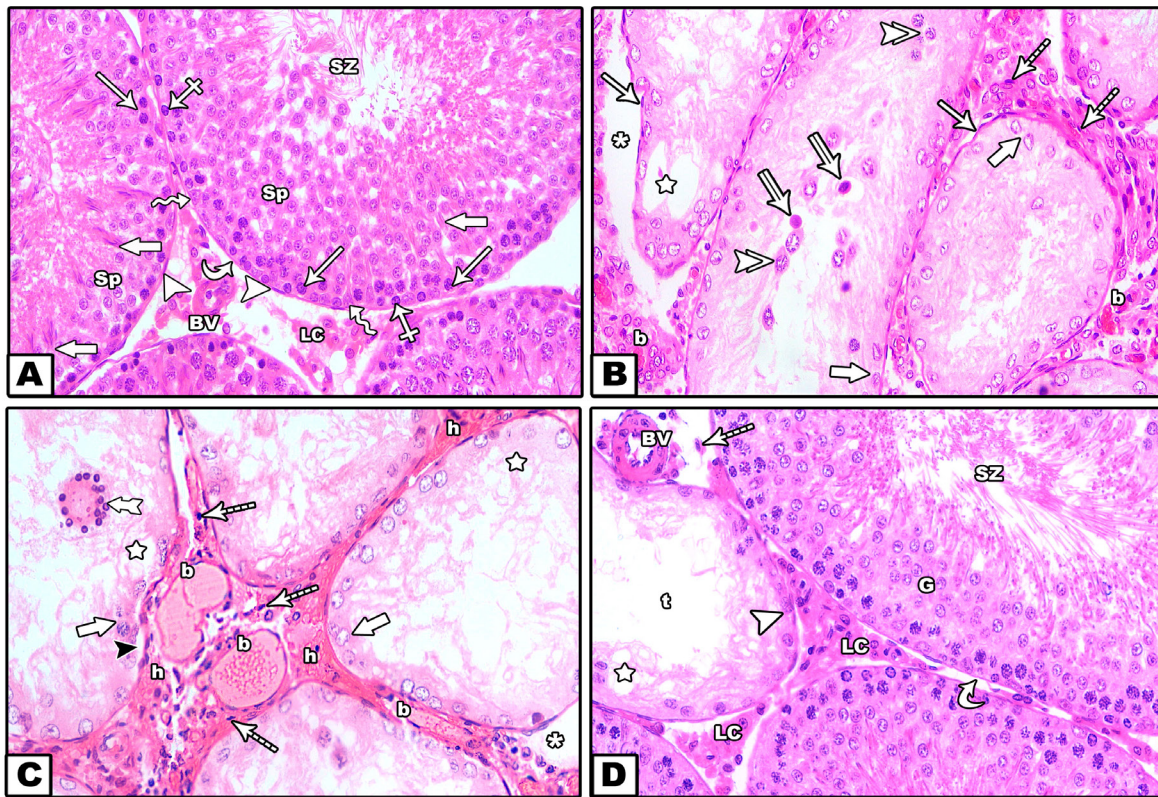
According to (Table 2) When compared to group I, group II had a significantly lower mean number of Ki67 immuno-positive cells /HPF.

Rats in group III showed a significant increase ( $P<0.001$ ) compared to group II but a nonsignificant decrease ( $P=0.117$ ) in the mean number of Ki67 immuno-positive cells /HPF.



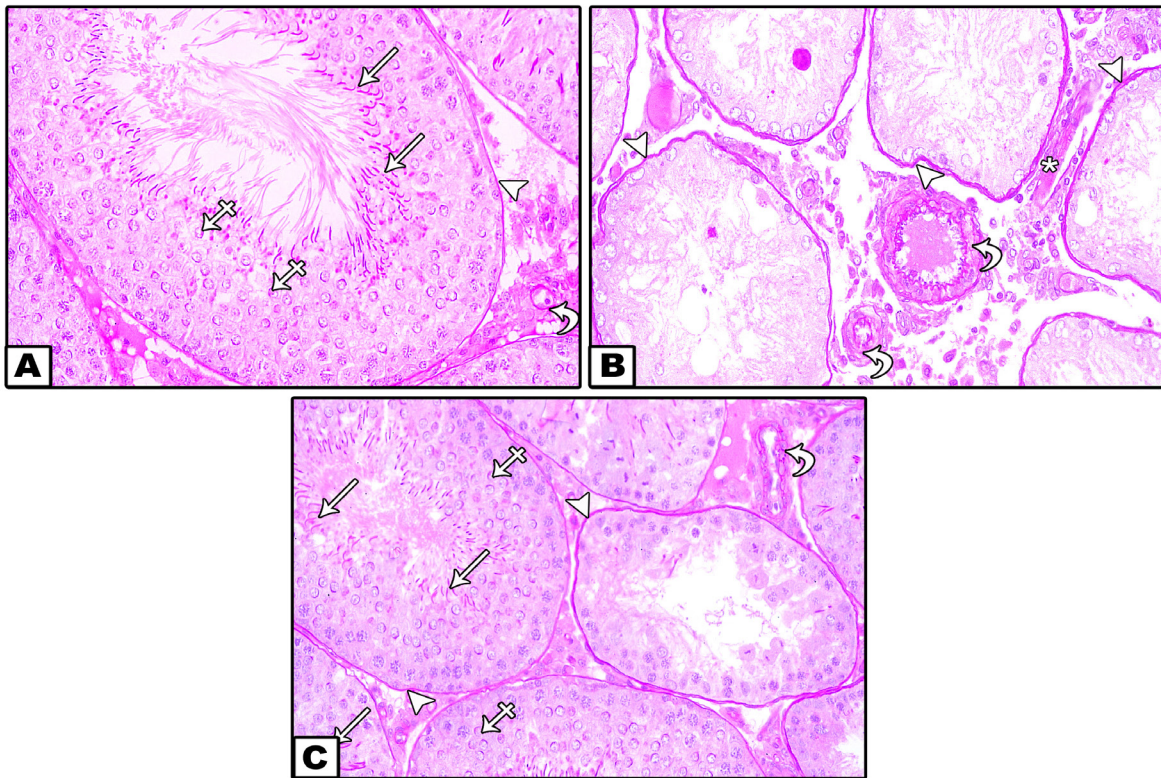


**Fig. 1:** photomicrographs for testicular sections from (A): control group showing the tunica albuginea (TA) and inner to it is the Tunica vasculosa (TV) containing blood vessels (BV). Seminiferous tubules(T) are lined by series of spermatogenic cells(G) and mature sperms are seen in their lumen (SZ). The tubules are separated by connective tissue which contains Leydig cells (LC). (B): Diabetic rats showing thick tunica albuginea (crossed arrow) and tunica vasculosa containing thickened congested blood vessels (b). STs have irregular shapes (t) and show complete degeneration of stratified germinal epithelium (thick arrow) and tubular lumina are free from spermatozoa. Wide interstitial tissue spaces are seen (\*). (c): Royal jelly treated rats showing the tunica albuginea (TA) and tunica vasculosa (TV), preservation of germinal epithelium with mature spermatozoa detected in lumen of most tubules (T). Few tubules reveal degenerated germinal epithelium with absence of mature spermatozoa in the lumen (t). interstitial tissue containing Leydig cells (LC) and blood vessels (BV) is widened at some areas (\*). (H & E x100).

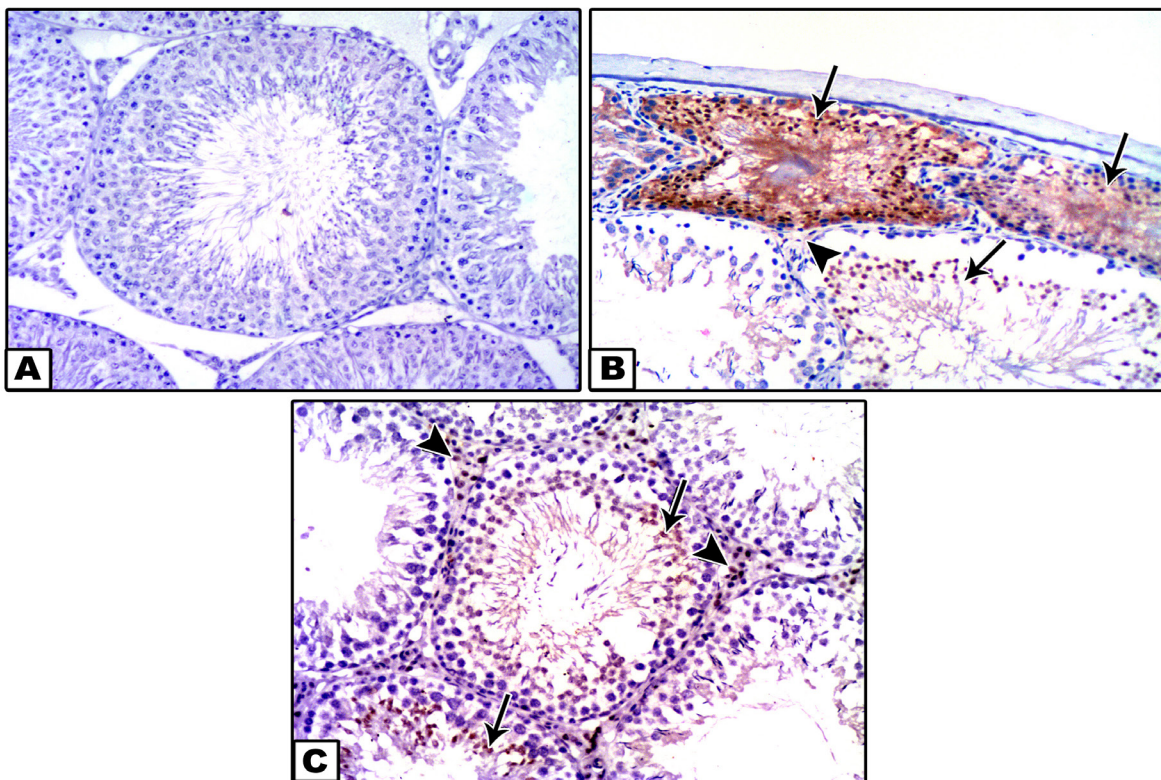


**Fig. 2:** photomicrographs for testicular sections from (A): control group revealing basement membrane (curved arrow) and myoid cells with flat dark nuclei (arrow heads) surrounding STs. The tubules are lined by Sertoli cells (zigzag arrow) and stratified germinal epithelium including; spermatogonia (crossed arrow), primary spermatocytes (arrow), round spermatids (SP), elongated spermatids (thick arrow) and mature spermatozoa are seen in their lumina (SZ). Leydig cells (LC) and blood vessels (BV) are seen in the interstitial tissue. (B): diabetic group: Seminiferous tubules with irregular basement membrane (arrow) and lined mainly by degenerating Sertoli cells (thick arrow), desquamated cells with fragmented nuclei (double arrow heads), degenerated cells having dark stained nuclei and deep acidophilic cytoplasm (double arrows) and vacuoles (star). Wide interstitial spaces (\*) with darkly Leydig cell nuclei (segmented arrow) and congested blood vessels (b). (c) diabetic group: Seminiferous tubules show separation of cells from basement membrane (black arrow head) with homogenous acidophilic material and large vacuoles (stars) replacing the spermatogenic cells and lined mainly by Sertoli cells (thick arrow). large multinucleated giant cell was seen (tailed arrow). Wide interstitial spaces (\*) with darkly stained Leydig cell nuclei (segmented arrow) and congested blood vessels (b) and some areas of hemorrhage (h). (D): RJ treated group: STs appear with close similarity to those of control group with intact germinal epithelial layers (G) and considerable amounts of mature spermatozoa (SZ) present in their lumina. Other tubule (t) shows degenerated vacuolated cells (star) and lined only with Sertoli cells (arrow head). The interstitial tissue containing blood vessel (BV) and majority of Leydig cells show open face nuclei (LC) and some of them appears with the darkly stained nuclei (segmented arrow). (H&E stain x 400)



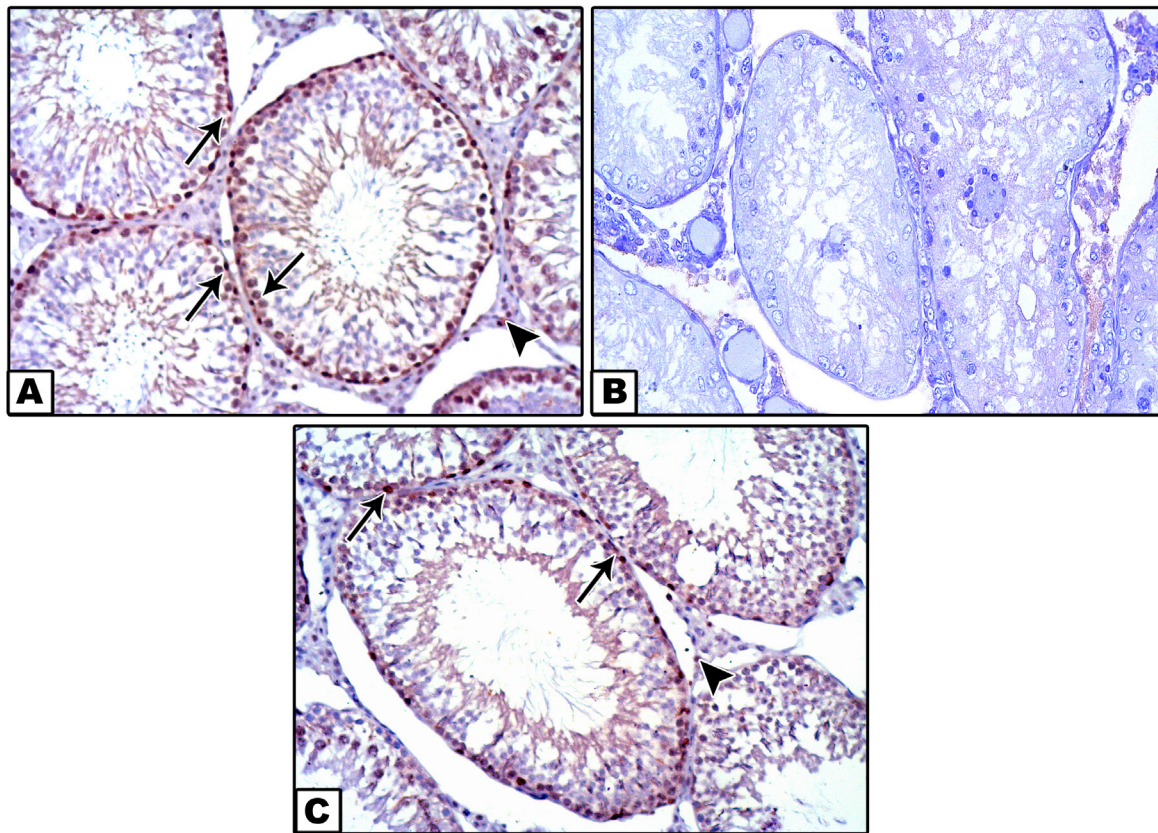


**Fig. 3:** (A) group 1 (control rats) revealing PAS +ve reaction in basal lamina surrounding seminiferous tubule (arrow heads), in acrosome of rounded (crossed arrows) and in late spermatids (arrows). PAS +ve reaction in the blood vessel wall was observed (curved arrow). (B): group2 (diabetic rats) revealing increased PAS +ve reaction in the thickened irregular basal lamina (arrow heads) and in the blood vessel wall (curved arrow) and it is also noticed between the seminiferous tubules (\*). (C): group 3 (Royal jelly treated rats) showing +ve reaction for PAS in basal lamina (arrowheads) and in the blood vessel wall (curved arrow). in acrosome of rounded (crossed arrows) and in elongated spermatids (arrows). (PAS stain, X400)



**Fig. 4:** photomicrograph of caspase-3stained sections of testis of all groups. (A): control group showing a negative immune-reaction for caspase-3 in STs and Leydig cells. (B): diabetic group showing +ve cytoplasmic and nuclear immune-reactions for caspase-3 in all spermatogenic cells (arrows) and +ve cytoplasmic reaction in Leydig cells (arrow head). (C): RJ treated diabetic group showing +ve nuclear immune-reaction for caspase-3 in the inner spermatogenic cells lining STs mainly spermatids and +ve nuclear reaction in Leydig cells (arrow head). (IHC for Caspase-3 x400)





**Fig. 5:** photomicrograph of Ki-67stained testicular sections of all groups. (A): control group showing a positive nuclear immune-reaction for ki-67 in the outer spermatogenic cells mainly spermatogonia and primary spermatocytes (arrows) and Leydig cells (arrow heads). (B): diabetic group showing negative immune-reactions for ki-67 in spermatogenic cells and interstitial cells of Leydig. (C): RJ treated diabetic group showing positive nuclear immune-reaction for ki-67 in early spermatogenic cells (arrows) and in Leydig cells (arrow head). (IHC for Ki-67 x400)

**Table 1:** The percentage area of caspase3 immuno-reaction in the study groups

Groups	Group I (Control)	Group II (diabetic)	Group III (Royal jelly)	Test of significance
The percentage area of caspase-3 immuno-reaction (%)				
Mean ± SD	3.37 ± 0.76	18.53 ± 1.36	4.67 ± 1.39	F= 486.024
Median (Range)	3.7 (2.1-4.2)	18.45 (14.9-18.4)	4.39 (3.2-7.6)	P < 0.001*
P1		< 0.001**	0.059	
P2			< 0.001*	

F: one way ANOVA test, P: general intergroup significance, P1: Significance compared to control group, P2: Significance compared to diabetic group.

**Table 2:** The number of Ki67 immuno-positive cells in the study groups

Groups	Group I (Control)	Group II (Diabetic)	Group III (Royal jelly)	Test of significance
The percentage area of Ki67 immuno-positive				
Mean ± SD	86.90 ± 4.01	3.2 ± 3.35	81.90 ± 7.80	KW= 20.487
Median (Range)	85 (83-94)	2 (0-10)	83 (72-95)	P < 0.001*
P1		< 0.001**	0.117	
P2			< 0.001*	

KW: Kruskal Wallis test, P: general intergroup significance, P1: Significance compared to Control group, P2: Significance in compared to Diabetic group



## DISCUSSION

Diabetes mellitus is a widespread health problem that has close association to oxidative stress causing many complications in different tissues. One of them is the testis thus affecting male fertility. Hyperglycemia is accompanied with elevation in oxidative stress. It was proved that there is increase in production of free oxygen radicals, peroxidation of membrane lipid and oxidation of protein in diabetic patients and diabetic animals<sup>[1,10]</sup>.

The cell membrane of spermatozoa is known to have a high amount of unsaturated fatty acids. Therefore, it is highly vulnerable to peroxidative damage. The lipid peroxidation affecting the lipid content of sperm membranes causes severe disturbance in sperm motility<sup>[21]</sup>.

RJ is a honey bee product that has an effective antioxidant due to metal chelating activities and scavenging of free radical and hydrogen peroxide. So, it can be used to decrease or prevent lipid oxidation and retard the formation of toxic products<sup>[9]</sup>.

This research revealed marked structural changes in testis of diabetic group that revealed severe damage to STs with degeneration of their lining spermatogenic cells and marked reduction in germinal epithelium with no spermatozoa seen in their lumina. Leydig cells were also affected with degenerative changes. These findings were in harmony with other studies for diabetic effect on rat testis<sup>[1,22,23]</sup>.

Testicular sections stained with H&E in diabetic rats revealed congestion of the blood vessels in the interstitium, which is in line with Kumar, *et al* (2023) who found that DM induces congestion in blood vessels in various organs like kidney, liver and brain<sup>[24-26]</sup>.

Some researchers reported that congestion induced by DM might be due to vasculopathy caused by hyperglycemia which leads to production of NO from the affected endothelium which is an endothelial relaxing factor together with various inflammatory cytokines that result in increasing vascular permeability with subsequent influx of various cytokines<sup>[22,27-30]</sup>.

Seminiferous tubules in this group had irregular basement membranes, sloughed degenerated cells and intraluminal homogenous acidophilic material and vacuoles. Multinucleated giant cells were also seen. Marked reduction in germinal epithelial cells and the presence of Sertoli cells only in seminiferous tubules with absence of spermatozoa. Widened interstitial spaces and Leydig cells with dark stained nuclei were also noticed. These results were consistent with the results obtained by other authors<sup>[23,31-33]</sup>.

Basement membrane corrugation observed in the current could be related to DM induced oxidative stress which affects myoid cells and causes loosening of the tight interaction between them, also it might be due to decreased tubular diameter<sup>[34,35]</sup>.

The homogenous acidophilic material present in some seminiferous tubules could be caused by oxidative stress. Also, this finding might result from hyalinization of the sloughed degenerated germ cells due to disturbed Sertoli cell phagocytic function. This finding comes in harmony with Nasiri, *et al* (2021)<sup>[36]</sup>.

The germ cell shedding observed in our work could be explained by disruption in the cell junctions between Sertoli and germ cells or it might be due to damage in cytoskeletal fibers of Sertoli cell leading to lost cell adhesion. These findings corroborated earlier research by Sayed, *et al* (2023)<sup>[23]</sup>.

In the current study some multinucleated giant cells were observed. These cells may be a sign of an ongoing degenerative process in the seminiferous tubules. These giant cells were suggested to be one of the evident features of testicular cell degeneration and atrophy. It resulted from failure of separation of spermatids due to damage in the intercellular bridges and impaired cytokinesis, or it could be a result of increased activity of phagocytosis in apoptotic spermatogenic cells<sup>[24,37,38]</sup>.

It was noted that the sperms and spermatids were rarely seen. This might be explained by the ROS production which are known to be cytotoxic and often cause tissue injuries<sup>[39]</sup>.

Wide interstitial spaces were observed in our study and this finding was in line with Anuar, *et al* (2023)<sup>[40]</sup> who accounted the excess interstitial spaces could be also explained by the presence of acidophilic homogenous material in the interstitium. This material might be formed as a result of excess lymphatic exudate oozing from degenerated lymphatic vessels as well as increase in vascular permeability that may result from accumulation of ROS and free radicals and this comes in harmony with several previous studies<sup>[39,41,42]</sup>.

The pathological alterations in testicular tissue induced by DM might be due to hyperglycemic effect of DM which causes lipid peroxidation, decreases the antioxidant enzyme activities as catalase (CAT), glutathione peroxidase (GPx) and sodium dismutase (SOD) indicating oxidative stress. It also increases the testicular levels of nitric oxide (NO), which facilitate damage of testicular tissue<sup>[43,44]</sup>.

Testicular sections stained with H&E in RJ treated diabetic group revealed restoration of testicular architecture with similarity to the control group being covered with relatively thin tunica albuginea and closely located seminiferous tubules. Only a few Leydig cells were degenerated. Most seminiferous tubules of this group appeared with regular shape, surrounded by thin basal lamina and lined by intact germinal epithelial layers and their lumen containing mature spermatozoa. Occasional tubules were affected, with the presence of degenerated and vacuolated cells and decrease in germinal epithelial layers with no mature spermatozoa seen in their lumina. Our results were similar to previous studies done by Karaca,

*et al* (2015) who explained that by antioxidant activity of RJ due to metal chelating activities and scavenging of free radical and hydrogen peroxide. The H-atom donation from phenolic group is responsible for the antioxidant properties of RJ<sup>[7,10,24]</sup>.

Because the Schiff's reagent reacts with the polysaccharide component of acrosomes, PAS-stained sections of the control group showed positive PAS reaction in the acrosomes of spermatids and spermatozoa. Zayman, *et al.* (2022) also reported these findings<sup>[45,46]</sup>.

PAS-stained sections in the diabetic group showed excess reaction basement membranes due to an increase in collagenous fibers. Oxidative stress was suggested to be the cause of the observed thickening in basement membranes as ROS have been proved to induce conversion of fibroblasts into myofibroblasts with more synthetic activity and excess formation of collagen fibers<sup>[38]</sup>.

PAS stained sections of RJ treated diabetic group revealed positive reaction in the acrosomes of spermatids and spermatozoa with close similarity to control group and showed thinner basement membranes in relation to diabetic group, as RJ antioxidant activity improve myoid cell condition<sup>[47]</sup>.

Apoptosis is a physiological process controlling the number of cells in testicular tissue and eliminates abnormal reproductive cells during spermatogenesis. If apoptosis exceeds normal limits it leads to excessive loss of cells causing disturbance in testicular reproductive function<sup>[48]</sup>. Immunohistochemically, the current study demonstrated that DM induces Caspase-3 positive cytoplasmic and nuclear immune reactions in spermatogenic cells and Leydig cells, The rise in caspase-3 expression as a marker for apoptosis were in harmony with earlier research done by Sayed, *et al* (2023) who demonstrated that hyperglycemia associated with diabetes induce generation of reactive oxygen species and oxidative stress. ROS causes impairment of the mitochondrial membrane with liberation of cytochrome C form mitochondria to the cytoplasm leading to activation of caspase-3 expression<sup>[23]</sup>.

Statistically, marked significant rise in the percent area of apoptotic cells in the testes of diabetic rat relation to control group. RJ treated diabetic group were significantly decreased in relation to diabetic group. These results agreed with previous studies by Faddladdeen, *et al.* (2022) This improved result is an indicative for protective role of RJ which could be attributed to its antioxidant activity competing oxidative stress of DM<sup>[37,49]</sup>.

Cell proliferation is associated with expression of some proteins, one of these proteins is Ki67 protein. It is in the nucleus during interphase stage, but during mitosis most of Ki67 protein is found on the chromosomal surface. The Ki-67 marker could be used to assess cellular proliferation in active dividing cells such as testicular cells. It was found that there is a correlation between Ki-67 expression and proliferative rate of spermatogenic cells<sup>[37]</sup>. In the current

work, the Ki-67immuno- expression was evident in the spermatogonia and primary spermatocytes in testes of control group rats and RJ treated diabetic rats but it was significantly decreased in testicular sections of diabetic rats in relation to control group. Karaca *et al.* (2015) results were in harmony with that found in the our study who explained the restoration of proliferative activity to RJ antioxidant effect scavenging free radicles that served to decrease oxidative damage to cells with preservation of spermatogenesis<sup>[24]</sup>.

## CONCLUSION

This research indicates that royal jelly administration could ameliorate the damaging effect of type I diabetes mellitus on testis as it can reduce apoptosis and preserve spermatogenesis.

## RECOMMENDATIONS

Daily administration of royal jelly supplements may beneficial to prevent diabetic complications on testes and preserve fertility in diabetic male patients,

## CONFLICT OF INTERESTS

There are no conflicts of interest.

## REFERENCES

1. Shokri, F., M. Shokoohi, H.R. Niazkar, A.R.R. Abadi, H. Kalarestaghi, and M. Ahin, Investigation the spermatogenesis and testis structure in diabetic rats after treatment with galega officinalis extract. Crescent Journal of Medical and Biological Sciences, 2019. 6(1): p. 31-36.
2. Sampannang, A., S. Arun, J. Burawat, W. Sukhorum, and S. Iamsaard, Testicular histopathology and phosphorylated protein changes in mice with diabetes induced by multiple-low doses of streptozotocin: An experimental study. International Journal of Reproductive BioMedicine, 2018. 16(4): p. 235.
3. Budin, S.B., F.F. Jubaidi, S.N.F.M.N. Azam, N.L.M. Yusof, I.S. Taib, and J. Mohamed, Kelulut honey supplementation prevents sperm and testicular oxidative damage in streptozotocin-induced diabetic rats. Jurnal Teknologi, 2017. 79(3).
4. Eisa, C.S., S.S. Mohammed, H.I.A. El-Aziz, L.M. Farghaly, and S. Hosny, The Effect of Selenium Nanoparticles versus Royal Jelly against Cisplatin-Induced Testicular Toxicity in Adult Male Albino Rats: A Light and Transmission Electron Microscopic Study. J Microsc Ultrastruct, 2022. 10(4): p. 180-196.
5. Ahmad, S., M.G. Campos, F. Fratini, S.Z. Altaye, and J. Li, New insights into the biological and pharmaceutical properties of royal jelly. International Journal of Molecular Sciences, 2020. 21(2): p. 382.
6. Kontogiannis, T., T.G. Dimitriou, N.A. Didaras, and D. Mossialos, Antiviral Activity of Bee Products. Curr Pharm Des, 2022. 28(35): p. 2867-2878.



7. Nazar-Zadeh, M., C. Jalili, A. Nikgoftar Fathi, A. Ghanbari, and M. Bakhtiari, Royal-jelly-based apitherapy can attenuate damages to male reproductive parameter following nicotine administration. *Animal Model Exp Med*, 2022. 5(2): p. 133-140.
8. Almeer, R.S., D. Soliman, R.B. Kassab, G.I. AlBasher, S. Alarifi, S. Alkahtani, D. Ali, D. Metwally, and A.E. Abdel Moneim, Royal Jelly Abrogates Cadmium-Induced Oxidative Challenge in Mouse Testes: Involvement of the Nrf2 Pathway. *Int J Mol Sci*, 2018. 19(12).
9. Kunugi, H. and A. Mohammed Ali, Royal Jelly and Its Components Promote Healthy Aging and Longevity: From Animal Models to Humans. *Int J Mol Sci*, 2019. 20(19).
10. Ghanbari, E., V. Nejati, and M. Khazaei, Antioxidant and protective effects of Royal jelly on histopathological changes in testis of diabetic rats. *Int J Reprod Biomed*, 2016. 14(8): p. 519-26.
11. Amirshahi, T., G. Najafi, and V. Nejati, Protective effect of royal jelly on fertility and biochemical parameters in bleomycin-induced male rats. *Iran J Reprod Med*, 2014. 12(3): p. 209-16.
12. Ghasemi, A. and S. Jeddi, Streptozotocin as a tool for induction of rat models of diabetes: a practical guide. *Excli j*, 2023. 22: p. 274-294.
13. Hu, X., Z. Liu, Y. Lu, X. Chi, K. Han, H. Wang, Y. Wang, L. Ma, and B. Xu, Glucose metabolism enhancement by 10-hydroxy-2-decenoic acid via the PI3K/AKT signaling pathway in high-fat-diet/streptozotocin induced type 2 diabetic mice. *Food Funct*, 2022. 13(19): p. 9931-9946.
14. Abd El-Hay, R.I., W.H.E. Hamed, N. Mostafa Omar, D. Refat El-Bassouny, and S.A. Gawish, The impact of busulfan on the testicular structure in prepubertal rats: A histological, ultrastructural and immunohistochemical study. *Ultrastruct Pathol*, 2023. 47(5): p. 424-450.
15. Bancroft, J.D. and C. Layton, 10 - The hematoxylin and eosin, in *Bancroft's Theory and Practice of Histological Techniques (Seventh Edition)*, S.K. Suvarna, C. Layton, and J.D. Bancroft, Editors. 2013, Churchill Livingstone: Oxford. p. 173-186.
16. Suvarna, K.S., C. Layton, and J.D. Bancroft, *Bancroft's Theory and Practice of Histological Techniques E-Book*. 2018: Elsevier Health Sciences.
17. Rutland, C.S., *Histological and Histochemical Methods 4th Edition*. *J Anat*. 2008 Sep;213(3):356. doi: 10.1111/j.1469-7580.2008.00957.x.
18. Huang, K.H., W.L. Fang, A.F. Li, P.H. Liang, C.W. Wu, Y.M. Shyr, and M.H. Yang, Caspase-3, a key apoptotic protein, as a prognostic marker in gastric cancer after curative surgery. *Int J Surg*, 2018. 52: p. 258-263.
19. Melling, N., C.M. Kowitz, R. Simon, C. Bokemeyer, L. Terracciano, G. Sauter, J.R. Izbiicki, and A.H. Marx, High Ki67 expression is an independent good prognostic marker in colorectal cancer. *J Clin Pathol*, 2016. 69(3): p. 209-14.
20. Hazra, A. and N. Gogtay, *Biostatistics Series Module 3: Comparing Groups: Numerical Variables*. *Indian J Dermatol*, 2016. 61(3): p. 251-60.
21. In *Bancroft's Theory and Practice of Histological Techniques (Seventh Edition)*, S.K. Suvarna, C. Layton, and J.D. Bancroft, Editors. 2013, Churchill Livingstone: Oxford. p. 605-608.
22. Xu, R., F. Wang, Z. Zhang, Y. Zhang, Y. Tang, J. Bi, C. Shi, D. Wang, H. Yang, Z. Wang, and Z. Tang, Diabetes-Induced Autophagy Dysregulation Engenders Testicular Impairment via Oxidative Stress. *Oxid Med Cell Longev*, 2023. 2023: p. 4365895.
23. Sayed, M.M., N.M. Abd El-Rady, W.M.S. Gomaa, A. Hosny, and A.M.S. Gomaa, Antioxidant, antiapoptotic, and antifibrotic abilities of L-Arginine ameliorate the testicular dysfunction in diabetic rats. *Tissue Cell*, 2023. 82: p. 102036.
24. Karaca, T., S. Demirtaş, İ. Karaboğa, and S. Ayvazz, Protective effects of royal jelly against testicular damage in streptozotocin-induced diabetic rats. *Turk J Med Sci*, 2015. 45(1): p. 27-32.
25. He, Z., G. Yin, Q.Q. Li, Q. Zeng, and J. Duan, Diabetes Mellitus Causes Male Reproductive Dysfunction: A Review of the Evidence and Mechanisms. In *Vivo*, 2021. 35(5): p. 2503-2511.
26. Kumar, G.G., E.K. Kilari, G. Nelli, and N. Bin Salleh, Oral administration of *Turnera diffusa* Willd. ex Schult. extract ameliorates steroidogenesis and spermatogenesis impairment in the testes of rats with type-2 diabetes mellitus. *J Ethnopharmacol*, 2023. 314: p. 116638.
27. Parlar Köprülü, R.E., M.E. Okur, B. Kolbaşı, İ. Keskin, and H. Ozbek, Effects of Vincamine on Testicular Dysfunction in Alloxan-induced Diabetic Male Rats. *Iran J Pharm Res*, 2022. 21(1): p. e132265.
28. Song, J., X. Gao, Z. Tang, H. Li, Y. Ruan, Z. Liu, T. Wang, S. Wang, J. Liu, and H. Jiang, Protective effect of Berberine on reproductive function and spermatogenesis in diabetic rats via inhibition of ROS/JAK2/NFκB pathway. *Andrology*, 2020. 8 (3): p.793-806.
29. Nethengwe, M., K. Okaiyeto, O.O. Oguntibeju, and N.L. Brooks, Ameliorative effects of *Anchomanes difformis* aqueous extract against oxidative stress in the testes and epididymis of streptozotocin-induced diabetic male Wistar rats. *Saudi J Biol Sci*, 2022. 29(5): p. 3122-3132.

30. Yaribeygi, H., M.T. Mohammadi, T. Jamialahmadi, and A. Sahebkar, PPAR- $\alpha$  Agonist Fenofibrate Ameliorates Oxidative Stress in Testicular Tissue of Diabetic Rats. *Crit Rev Eukaryot Gene Expr*, 2020. 30(2): p. 93-100.
31. Kanter, M., C. Aktas, and M. Erboga, Curcumin attenuates testicular damage, apoptotic germ cell death, and oxidative stress in streptozotocin-induced diabetic rats. *Mol Nutr Food Res*, 2013. 57(9): p. 1578-85.
32. Kucuk Baloglu, F., D. Guldag Tas, O. Yilmaz, and F. Severcan, The recovery effect of Vitamin C on structural alterations due to Streptozotocin-Induced diabetes in rat testicular tissues. *Spectrochim Acta A Mol Biomol Spectrosc*, 2023. 288: p. 122149.
33. Liu, Y., Z. Yang, D. Kong, Y. Zhang, W. Yu, and W. Zha, Metformin Ameliorates Testicular Damage in Male Mice with Streptozotocin-Induced Type 1 Diabetes through the PK2/PKR Pathway. *Oxid Med Cell Longev*, 2019. 2019: p. 5681701.
34. Atta, M.S., E.A. Almadaly, A.H. El-Far, R.M. Saleh, D.H. Assar, S.K. Al Jaouni, and S.A. Mousa, Thymoquinone Defeats Diabetes-Induced Testicular Damage in Rats Targeting Antioxidant, Inflammatory and Aromatase Expression. *Int J Mol Sci*, 2017. 18(5).
35. Sahu, C., D.K. Dwivedi, and G.B. Jena, Zinc and selenium combination treatment protected diabetes-induced testicular and epididymal damage in rat. *Hum Exp Toxicol*, 2020. 39(9): p. 1235-1256.
36. Nasiri, K., A. Akbari, M. Nimrouzi, M. Ruyvaran, and A. Mohamadian, Safflower seed oil improves steroidogenesis and spermatogenesis in rats with type II diabetes mellitus by modulating the genes expression involved in steroidogenesis, inflammation and oxidative stress. *J Ethnopharmacol*, 2021. 275: p. 114139.
37. Faddladdeen, K.A.J., The possible protective and therapeutic effects of ginger and cinnamon on the testis and coda epididymis of streptozotocin-induced-diabetic rats: Histological and biochemical studies. *Saudi J Biol Sci*, 2022. 29(12): p. 103452.
38. Sarhan, N.R., The Ameliorating Effect of Sodium Selenite on the Histological Changes and Expression of Caspase-3 in the Testis of Monosodium Glutamate-Treated Rats: Light and Electron Microscopic Study. *J Microsc Ultrastruct*, 2018. 6(2): p. 105-115.
39. Long, L., H. Qiu, B. Cai, N. Chen, X. Lu, S. Zheng, X. Ye, and Y. Li, Hyperglycemia induced testicular damage in type 2 diabetes mellitus rats exhibiting microcirculation impairments associated with vascular endothelial growth factor decreased via PI3K/Akt pathway. *Oncotarget*, 2018. 9(4): p. 5321-5336.
40. Anuar, N.S., S.A. Shafie, M.A.F. Maznan, N. Zin, N.A.S. Azmi, R.A. Raoof, D. Myrzakozha, and N. Samsulrizal, Lauric acid improves hormonal profiles, antioxidant properties, sperm quality and histomorphometric changes in testis and epididymis of streptozotocin-induced diabetic infertility rats. *Toxicol Appl Pharmacol*, 2023. 470: p. 116558.
41. ElBanna, A.H., A.S. Osman, A. Hossny, H. ElBanna, and F.I. Abo El-Ela, Dose-dependent effects of taurine against testicular damage in a streptozotocin-induced type 1 diabetes mellitus rat model. *Int J Immunopathol Pharmacol*, 2023. 37: p. 3946320231172745.
42. Jiao, N., Y. Chen, Y. Zhu, W. Wang, M. Liu, W. Ding, G. Lv, J. Lu, B. Yu, and H. Xu, Protective effects of catalpol on diabetes mellitus-induced male reproductive damage via suppression of the AGEs/RAGE/Nox4 signaling pathway. *Life Sci*, 2020. 256: p. 116736.
43. Killari, K.N., H. Polimati, D. Prasanth, G. Singh, S.P. Panda, G.S. Vedula, and V.B. Tatipamula, Salazinic acid attenuates male sexual dysfunction and testicular oxidative damage in streptozotocin-induced diabetic albino rats. *RSC Adv*, 2023. 13(19): p. 12991-13005.
44. Toprak, V., S.A. Akalın, E. Öcal, Y. Çavuş, and İ. Özdemir, Histopathological examination of the protective effect of intense exercise in apoptotic germ cell damage due to diabetes. *Acta Cir Bras*, 2023. 38: p. e381423.
45. Souza, H.V. and M.M. Itoyama, Study of acrosome formation, interspecific and intraspecific, in the testicular lobes of some pentatomid species. *J Insect Sci*, 2010. 10: p. 132.
46. Zayman, E., M. Gül, M.E. Erdemli, S. Gül, H.G. Bağ, and E. Taşlıdere, Biochemical and histopathological investigation of the protective effects of melatonin and vitamin E against the damage caused by acetamidrid in Balb-c mouse testicles at light and electron microscopic level. *Environ Sci Pollut Res Int*, 2022. 29(31): p. 47571-47584.
47. Abbaszadeh, A., V. Assadollahi, M. Alasvand, K. Anbari, N. Tavakoli, and M. Gholami, Protective effects of royal jelly on testicular torsion induced ischaemia reperfusion injury in rats. *Andrologia*, 2020. 52(9): p. e13716.
48. Besong, E.E., P.J. Ashonibare, O.O. Obembe, M.A. Folawiyo, D.H. Adeyemi, M.A. Hamed, T.M. Akhigbe, and R.E. Akhigbe, Zinc protects against lead-induced testicular damage via modulation of steroidogenic and xanthine oxidase/uric acid/caspase 3-mediated apoptotic signaling in male Wistar rats. *Aging Male*, 2023. 26(1): p. 2224428.
49. Asadi, N., A. Kheradmand, M. Gholami, S.H. Saidi, and S.A. Mirhadi, Effect of royal jelly on testicular antioxidant enzymes activity, MDA level and spermatogenesis in rat experimental Varicocele model. *Tissue Cell*, 2019. 57: p. 70-77.



## المخلص العربي

## يعزز غذاء ملكات النحل على تكوين الحيوانات المنوية ويقتل من موت الخلايا المبرمج في خصية الجرذان المصابة بداء السكري: دراسة هستولوجية وهستوكيميائية مناعية

ايمان أحمد يوسف الحلو، وفاء سعد حامد، أمل محمد مصطفى، زينب عبدالحى سقارة

قسم علم الأنسجة الطبية وبيولوجيا الخلية - كلية الطب - جامعة المنصورة

**الخلفية:** يعد مرض السكري مشكلة صحية شائعة وقد وجد ان لارتفاع نسبة السكر بالدم أضرار بالغة لكل من الخصائص المورفولوجية للخصيتين و كذلك تكوين الحيوانات المنوية. ويتميز غذاء ملكات النحل بخصائص عديدة مثل انه مضاد للاكسدة وله تأثير مضاد للسكري.

**الهدف من البحث:** هدفت هذه الدراسة إلى تقييم الدور الوقائي لغذاء ملكات النحل على التغيرات التي يسببها مرض السكري من النوع الأول المستحث بعقار الستربتوزوتوسين للخصية في الجرذان البالغة.

**مواد وطرق البحث:** تم تقسيم ثلاثين ذكرا من الجرذان البيضاء البالغة الذين تتراوح اعمارهم بين ١٠ و ١٢ اسبوعا و تصل أوزانهم إلى ٢٥٠ جرام تقريبا إلى ثلاث مجموعات متساوية. المجموعة الضابطة (المجموعة ١) تلقت محلولاً فسيولوجياً ملحيًا (١مل/كجم/يومياً). مجموعة مرض السكري المستحث (المجموعة ٢) وتم حقنها داخل الصفاق بجرعه واحده من ٥٠ ملجرام/ كيلوجرام من الستربتوزوتوسين، وبعد ثبوت الإصابة بالسكري تركت بدون علاج لمدة ٤ اسابيع. مجموعة غذاء ملكات النحل (المجموعة ٣) وتم حقنها مثل المجموعة الثانية وبعد ثبوت الإصابة بالسكري تلقت عن طريق الفم جرعه ١٠٠ مجم/كجم/اليوم من غذاء ملكات النحل لمدة ٤ أسابيع.

تم تحضير عينات من الخصيتين لجميع الجرذان وصباغتها للدراسة بالمجهر الضوئي (الهيماتوكسيلين والإيوسين، صبغة PAS، بالإضافة إلى الصبغة الهستوكيميائية المناعية Caspase-٣ و Ki-٦٧.

**النتائج:** بسبب داء السكري تغير ملحوظ في السمات النسيجية للخصية بالإضافة إلى زيادة كبيرة في النسبة المئوية لمساحة التعبير المناعي Caspase-٣ وانخفاض في التعبير المناعي Ki-٦٧.

وقد أدى تعاطي غذاء ملكات النحل كمكمل غذائي إلى تحسن في السمات النسيجية للخصية، وانخفاض كبير في النسبة المئوية لمساحة التعبير المناعي Caspase-٣، وزيادة كبيرة في التعبير المناعي Ki-٦٧.

**الاستنتاج:** يقوم غذاء ملكات النحل بتأثيرات واقية على اعتلال الخصية الناجم عن داء السكري لامتعه بخصائص مضادة للاكسدة مما يقلل من الموت المبرمج للخلايا.