

# A Comparative Study between Distally Based Sural Artery Flap and Medial Plantar Artery Flap in Reconstruction of Ankle and Foot Defects

Ahmed Mohammed Hussien, MSC; Ahmed Gaber Abdel-Megeed, MD; Karam Ahmed Allam, MD; Mohammed Abdel-Aal Hasanyn, MD

Plastic Surgery Department, Faculty of Medicine, Sohag University, Sohag, Egypt

**Background:** Frequently, foot injuries are accompanied by the loss of soft tissues and the exposure of bone. The plantar (P) skin is thick and firmly attached to the underlying structures. Therefore, the objective of reconstructive surgery is to restore the foot skin's capacity to respond to weight bearing and withstand shearing pressures. This study was undertaken to compare the clinical implementations of distally based sural artery flap (DSAF) against medial plantar artery flap (MPAF) as a reconstructive alternative for foot abnormalities in terms of size of the defect, operational technique, and results (success and complications).

**Methods:** This prospective research was done on 20 cases presented with foot defects. Cases were allocated into two equal groups: Group 1 comprised 10 cases with MPAF, and Group 2 comprised 10 cases with reversed sural flap.

**Results:** Size of the defect was significantly lower in MPAF compared to reversed sural flap group. Donor closure was significantly better in reversed sural flap group compared to MPAF. Donor morbidity represented in graft healed, delayed healing, wound healed was indifferent between both groups. Flap sensation was significantly better in MPAF compared to reversed sural flap group. Flap reach was significantly longer in reversed sural flap group compared to MPAF. Complications (dehiscence in one edge, ischemic flap and ischemic distal part) were indifferent between both groups

**Conclusions:** In cases with foot defects, size of defect, and flap reach were significantly higher in MPAF compared to reversed sural flap. Flap sensation was significantly better in MPAF compared to reversed sural flap in contrast to donor closure. Additionally, reported complications, case satisfaction, and donor morbidity were indifferent between both groups.

**Key words:** Distally based sural artery flap, medial plantar artery flap, rebuild of ankle and foot defects.

## Introduction

Frequently, foot injuries result in tissue loss and bone exposure.<sup>1,2</sup> Sole of foot skin is thickened and tightly bound to underlying tissue. The objective of reconstruction surgery is to rebuild the skin of the foot and regain its capacity to bear weight and withstand shearing pressures. Moreover, rebuild should incorporate sensations. Additional considerations the ankle region is subject to a large deal of stress during movement, and shoes must provide adequate stability.<sup>3</sup> Shanahan and Gingrass.<sup>4</sup> demonstrated the medial sensory flap for heel defect covering. Harrison.<sup>5</sup> characterised the flap's island variant. The flap is a fasciocutaneous island flap harvested from the P foot's non-weight-bearing area. The medial plantar artery (MPA) and venae comitantes comprise the major vascular pedicle of the flap. MPA is the smaller terminal branch of the posterior tibial artery. It is initially located above the abductor hallucis and subsequently between it and the flexor digitorum brevis, both of which it serves. The medial P flap has been utilised efficiently in the restoration of mild to moderate soft tissue abnormalities localised to the P foot, forefoot, posterior heel, and ankle.<sup>6</sup> This flap can be transplanted as a proximally or distally pedicled island flap to the defect.<sup>7</sup> This study was undertaken to compare the practical implementations of distally

based sural flap (DSAF) against medial plantar artery flap (MPAF) as a reconstructive alternative for foot abnormalities in terms of size of the defect, operational technique, and results (Success and complications).

## Patients and methods

This prospective research was done on twenty cases with defect at the foot and size of the defect (5- 15) cm<sup>2</sup> at the Plastic Surgery Department Sohag University. The study was done after approval from the Ethical Committee Sohag University. An informed written consent was obtained from the case or relatives of the cases.

Defects in the foot or ankle, with a size of the defect of 5-15 cm<sup>2</sup>, in cases aged 5 to 70 were considered for inclusion. Defects larger than 15 centimetres and injuries to the vascular pedicle of the targeted flap were incompatible with the procedure.

Cases were randomly allocated into two equal groups. The allocation of cases was concealed with sequentially numbered and sealed envelopes and was stored in a research office away from the clinical care team. The envelope was opened during the surgery after the wounds of the lower limbs were debrided.

Cases were randomized to receive either to MPAF or reversed sural flap

**Group I:** 10 cases were subjected MPAF.

**Group II:** 10 cases were subjected to reversed sural flap.

**All cases were subjected to the followings:**

Full history taking. Routine laboratory investigation. Clinical evaluation of case includes time of trauma, site of the defect, size of the defect & associated injuries. Radiological evaluation with x-rays in 2 views.

**First aid to recent trauma cases:** Appropriate emergency treatment is given for associated head, chest, and/or abdominal injuries after hemodynamic stabilization in cases of recent trauma. Antibiotics injection and tetanus toxoid. The limb is rested on splint after dressing.

**Operative Technique & Modifications**

**For reversed sural flap:** After administering spinal anaesthesia, the case is positioned in the prone position. A tourniquet (350 psi inflated) is applied and withdrawn 60 to 90 minutes later. Wound debridement is the initial step in every surgical procedure. In order to ascertain how big a flap is needed, the wounds must first be measured. One can visualise the superficial sural nerve (SN) and the lesser saphenous vein by tracing a line from the midpoint of the Achilles tendon and the lateral malleolus at the level of the lowest septocutaneous perforator to the mid-popliteal fossa. Once the size of the deficiency in the proximal third of the posterior calf is determined, the flap may be carefully drawn. The cutaneous pedicle, measuring 3 cm in width, is marked off from the flap's base along the central line to the lowest septocutaneous perforator. To begin, the medial sural cutaneous nerve is found and ligated before the Long saphenous vein (LSV) is located at the proximal boundary of the cutaneous flap. At once, subfascial dissection was carried out from both sides of the cutaneous flap toward its midline. Next, incisions are made (all the way to the dermis) along the 3 cm skin pedicle and along the lower flap's skin border. The subdermal plexus is exposed by lifting a flap of skin. To perform an anastomosis between the peroneal artery and the concomitant arteries around the LSV and SN, the subfascial elevation under the flap and pedicle was carried out from proximal to distal and culminated at a pivot point. Our method involves creating a spoon-shaped cutaneous flap that protects the medial sural cutaneous nerve, the lateral sagittal vein, and the veins that run with them. The cutaneous flap

is then rotated by 180 degrees, either medially or laterally, to resurface the defect. No tunnelling was done. The flap and its cutaneous pedicle were given access by incising the skin that joined the donor and recipient sites. The donor site may be sutured or covered with a split skin graft thereafter, depending on how large the flap is. The limb is immobilised with a non-compressive slab and dressing.

**For medial plantar artery flap:** The case is positioned either supine or laterally. Starting It's curved and begins 1 cm beyond the medial malleolus (MM) and extends into the first web area. Dissection is carried out to reveal the posterior tibial artery (PTA) behind the MM all the way to its bifurcation into the plantar arteries (PA). The origin of (medial plantar artery) MPA is traced back to the PTA by locating it and then removing the head of the abductor hallucis. The sensory properties of the flap are protected by isolating the branches of the medial plantar nerve (MPN) that supply it from the nerve's main stem. The P fascia is subsequently integrated into flap's proximal-to-distal elevation. At the margins of the desired flap, a cut is made in the P fascia between the abductor hallucis muscle and the first slip of the flexor digitorum brevis muscle. The MPN, MPA, and accompanying veins are found at the end of the cut and are dissected proximally beneath the flap. To make a tunnel, subcutaneous tissue is taken from the area between the flap donor site and the defect by surgical cut. At the completion of the procedure, the cut is typically closed. As soon as the bandage is no longer in place, the flap's blood flow may be assessed. The flap is turned to cover the recipient area after meticulous hemostasis, and loose interrupted sutures are utilised to attach it without stress. Most of the flaps' donor sites are grafted using split-thickness cutaneous grafts.

**Statistical analysis**

Version 25 of the SPSS (Statistical Package for the Social Sciences) was used for statistical analysis (IBM Inc., Chicago, IL, USA). The mean, standard deviation (SD), and range were used to represent quantitative values (e.g., age). Categorical variables (such as gender) were expressed as frequencies and percentages, and the Chi-square test was used to analyse them statistically. A two-tailed P value less than or equal to 0.05 was considered statistically significant.

**Results**

Regarding demographic data of the studied groups, age and sex were indifferent between both groups. Size of the defect was significantly lower in MPAF than reversed sural flap group. **(Table 1).**

**Table 1: Demographic data of the studied groups**

		MPAF (n=10)	Reversed sural flap (n=10)	P value
Age (years)	Mean ± SD	33.8 ± 10.87	34.6 ± 12.01	0.878
	Range	12 - 50	16 - 56	
Sex	Male	6 (60%)	8 (80%)	0.629
	Female	4 (40%)	2 (20%)	
Defect size (cm)	Mean ± SD	27 ± 12.33	56.3 ± 22.78	0.002*
	Range	12 - 42	24 - 90	

Donor site closure was significantly better in reversed sural flap group than MPAF. Donor site morbidity

was indifferent between both groups. (Table 2).

**Table 2: Donor site closure and donor site morbidity of the studied groups**

		MPAF (n=10)	Reversed sural flap (n=10)	P value
Donor closure	Full thickness graft	4 (40%)	0 (0%)	0.029*
	Split thickness graft	6 (60%)	7 (70%)	
	1ry closure	0 (0%)	3 (30%)	
Donor morbidity	Graft healed	5 (50%)	3 (30%)	0.082
	Delayed healing	5 (50%)	3 (30%)	
	Wound healed	0 (0%)	4 (40%)	

Regarding Flap advantages of the studied groups, flap sensation was significantly better in MPAF compared to reversed sural flap group. Flap reach

was significantly longer in reversed sural flap group than MPAF. (Table 3).

**Table 3: Flap advantages of the studied groups**

		MPAF (n=10)	Reversed sural flap (n=10)	P value
Flap sensation	Sensate	2 (20%)	0 (0%)	0.032*
	Insensate	8 (80%)	10 (100%)	
Flap reach (cm)	Mean ± SD	3.70 ± 0.82	9.30 ± 1.70	<0.001*
	Range	3 - 5	7 - 12	

Regarding Complications of the studied groups, Complications (dehiscence in one edge, ischemic

flap, ischemic distal part) were indifferent between both groups. (Table 4).

**Table 4: Complications of the studied groups**

		MPAF (n=10)	Reversed sural flap (n=10)	P value
Complications	Dehiscence in one edge	3 (30%)	1 (10%)	1.00
	Ischemic flap	0 (0%)	2 (30%)	0.462
	Ischemic distal part	0 (0%)	2 (30%)	0.462

Regarding case satisfaction and follow up, Case satisfaction and follow up were indifferent between

both groups. **(Table 5).**

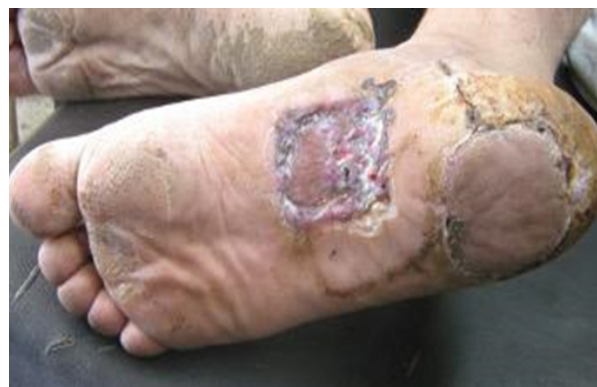**Table 5: Case satisfaction and follow up of the studied cases**

		MPAF (n=10)	Reversed sural flap (n=10)	P value
<b>Case satisfaction</b>	<b>Good</b>	7 (70%)	5 (50%)	0.65
	<b>Poor</b>	3 (30%)	5 (50%)	
<b>Follow up (Months)</b>	<b>Mean ± SD</b>	3.10 ± 0.74	3.40 ± 0.70	0.363
	<b>Range</b>	2 - 4	2 - 4	

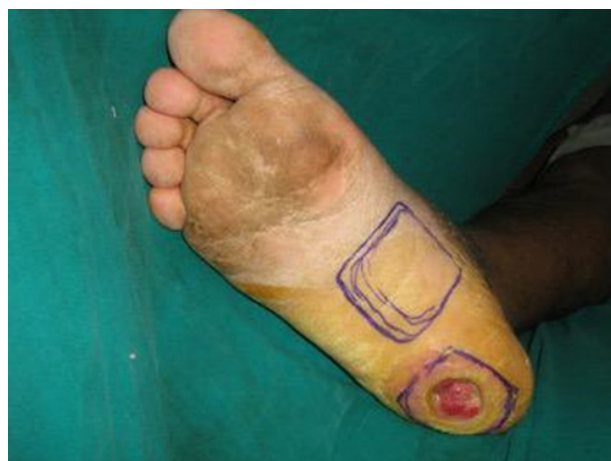**Cases presentation**

**Case 1**

Forty years old male patient with chronic ulcer in the right heel excision & reconstruction done with medial plantar artery flap.



**Fig 1c: 3 months post operative.**

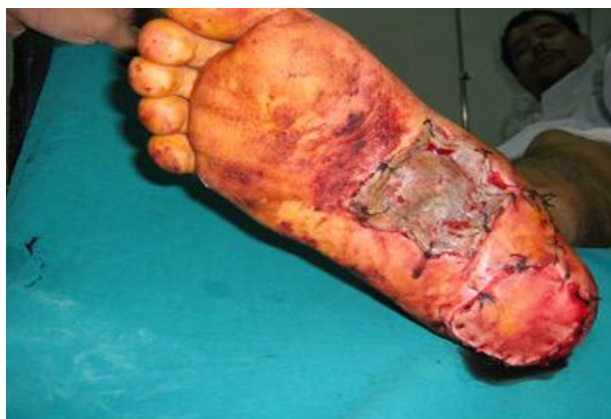

**Fig 1a: Chronic ulcer in the right heel.**

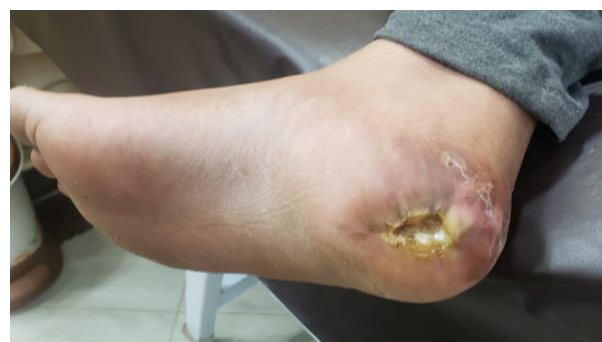**Case 2**

Forty years old male patient with a chronic ulcer in the right heel.

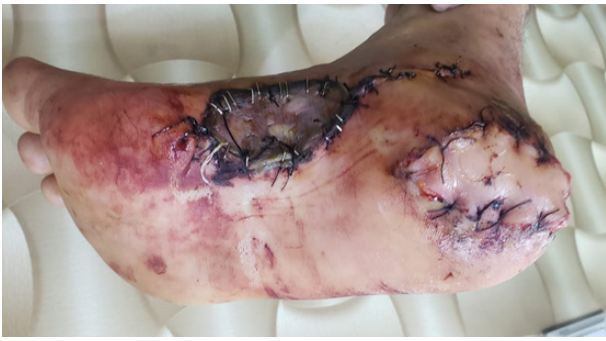Excision and reconstruction was done by MPAF.



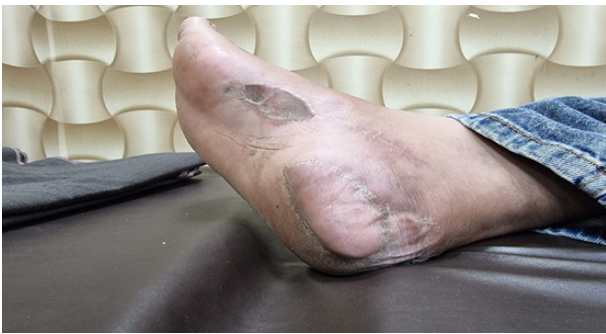**Fig 1b: Flap inseting to the defect and donor site closure by split-thickness skin graft.**



**Fig 2a: Ulcerative lesion in the heel.**



**Fig 2b: Defect coverage by the flap and donor site closure with split thickness skin graft.**

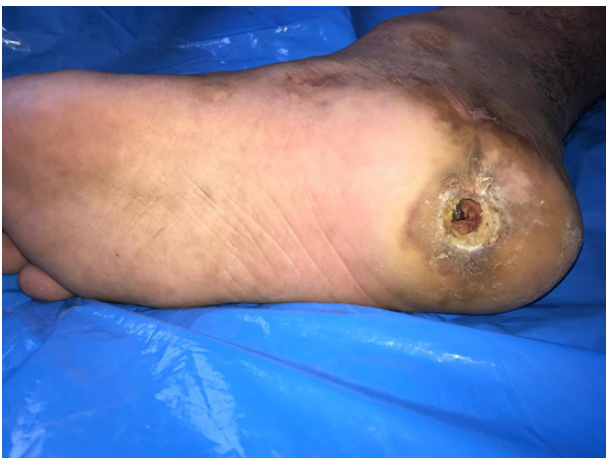

**Fig 2c: Four months post operative.**

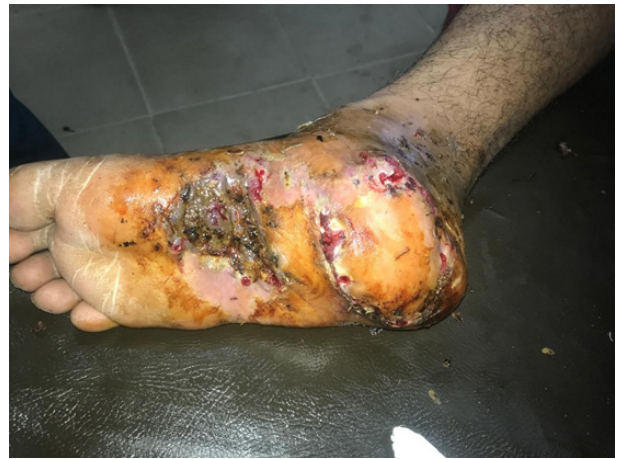**Case 3**

Thirty five years old male patient with a chronic ulcer in the heel.

Excision and reconstruction was done by MPAF.



**Fig 3a: Ulcerative lesion in the heel.**

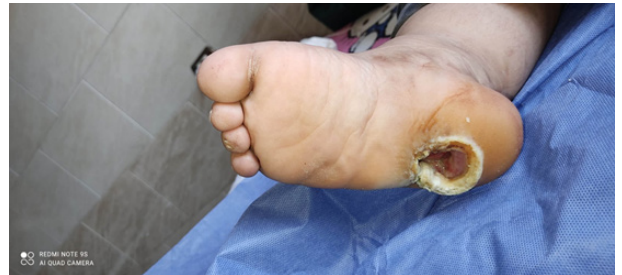

**Fig 3b: Two months post operative.**

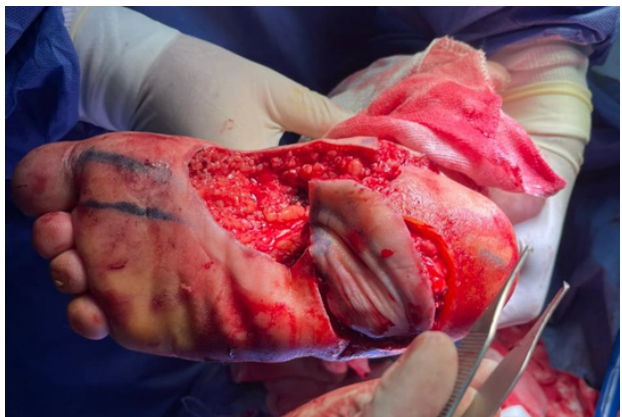
**Case 4**

Twelve years old female patient with ulcerative lesion in the heel.

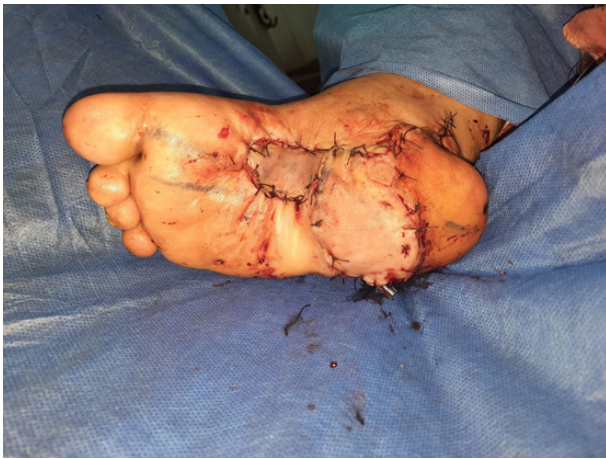Excision and reconstruction was done with MPAF.



**Fig 4a: Ulcerative lesion in the heel.**



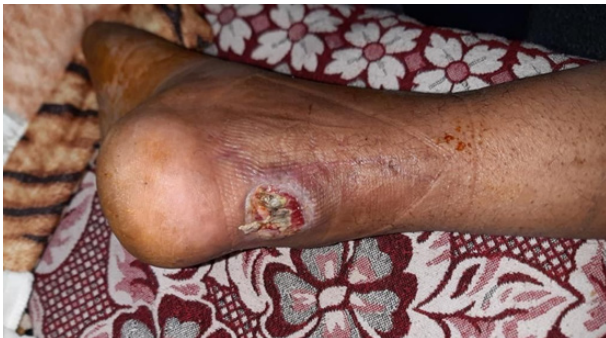**Fig 4b: Flap raising intraoperative.**



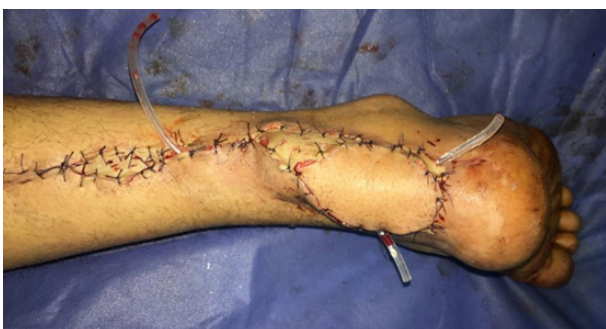**Fig 4c: Flap covered the defect and donor site closure with full thickness graft.**

**Case 5**

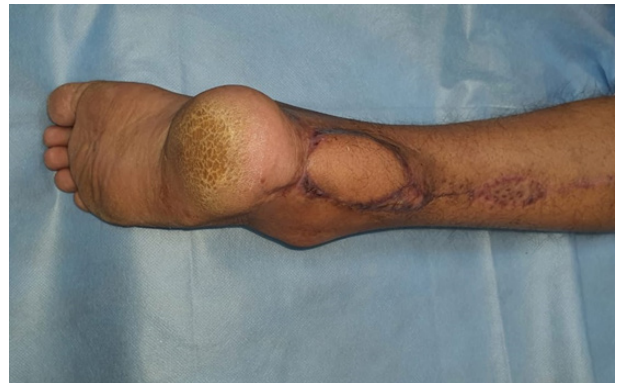Forty years old male patient with traumatic raw area over tendon achilles ,debridement was done and reconstruction by RSAF.



**Fig 5a: Traumatic raw area over tendon achilles.**



**Fig 5b: Coverage of the defect with RSAF and donor site closure with split thickness skin graft.**

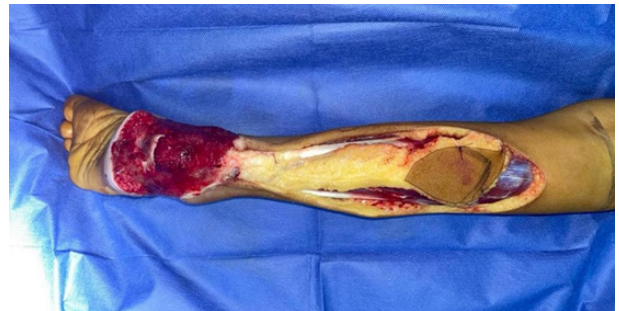

**Fig 5c: Four months post operative.**

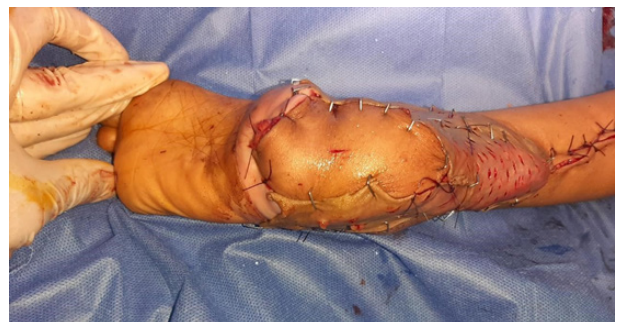**Case 6**

Sixteen years old male patient with traumatic raw area on the heel.

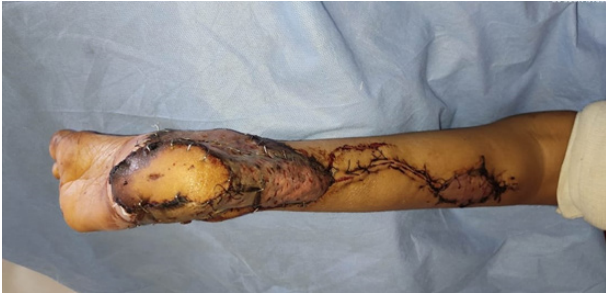Debridement and reconstruction by RSAF and split thickness graft was done.



**Fig 6a: Debridement was done flap raised.**



**Fig 6a: Flap sitted to the defect.**

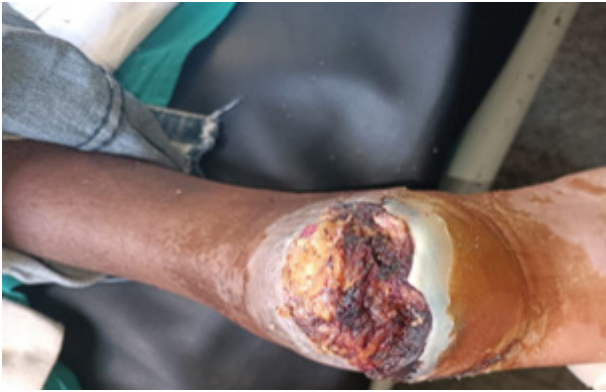

**Fig 6b: Post operative follow up.**

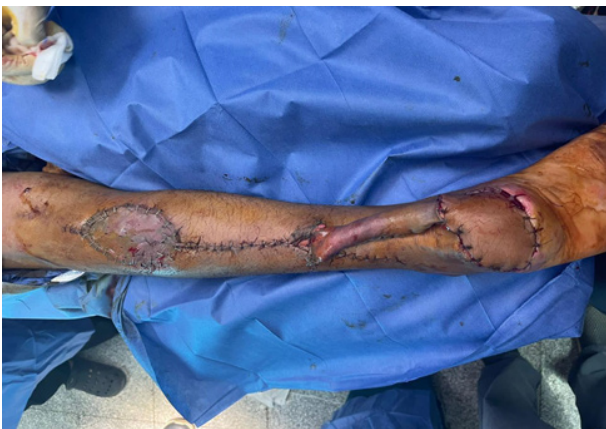### Case 7

Twenty years old male patient with traumatic raw area on the heel.

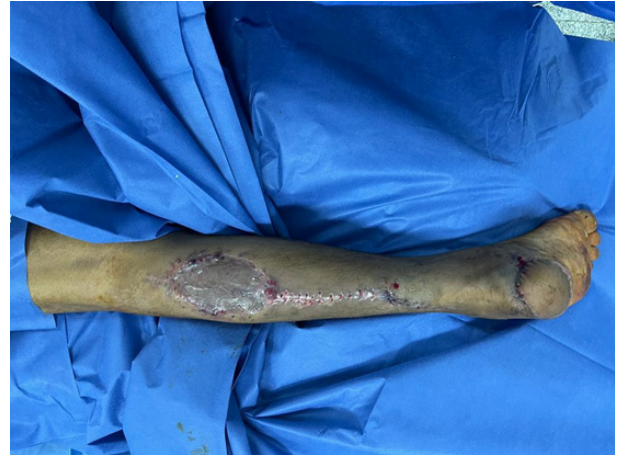Debridement and reconstruction was done with RSAF.



**Fig 7a: Traumatic raw area in the heel.**



**Fig 7b: Coverage of the defect with the flap and donor site closure with split thickness skin graft.**



**Fig 7c: After separation of the pedicle of the flap.**

### Discussion

The flap is a fasciocutaneous island flap raised from the non-weight bearing P foot instep. MPA is the smaller terminal branch of PTA. Both the abductor hallucis and the flexor digitorum brevis are supplied by this artery, which may be found at first above the abductor hallucis and later between the two muscles. This artery begins as a large vein near the base of the first metatarsal (MT) bone, narrows as it travels along the medial border of the first toe, and finally joins the first dorsal MT artery. The MPAF has been utilised successfully in the restoration of soft tissue abnormalities confined to the P foot, forefoot, posterior heel, and ankle in cases with mild to moderate deformities.

In accordance with our findings, using a cross-sectional design, Mahmoud et al.<sup>8</sup> compared the results of using the medial plantar fascia (MPAF) to the distally based sural artery flap (DSAF) in foot repair. The study included 30 adults with soft tissue abnormalities in the foot and around the ankle. One group went through rebuilding with the island-based MPAF. The second group had reconstructive surgery using the reversed sural artery flap (RSAF). The surgical duration and consequences were meticulously documented.

Moreover, Khan et al.<sup>9</sup> conducted a three-year retrospective research that included heel soft-tissue damage. All cases were treated with a Medial Plantar Artery Perforator (MPAP) flap to fill the defect. Cases' demographics, method of injury, size of the defect, size of the flap and longevity, needed time to weight-bear, restoration of sensation, and comparative 2-point discrimination with the opposite heel were investigated. The average surface area of the flaw was determined to be 10 6 cm.

Hashmi et al.<sup>10</sup> did a retrospective review of 53 fasciocutaneous flaps (27 sural and 26 supramalleolar) used to rebuild soft tissue

abnormalities of the foot. Their findings were consistent with ours. They demonstrated that in distally based sural artery flaps, 26 cases had complete defect coverage and were assessed as good, while only one case required skin grafting due to incomplete defect coverage. 19 cases rated the aesthetic look as outstanding deemed it to be satisfactory.

However, Mahmoud et al.<sup>8</sup> findings highlighted that Significantly more functional outcomes improved in the MPAF than in the RSAF group ( $p = .004$ ). This difference could be justified by relatively larger sample size.

In addition, Sever et al.<sup>11</sup> detailed their experience covering foot deformities with a MPAF. Eleven cases with abnormalities in the soft tissues of the P fascia, distal forefoot, posterior heel, and ankle were treated. The age and gender of each case, the origin and location of deformities, flap size, surgical outcomes, and complications were noted. One case's flap donor sites were covered with split-thickness skin grafts although partial necrosis was noted. Postoperatively, ten flaps made a full recovery. All surviving defect-covering flaps adapted effectively to their recipient regions, exhibiting a good colour match and enough mass.

Similar to our findings, Mahmoud et al.<sup>8</sup> found that, In the MPAF, the donor site healed normally and the graft took well, with the exception of a single instance of delayed graft healing. In the RSAF group, delayed healing of the graft was also reported in 1 case. Further, El-Shazly et al.<sup>1</sup> study results reported delayed healing in 3 cases in RSAF compared to 1 case in MPAF.

Our findings are in consistent with Hashmi et al. (10) observed that one of the disadvantages of sural artery flap is that it causes irreversible numbness along the lateral foot and 5th toe where the SN is located.

The superiority of MPAF was demonstrated by Khan et al.,<sup>9</sup> as their cases regained protective sensation on covered area in  $4 \pm 2$  days and none of their cases complained of decreased or loss of sensation. Further, El-Shazly et al.<sup>1</sup> found in MPAF and among 12 cases, flaps were sensitive in 5 cases where in RSAF group, deep sensation developed.

Rashid et al.<sup>15</sup> evaluated the indications, ease of elevation, operational time, complications, and longevity of two fasciocutaneous flaps, i.e., the sensate MPAF and the distally based sural artery neurocutaneous flap (SANF), utilised to cover the weight-bearing heel in young ambulatory people. Twenty cases received an MPAF whereas thirty cases underwent a SANF to repair their faults. The cases were monitored postoperatively to assess any short- or long-term problems. They discovered that

the MPAF and the DSAF produce equivalent feeling. This could be justified by relatively larger sample size and ethnic consideration.

Similarly, Sever et al.<sup>11</sup> discovered that at the end of the fourth month, all cases with MPAF had developed a protective deep-pressure feeling and were totally mobile.

In addition, Hashmi et al.<sup>10</sup> study results reported that the maximum size of the flap harvested was  $25 \times 10$  cm for sural flap.

The capability of larger area coverage was also showed by Jeng and Wei.<sup>16</sup> Nineteen cases with abnormalities in the ankle and/or the dorsal and plantar surfaces of the foot were reconstructed using the distally based sural island flap. Resurfacing the load-bearing portions of the heel was accomplished with four sural flaps, each of which was supplied by the lateral sural cutaneous nerve. They found that the sural flap's cutaneous paddle may grow to be 180 centimetres in length.

In concurrence with our findings, Thammanagowda et al.<sup>12</sup> Their results confirmed that RSAF should be chosen for defects in larger size defects the average surface area covered by RSAF was 38 cm<sup>2</sup>.

In addition, Sever et al.<sup>11</sup> noted that MPAF may reach as far as the heel pad, dorsal aspect of the ankle, and forefoot.

Moreover, Daar et al.<sup>14</sup> noted that complication rates following RSAF repair range greatly in the literature, with some authors reporting no difficulties, and that the rates of partial and entire flap loss varied substantially among included studies (0–44% and 0–20%, respectively). In contrast to attempted primary closure or skin grafting over a dermal replacement, the proposed techniques can limit the likelihood of surgical site problems and assure good soft tissue flap coverage.

However, Mahmoud et al.<sup>8</sup> found no difference in the MPAF group or all cases Except for one case whose graft healed slowly, the donor area in the MPAF recovered normally. There were no issues at the donor area for the RSAF group, however three cases did end up with an unattractive scar and one had a transplant that took longer to heal than expected. overall, the incidence of complications was found to be significantly lower in the MPAF than in the DSAF, as shown by their study. Variability in measured complications between our study (Dehiscence in one edge, ischemic flap and ischemic distal part) and their study (Flap necrosis, graft loss, infection, paresthesia, and donor site morbidity) could explain this contradiction.

In contrast to our findings, Rashid et al.<sup>15</sup> noted that the postoperative complications were more in



cases who underwent SANF compared to cases who underwent MPAF.

In agreement with our observations, El-Shazly et al.<sup>1</sup> calculated a combination of factors including the length of time the rebuild lasts, the case's ability to walk with or without aids, the case's ability to utilise appropriate footwear, the amount of pain experienced at the donor area, and the assessment of the aesthetic result. They revealed that although the majority of cases who underwent the sural flaps had to dress up larger or custom-made shoes on the involved foot, all cases were able to amputate the affected toe. The majority of cases had long-term foot care and short-term application of a pressure bandage, although this did not cause a significant disability.

Nevertheless, Mahmoud et al.<sup>8</sup> elucidated during the mean follow-up period (13.2 months), weightbearing was significantly earlier in the MPAF than in the RSAF ( $5.8 \pm 0.26$  weeks compared with  $6.9 \pm 0.19$  weeks;  $p = .003$ ).

**Recommendations:** Further studies are needed with large sample size and longer follow up duration. Rebuild of the foot using either the MPAF or the DSAF flap offers similar benefits. Therefore, the demands of the case and the preferences of the surgeon are always taken into account while determining the best course of therapy. For moderate-sized abnormalities in the foot, we recommend using the Minimally Invasive Foot Fixation technique. for better flap sensation. DSAF offers better functional outcomes and donor closure for large size foot defects.

## Conclusions

In cases with foot defects, size of defect, and flap reach were significantly higher in MPAF compared to reversed sural flap. Flap sensation was significantly better in MPAF compared to reversed sural flap in contrast to donor closure. Additionally, reported complications, case satisfaction, and donor morbidity were indifferent between both groups.

**Financial support and sponsorship:** Nil

**Conflict of Interest:** Nil

## References

1. El-Shazly M, Yassin O, Kamal A, Makboul M, Gherardini G: Soft tissue defects of the heel: A surgical rebuild algorithm based on a retrospective cohort study. *J Foot Ankle Surg.* 2008; 47(2): 145-52.
2. Li X, Cui J, Maharjan S, Lu L, Gong X: Rebuild of the foot and ankle using pedicled or free flaps: perioperative flap survival analysis. *PLoS One.* 2016; 11(12): e0167827.
3. Shen Z-L, Jia W-X, Hou M-Z, Huang X-Q, Cai Y-X, Wang L, et al: Application of flaps for coverage of foot wounds with tendon and bone exposure based on a subunit principle. *Innovations in Plastic and Aesthetic Surgery: Springer.* 2008: 119-26.
4. Shanahan RE, Gingrass RP: Medial plantar sensory flap for coverage of heel defects. *Plastic and Reconstructive Surgery.* 1979; 64(3): 295-8.
5. Harrison DH, Morgan BD: The instep island flap to resurface plantar defects. *Br J Plast Surg.* 1981; 34(3): 315-8.
6. Acikel C, Celikoz B, Yuksel F, Ergun O: Various implementations of the medial plantar flap to cover the defects of the plantar foot, posterior heel, and ankle. *Ann Plast Surg.* 2003; 50(5): 498-503.
7. Uygur F, Duman H, Ulkür E, Noyan N, Çeliköz B: Rebuild of distal forefoot burn defect with retrograde medial plantar flap. *Burns.* 2008; 34(2): 262-7.
8. Mahmoud WH: Foot and ankle rebuild using the distally based sural artery flap versus the medial plantar flap: A comparative study. *J Foot Ankle Surg.* 2017; 56(3): 514-8.
9. Khan FH, Beg MSA, Obaid Ur R: Medial plantar artery perforator flap: Experience with soft-tissue coverage of heel. *Plast Reconstr Surg Glob Open.* 2018; 6(12): e1991.
10. Hashmi M, Musaddiq A, Hashmi A, Zahid M: Comparison of distally based sural artery and supramalleolar flap for coverage of dorsum of foot and ankle defects; a cross-sectional study of 53 cases. *Ann Med Surg (Lond).* 2022; 73: 103109.
11. Sever C, KÜLAHÇI Y: Rebuild of various moderate-size foot defects with the medial plantar flap. *Journal of Turgut Ozal Medical Center.* 2011; 18(4): 222-7.
12. Thammannagowda RK, Ashish G, Mudukappa S, Pushkar D, Vijayakumar A: Comparison between peroneus brevis flap and reverse sural artery flap for coverage of lower one-third leg defects. *International Scholarly Research Notices.* 2014.
13. Boughdadi NS, Zaki BM, Hanafy A: Hindfoot rebuild using the distally based hemisoleus muscle versus the distally based sural flap: A comparative study. *Egypt J Plast Reconstr Surg.* 2012; 36: 215-24.
14. Daar DA, Abdou SA, David JA, Kirby DJ, Wilson SC, Saadeh PB: Revisiting the Reverse Sural

Artery Flap in Distal Lower Extremity Rebuild: A Systematic Review and Risk Analysis. *Ann Plast Surg.* 2020; 84(4): 463-70.

15. Rashid M, Hussain SS, Aslam R, Illahi I: A comparison of two fasciocutaneous flaps in the

rebuild of defects of the weight-bearing heel. *J Coll Physicians Surg Pak.* 2003; 13(4): 216-8.

16. Jeng S-F, Wei F-C: Distally based sural island flap for foot and ankle rebuild. *Plastic and Reconstructive Surgery.* 1997; 99(3): 744-50.