



## Correlation between Digitally Assessed Dental and Skeletal Maturity Methods in Pediatric Dental Patients

Arafa M. Khatab<sup>\*1</sup>, Shereen.A.Ibrahim<sup>2</sup>, DaliaAbou-Alnour<sup>3</sup>

Codex : 05/2023/10

Aadj@azhar.edu.eg

### KEYWORDS

*Dental Maturity;*  
*Skeletal Maturity;*  
*mixed dentition;*  
*Demirjian Method*

1. Department of pediatric dentistry, Faculty of Dental Medicine, Tanta University, Egypt.
2. Department of Orthodontics,, Faculty of Dental Medicine, Fayoum university, Egypt.
3. Department of Oral and Maxillofacial Radiology, Faculty of Dentistry, Modern University for Technology and information (MTI), Egypt

\* Corresponding Author e-mail:  
Khatab68@hotmail.com

### ABSTRACT

**Aim:** The aim of the present study was to evaluate the correlation between dental maturity stages and CVMS digitally wise **Subjects and Methods:** The present retrospective study was conducted on digital Panoramic and lateral cephalometric radiographs obtained from 50 pediatric patients (24 males and 26 females) at active growth period from 7 to 12 years with a mean age of 9.32y. Inclusion criteria included availability of radiographs with adequate quality denoting the patients complete mandibular teeth set either erupted or unerupted. Exclusion criteria included any medical history affecting the teeth development, bony pathological condition, any missed mandibular permanent tooth except the wisdom ones and distorted radiographic images. **Results:** There is a positive correlation between dental maturity stages and CVM. Females had higher correlation coefficient than males. Dental maturation stages, F, G, and H, seemed to be more frequent and appeared earlier in females. In the current study; the mandibular second premolar tooth advancement had the highest correlation coefficient with the maturation stages of the cervical vertebra among male participants (0.649), among female participants; the advancement of mandibular first premolar tooth shown the highest correlation coefficient with CVMS (0.720). Dental maturation stage F showed the highest correlation with CVMS 2 among females and males. **Conclusion:** There is a high correlation between the tooth calcification stages and CVM stages regarding the pediatric Egyptian patients, where CVM stage2- F dental maturation stage showed the highest correlation among both females and males.

### INTRODUCTION

Determination of the timing of intervention and functional treatments play a critical role in the treatment of numerous types of malocclusions. Dentofacial orthopedic treatment success necessitate the growth prediction and assessment via the assessment of several factors including body height and weight, gender features, and dental and skeletal maturity.<sup>[1]</sup> Skeletal maturation assessment using cervical vertebral maturation stage (CVMS) method by **Baccetti** evidenced to be as reliable and valid as hand-wrist analysis.<sup>[2]</sup> Although dental

maturity can be estimated by tooth eruption stage; tooth formation has been anticipated as a better dental maturation method.<sup>[3-5]</sup>

Orthodontist treatment planning decision is usually based on detailed patient subjective information and objective diagnostic records including clinical examination, photograph evaluation, cast analysis and radiographs.<sup>[6,7]</sup> While lateral cephalometric radiographic images is considered as the default radiographic images at the beginning of an orthodontic treatment planning,<sup>[8]</sup> panoramic radiography has a supportive value regarding the orthodontic pre-treatment planning and also in post-treatment assessment evaluation.<sup>[9]</sup>

Because lateral cephalometric images illustrate various anatomical structures including; the cervical spine, all whole teeth set and craniofacial bones and soft tissue, this is why it can reflect the dentoskeletal aging changes of these areas.<sup>[10]</sup> on the other hand panoramic imaging offer great valuable information about the full teeth set, supernumerary and missing teeth if present, which can provide hints about chronology and tooth eruption sequence.<sup>[9]</sup>

Aiming to save time, allowing flexible image adjustments, reducing the patient exposure to radiation, and allowing annotations and measurements to be made on the images; digital imaging is nowadays recommended for children owing to the aforementioned advantages.<sup>[11]</sup>

The current study aimed to digitally assess the association between dental and skeletal maturity by evaluating the correlation between dental maturity stages and CVMS.

## MATERIAL AND METHODS

The present retrospective study was conducted on digital standardized panoramic radiographs and lateral cephalograms obtained from 50 patients (24 males and 26 females) from outpatient clinic of Orthodontic Dentistry Department, Faculty of

Dentistry, Tanta University ,where it was ethically approved. The total sample size estimated for the study was 48 with statistical power of 90% at 5% significance level, based on a previous study <sup>[12]</sup>. All patients were healthy children at active growth period from 7 to 12 years with a mean age of 9.32y.

Inclusion criteria included availability of radiographs with adequate quality denoting the patient complete mandibular teeth set either erupted or unerupted. Exclusion criteria included any medical history affecting the teeth development, bony pathological condition, any missed mandibular permanent tooth except the wisdom ones and distorted radiographic images.

The radiographs were performed using the “FONA XPAN DG Plus” (FONA S.r.l, Galilei 11 - 20090 Assago, Italy) scanner. The scan specifications were as follows: CCD sensor Receptor technology, focal spot size (mm) 0.5, tube potential (kV) 79, tube current (mA) 8, and scan time (s) 8-12.

After the adjustment of the contrast and brightness of the digital panoramic and lateral cephalometric radiographs for optimum visual and assessment conditions using MicroDicom software version 3.9.5, dental and skeletal maturity assessment of all cases images was performed without any knowledge of neither age nor gender by a single observer.

For all the lateral cephalometric radiographs, **CVMS method** was used for skeletal maturity assessment with the tracing of the inferior border of C2 dense odontoid and body of the cervical vertebrae C3 and C4 using the free hand tool of the MicroDicom software **fig 1**, and scored on a six-level scale from cervical stage **CS1 to CS6**:<sup>[2]</sup>

**CS1:** The vertebrae lower borders are flat, with trapezoid shaped C3 and C4 bodies.

**CS2:** C2 body has a concave shaped lower border. C3 and C4 bodies are maintaining the trapezoid shape.



**CS3:** C2 and C3 bodies have a concave shaped lower border. C3 and C4 bodies may maintain the trapezoid shape or adapt a rectangular shape, where the growth peak starts a year after that.

**CS4:** All the mentioned vertebrae adapt bodies with concave lower borders, where the bodies of C3 and C4 are both rectangular in shape.

**CS5:** One or both of the C3 and C4 bodies is square in shape.

**CS6:** One or both of C3 and C4 bodies has large height/width ratio and denoting rectangular shape.

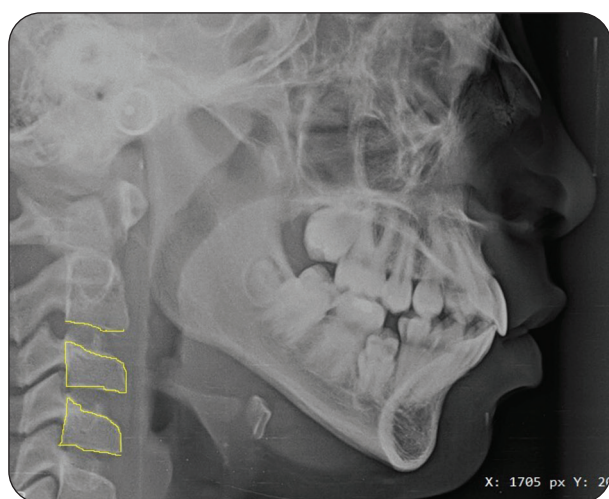


Fig. (1) Lateral cephalometric radiograph showing free hand tracing of the inferior border of C2 dense odontoid and body of C3 and C4 using MicroDicom software

For all the panoramic radiographs, **Demirjian** method was used for dental maturation assessment according to the calcification sequence of individual teeth.<sup>[13]</sup> where the cusp tip, CEJ and the formed root terminal end of the left mandibular canine, premolars, and second molars were reflected using red points, also tracing of the second molars pulp chamber and the root furcation area were performed using free hand tool of the aforementioned used software **fig 2**. Only the left side was used for standardization purposes, and dental maturation stages were rated on an 8-stage scale from **A to H**:

**A.** Calcification of occlusal single standing entities without fusion.

**B.** Fusion of the single calcified entities to form recognizable occlusal surface.

**C.** Completion of enamel formation, beginning of the dentin formation. There is no pulp horn obviously seen in the pulp chamber.

**D.** Crown development up to the cemento enamel junction level with beginning of the root formation. The pulp horns are beginning to distinguish, with curved pulp chamber wall.

**E.** Large crown/root ratio. More differentiated pulp horns with straight pulp chamber wall. Bifurcation area has started the mineralization in molar teeth.

**F.** Equal or slight small crown/root ratio, with triangle shaped pulp chamber wall. Bifurcation has differentiated to well recognized roots.

**G.** Well-formed parallel root walls with opened apex. Regarding the molars; the distal root was considered as a reference.

**H.** The root has been fully formed. Regarding the molars; the distal root was considered as a reference.

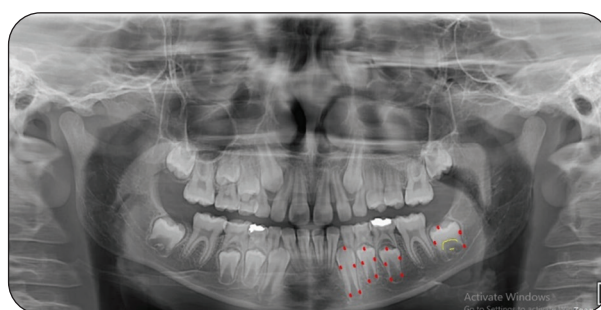


Fig.(2) panoramic radiograph showing red points reflecting the cusp tip, CEJ and the formed root terminal end of the left mandibular canine, premolars, and second molars. Yellow line reflecting the tracing of the second molars pulp chamber and the root furcation area using free hand tool of MicroDicom software

### Statistical analysis

Statistical analyses were performed using Statistical Package for Social Sciences (SPSS version 26). Gender and each CVMS mean age were calculated. Demirjian advancement stages (ordinal variable) and CVM method stages (ordinal variable) were designated as numbers. Pearman rank order correlation coefficient between CVM stages and advancement stages of each tooth entity was calculated to find the most correlated teeth. To find the frequently distributed tooth advancement phase in each cervical vertebra stage; Percentage distribution for both was calculated. The interexaminer reliability test indicated substantial agreement.

### RESULTS

Based on Demirjian and Bacetti et al. methods, respectively; fifty panoramic and lateral cephalogram images were assessed. Chronological age in the sample showed variation from 7 to 12 years, with a mean age of  $9.32 \pm 1.36$ . Assessment of CVM stages shown that except for CVMS 1; the mean chronological age of females was inferior than that of males, where the appearance of each maturation phase being consistently earlier in females than in males with a gap of half to one year. CVMS 3 coincides with the onset of pubertal age with a mean chronological age of  $10.20 \pm 2.05$  and  $10.78 \pm 0.97$  for females and males respectively. The highest frequency represented by CVMS 2, which was 50%. The rate of females was inferior than males in the first two stages. [Table 1] In the current study there is no patients scored as post pubertal stage (CVMS4- CVMS6) as age range was 7 to 12.

**N:** number **S.D:** standard deviation

Canine represented the lowest correlation between the involved teeth ( $r = 0.533$  and  $0.429$  for females and males, respectively). In the current study, the advancement of the lower 2<sup>nd</sup> premolar

represented the greatest correlation coefficient with CVM stages among male subjects ( $0.649$ ), while regarding females; the advancement of lower 1<sup>st</sup> premolar had the greatest correlation coefficient with CVM stages ( $0.720$ ). [Table 2].

**Table (1)** Distribution of cervical vertebral maturation stages through the chronological age

CVMS	Gender	N (%)	Age
			Mean $\pm$ S.D
Stage 1	Male	8(16%)	7.67 $\pm$ 0.58
	Female	3(6%)	8 $\pm$ 0.76
Stage 2	Male	13(26%)	9.50 $\pm$ 0.79
	Female	12(24%)	9 $\pm$ 0.82
Stage 3	Male	5(10%)	10.78 $\pm$ 0.97
	Female	9(18%)	10.20 $\pm$ 2.05
Total		50(100%)	9.32 $\pm$ 1.36

**Table (2)** Correlation between CVM and dental maturation stages of each individual tooth

Tooth	$r$	
	Male	Female
Canine	0.429*	0.533*
Second molar	0.548*	0.712*
First premolar	0.491*	0.720*
Second premolar	0.649*	0.615*

Regarding the distribution of dental maturation stages among different cervical vertebral maturation stages, CVMS 1 showed the least correlation with the dental maturation stages with a quite similar distribution among each individual tooth type, where dental maturation stage G and E showed the highest distribution among males and females respectively, and there is no distribution through stages D and H among female participants. Dental maturation stage F showed the highest correlation



with CVMS 2 and CVMS 3 among females and with CVMS 2 among males, where CVMS 2 showed the highest correlation with the dental maturation stages. Regarding CVMS 3, the distribution through stage D among male participants is greater than that of females. [Table 3]

There is a correlation between the dental maturation stage E of 2<sup>nd</sup> molar and CVMS 2 in males, while stage E of 2<sup>nd</sup> molar reflects the peak of puberty in females. There is a similar correlation regard-

ing the canine and 2<sup>nd</sup> molar stage F and E respectively and CVMS 2 in males, while stage F of the canine and 2<sup>nd</sup> molar reflect the highest correlation with CVMS 2 in females. Regarding 1<sup>st</sup> premolar; dental maturation stage F is correlated with CVMS 2 in males while in females stage F is correlated with the peak of puberty. On the other hand; there is a correlation between 2<sup>nd</sup> premolar dental maturation stage E and CVMS 2 in males, among females CVMS 2&3 mostly correlated with 2<sup>nd</sup> premolar dental maturation stages E&F. [Table 3]

**Table (3)** Distribution of dental maturation stages among different cervical vertebral maturation stages

CVMS	Calcification stage	Canine		M2		PM1		PM2	
		M	F	M	F	M	F	M	F
Stage 1	D	2(25%)	0(0%)	2(25%)	0(0%)	0(0%)	0(0%)	0(0%)	0(0%)
	E	0(0%)	2(66.7%)	0(0%)	2(66.7%)	2(25%)	1(33.3%)	2(25%)	1(33.3%)
	F	2(25%)	1(33.3%)	2(25%)	0(0%)	1(12.5%)	1(33.3%)	3(37.5%)	2(66.7%)
	G	3(37.5%)	0(0%)	4(50%)	1(33.3%)	3(37.5%)	1(33.3%)	1(12.5%)	0(0%)
	H	1(12.5%)	0(0%)	0(0%)	0(0%)	2(25%)	0(0%)	2(25%)	0(0%)
Stage 2	D	1(7.7%)	3(33.3%)	1(7.7%)	3(25%)	1(7.7%)	1(8.3%)	1(7.7%)	1(8.3%)
	E	1(7.7%)	0(0%)	8(61.5%)	2(16.7%)	1(7.7%)	2(16.7%)	6(46.1%)	4(33.3%)
	F	8(61.5%)	4(44.5%)	3(23.1%)	4(33.3%)	7(53.8%)	3(25%)	3(23.1%)	2(16.7%)
	G	2(15.4%)	1(11.1%)	1(7.7%)	3(25%)	4(30.8%)	4(33.3%)	3(23.1%)	3(25%)
	H	1(7.7%)	1(11.1)	0(0%)	0(0%)	0(0%)	2(16.7%)	0(0%)	2(16.7%)
Stage 3	D	2(40%)	1(11.1%)	1(20%)	0(0%)	1(20%)	0(0%)	1(20%)	0(0%)
	E	1(20%)	0(0%)	2(40%)	7(77.8%)	1(20%)	2(22.2%)	2(40%)	4(44.4%)
	F	1(20%)	3(33.3%)	1(20%)	1(11.1%)	2(40%)	5(55.6%)	1(20%)	4(44.4%)
	G	0(0%)	3(33.3%)	1(20%)	1(11.1%)	1(20%)	2(22.2%)	1(20%)	1(11.1%)
	H	1(20%)	2(22.2%)	0(0%)	0(0%)	0(0%)	0(0%)	0(0%)	0(0%)

**M2:** second molar

**PM1:** first premolar

**PM2:** second premolar

## DISCUSSION

Various studies investigated correlation between skeletal maturity and other growth indicators. However, fewer studies exploring correlation between skeletal and dental maturity indicators are accessible.<sup>[4,14,15]</sup> Therefore, a sample of Egyptian population in this study were investigated for correlation between the calcification stages of teeth and CVMS. In the current study we assessed the routinely used panoramic radiograph to anticipate the skeletal maturity stages as a substitute to other radiographic approaches in order to reduce radiation hazards and extra cost.

The review of literature exposed various studies in different populations which indicated a high, moderate or low correlation between each individual tooth and CVMS.<sup>[3,16,17]</sup> These studies reported that the correlation varies relative to ethnicity. To distinguish if skeletal maturity is related to dental maturity, specific population studies are needed. Our sample study included 26 males and 24 females. The sample chronological age distribution showed a variation ranged from 7 to 12 years, with a mean of  $9.32 \pm 1.36$ . At stage CVMS3, which represents the onset of puberty, the chronological age mean was  $10.78 \pm 0.97$  for males and  $10.20 \pm 2.05$  for females. This was earlier than previous records concerning the onset of pubertal growth spurt at other populations. For Indian residents, it was 13.2 at males and 11.8 at females in the study by Kiran et al 2011<sup>[18]</sup> while by Mittal et al 2009<sup>[19]</sup> it was 14.5 for males and 12.5 for females. In Chinese population, the mean chronologic age was  $11.60 \pm 1.44$  years in girls and  $12.73 \pm 0.81$  years in boys.<sup>[4]</sup>

There has been a debate about association between dental and skeletal maturity. Some studies reported high correlation between skeletal and dental maturity while others indicated the opposite.<sup>[20]</sup> According to researches on the correlation among the teeth, body, skeleton and secondary sexual characteristics, the best indicator for evaluating the stages of growth and development in the pubertal period was the dental maturity, where levels of calcification of teeth were considered to be important bio-

logic parameters in such evaluations.<sup>[21-23]</sup> Different methods for assessment of dental and skeletal age have induced discrepancies between studies. In the present study, the correlation between CVMS and dental maturation stages varied from 0.429 to 0.629 for males and from 0.533 to 0.72 for females. The highest correlation of 0.649 for males was found at mandibular second premolar, mandibular first premolar showed the highest correlation of 0.72 for females while the lowest correlation of (0.533 for females and 0.429 for males) was shown at mandibular canine where males had a lower correlation coefficient than females. Second molar had less correlation than first premolar in females however it was the opposite for males. These results are consistent with Mittal et al<sup>[19]</sup> study, the sequence in an Indian population was in males as (0.62) canine, (0.64) first premolar, (0.66) second premolar, and (0.75) second molar; the order in females was (0.65) canine, (0.78) first premolar, (0.79) second premolar, and (0.81) second molar, where the canine showed the lowest correlation. However, another study<sup>[4]</sup> at Chinese population, the tooth sequence for girls in order from the highest to lowest the correlation was second molar (0.528), first premolar (0.482), second premolar (0.454) and canine (0.391). The sequence for boys was canine (0.496), second premolar (0.491), second molar (0.467), and first premolar (0.464). Studies<sup>[24, 25]</sup> that reported low correlation between pubertal growth period and dental age had found that canine maturity was more nearly related to the puberty peak height velocity than other teeth. In the current study, the correlation between skeletal maturity indicator and canine was (0.533) at females and (0.429) at males. The correlation coefficient showed that second premolar had the highest relationship in females (0.72) and the first premolar for males (0.649). Other study<sup>[26]</sup> reported that mandibular second premolar developmental stages had the highest while canine had the lowest correlation with CVMS for both females and males. Mittal et al 2009<sup>[19]</sup> proposed stage G of second molar, first premolar and canine coordinated to pubertal growth peak in a study at Indian subjects on correlation between dental calcification stages and determination



of skeletal maturation using cervical vertebrae .

Gupta et al. 1995<sup>[27]</sup> showed that there is a significant correlation between the G stage of the canine and the peak of growth in females, but not in males, such that the apical has already formed at the peak of the pubertal growth .Some researchers<sup>[28, 29]</sup> pointed out that stage F correspond with the onset of the adolescent growth peak and stage G correspond with the canine eruption in the oral cavity and occurs 5 months before the peak of pubertal growth in women and 1 year before in men. According to Coutinho et al.1993<sup>[23]</sup>, the canine is in stage G, 1.3 years before the peak of pubertal growth in males and 0.4 years before in females. Krisztina et al. 2013<sup>[30]</sup> showed that CVMS was in stages 3 and 4 when the Demirjian index was in stage F.

The disparity among previous studies and this one could be due in part to the various methods utilized to estimate dental and skeletal maturity. The interrelation between skeleton and teeth appear to differ across ethnic / races groups and regional geography. In Africans, stage H during the growth period when the sesamoid bone has just appeared, the root apex of the canine is completely closed whereas at stage G the apical end is partially open in Europeans. Geographical differences at skeletal and tooth maturity have also been found between Midsouthern and Midwestern American adolescents.<sup>[14]</sup>

## CONCLUSION

There is a high correlation between the tooth calcification stages and CVM stages regarding the pediatric Egyptian patients, where CVM stage2- F dental maturation stage showed the highest correlation among both females and males. Female has advanced dental maturation age than male especially near the peak of puberty stage, this coincides with a retrospective study done in India by Syeda Arshiya et.al 2014 with the same conclusion<sup>[31]</sup>.

## REFERENCES

1. Perinetti G, Franchi L, Contardo L. Determination of timing of functional and interceptive orthodontic treatment: A critical approach to growth indicators. *Journal of the World Federation of Orthodontists*. 2017;6(3):93-7.
2. Baccetti T, Franchi L, McNamara Jr JA. An improved version of the cervical vertebral maturation (CVM) method for the assessment of mandibular growth. *The Angle Orthodontist*. 2002;72(4):316-23.
3. Uysal T, Sari Z, Ramoglu SI, Basciftci FA. Relationships between dental and skeletal maturity in Turkish subjects. *The Angle Orthodontist*. 2004;74(5):657-64.
4. Chen J, Hu H, Guo J, Liu Z, Liu R, Li F, et al. Correlation between dental maturity and cervical vertebral maturity. *Oral Surgery, Oral Medicine, Oral Pathology, Oral Radiology, Endodontology*. 2010;110(6):777-83.
5. Kumar S, Singla A, Sharma R, Viridi MS, Anupam A, Mittal B. Skeletal maturation evaluation using mandibular second molar calcification stages. *The Angle Orthodontist*. 2012;82(3):501-6.
6. Currier G, Riolo M. Orthodontic exam and diagnosis. *Essentials for orthodontic practice*. 2003:264-301.
7. Proffit WR, Fields HW, Msd DM, Larson B, Sarver DM. *Contemporary Orthodontics, 6e: South Asia Edition-E-Book*: Elsevier India; 2019.
8. Devereux L, Moles D, Cunningham SJ, McKnight M. How important are lateral cephalometric radiographs in orthodontic treatment planning? *American Journal of Orthodontics Dentofacial Orthopedics*. 2011;139(2):e175-e81.
9. Farman AG, editor *Panoramic radiographic assessment in orthodontics. Panoramic Radiology: Seminars on Maxillofacial Imaging and Interpretation*; 2007: Springer.
10. Liu N. Chronological age estimation of lateral cephalometric radiographs with deep learning. *arXiv preprint arXiv:11805*. 2021.
11. Ozdemir S, Parlakyıldız Gokce A, Unver T. Simulation of three intraoral radiographic techniques in pediatric dental patients: subjective comfort assessment using the VAS and Wong-Baker FACES Pain Rating Scale. *BMC Oral Health*. 2020;20(1):1-7.
12. Lund E, Tonje T. 2014 Relationship between dental age, skeletal maturity and chronological age in young orthodontic patients. Master's thesis, UiT Norges Arktiske University.

13. Demirjian A, Goldstein H, Tanner JM. A new system of dental age assessment. *Human biology*. 1973;211-27.
14. Krailassiri S, Anuwongnukroh N, Dechkunakorn S. Relationships between dental calcification stages and skeletal maturity indicators in Thai individuals. *The Angle Orthodontist*. 2002;72(2):155-66.
15. Grave K, Brown T. Skeletal ossification and the adolescent growth spurt. *American Journal of Orthodontics*. 1976;69(6):611-9.
16. Perinetti G, Contardo L, Gabrieli P, Baccetti T, Di Lenarda R. Diagnostic performance of dental maturity for identification of skeletal maturation phase. *The European Journal of Orthodontics*. 2012;34(4):487-92.
17. Rai B, Kaur J, Anand S, Jain R, Sharma A, Mittal S. Accuracy of the Demirjian method for the Haryana population. *Internet J Dent Sci*. 2008;6(1):1-4.
18. Sachan K, Sharma VP, Tandon P. A correlative study of dental age and skeletal maturation. *Indian Journal of Dental Research*. 2011;22(6):882.
19. Mittal S, Singla A, Virdi M, Sharma R, Mittal B. Correlation between determination of skeletal maturation using cervical vertebrae and dental calcification stages. *Internet J Forensic Sci*. 2009;4(2):1-9.
20. Demisch A, Wartmann P. Calcification of the mandibular third molar and its relation to skeletal and chronological age in children. *Child development*. 1956;459-73.
21. Kucukkeles N, Acar A, Biren S, Arun T. Comparisons between cervical vertebrae and hand-wrist maturation for the assessment of skeletal maturity. *Journal of clinical pediatric dentistry*. 1999;24(1):47-52.
22. Hedayati Z, Vafaei M, Heidari S. Relationship between chronological, dental and skeletal ages among 7- to 13-year-old children. *Journal of Dentistry*. 2009;10(1): 51-9.
23. Coutinho S, Buschang PH, Miranda F. Relationships between mandibular canine calcification stages and skeletal maturity. *American Journal of Orthodontics Dentofacial Orthopedics* 1993;104(3):262-8.
24. Różyło-Kalinowska I, Kolasa-Rączka A, Kalinowski P. Relationship between dental age according to Demirjian and cervical vertebrae maturity in Polish children. *The European Journal of Orthodontics*. 2011;33(1):75-83.
25. Franchi L, Baccetti T, McNamara Jr JA. Mandibular growth as related to cervical vertebral maturation and body height. *American Journal of Orthodontics Dentofacial Orthopedics*. 2000;118(3):335-40.
26. Mini MM, Thomas V, Bose T, Radiology. Correlation between dental maturity by Demirjian method and skeletal maturity by cervical vertebral maturity method using panoramic radiograph and lateral cephalogram. *Journal of Indian Academy of Oral Medicine*. 2017;29(4):362-7.
27. Gupta S, Chada M, Sharma A. Assessment of puberty growth spurt in boys and girls--a dental radiographic method. *Journal of the Indian Society of Pedodontics Preventive Dentistry*. 1995;13(1):4-9.
28. Demirjian A, Levesque G-Y. Sexual differences in dental development and prediction of emergence. *Journal of dental research*. 1980;59(7):1110-22.
29. Fernandes-Retto P, Matos D, Ferreira M, Bugaighis I, Delgado A. Cervical vertebral maturation and its relationship to circum-pubertal phases of the dentition in a cohort of Portuguese individuals. *Journal of Clinical Experimental Dentistry*. 2019;11(7): e642.
30. Krisztina MI, Ogodescu A, Réka G, Zsuzsa B. Evaluation of the skeletal maturation using lower first premolar mineralisation. *Acta Marisiensis-Seria Medica*. 2013;59(6):289-92.
31. Syeda Arshiya Ara, Vini Arora and Syed Zaka Ullah. Relationship between Dental Maturity and Cervical Vertebral Maturity in North Karnataka (India) Children.
32. A Hospital-based Retrospective Study. *Journal of Orofacial Research*, January-March 2014;4(1):35-40.







# الأزهر

## مجلة أسبوط لطب الأسنان

النشر الرسمي لكلية طب الأسنان  
جامعة الأزهر أسيوط  
مصر

AADJ, Vol. 6, No. 2, October (2023) — PP. 205

## العلاقة بين طرق التقييم الرقمي لنضج الأسنان والهيكل العظمي لدى مرضى أسنان الأطفال

عرفة محمد خطاب<sup>1\*</sup>, شيرين إبراهيم<sup>2</sup> وداليا أبو النور<sup>3</sup>.

1. أقسم طب أسنان الاطفال . كلية طب الأسنان. جامعة طنطا . مصر
  2. قسم تقويم الاسنان . كلية طب الأسنان ,جامعة الفيوم . مصر
  3. قسم أشعة الفم والوجه والفكين . كلية طب الأسنان . الجامعة الحديثة للتكنولوجيا والمعلومات. مصر
- \* البريد الإلكتروني: ALAASALATEIN.EL.8.1918@AZHAR.EDU.EG

### الملخص :

**الهدف:** كان الهدف من هذه الدراسة هو تقييم العلاقة بين مراحل نضج الأسنان و CVMS رقميًا.

**المواد والاساليب:** أجريت هذه الدراسة بأثر رجعي على الصور الأشعاعية الرقمية البانورامية والرأسية الجانبية التي تم الحصول عليها من 50 مريضًا من الأطفال (24 من الذكور و 26 من الإناث) في فترة نمو نشطة من 7 إلى 12 عامًا بمتوسط عمر 9.32 عامًا. تضمنت معايير الاشتغال توافر الصور الأشعاعية بجودة مناسبة تدل على أن مجموعة أسنان الفك السفلي كاملة للمرضى إما ظهرت في الفم أو لم تظهر. تضمنت معايير الاستبعاد أي تاريخ طبي يؤثر على نمو الأسنان. والحالة المرضية للعظام . وأي ضرس دائم في الفك السفلي مفقود باستثناء ضروس العقل والصور الشعاعية المشوهة.

**النتائج:** هناك علاقة ارتباط موجبة بين مراحل نضج الأسنان و CVM. كان للإناث معامل ارتباط أعلى من الذكور. بدأ أن مراحل نضج الأسنان. F و G و H . أكثر تكرارا وظهرت في وقت مبكر عند الإناث. في الدراسة الحالية: تقدم السن الضاحك الثاني للفك السفلي كان له أعلى معامل ارتباط مع مراحل نضوج فقرات عنق الرحم بين المشاركين الذكور (0.649). بين المشاركات الإناث: أظهر تقدم سن الضاحك الأول للفك السفلي أعلى معامل ارتباط مع (0.720). أظهرت مرحلة نضج الأسنان F أعلى ارتباط مع CVMS 2 بين الإناث والذكور.

**الخلاصة:** هناك علاقة ارتباط قوية بين مراحل تكلس الأسنان ومراحل CVM فيما يتعلق بالأطفال المرضى المصريين. حيث أظهرت المرحلة 2-F مرحلة نضوج الأسنان أعلى ارتباط بين الإناث والذكور.

**الكلمات المفتاحية:** نضج الأسنان : نضج الهيكل العظمي أسنان مختلطة طريقة ديمرجن