

The Protective Role of Nesfatin-1 on Fundic Mucosal Changes Induced by Acute Pancreatitis in Rats

Original
Article

Eman M. Mohamed, Samaa M. El-Mahroky and Enas G. Abd Allah

Department of Medical Histology and Cell Biology, Faculty of Medicine, Zagazig University, Egypt

ABSTRACT

Introduction: Acute pancreatitis (AP) is a sudden pancreatic inflammation that has a high mortality rate, especially when associated with systemic inflammation and multiple organ failure. According to reports, cases having acute pancreatitis developed stress ulcers or gastrointestinal mucosal lesions. Nesfatin-1 could control apoptosis and inflammatory effects.

Aim of the Work: This research is designed to find out the possible protective role of nesfatin-1 on fundic gland mucosal affection in cerulein-induced acute pancreatitis.

Materials and Methods: Forty rats were splitted into three groups: Group I (control), Group II (induced acute pancreatitis): exposed to cerulein (20 µg/kg, s.c.) five times each separated by one hour, Group III (nesfatin-1 treated): nesfatin-1 (10 µg/kg) is injected intraperitoneally 5 min before the first cerulein administration.

Results: Acute pancreatitis demonstrated high serum amylase, lipase, IL-1β, and oxidative stress marker (MDA) levels. Fundic gland histological changes secondary to pancreatic injury were confirmed by H&E, immunohistochemical (IL-1β, CD68), morphometrical, and statistical studies. The fundic glands of Group II showed mucosal disruption and desquamation of the surface epithelial cells. Cells had pyknotic nuclei and vacuolated cytosol aligned parts of the glands, while others were aligned by cells with flattened nuclei. Inflammatory cells were also seen. Many cellular infiltrations and engorged blood vessels were seen. Group III (nesfatin-1 treated) showed results similar to control group. Many fundic mucosal cells in the upper and lower parts had vesicular nuclei and few had darkly stained nuclei. The gastric pits appeared narrow.

Conclusions: Nesfatin-1 reduces pancreatic oxidative stress damage and reduces inflammation to decrease AP-induced fundic gland mucosal affection.

Received: 19 September 2023, **Accepted:** 21 November 2023

Key Words: Acute pancreatitis, cerulein, gastric fundic Mucosa, nesfatin-1.

Corresponding Author: Enas G. Abd Allah, PhD, Department of Medical Histology and Cell Biology, Faculty of Medicine, Zagazig University, Egypt, **Tel.:** +20 10 0282 7993, **E-mail:** baselmobasher1987@gmail.com

ISSN: 1110-0559, Vol. 47, No. 4

INTRODUCTION

Pancreatitis is a pancreatic inflammatory disease caused by pancreatic parenchyma dissolution from activated pancreatic enzyme leakage^[1]. It is fatal to 39% of cases^[2]. Numerous factors participate in its occurrence, including genetic, immunological, and metabolic factors. Also, alcohol abuse and pancreatic duct obstructions have been incriminated^[3]. Pancreatitis occurs in two types: acute and chronic types. Clinical manifestations of acute pancreatitis is typically limited to epigastric or right upper quadrant pain, but chronic pancreatitis can include abdominal discomfort along with signs and symptoms of pancreatic endocrine and exocrine insufficiency^[4]. Their morphological characteristics involve edema, acinar necrosis, infiltration of leucocytes, and intravascular microthrombi^[5].

The severe form can advance to microcirculation failure that lead to tissue damage in distant organs^[5]. No investigations can anticipate progression to severe form^[6]. According to reports, stress ulcers or gastrointestinal mucosal lesions (AGML) developed in 52% of individuals

with acute pancreatitis^[7]. Muddana *et al.*,^[8] explained these complications to occur due to the stressful situation arising in acute pancreatitis, which causes low blood perfusion and high hydrogen ion diffusion in gastric mucosa. These complications may happen from the inflammatory mediators and toxic substances present in the serum and ascetic fluid of AP^[9]. All these issues share in multiple organ dysfunctions in acute pancreatitis patients^[10].

Symptomatic treatments such as analgesics and fluid replacement are the helping trials in these cases^[11]. From this point, AP patients are at a significant risk of mortality. Therefore, urgent treatment must be taken to control the disease. In addition, methods for the prevention of the disease and support body systems are very important. Animal models are used to test the efficacy of these methods. Cerulein is a cholecystokinin analog extracted from frog *Litoria cerulea* tree. It is utilized in experimental research to induce acute or chronic pancreatitis^[12].

Cerulein induces early proteolysis of pancreatic zymogens, activating trypsin and other proteolytic enzymes to digest the pancreatic tissue^[13].

Nesfatin is an amino-acid that contributes to the nucleobinding-2 (NUCB2) amino-terminal fragment. Nesfatin-1 was recognized in rats, hypothalamus as a powerful anorexigenic agent. Its precursor amino acid, NUCB2, when broken down yields three distinct components called nesfatin-1, nesfatin-2, and nesfatin-3^[14]. Nesfatin-1 is discovered in gastric oxyntic mucosal cells with 20-fold greater than its presence in the brain. Nesfatin-1, according to the study's findings, controls gastrointestinal functioning and motility^[15].

Nesfatin-1/ NUCB2 immunoreaction was additionally seen in islets of pancreatic tissue and act a role in the regulation of blood glucose as it promotes insulin release and is almost involved in insulin resistance^[16]. Beside its anorexigenic role, nesfatin-1 can control inflammation and apoptosis^[17]. It regulates sleep, stress, and glucose homeostasis in liver^[18]. It was discovered that AP had lower serum values of nesfatin-1 due to the high oxidative and inflammatory states^[6].

To our knowledge, the relationship between AP and nesfatin is limited to very few studies. Accordingly, we aimed in this work to study the impact of nesfatin-1 in preventing gastric tissue damage after cerulein-induced acute pancreatitis.

MATERIALS AND METHODS

Study animals

Forty male adult albino rats (12–14 weeks, 180–200 g) were held in plastic cages in the Animal holding of the Faculty of Medicine, Zagazig University, Egypt. Animals were kept in a controlled environment; artificial light/dark cycle, temperature and humidity. Animals had ad libitum get of food and water. Rats were cared in accordance with Ethical Committee guidelines from Zagazig University and Guide for the Use and Care of Laboratory Animals. The experimental protocol was accepted by the Medical Research Ethics Committee of the Faculty of Medicine, Zagazig University, Egypt (ZU-IACUC/3/F/192/2023).

Chemicals

Nesfatin-1 and cerulein were obtained from Sigma (Sigma-Aldrich Co. LLC, Germany). All drugs were freshly dissolved in 0.9% sterile saline.

Experimental design

Forty rats were splitted into three major groups:

Group I (control group): Includes twenty-four animals that were splitted into three minor subgroups (8 rats each),

- Subgroup1a (Negative control group): got no treatment.
- Subgroup1b: (vehicle control group): was subcutaneously administered five saline injections with 1-hour intervals to complete the whole dose 50µg/kg^[6].

- Subgroup1c: was given nesfatin-1 (10 µg/kg) intraperitoneally^[19].

Group II (induced acute pancreatitis group): eight rats were injected subcutaneously with five cerulein injections at 1-hour intervals to complete the whole dose (100µg/kg)^[6].

Group III (nesfatin-1 treated group): eight rats were injected with nesfatin-1 (10 µg/kg) intraperitoneally 5 min before the first cerulein injection^[19].

Biochemical analysis

Retro-orbital blood samples were taken in capillary tubes prior to scarification. Serum lipase, amylase, IL-1β and the oxidative stress marker malondialdehyde (MDA) levels were tested using ELISA. From Spinreact Inc. (France), kits for amylase and lipase enzymes were purchased, and IL-1β kits were gotten from (Biosource International, Nivelles, Belgium), and MDA from (Biodiagnostic Co., Cairo, Egypt). Increased serum lipase and amylase three times more than the control are indicator of AP^[4].

Light and immunohistochemical study

Sampling

Twelve hours following the last administration of cerulein, rats were sacrificed by receiving pentobarbital (40 mg/kg, ip). Each animal's fundic mucosa were carefully removed, and then submerged in formol saline 10% for 48 hours to prepare 5 µm thick paraffin slices, that were stained to show the histological details^[20].

The same previous steps were done on the pancreas and the sections were stained with H & E to ensure the effect of cerulein on the pancreatic tissue.

Immunohistochemical staining was achieved for the localization of cluster of differentiation 68 (CD68) (Cat. No. MA5-13324, Lab Vision, Fremont, USA) diluted 1:200 in PBS and IL-1β (BA2782; 1:100; Wuhan Boster Biological Technology, Ltd., Wuhan, China) antibodies.

CD68 protein is a marker for monocytes and macrophages predominantly. These cells are the corner stones in defending against any bacteria or antigens. While, IL-1β is pro-inflammatory cytokine.

Avidin-biotin-peroxidase complex method was implemented. Processing of the paraffin slices, detaching endogenous peroxidase, blocking nonspecific attachment, covering sections with the needed primary and secondary antibodies (biotinylated), and labelling with horseradish peroxidase to sections were accomplished. Brown staining appears at the antigen site (the cytoplasm of the macrophages in anti-CD68+ and the cytoplasm of fundic glands' cells especially the parietal cells in anti-IL-1β sections^[21,22].

Morphometric study

Ten distinct zones from each section of each animal

group were subjected to semiquantitative microscopical analysis at 400 magnifications. The area % of anti-CD68+ and IL-1 β immunoreactivity was measured. Measures were all obtained at 400 magnifications.

Statistical analysis

ANOVA test in SPSS was accomplished to analyze the data. *P* value lower than 0.05 is significant^[23].

RESULTS

Biochemical results

A highly significant rise in the serum lipase and amylase, IL-1 β , and MDA values relating group II (induced acute pancreatitis) to control, and nesfatin-1 treated groups ($p < 0.001$). A non-significant change existed between control, and nesfatin-1 treated groups ($p > 0.05$) (Table 1).

Histological results

Data collected from all control subgroups (Ia, Ib, and Ic) were close to each other; hence subgroup (Ia) data were chosen for comparison with other groups.

H & E stained results

On checking slides from the pancreas of group I (control group), it showed acinar cells that appeared pyramidal; their base rested on the basal lamina, separating them from the connective tissue. The nuclei were round and basally located, surrounded by basophilic cytoplasm. Also, the cells had characteristic apical acidophilia (Figure 1a). Group II (induced acute pancreatitis group) showed interstitial edema and cellular infiltration (Figure 1b), small dark nuclei and engorged blood vessels (Figure 1c).

H & E stained fundic gland slides of group I (control group) showed that fundic mucosa was aligned by mucous surface cells having oval basal nuclei and mucous neck cells. The gastric pits appeared narrow (Figure 2a). Round nuclei and eosinophilic cytosol were features of parietal cells (Figure 2b). The bottom of the glands displayed parietal cells with eosinophilic cytosol and central nuclei. Columnar chief cells had basal round nuclei and basophilic cytosol (Figure 2c).

The upper fundic gland component of group II (induced acute pancreatitis) showed mucosal disruption

and desquamation of the surface epithelial cells into lumina. Dilated fundic gastric glands and wide gastric pits were seen. Cells with pyknotic nuclei and vacuolated cytoplasm aligned many glands, while others were aligned by cells with flattened nuclei. Inflammatory cells and extravasation of blood were also seen (Figures 3 a,b). Vacuolated cytoplasm of the damaged cells of the fundic glands and shrunken pyknotic nuclei were observed (Figure 3c). The lower component of the fundic glands was also aligned by cells with darkly stained nuclei and cytoplasmic vacuolations. Many cellular infiltrations and engorged blood vessels with extravasated blood were seen (Figure 3d). Parietal and chief cells appeared having vacuolations and dark nuclei (Figure 3e).

Inspection of H & E stained slides of group III (nesfatin-1 treated) showed results nearly similar to group I. Several fundic mucosal cells in the upper and lower parts had vesicular nuclei and few had darkly stained nuclei. The gastric pits appeared narrow. Engorged blood vessels, and extravasation of blood were seen (Figures 4 a,b).

Immunohistochemical results

CD68 immunostaining displayed few brown positive immunoreaction in macrophages' cytoplasm in group I (Figure 5a), while in group II (induced acute pancreatitis group), strong positive cytoplasmic immunoreaction was seen in many macrophage cells (Figures 5 b,c). A few macrophages from group III (nesfatin-1 treated group) exhibited few brown positive cytoplasmic immunoreaction for CD68 (Figure 5d).

In the control group, IL-1 β immunostaining revealed positive cytoplasmic immunoreaction (Figure 6a), while in group II (induced acute pancreatitis group), strong positive IL-1 β cytoplasmic immune presentation was seen in several cells, especially the parietal cells (Figure 6b). A few cells from group III (nesfatin-1 treated group) exhibited positive cytoplasmic immunoreaction for IL-1 β (Figure 6c).

Morphometric and statistical results

Statistical analysis of anti-CD68+ and anti-IL-1 β area percent displayed a highly significant rise relating group II with groups I and III ($p < 0.001$). A Non-significant alteration noticed when relating group III to group I ($p > 0.05$) (Table 2).

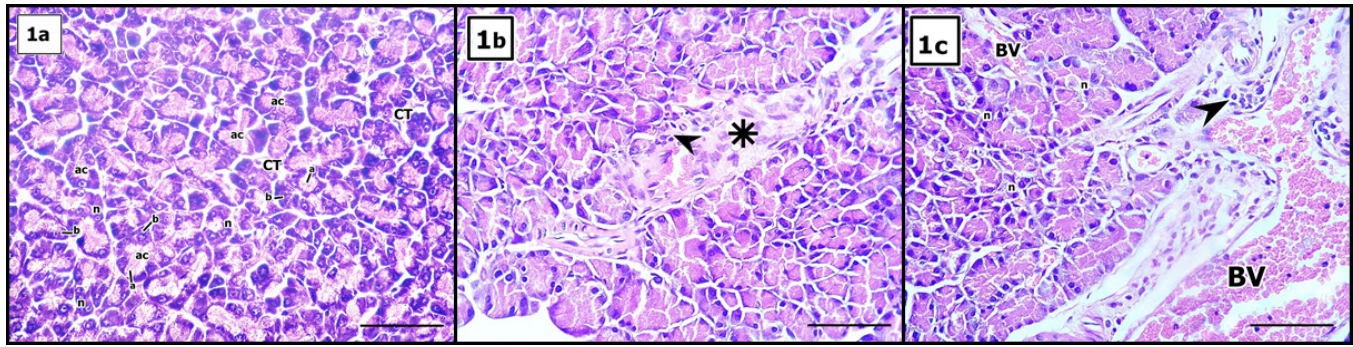


Fig. 1: Photomicrographs of H & E stained pancreatic sections of group I (control group) showing (a) pyramidal acinar cells (ac) with characteristic apical acidophilia (a) and basal basophilia (b) lying on the basal lamina, separating them from the connective tissue (CT). The nuclei (n) are round and basally located. (b): Group II (induced acute pancreatitis group) showing interstitial edema (asterisk) and cellular infiltration (arrowhead). (c): Another section reveals small dark nuclei (n), cellular infiltration (arrowhead), and engorged blood vessels (BV) (Scale Bar X40 μ m, H& E X 400).

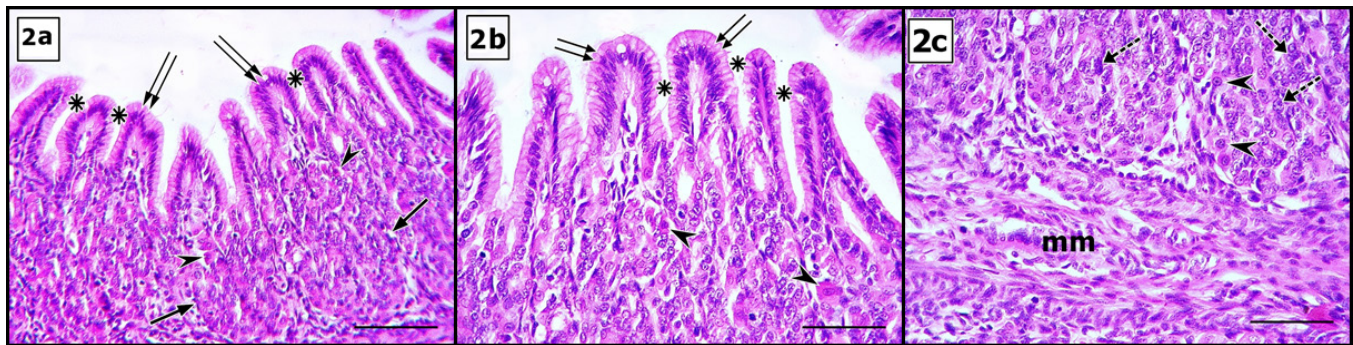


Fig. 2: Photomicrographs of H & E stained fundic mucosal sections of the control group showing (a): the upper part of fundic glands with the surface mucous cells having oval basal nuclei (double arrow) and the mucous neck cells (arrow). Parietal cells contain rounded nuclei and eosinophilic cytosol (arrowhead). The gastric pits appear narrow (asterisks). (b): more magnification of the upper fundic glands showing narrow gastric pits (asterisks) and surface mucous cells with oval basal nuclei (double arrow). Parietal cells contain rounded nuclei and eosinophilic cytosol (arrowheads). (c): The lower part of fundic glands shows parietal cells having rounded nuclei and eosinophilic cytosol (arrowheads). Low columnar chief cells contain basal rounded nuclei and basophilic cytosol (knotted arrows). Notice: the muscularis mucosa (mm) (Scale Bar X40 μ m, H&E X 400).

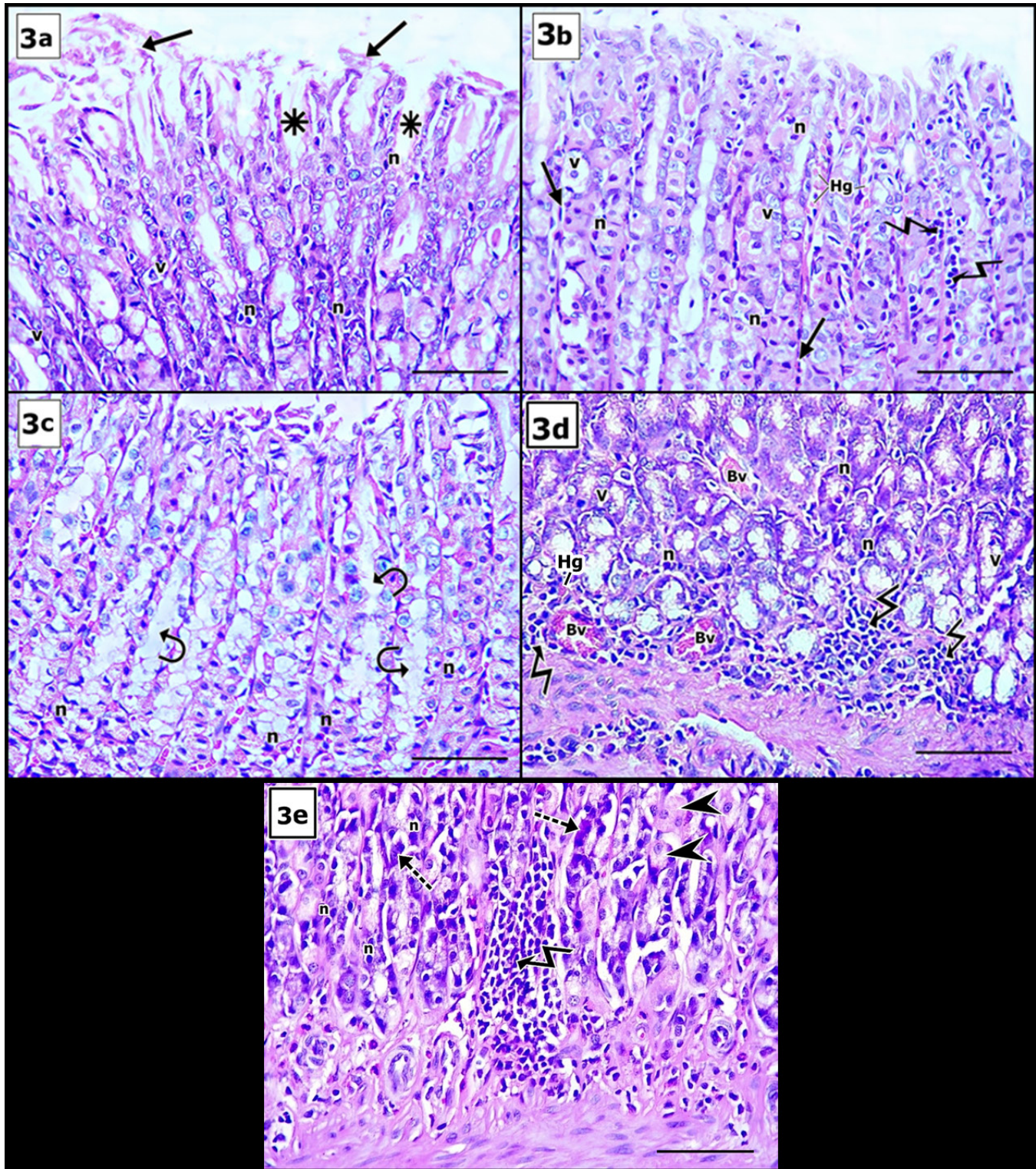


Fig. 3: Photomicrographs of H & E stained sections of the upper section of the fundic glands of group II (induced acute pancreatitis) showing (a) desquamation of the surface epithelial cells (arrows) and wide gastric pits (asterisk). Cells have pyknotic nuclei (n) and vacuolated cytosol (v). (b) Fundic glands are aligned by cells with darkly stained nuclei (n) and vacuolated cytosol (v), while others have changed cellular and nuclear morphology to flat shape and flat nuclei (arrows). Notice: Inflammatory cells (zigzag arrows) and extravasation of blood (Hg) (c): Vacuolated cytoplasm of the damaged cell of the fundic glands (curved arrows) and shrunken pyknotic nuclei (n) are noticed (d): Fundic glands are aligned by cells with darkly stained nuclei (n) and vacuolations of the cytosol (v). Engorged blood vessels (Bv) with blood extravasation (Hg) and cellular infiltrations (zigzag arrows). (e): vacuolated parietal cells (arrowheads), chief cells with darkly stained nuclei, and basophilic cytoplasm (knotted arrows). Other cells having darkly stained nuclei (n) and many cellular infiltrations (zigzag arrow) are observed (Scale Bar X40 μ m, H&E X 400).

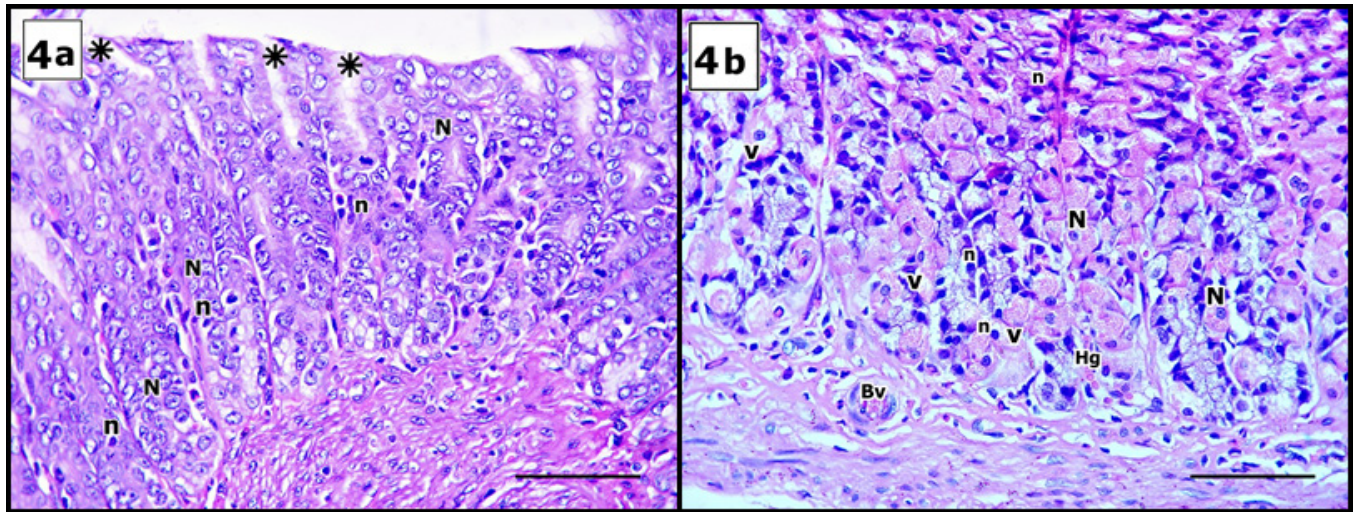


Fig. 4: Photomicrographs of H & E stained tissues of the fundic glands of group III (nesfatin-1 treated group) showing (a) fundic mucosal cells in the upper part and (b) in the lower part have vesicular nuclei (N) with few darkly stained nuclei (n). The gastric pits appear narrow (asterisks). (b): Some cells in the lower part reveal darkly stained nuclei (n) and vacuolations of the cytoplasm (v), and others with vesicular nuclei (N) and eosinophilic cytoplasm. Notice engorged blood vessels (Bv) and extravasation of blood (Hg) (Scale Bar X40 μ m, H&E X 400).

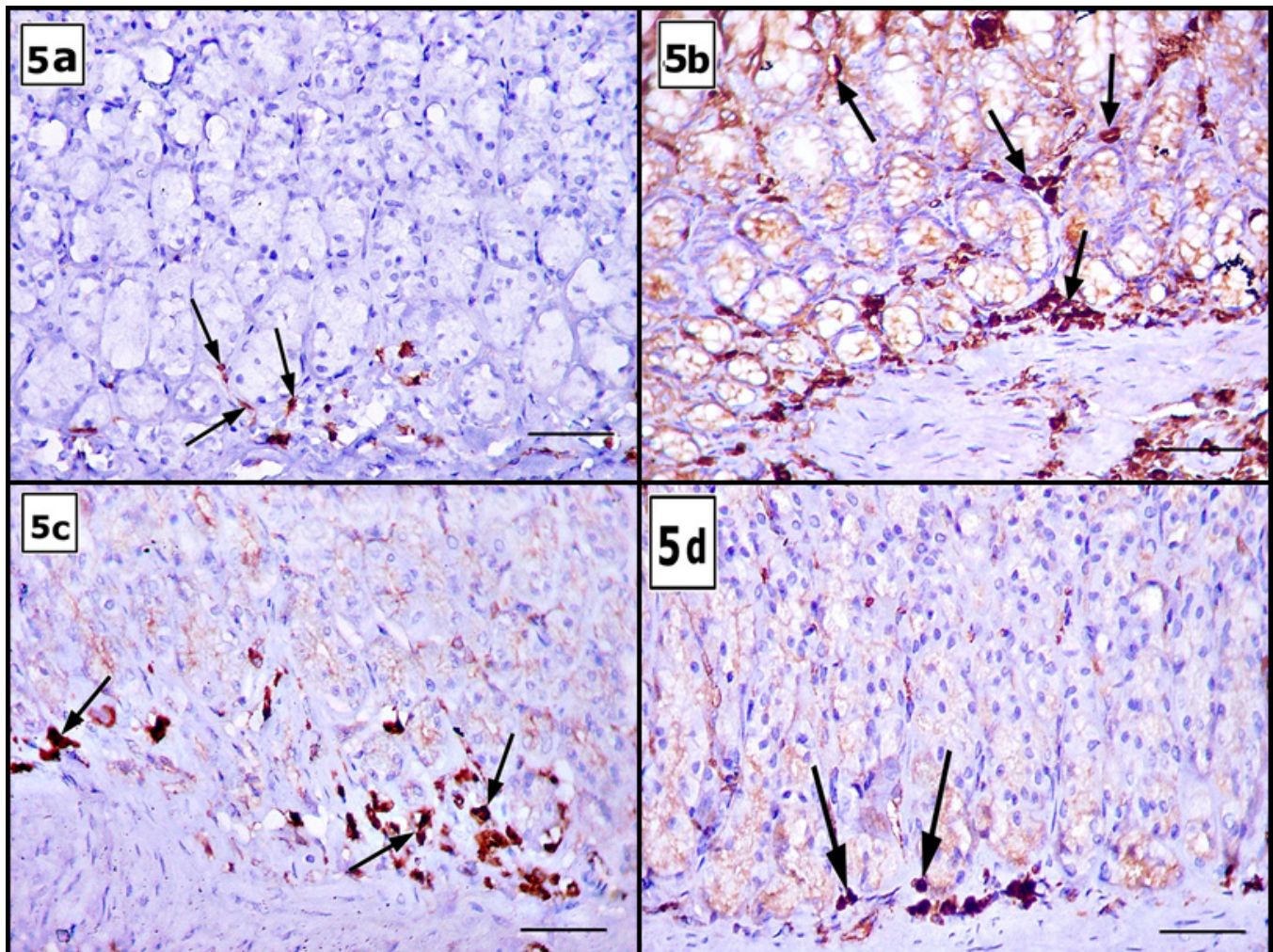


Fig. 5: Photomicrographs of CD68 immunohistochemical stained tissues: (a): the control group displays some positive immunoreaction in the cytoplasm of the macrophage (arrows). (b, c): Group II shows strong positive cytoplasmic immunoreaction in many macrophages (arrows). (d): A small number of macrophages from group III exhibit few positive cytoplasmic immunoreaction (arrows) (Scale Bar X30 μ m, CD68 immunohistochemical X 400).

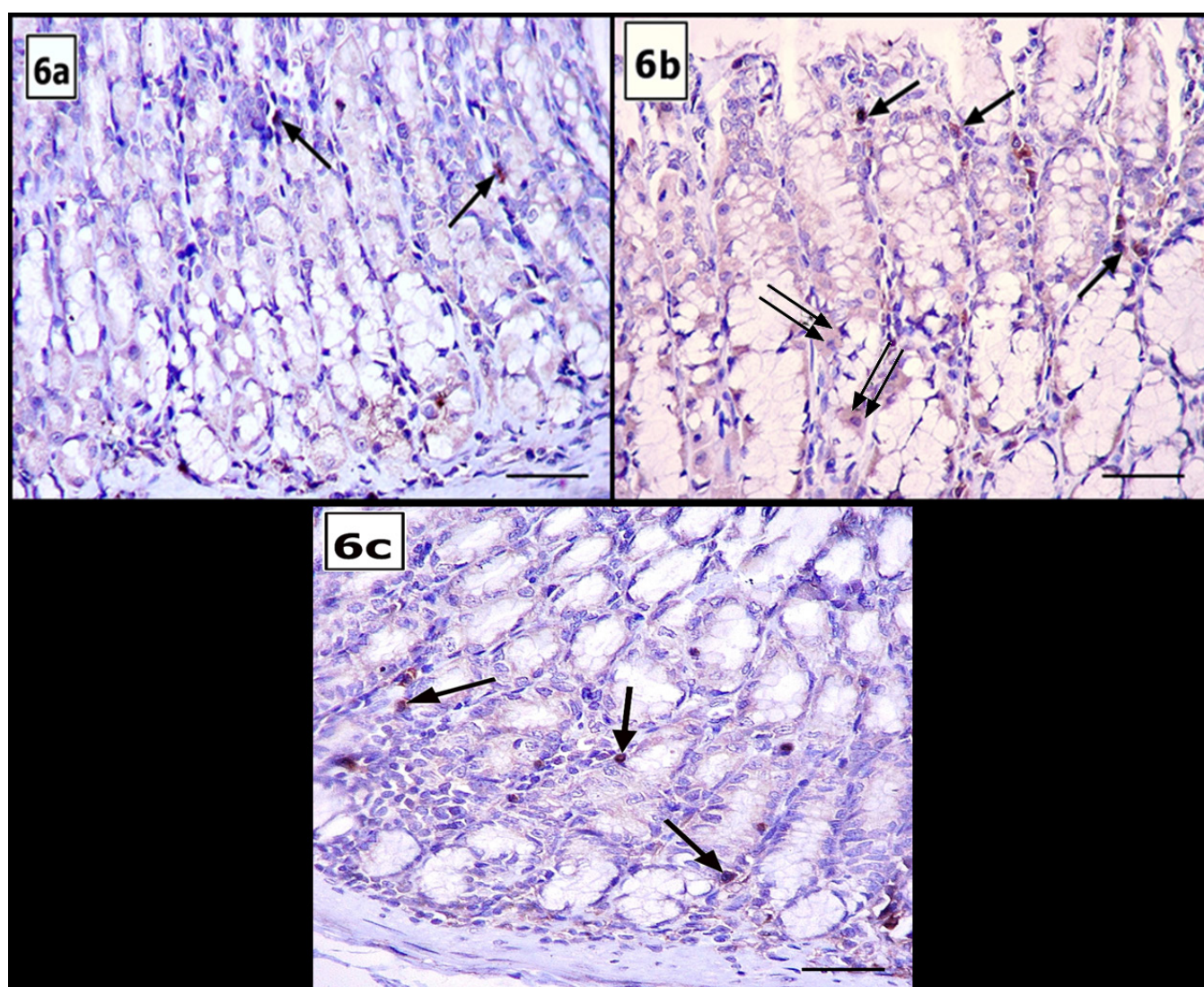


Fig 6: Photomicrographs of IL-1 β immunohistochemical stained tissues: (a) the control group reveals positive immunoreaction in the cytoplasm (arrows). (b): Group II shows strong positive cytoplasmic immunoreaction in many cells (arrows), especially the parietal cells (double arrows). (c): A small number of cells from group III exhibit positive cytoplasmic immunoreaction (arrows) (Scale Bar X30 μ m, IL-1 β immunohistochemical X 400).

Table 1: Comparison between serum amylase, lipase, IL-1 β and MDA of different groups:

Groups	Group I (control group)	Group II (induced acute pancreatitis)	Group III (nesfatin group)
Amylase (U/L)	569 \pm 40.7	1039.9 \pm 33.6 ^{a,b}	602 \pm 47.8 ^{NS}
Lipase (U/L)	147 \pm 31.6	335 \pm 30.1 ^{a,b}	176 \pm 23.7 ^{NS}
IL-1 β (pg/mL)	9.5 \pm 1.24	56.21 \pm 3.70 ^{a,b}	12.03 \pm 1.27 ^{NS}
MDA (nmol/ ml)	57.1 \pm 3.12	175,9 \pm 23.69 ^{a,b}	64 \pm 4.85 ^{NS}

Values are presented as mean \pm standard deviation (SD)

^a Highly significant difference relating group II to group I (p <0.001).

^b Highly significant difference relating group II to group III (p <0.001).

^{NS} Non-significant difference relating group III to group I (p >0.05)

Table 2: Comparison between the mean areas % of anti CD68+ and anti-IL-1 β in different groups

Groups	Group I (control group)	Group II (experimentally induced acute pancreatitis)	Group III (nesfatin-1 treated group)
CD68+	2.70 \pm 0.95	16.07 \pm 0.56 ^{a,b}	3.41 \pm 0.85 ^{NS}
IL-1 β	0.34 \pm 0.15	4.80 \pm 0.78 ^{a,b}	0.69 \pm 0.22 ^{NS}

Values are presented as mean \pm standard deviation (SD)

^a Highly significant difference relating group II to group I ($p < 0.001$).

^b Highly significant difference relating group II to group III ($p < 0.001$).

^{NS} Non-significant difference relating group III to group I ($p > 0.05$)

DISCUSSION

Multiple organ failure is the hardest catastrophe of acute pancreatitis, in which the gut is significantly impacted^[24]. Research showed that acute pancreatitis was associated with peptic ulcer, mainly in the stomach (67%) and acute gastrointestinal mucosal lesions^[25,7].

Most acute pancreatitis patients are often complicated with AGML or stress ulcers. This ulcer comes from increased gastric acid production due to inflammatory stress activating the hypothalamic-pituitary-adrenal cortex pathway leading to increased glucocorticoid and catecholamines hormones secretion. Also, these stimulated hormones cause gastrointestinal mucosal ischemia due to blood flow shifting. This ischemia has a role in decreasing gastric pH and activating protease, and consequent ulceration^[8].

In this present study, a highly significant increase in the serum amylase, lipase, IL-1 β , and serum malondialdehyde (MDA) values were reported when relating group II to group I ($p < 0.001$). Similar findings were reported by Buzcu *et al.*^[19], who attributed these results to successful acute pancreatitis induction.

Serum interleukin IL-1 β level was elevated in cerulein-induced acute pancreatitis group, which agreed with Ozkan *et al.*^[26]. Ueda *et al.*^[27] mentioned that interleukin IL-1 β was released in an early stage of AP. It excited phospholipase A-1 expression and caused monocyte vascular migration to the place of the lesion which released nitrous oxide and ROS, which are intermediaries of the acute gastrointestinal mucosal lesion (AGML) and gastric ulceration.

Also, Chan and Leung^[5] and Bakoyiannis *et al.*^[28] stated that damaged acinar cells emitted cytokines that stimulated the complement system, platelets, and neutrophil attraction. Pro-inflammatory cytokines like TNF- α and IL-1 β were up-regulated during pancreatitis, and they are crucial in emergence of polymorphonuclear leukocytes as well as the creation of several symptoms of acute pancreatitis. The current investigation found that cerulein significantly raised the serum level of IL-1 β , indicating a systemic inflammatory response.

MDA is increased in this study which follow Akyuz *et al.*^[29] and Ozkan *et al.*^[30]. Buzcu *et al.*^[19] reported that activated neutrophils release reactive oxygen, which, with increased myeloperoxidase (MPO) and MDA played a role

in oxidant damage with acute pancreatitis. Eamlamnam *et al.*^[31] and Laine *et al.*^[32] reported increased endothelin in vascular gastric endothelium which weakened the mucosa and caused its damage by hydrochloric acid.

H & E stained results of the pancreas in group II (induced acute pancreatitis group) showed characters of pancreatic affection and inflammation as interstitial edema, cellular infiltration, small dark nuclei and engorged blood vessels.

Cerulein, an equivalent of cholecystokinin (CCK) that functions by activating CCK receptors, causes acinar cells to be overstimulated, which in turn causes trypsinogen to be prematurely activated. This is followed by lysosomal breakdown of intracellular organelles within acinar cells' autophagic vacuoles and pronounced interstitial edema. In the early stages of acinar cell injury, premature activation of digestive enzymes in the acinar cell and their retention are thought to be crucial^[5].

In this study, histopathological results of acute pancreatitis-induced gastric lesion revealed mucosal disruption and exfoliation of the surface epithelial cells into lumina. Dilated fundic glands and wide gastric pits were observed. These findings concur with those of Ibrahim *et al.*^[33], who explained the mucosal disturbance as mucosal ulceration. They added that these ulcer sites might be favorable places for bacterial invasion. Fujimura *et al.*^[34] mentioned that stress decreased prostaglandin E2, which in turn decreased mucus secretion, allowing pepsin and hydrogen to diffuse into the mucosa, causing connective tissue damage and erosion of capillaries leading to mucosal hemorrhage^[35].

The current study demonstrated degenerated glands. Their degenerated cells appeared either with pyknotic nuclei or changed cellular and nuclear morphology to flat shape. Some researchers attributed gastric mucosal atrophy to decreased gastrin hormone secretion, which significantly controls gastric growth^[36].

Strong positive and highly significant elevation in area % of cytoplasmic immunoreaction in many macrophages in group II relative to groups I and III ($p < 0.001$) was reported. CD68 protein is a marker for monocytes and macrophages predominantly, and also for neutrophils, and large lymphocytes. These cells are the corner stones in defending against any bacteria or antigens reach the

epithelium^[37]. They release pro-inflammatory cytokines, attracting leukocytes toward the lesion sites^[38,39]. These leukocytes also release and activate inflammatory mediators beside cytotoxic enzymes such as prostaglandin E2 (PGE2) and leukotrienes B4 (LTB4), myeloperoxidase, proteases, and elastase which aggravate more inflammation and destruct the capillary endothelial barrier causing capillary leakage^[40]. This was in line with the findings of the current study. Blood leakage manifests grossly by retroperitoneal edema, ascites, and intraabdominal hypertension that may affect the perfusion of other organs^[41]. Finally, excess leukocyte attraction at the site of the lesion causes venous occlusion^[42].

Also, IL-1 β immunohistochemical results showed strong positive and highly significant elevation in area % of cytoplasmic immunoreaction in group II relative to groups I and III ($p < 0.001$). Increasing IL-1 β value proves the inflammation occurrence and stimulates infiltration of several cells as T lymphocytes^[43].

The nesfatin-1 treated group showed near normal appearance of gastric mucosa. This was similar to what was seen endoscopically by Baez *et al.*^[44]. They also found that nesfatin-1 protected the mucosa by preventing the depletion of gastric SOD and GSH and inhibited the production of MDA. It decreased secretion of HCL and increased gastric mucosal blood flow^[45].

Nesfatin-1 importance is not only incorporated in saving gastric tissue but also regulates glucose homeostasis, insulin secretion, and whole gut motility due to its presence in β -cells of the islets of Langerhans^[46,47].

Decreased inflammation and apoptosis in this group (group III) goes hand in hand with Xu and Chen^[17], who reported that nesfatin-1 could control apoptosis and inflammation. It prevents neutrophil recruitment to tissues by suppressing myeloperoxidase (MPO) by interaction with melanocortin receptors^[19]. It prevented hepatocyte necrosis in the study of Solmaz *et al.*^[48].

In the current study, the administration of nesfatin-1 restored the normal CD68-positive immunoreaction confirms that nesfatin-1 may enhance the immunoprotective function of the fundic mucosa.

Nesfatin-1 is implicated in lipid metabolism through decreasing triglyceride and cholesterol levels^[49]. Its antioxidant role in preventing tissue damage is seen in enhancing GSH levels and suppressing MDA in this work and other research^[19]. It also inhibits endothelial nitric oxide production and heal gastric ulceration^[50].

Nesfatin-1 can protect cellular structure affected by oxidative stress. The most susceptible proteins to oxidative damage are proteins with sulphur and carbonyls^[51]. The different radicals have multiple cellular attack sites generating different protein and cellular structure, folding and charge and also lipid peroxidation of the cell membranes which inhibit cellular functions as enzymatic actions, cross linking and aggregation leading finally to cellular degeneration^[52,53].

CONCLUSION

Nesfatin-1 modifies AP-induced fundic gland mucosal affection by reducing pancreatic oxidative stress damage and inflammation.

CONFLICT OF INTERESTS

There are no conflicts of interest.

REFERENCES

1. Mederos MA, Reber HA, Girgis MD. Acute pancreatitis: A review. *JAMA*, 2021; 325(4):382-390. doi:10.1001/jama.2020.20317.
2. Bugiantella W, Rondelli F, Boni M, Stella P, Polistena A, Sanguinetti A, Avenia N. Necrotizing pancreatitis: A review of the interventions. *International journal of surgery*, 2016; 28, S163-S171. doi.org/10.1016/j.ijso.2015.12.038.
3. Khokhar AS, Seidner DL. The pathophysiology of pancreatitis. *Nutr Clin Pract*, 2004; 19: 5-15. doi.org/10.1177/011542650401900105.
4. Ashraf H, Colombo JP, Marcucci V, Rhoton J, Olowoyo O. A clinical overview of acute and chronic pancreatitis: the medical and surgical management. *Cureus*, 2021; 13 :(11). doi: 10.7759/cureus.19764.
5. Chan YC, Leung PS. Acute pancreatitis: animal models and recent advances in basic research. *Pancreas*, 2007; 34: 1-14. doi: 10.1097/01.mpa.0000246658.38375.04.
6. Ferlenguez AG, Tatar C, Degerli MS, Koyuncu A, Ahlatci FA, Nayci AE, Idiz UO. The role of serum nesfatin-1 in a rat model of acute pancreatitis. *Advances in Clinical and Experimental Medicine: Official Organ Wroclaw Medical University*, 2022. doi:10.17219/acem/156141.
7. Lee KM, Paik CN, Chung WC, Yang JM. Association between acute pancreatitis and peptic ulcer disease. *World J Gastroenterol*, 2011; 17: 1058–1062. doi: 10.3748/wjg.v17.i8.1058.
8. Muddana V, Whitcomb DC, Khalid A, Slivka A, Papachristou GI. Elevated serum creatinine as a marker of pancreatic necrosis in acute pancreatitis. *Am J Gastroenterol*, 2009; 104: 164-170 . doi: 10.1038/ajg.2008.66.
9. Ramudo L, Manso MA, De Dios I. Biliary pancreatitis-associated ascetic fluid activates the production of tumor necrosis factor-alpha in acinar cells. *Crit Care Med*, 2005; 33: 143-148. doi: 10.1097/01.CCM.0000150654.13653.5B
10. Li YY, Lu XY, Li XJ, Li YN, Li K, *et al.* Intervention of pyrrolidine dithiocarbamate and tetrandrine on cellular calcium overload of pancreatic acinar cells induced by serum from rats with acute pancreatitis. *J Gastroenterol Hepatol*, 2009; 24: 155–165. doi.org/10.1111/j.1440-1746.2008.05592.x

11. Kiriya S, Gabata T, Takada T, Hirata K, Yoshida M, Mayumi T, *et al.* New diagnostic criteria of acute pancreatitis. *J Hepatobiliary Pancreat Sci.* 2010;17(1):24–36. doi: 10.1007/s00534-009-0214-3.
12. Aghdassi AA, Mayerle J, Christochowitz S, Weiss FU, Sendler M, Lerch MM. Animal models for investigating chronic pancreatitis. *Fibrogenesis & tissue repair*, 2011; 4(1), 26. doi.org/10.1186/1755-1536-4-26.
13. Dur A, Kose H, Kocyigit A, Kocaman O, Ismayilova M, Sonmez FC. The anti-inflammatory and antioxidant effects of thymoquinone on caeruleine induced acute pancreatitis in rats. *Bratisl Lek Listy*, 2016; 117: 614-618. doi: 10.4149/bll_2016_119.
14. Oh-I S, Shimizu H, Satoh T, *et al.* Identification of nesfatin-1 as a satiety molecule in the hypothalamus. *Nature* 2006; 443: 709-712. doi.org/10.1038/nature05162.
15. Stengel A, Goebel M, Yakubov I, *et al.* Identification and characterization of nesfatin-1 immunoreactivity in endocrine cell types of the rat gastric oxyntic mucosa. *Endocrinology* 2009; 150: 232-238. doi.org/10.1210/en.2008-0747
16. Zhang Z, Li L, Yang M, Liu H, Boden G, Yang G. Increased plasma levels of nesfatin-1 in patients with newly diagnosed type 2 diabetes mellitus. *Exp. Clin. Endocrinol. Diabetes* 2012; 120: 91-5. doi: 10.1055/s-0031-1286339.
17. Xu Y, Chen F. Antioxidant, Anti-Inflammatory and Anti-Apoptotic Activities of Nesfatin-1: A Review. *J Inflamm Res.* 2020 Sep 28;13:607-617. doi: 10.2147/JIR.S273446.
18. Aydin S. Multi-functional peptide hormone NUCB2/nesfatin-1. *Endocrine.* 2013; 44(2):312–325. doi.org/10.1007/s12020-013-9923-0.
19. Buzcu H, Ozbevl D İLEK, Yüksel MERAL, Kava O, Çakır ÖZGÜR. Nesfatin-1 protects from acute pancreatitis: Role of melanocortin receptors. *Journal of Physiology and Pharmacology*, 2019; 70(6). doi: 10.26402/jpp.2019.6.03
20. Kiernan J A. *Histological and Histochemical Methods- Theory and Practice.* 5th Ed. (Banbury: Scion Publishing Ltd; 2015). doi: 10.1111/joa.12390
21. Liu Z, Wang Y, Wang Y, Ning Q, Zhang Y, Gong C, Wang Q. Dexmedetomidine attenuates inflammatory reaction in the lung tissues of septic mice by activating cholinergic anti-inflammatory pathway. *International Immunopharmacology*, 2016; 35, 210-216. doi.org/10.1016/j.intimp.2016.04.003
22. Ramos-Vara JA, Kiupel M, Baszier T, *et al.* Suggested guidelines for immunohistochemical techniques in veterinary diagnostic laboratories. *J Vet Diagn Invest.* 2008; 20:393–413. doi.org/10.1177/104063870802000401
23. Emsley R, Dunn G and White IR. Mediation and moderation of treatment effects in randomized controlled trials of complex interventions. *Stat Methods Med Res* (2010); 19(3):237–270. doi.org/10.1177/0962280209105014.
24. Liu X, Yuan L, Tang Y, Wu Y, Kong J, Zhou B, Wang X, Lin M, Li Y, Xu G, Wang Y, Xu T, He C, Fang S, Zhu S. Da-Cheng-Qi decoction improves severe acute pancreatitis-associated acute lung injury by interfering with intestinal lymphatic pathway and reducing HMGB1-induced inflammatory response in rats. *Pharm Biol*, 2023; 61(1), 144-154. doi.org/10.1080/13880209.2022.2160768.
25. Chen TA, Lo GH, Lin CK, Lai KH, Wong HY, Yu HC, Hsu PI, Chen HH, Tsai WL, Chen WC. Acute pancreatitis-associated acute gastrointestinal mucosal lesions: incidence, characteristics, and clinical significance. *J Clin Gastroenterol*, 2007; 41(6), 630-634. doi: 10.1097/01.mcg.0000225638.37533.8c.
26. Özkan E, Akyüz C, Dulundu E, Topaloğlu Ü, Şehirli AÖ, Ercan F, Şener G. Protective effects of lycopene on cerulein-induced experimental acute pancreatitis in rats. *Journal of Surgical Research*, 2012; 176(1), 232-238. doi.org/10.1016/j.jss.2011.09.005.
27. Ueda K, Ueyama T, Yoshida K, Kimura H, Ito T, Shimizu Y, Oka M, Tsuruo Y, Ichinose M. Adaptive HNE-Nrf2-HO-1 pathway against oxidative stress is associated with acute gastric mucosal lesions. *Am J Physiol Gastrointest Liver Physiol* 2008; 295: G460-G469. doi.org/10.1152/ajpgi.00204.2007
28. Bakoyiannis A, Delis S, Dervenis C. Pathophysiology of acute and infected pancreatitis. *Infect Disord Drug Targets* 2010; 10:2-4. doi.org/10.2174/187152610790410954.
29. Akyuz C, Sehirli AO, Topaloglu U, Ogunc AV, Cetinel S, Sener G. Protective effects of proanthocyanidin on cerulein-induced acute pancreatic inflammation in rats. *Gastroenterology Research*, 2009; 2(1), 20 doi: 10.4021/gr2009.02.1276.
30. Özkan E, Akyüz C, Sehirli AÖ, Topaloglu Ü, Ercan F, Sener G. Montelukast, a selective cysteinyl leukotriene receptor 1 antagonist, reduces cerulein-induced pancreatic injury in rats. *Pancreas*, 2010; 39(7), 1041-1046. doi: 10.1097/MPA.0b013e3181db2dfd
31. Eamlamnam K, Patumraj S, Visedopas N, Thong-Ngam D. Effects of Aloe vera and sucralfate on gastric microcirculatory changes, cytokine levels and gastric ulcer healing in rats. *World Journal of Gastroenterology: WJG*, 2006; 12(13), 2034. doi: 10.3748/wjg.v12.i13.2034
32. Laine L, Takeuchi K, Tarnawski A. Gastric mucosal defense and cytoprotection: bench to bedside. *Gastroenterology*, 2008; 135(1), 41-60. doi.org/10.1053/j.gastro.2008.05.030

33. Ibrahim BM, Salama AA, Abdallah HM, Awdan SA and Shaffie NM. Study of the protective effects of flaxseed oil on ethanol induced gastric mucosal lesions in non ovariectomized and ovariectomized rats. *Int. J. Pharmacol.* 2016; 12 (4): 329-339. doi:10.3923/ijp.2016.329.339
34. Fujimura T, Ohta T, Oyama K, Miyashita T, Miwa K. Role of cyclooxygenase-2 in the carcinogenesis of gastrointestinal tract cancers: a review and report of personal experience. *World journal of gastroenterology: WJG*, 2006; 12(9), 1336. doi: 10.3748/wjg.v12.i9.1336.
35. Pavlick KP, Laroux FS, Fuseler J, Wolf RE, Gray L, Hoffman J, Grisham MB. Role of reactive metabolites of oxygen and nitrogen in inflammatory bowel disease 1, 2. *Free Radical Biology and Medicine*, 2002; 33(3), 311-322. doi.org/10.1016/S0891-5849(02)00853-5.
36. Wu WK, Cho CH. The pharmacological actions of nicotine on the gastrointestinal tract. *J Pharmacol Sci.* 2004 Apr;94(4):348-58. doi: 10.1254/jphs.94.348.
37. Hassan ZA, Zauszkiewicz-Pawlak A, Abdelrahman SA, Algaidi S, Desouky M, Shalaby SM. Morphological alterations in the jejunal mucosa of aged rats and the possible protective role of green tea. *Folia Histochem Cytobiol*, 2017; 55(3):124-139. doi: 10.5603/FHC.a2017.0012.
38. Dang SC, Wang H, Zhang JX, Cui L, Jiang DL, Chen RF, ... & Gu M. Are gastric mucosal macrophages responsible for gastric injury in acute pancreatitis?. *World Journal of Gastroenterology: WJG*, 2015; 21(9), 2651. doi: 10.3748/wjg.v21.i9.2651
39. Holzer P. Gastroduodenal mucosal defense: coordination by a network of messengers and mediators. *Current Opinion in Gastroenterology*, 2001; 17(6), 489-496. doi: 10.1097/00001574-200111000-00003
40. Cappell MS. Acute pancreatitis: etiology, clinical presentation, diagnosis, and therapy. *Med Clin North Am.* 2008; 92(4):889-923. doi.org/10.1016/j.mena.2008.04.013.
41. De Waele JJ, Leppaniemi AK. Intra-abdominal hypertension in acute pancreatitis. *World J Surg.* 2009; 33(6):1128-33. doi.org/10.1007/s00268-009-9994-5
42. Hackert T, Werner J, Gebhard MM, Klar E. Effects of heparin in experimental models of acute pancreatitis and post-ERCP pancreatitis. *Surgery* 2004; 135: 131-138. doi.org/10.1016/j.surg.2003.08.001
43. Saleh H, Nassar AMK, Noreldin AE, Samak D, Elshony N, Wasef L, Elewa YHA, Hassan SMA, Saati AA, Hetta HF, *et al.* Chemo-Protective Potential of Cerium Oxide Nanoparticles against Fipronil-Induced Oxidative Stress, Apoptosis, Inflammation and Reproductive Dysfunction in Male White Albino Rats. *Molecules.* 2020; 25(15):3479. doi.org/10.3390/molecules25153479
44. Baez JC, Hamilton MJ, Bellizzi A, Mortelé KJ. Gastric involvement in autoimmune pancreatitis: MDCT and histopathologic features. *JOP; Journal of the Pancreas*, 2010; 11(6), 610-613. doi.org/10.6092/1590-8577/3407
45. Szlachcic A, Sliwowski Z, Krzysiek-Maczka G, *et al.* New satiety hormone nesfatin-1 protects gastric mucosa against stress-induced injury: mechanistic roles of prostaglandins, nitric oxide, sensory nerves and vanilloid receptors. *Peptides* 2013; 49:9. doi.org/10.1016/j.peptides.2013.07.017
46. Gonzalez R, Tiwari A, Unniappan S. Pancreatic beta cells colocalize insulin and pronofatin immunoreactivity in rodents. *Biochem Biophys Res Commun*, 2009; 381: 643-648. doi.org/10.1016/j.bbrc.2009.02.104
47. Gonzalez R, Perry RL, Gao X, Gaidhu MP, Tsushima RG, Ceddia RB, *et al.* Nutrient responsive nesfatin-1 regulates energy balance and induces glucose-stimulated insulin secretion in rats. *Endocrinology*, 2011; 152:3628-37. doi.org/10.1210/en.2010-1471
48. Solmaz A, Gulcicek OB, Ercetin C, Yiğitbaş H, Yavuz E, Arıcı S *et al.* Nesfatin-1 alleviates extrahepatic cholestatic damage of liver in rats. *Bosn J Basic Med Sci* 2016; 16(4):247-53. doi: 10.17305/bjbm.2016.1465
49. Yin Y, Li Z, Gao L, Li Y, Zhao J, Zhang W. AMPKdependent modulation of hepatic lipid metabolism by nesfatin-1. *Mol Cell Endocrinol* 2015; 417: 20-26. doi.org/10.1016/j.mce.2015.09.006
50. Kolgazi M, Cantali-Ozturk C, Deniz R, Ozdemir-Kumral ZN, Yuksel M, Sirvanci S. Nesfatin-1 alleviates gastric damage via direct antioxidant mechanisms. *J Surg Res* 2015; 193(1): 111-118. doi.org/10.1016/j.jss.2014.06.057
51. Bayr, H. Reactive oxygen species. *Crit. Care Med.* 2005, 33, S498. doi: 10.1097/01.CCM.0000186787.64500.12
52. Hawkins, C.L.; Davies, M.J. Detection, identification, and quantification of oxidative protein modifications. *J. Biol. Chem.* 2019, 294, 19683-19708. doi.org/10.1074/jbc.REV119.006217
53. Fuentes-Lemus, E.; Hägglund, P.; López-Alarcón, C.; Davies, M.J. Oxidative Crosslinking of Peptides and Proteins: Mechanisms of Formation, Detection, Characterization and Quantification. *Molecules* 2021, 27, 15. doi.org/10.3390/molecules27010015

الملخص العربي

الدور الوقائي للنسفاتين- ١ على تغيرات الغشاء المخاطي لقرع المعدة المستحدث بالتهاب البنكرياس الحاد في الجرذان

إيمان مسلم محمد، سماء محمد المحروقي، ايناس جمال عبد الله

قسم الهستولوجيا وبيولوجيا الخلية، كلية الطب البشري، جامعة الزقازيق

الهدف من البحث: تهدف هذه الدراسة إلى دراسة الدور الوقائي المحتمل للنسفاتين -١ على تأثير الغشاء المخاطي لقرع المعدة في التهاب البنكرياس الحاد الناجم عن السيروولين.

المواد وطرق البحث: تم دمج مجموعه مكونة من ٤٠ من الفئران البيضاء البالغة في هذا العمل. تم تقسيم الفئران الى ثلاثة مجموعات: مجموعة ضابطة , مجموعة التهاب البنكرياس الحاد الناجم عن السيروولين، المجموعة المعالجة بالنسفاتين-١. تم الفحص بالمجهر الضوئي. تم استخدام الإحصائيات لتحليل جميع البيانات.

النتائج: أظهرت الحيوانات المصابة بالتهاب البنكرياس الحاد مستويات مرتفعة من الأميليز في الدم، والليباز، و-II- β ، وعلامات الإجهاد التأكسدي (MDA)، وتم تأكيد التغيرات النسيجية في الغشاء المخاطي لقرع المعدة الثانوية لإصابة البنكرياس من خلال الدراسات H&E والدراسات الكيميائية المناعية والمورفومترية والإحصائية. أظهرت جميع النتائج الدور الوقائي للنسفاتين-١ على تأثير الغشاء المخاطي لقرع المعدة في التهاب البنكرياس الحاد الناجم عن السيروولين. أكدت التحليلات البيوكيميائية صحة النتائج النسيجية.

الاستنتاج: يقلل النسفاتين-١ من تأثير الغشاء المخاطي لقرع المعدة الناجم عن التهاب البنكرياس الحاد.