

RESEARCH ARTICLE

**EFFECT OF GESTATIONAL EXPOSURE TO NEONICOTINOID
INSECTICIDE "THIACLOPRID" ON WISTAR RATS AND THEIR FETUSES**

Ahmed Emam Dakrory; Omnia Ibrahim Elsaheed; Amel Ramadan Omar*

Zoology Department, Faculty of Sciences, Cairo University, Giza, Egypt

ABSTRACT

Article History:

Received: 26 October 2023

Accepted: 24 November 2023

Published Online:

24 November 2023

Keywords:

DNA damage

Gestation period

Oxidative stress

Rat fetuses

Thiacloprid

***Correspondence:**

Amel Ramadan Omar

Zoology Department

Faculty of Science

Cairo University

Giza, Egypt

E-mail:

amel@sci.cu.edu.eg

One of the insecticides in the neonicotinoid group is thiacloprid (THIA), the first chloronicotinyl pesticide with significant insecticidal action, which is applied to numerous crops to manage a variety of pest species. THIA may target the liver primarily, although reports of nephrotoxicity, teratogenicity, and carcinogenicity have indeed surfaced. The current study endeavors to investigate the teratogenic, oxidative stress, and genotoxic effect of THIA (1/40 and 1/20 of median lethal dose "LD₅₀") on the rat pregnant dams and their fetuses from 6th to 20th days of gestation. The two THIA-treated groups displayed teratogenic anomalies including fetuses not evenly distributed across the uterine horns, dead fetuses, and resorption sites in the uteri. Histologically, both maternal and fetal hepatic and renal tissues exhibited some histopathological alterations. Additionally, hepatic tissues from both the mother and their fetuses displayed a significant increase ($P<0.05$) in malondialdehyde level (indicating lipid peroxidation), a significant decrease ($P<0.05$) in the catalase and superoxide dismutase activities, and reduced glutathione level (indicating a defect in the antioxidant defense system), with a significant rise ($P<0.05$) in the comet parameter (indicating DNA damage). In conclusion, THIA treatment during the gestational period has a high potential for causing teratogenic and genotoxic effects, as well as oxidative stress, in pregnant dams and their fetuses. According to the study's findings, both pregnant females and their fetuses exposed to THIA may be at risk.

INTRODUCTION

Neonicotinoids (NEOs) are efficient against different kinds of insect pests, making them a useful tool for protecting both food crops and livestock^[1]. In the past decade, NEOs were the most widely used type of insecticide in the world, likely due to their potential to replace classical insecticides due to their weak binding of NEOs for mammalian neuronal nicotinic acetylcholine receptors^[2]. Elumalai *et al.*^[3] noted that the

gathering of NEOs in soil and water may provide a serious threat to the ecosystem, since they upset non-target creatures, while having a detrimental impact on biodiversity and the eco-system. As an agonist of the nicotinic acetylcholine receptor, the neonicotinoid pesticide "thiacloprid (THIA)" demonstrates neurotoxic action^[2,4]. Its use could pose a threat to the health of humans and animals that consume polluted food or water^[5]. It has been proposed that THIA

primarily targets the liver^[6,7], reports of nephrotoxicity, teratogenicity, and carcinogenicity also surfaced^[7,8].

Exposure to pesticides raises lipid peroxidation (LPO) and reactive oxygen species (ROS) levels, disrupted homeostasis and regulation and decreased antioxidant defense, all of which contribute to toxicity^[9]. As ROS level rise, they may react with macromolecules of cells, leading to enzyme deactivation and genotoxicity^[9]. Recent research has shown that the genotoxic effects of various pesticide mixtures are often greater than those of exposure to any one pesticide alone^[10]. Certain pesticides can cause organ toxicity, immunotoxicity, and carcinogenicity by disrupting the normal functioning of numerous body organs^[10-12]. THIA has been demonstrated to cause oxidative stress, DNA damage, and cytotoxicity in bovine and human lymphocytes^[13,14]. Treatment with THIA in rats for 30 days showed a considerable reduction in glutathione S-transferase (GST), an elevation in the level of malondialdehyde (MDA)^[6], a decrease in reduced glutathione (GSH) level^[15] and induced hepatotoxicity and nephrotoxicity in rats^[7]. THIA treatment of bovine peripheral lymphocytes for four hours resulted in oxidant-based DNA damage, lower cell viability, and reduced cell proliferation^[13].

The study's purpose was to evaluate the teratogenic effect of the neonicotinoid THIA on pregnant dams and their fetuses. In addition to record the growth parameters, pregnancy outcomes, and histological examinations of the main vital organs as liver and kidney. Moreover, to estimate the oxidative stress/antioxidant parameters represented by MDA, superoxide dismutase (SOD), catalase (CAT), and GSH of both the maternal liver and kidney, as well as the fetal liver, and to evaluate any potential genotoxic effects.

MATERIAL AND METHODS

Insecticide

The THIA compound "Blanch 48% SC" is

the insecticide used in the current study of the neonicotinoid class with the structure formula (Z)-3-(6-chloro-3-pyridylmethyl)-1,3-thiazolidin-2-ylidenecyanamide. It was purchased from Starchem (Giza, Egypt) under the trade name "calypso; YRC-2894".

Experimental animals and treatments

An overall of 18 virgin female albino Wistar rats (170±20 g) and 9 males (180±20 g) were supplied from the National Research Center, Giza, Egypt. The experimental animals were given 7 days to acclimatize before the experiment began. Animals were kept in well-ventilated cages at a temperature of 25 ±27°C and 49±55% humidity and 12 hours light/dark cycle. The Institutional Animal Care and Use Committee (CU-IACUC) at Cairo University (Egypt) approved all the animal protocols and experimental methods (approval no.: CU/I/F/29/20).

Two adult Females were caged with one male overnight and vaginal smears were stained with methylene blue the following morning to prove fertilization by revealing the presence of sperm and deemed to be the first day of gestation. Pregnant rats were divided into three regimens, 6 females each; the treatments were given orally/daily by gavage from the 6th day to the 20th day of pregnancy: Group A (control), received water. Group (B), received 9.9 mg/kg body weight (1/40 LD₅₀) of THIA. Group (C), received 19.8 mg/kg body weight (1/20 LD₅₀) of THIA. All animals of control and treated groups were daily spotted for any signs of toxicity or mortality.

Evaluation of teratogenicity and reproductive toxicity

The euthanasia with 50 mg sodium pentobarbital/kg body weight of the mothers took place on the 20th day of gestation then subjected to a cesarean incision. Both the right and left ovarian corpora lutea were counted in both the control and treated pregnant rats. The resorption sites, number of implantations,

and live and dead fetuses, as well as the weight and length of their bodies were recorded. The pre and post-implantation loss index were recorded according to Burdan *et al.*^[16] as follows: pre-implantation loss (%) = [(number of corpora lutea – number of implantation sites)/number of corpora lutea] × 100, post-implantation loss (%) = [(number of implantation sites – number of live fetuses)/number of implantation sites] × 100

Collection of maternal and fetal tissue samples

Dissected livers and kidneys of both the mothers and their unborn offspring were washed in saline to eliminate blood. Some tissue samples of livers and kidneys have been frozen at –80°C for later use in an oxidative stress and comet analyses. The histological analyses were performed on the remaining tissue samples of livers and kidneys.

Evaluation of oxidative stress

The kits for determination of MDA, GSH, CAT, and SOD have been acquired from Biodiagnostic (Dokki, Giza, Egypt) and were evaluated by colorimetric method^[17-20].

Histopathological analysis

Maternal and fetal samples of the kidney and liver of the three experimental groups were fixed in 10% formalin. Tissues were dehydrated using ascending series of ethyl alcohol, cleared in xylene, embedded in paraffin, sectioned at 5 µm thickness, stained with hematoxylin and eosin for routine examination and then photomicrographed using a Leica microscope (Leica Microsystems Inc., Deerfield, IL, USA). Histopathological alterations and deviations from the normal were recorded in the control and treated groups of pregnant rats and their fetuses.

Comet assay

Comet assay under alkaline conditions was executed for hepatic tissue of dams and fetuses according to the protocol reported

by Tice *et al.*^[21] and Nandhakumar *et al.*^[22]. The percentage of DNA in the tail, tail length, and tail moment were analyzed for DNA damage.

Statistical analysis

The statistical package for social sciences software (SPSS 25.0) was used for data analysis. ANOVA followed by Tuckey was applied for comparison among groups. The results are presented as mean ± standard error. The *P*-value < 0.05 was deemed as statistical significance.

RESULTS

Effect of THIA on rat reproductive teratogenicity

The results showed that dams remained alive until the experiment's end in groups treated with both doses of THIA between day 6 and day 20 of gestation, and no cases of abortion or death were noted. The maternal rats demonstrated no visible indicators of illness or abnormal behavior. The THIA treatment caused a significant decrement (*P*<0.05) in the body weight gain of pregnant rats relative to the control group, which was dose dependent (Table 1).

Through cesarean sections, gravid uteri taken from control dams revealed no anomalies and normal distribution of fetuses implanted in the two horns (Figure 1A). Asymmetrical distribution of the fetuses in the two horns was seen in the gravid uteri received 9.9 mg THIA/kg body weight (Figure 1B). In a few instances, resorption and dead fetuses were found in the uterine horns of mothers that received 19.8 mg THIA/kg body weight (Figures 1C,D). In comparison with the control group, dams in the group received 19.8 mg THIA/kg body weight exhibited a significant reduction (*P*<0.05) in uterus and placenta weights (Table 1). The placental weight in group received 19.8 mg THIA/kg body weight displayed a significant decrement (*P*<0.05) also as compared with the 9.9 mg THIA/kg body weight-treated group (Table 1).

Table 1: Effect of thiacloprid on rat maternal weights.

	Control	Thiacloprid	
		9.9 mg/kg body weight	19.8 mg/kg body weight
Number of pregnant rats	6	6	6
Maternal body weight gain (g)	68.60±2.89	49.41±3.09*	33.66±3.32*#
Uterus weight (g)	38.08±4.42	26.00±2.48	14.56±2.99*
Placental weight (g)	36.90±5.33	27.81±1.84	12.69±2.67*#

Values are represented as mean ± standard error. *, #: Significant difference ($P < 0.05$) compared with the control and 9.9 mg thiacloprid/kg body weight groups, respectively.

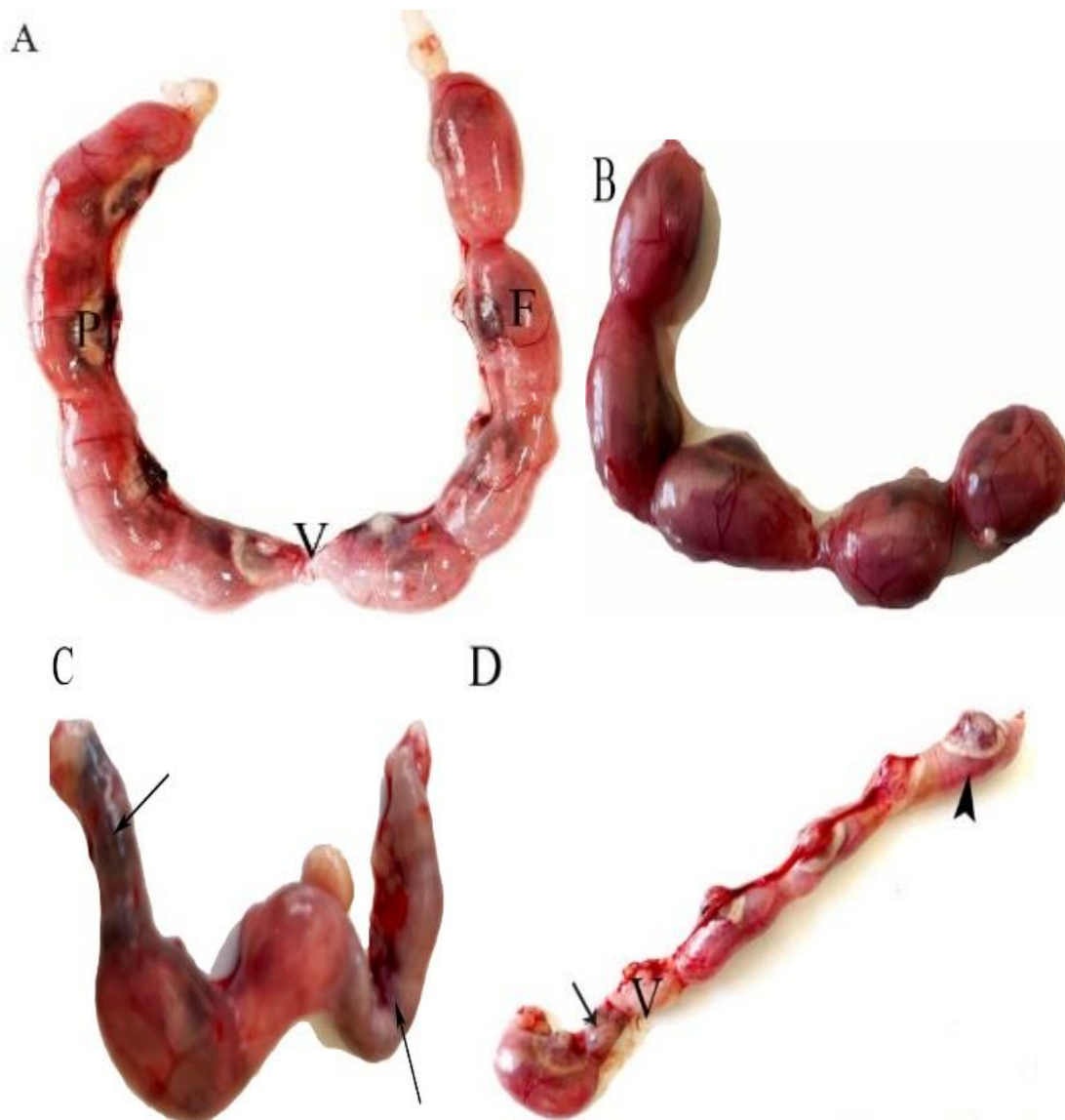


Figure 1: Photographs of the uteri of pregnant rats on the 20th day of gestation. (A) The control group showed a uterus with a normal distribution of implanted fetuses in both horns. (B) Thiachloprid group (9.9 mg/kg body weight) showed unequal distribution and some reduction in the number of fetuses. (C, D) Thiachloprid group (19.8 mg/kg body weight) displayed resorbed (arrow) and dead fetuses (arrowhead). F: fetus, V: vagina, Pl: placenta.

Effect of THIA on rat pregnancy outcomes

Non-significant appearance ($P \geq 0.05$) in the number of corpora lutea, resorption sites, number of implants, and pre-implantation loss index in the three groups was observed (Table 2). However, a significant decrease ($P < 0.05$) in the number of the viable fetuses and a significant increment ($P < 0.05$) in the post-implantation index was noted in the group received 19.8 mg THIA/kg body

weight relative to the control group (Table 2). Fetuses from both maternally THIA-treated groups showed a significant reduction ($P < 0.05$) in their weight and length relative to the control group. Moreover, the fetal length in group received 19.8 mg THIA/kg body weight displayed a significant decrement ($P < 0.05$) also as compared with the 9.9 mg THIA/kg body weight-treated group (Table 2).

Table 2: Effect of thiacloprid on rat pregnancy outcome.

	Control	Thiacloprid	
		9.9 mg/kg body weight	19.8 mg/kg body weight
Number of viable fetuses/litter	8.00±0.25	5.50±0.84	3.00±0.96*
Number of litters with resorption	0.0	0.33±0.21	1.66±1.11
Number of corpora lutea/litter	8.50±0.22	7.33±0.71	7.16±0.47
Number of implants/litter	8.00±0.25	5.83±0.79	6.00±0.73
Pre-implantation loss index (%)	5.55±3.79	21.63±4.03	16.78±8.39
Post-implantation index (%)	0.0	6.54±4.36	48.01±16.54*#
Fetal weight (g)	3.38±0.12	2.05±0.19*	1.78±0.26*
Fetal length (cm)	3.58±0.06	3.15±0.08*	2.66±0.16*#

Values are represented as mean \pm standard error. *, #: Significant difference ($P < 0.05$) compared with the control and 9.9 mg thiacloprid/kg body weight groups, respectively.

Effect of THIA on oxidative stress markers in rat maternal and fetal tissues

The level of MDA in the maternal liver showed a significant increase ($P < 0.05$) in the group received 19.8 mg THIA/kg body weight compared with the control and the 9.9 mg THIA/kg body weight-treated groups (Table 3). Fetal liver MDA increased significantly ($P < 0.05$) in both THIA-treated groups compared with the control group. In contrast, SOD activity in maternal and fetal livers was significantly lower ($P < 0.05$) in both THIA-treated groups compared with the control group. Moreover, the MDA level and SOD activity in the maternal liver of group received 19.8 mg THIA/kg body weight displayed a significant increase and decrease ($P < 0.05$), respectively, as compared with the

9.9 mg THIA/kg body weight-treated group (Table 3). The CAT activity in maternal liver reduced significantly ($P < 0.05$) in the THIA-treated groups compared with the control one. In the fetal liver, the CAT activity showed a significant reduction ($P < 0.05$) in the group received 19.8 mg THIA/kg body weight only as compared with the control group. The significant decrease ($P < 0.05$) in GSH levels of both maternal and fetal liver were noticed in the HIA-treated groups compared with the control one (Table 3).

A statistically significant elevation ($P < 0.05$) in the level of MDA in the maternal renal tissues was detected in both THIA-treated groups as compared with the control group (Table 4). However, rats treated with 19.8 mg THIA/kg body

weight exhibited a significant elevation ($P<0.05$) in the renal MDA level compared with rats treated with the lower dose of THIA. In contrast the SOD and CAT activities, as well as the GSH levels were significantly decreased ($P<0.05$) in the maternal renal tissues of THIA-treated

groups compared with the control one. In addition, the CAT activity in the maternal renal tissues of rats treated with 19.8 mg THIA/kg body weight was significantly decreased ($P<0.05$) compared with rats treated with the lower dose of THIA (Table 4).

Table 3: Effect of thiacloprid on the oxidative stress/antioxidant markers in the maternal and fetal liver at 20th day of gestation.

		Control	Thiacloprid	
			9.9 mg/kg body weight	19.8 mg/kg body weight
MDA (nmol/g tissue)	Mother	2.82±0.09	3.09±0.10	4.69±0.22*#
	Fetus	3.95±0.26	5.47±0.06*	6.82±0.64*
SOD (U/g tissue)	Mother	133.33±3.20	91.22±24.79*	35.00±9.76*#
	Fetus	175.78±3.02	118.52±17.10*	81.48±26.70*
CAT (U/g tissue)	Mother	173.32±39.19	74.38±4.20*	69.86±4.43*
	Fetus	245.38±22.65	166.51±17.62	88.69±0.40*
GSH (mmol/g tissue)	Mother	1.99±0.28	0.75±0.12*	0.50±0.04*
	Fetus	2.09±0.45	0.97±0.04*	0.40±0.06*

Values are represented as mean ± standard error. *, #: Significant difference ($P<0.05$) compared with the control and 9.9 mg thiacloprid/kg body weight groups, respectively. MDA: malondialdehyde; SOD: superoxide dismutase; CAT: catalase; GSH: reduced glutathione.

Table 4: Effect of thiacloprid on the oxidative stress/antioxidant markers in the maternal kidney at 20th day of gestation.

		Control	Thiacloprid	
			9.9 mg/kg body weight	19.8 mg/kg body weight
MDA (nmol/g tissue)		3.55±0.21	5.59±0.28*	7.29±0.47*#
SOD (U/g tissue)		140.11±3.45	104.17±3.76*	89.74±4.44*
CAT (U/g tissue)		203.66±8.29	160.66±8.45*	114.07±2.35*#
GSH (mmol/g tissue)		1.64±0.20	0.76±0.53*	0.47±0.26*

Values are represented as mean ± standard error. *, #: Significant difference ($P<0.05$) compared with the control and 9.9 mg thiacloprid/kg body weight groups, respectively. MDA: malondialdehyde; SOD: superoxide dismutase; CAT: catalase; GSH: reduced glutathione.

Histopathological alterations in maternal and fetal tissues of THIA-treated rats

The control liver of pregnant rats exhibited a normal central vein with its squamous endothelium lining and regular hepatic cords with polygonal hepatocytes (Figure 2A). The maternal liver tissue in the

group that received 9.9 mg THIA/kg body weight showed a light vesicular nucleus of hepatocytes, some vacuolation, and apoptotic cells; in addition, enlarged hepatic sinusoids, a congested central vein, and inflammatory cells gathered around it were considered as well (Figure 2B).

Mother received 19.8 mg THIA/kg body weight showed substantial vacuolations and degenerative alterations in the hepatic tissue, endothelium damage in the central vein;

moreover, necro-apoptotic alterations, and necrotic regions were noticed between the hepatic cords (Figure 2C).

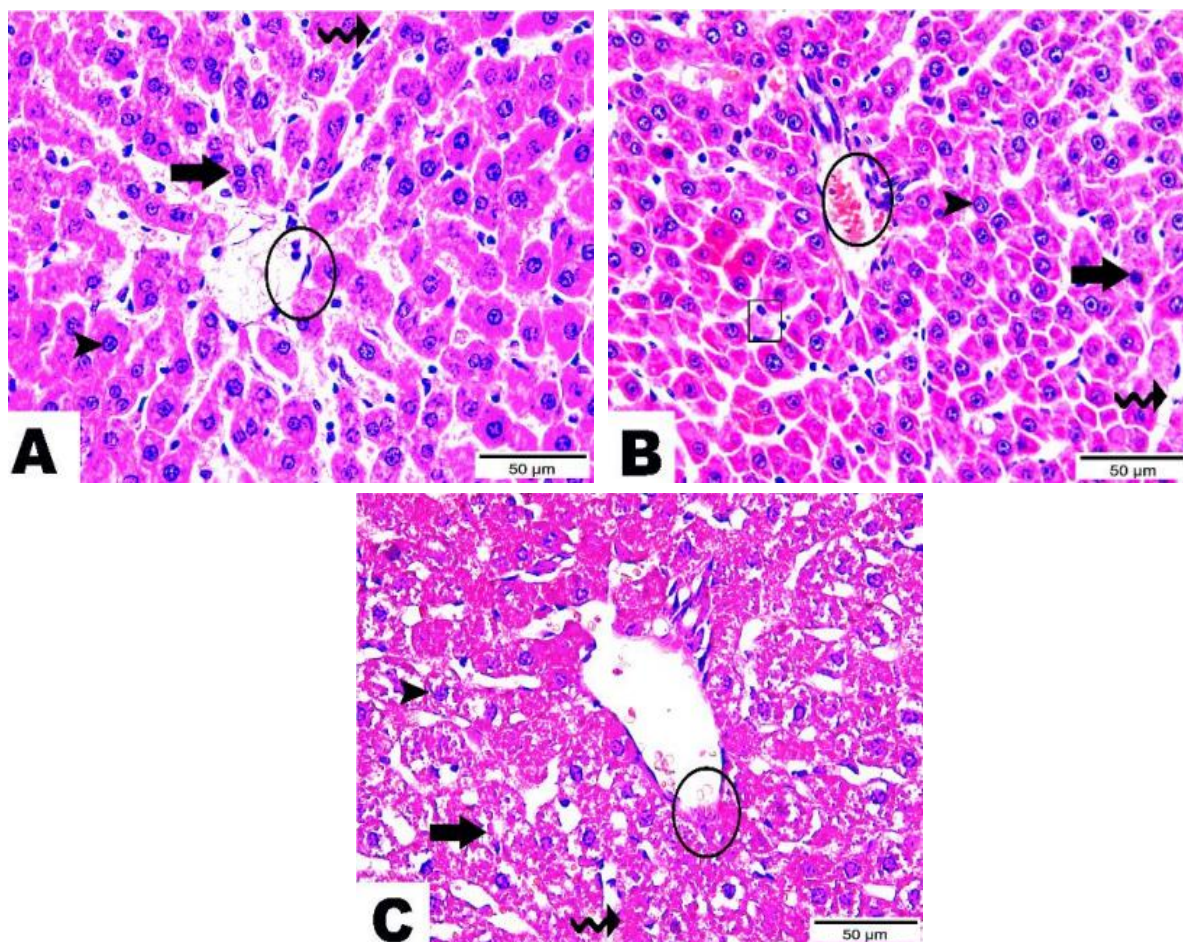


Figure 2: Photomicrographs of hepatic tissues of pregnant rats obtained on the 20th day of gestation that stained with hematoxylin and eosin. (A) The control group: central vein region with simple squamous endothelium (circle), hepatic cords protruded from the central vein (thick arrow), and polygonal hepatocytes with a sizable round central light vesicular nucleus (Uni- or Bi-nucleated, arrowhead), these cords were divided by Kupffer cells and hepatic sinusoids (wave arrow). (B) The 9.9 mg thiacloprid/kg body weight group: hepatic tissue with a light vesicular nucleus of hepatocytes (arrowhead) excluding some of appeared in an apoptotic form (thick arrow), vacuolated ones (cube), dilated hepatic sinusoids (wave arrow), and congested central vein besides aggregated inflammatory cells (circle). (C) The 19.8 mg thiacloprid/kg body weight group: vacuolations with degenerative changes along hepatic tissue (thick arrow), central vein with destructed endothelium (circle), hepatocytes with necro-apoptotic changes (arrowhead), and notice necrotic areas between hepatic cords (wave arrow).

The microscopic examination of the fetal liver of the control group manifested a well-differentiated central vein region with normal endothelium lining and normal primitive hepatic tissue (Figure 3A). At the

dose of 9.9 mg THIA/kg body weight, the fetal liver displayed patches of central vein endothelium degeneration, multinucleated megakaryocytes in hepatic tissue, typical light vesicular hepatocytes, and surrounded

congested blood sinusoids (Figure 3B). The fetal liver of the group received 19.8 mg THIA/kg body weight revealed blatant degenerative changes, the central vein was found to have alterations in its endothelium and a substantial congestion inside its lumen,

detection of deep basophilic apoptotic nuclei in hepatocytes was observed, there was hemorrhaging between the hepatic sheets, and inflammatory cell clusters were found (Figure 3C).

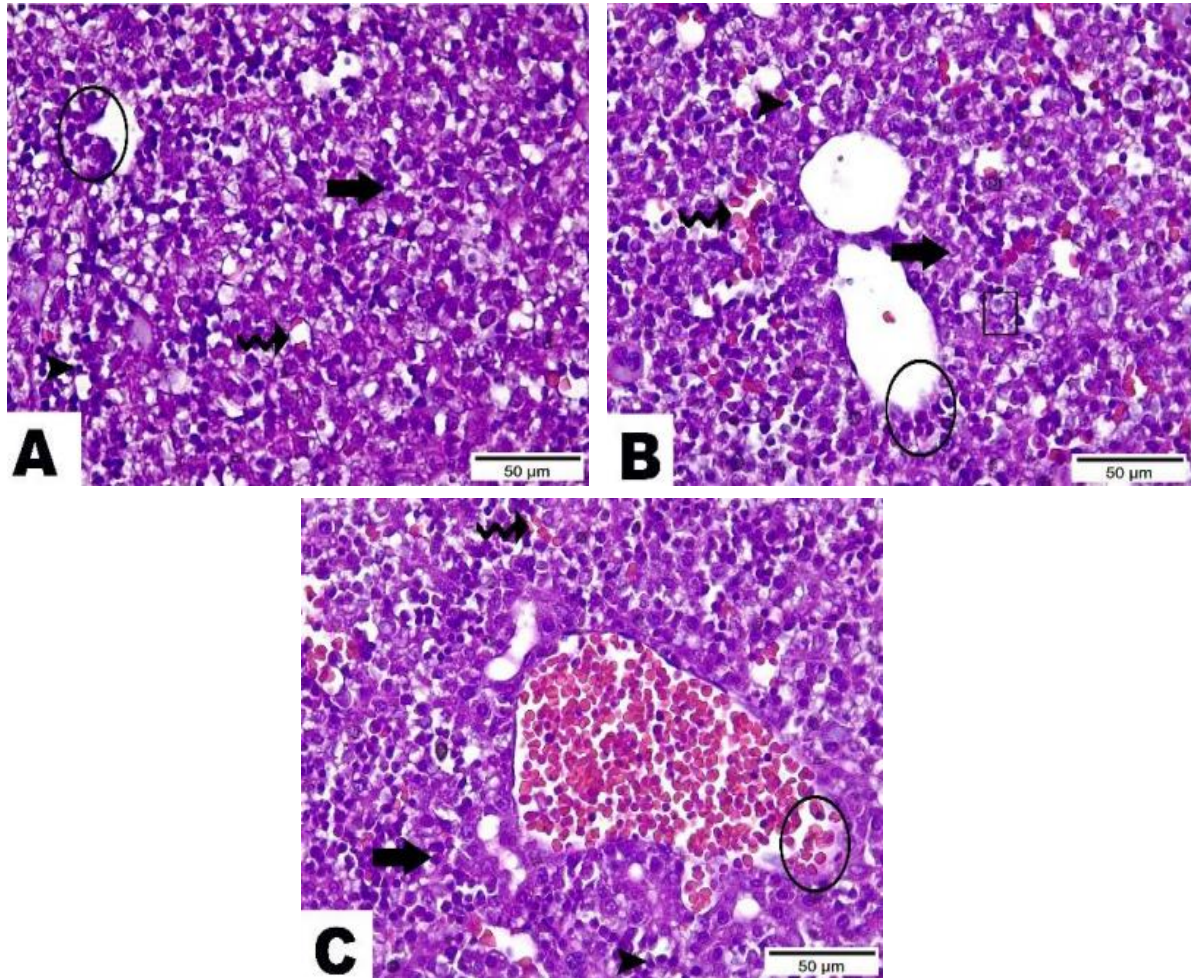


Figure 3: Photomicrographs of fetal liver sections at the 20th day of gestation that stained with hematoxylin and eosin. (A) The control group showing disclosed regular lining endothelium (circle), settled sheets of polygonal hepatocytes with huge round central light vesicular nuclei (thick arrow), diverge by hepatic sinusoids (wavy arrows), and distinct phases of erythroblast scattered encircling hepatocytes (arrowheads). (B) The 9.9 mg thiacloprid/kg body weight group showing manifested areas with degenerated endothelium of the central vein (circle), normal light vesicular hepatocytes (thick arrow), presence of multinucleated megakaryocyte (cube), and encircled congested blood sinusoids (wave arrows). (C) The 19.8 mg thiacloprid/kg body weight group showing endothelium of central vein spotted with destructive changes, as well as severe congestion inside its lumen (circle), hepatocytes with deep basophilic apoptotic nuclei (thick arrow), hemorrhage between hepatic sheets (wave arrow), and aggregations of inflammatory cells (arrowhead).

The maternal kidney of the control group showed normal glomerulus and Bowman's capsule, and both were intact

in the renal corpuscle; the proximal and distal convoluted tubules were normally assembled (Figure 4A). The renal corpuscle

in the group received 9.9 mg THIA/kg body weight appeared normal with some tubules that had lining cells died, the tubule lumen was found to have a hyaline cast, and hemorrhage between renal tubules was shown (Figure 4B). The renal cortex area showed severe degenerative alterations in the group received 9.9 mg THIA/kg

body weight. A destructive glomerulus and enlarged interglomerular space were present in the renal corpuscle; in addition, apoptotic lining cells, hyaline cast homing tubular lumen, and epithelial desquamation along the renal tubule were also observed in the group received 19.8 mg THIA/kg body weight (Figure 4C).

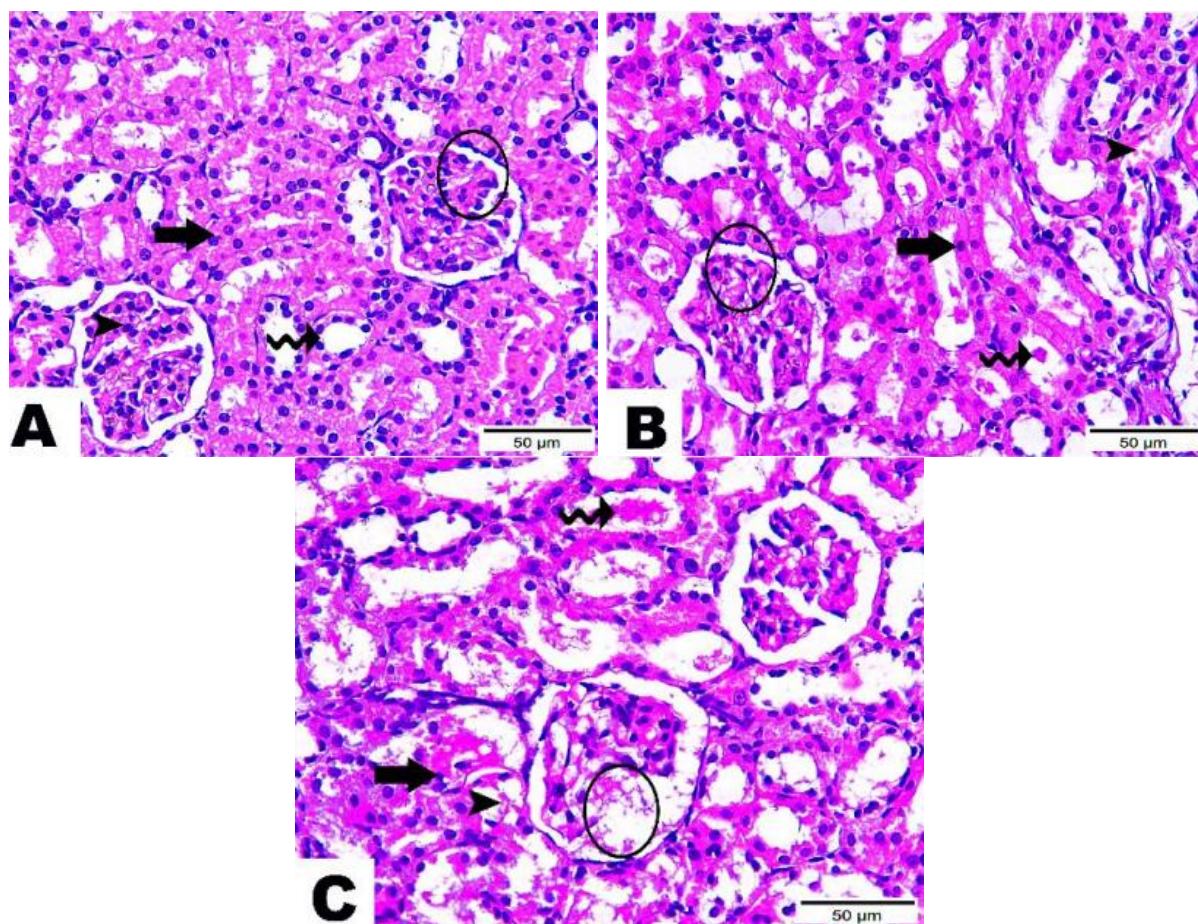


Figure 4: Photomicrographs of maternal renal tissue at the 20th day of gestation that stained with hematoxylin and eosin. **(A)** The control group: normal renal tissue histological pattern, Bowman's capsule (circle) and glomerulus (arrowhead), and proximal convoluted tubule (wave arrow) along with distal convoluted tubule (thick arrow). **(B)** The 9.9 mg thiacloprid/kg body weight group: a regular renal corpuscle (circle), some tubules with apoptotic lining cells (thick arrow), hyaline cast within the tubules lumen (wave arrow), and hemorrhage between renal tubules (arrowhead). **(C)** The 19.8 mg thiacloprid/kg body weight group: wide interglomerular space (circle), epithelial desquamation along renal tubule (arrowhead), apoptotic lining cells (thick arrow), and hyaline cast homing tubular lumen (wave arrow).

Examination of the fetal kidney in the control group showed a normal morphological manner (Figure 5A). The renal corpuscle was detected in a normal structure; however, several proximal con-

voluted tubules had degenerative alterations along with edema between renal tubules, and the distal convoluted tubule collapse was also noticed in the group received 9.9 mg THIA/kg body weight (Figure 5B).

The kidney tissues had significant vacuolations and degenerative alterations, Bowman's capsule suffered severe damage, and there

was also a noticeable increase in the interglomerular area in the group received 19.8 mg THIA/kg body weight (Figure 5C).

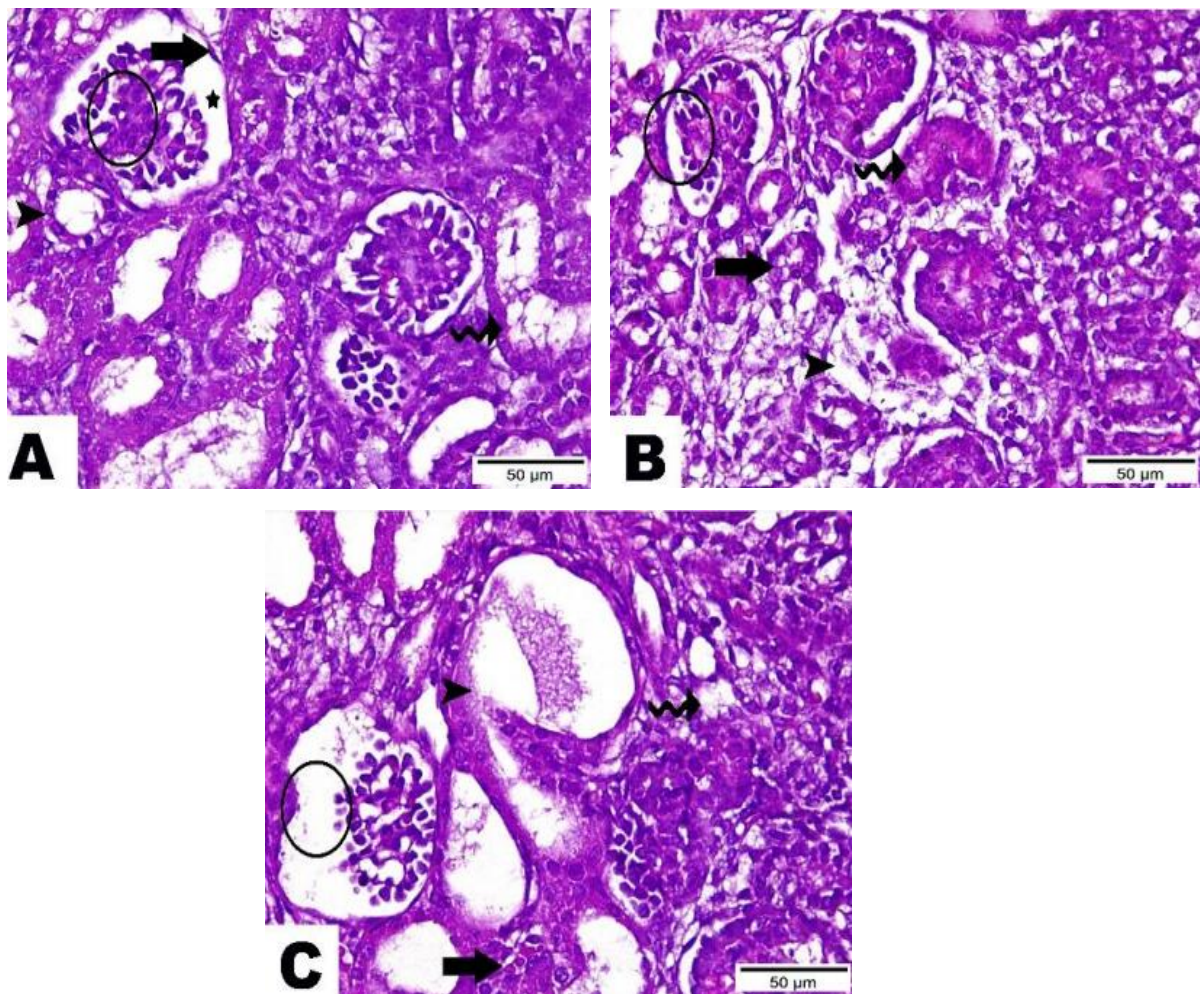


Figure 5: Photomicrographs of the fetal kidney at the 20th day of gestation that stained with hematoxylin and eosin. (A) The control group: renal corpuscle with intact Bowman's capsule (thick arrow), interglomerular space (star), and glomerulus (circle), proximal convoluted tubule (arrowhead), and distal convoluted tubule (wave arrow). (B) The 9.9 mg thiacloprid/kg body weight group: renal corpuscle (circle), proximal convoluted tubules (thick arrow), collapse of the distal convoluted tubule (wave arrow), and edema between renal tubules (arrowhead). (C) The 19.8 mg thiacloprid/kg body weight group: vacuolations and degenerative changes along kidney tissue (wave arrow), Bowman's capsule (arrowhead), wide interglomerular space (circle), and hemorrhage between renal tubules (thick arrow).

DNA damage in maternal and fetal hepatic tissues

The comet assay data revealed that THIA doses caused significant elevations ($P<0.05$) in DNA damage in maternal and fetal hepatic tissues, as indicated by comet (%), tail moment, DNA in the tail (%), and olive moment comparable with the control group (Table 5, Figure 6).

DISCUSSION

The THIA compound, the first chloronicotinyl pesticide having a considerable insecticidal effect, is used to control a range of pest species on different crops. A survey of the literature revealed that THIA's cytotoxic, genotoxic, and carcinogenic potential still needs more investigation. The only known information on THIA

Table 5: Comet assay parameters in maternal and fetal hepatic tissues of thiacloprid-treated groups at 20th day of gestation.

		Thiacloprid		
		Control	9.9 mg/kg body weight	9.9 mg/kg body weight
Comet (%)	Mother	8.27±0.59	18.03±1.49*	23.23±2.28*
	fetus	10.17±1.30	17.73±1.82	25.03±2.77*
DNA in tail (%)	Mother	5.22±0.65	9.10±0.99*	7.50±0.73
	fetus	6.82±0.24	7.65±0.78	8.24±0.90
Tail length (mm)	Mother	7.75±0.89	6.99±0.61	9.04±0.76
	fetus	7.75±1.15	8.97±1.24	8.00±0.12
Tail moment	Mother	0.28±0.10	0.52±0.08	0.69±0.02*
	fetus	0.45±0.03	0.65±0.09*	0.61±0.09*
Olive moment	Mother	0.80±0.10	1.30±0.04	1.20±0.06
	fetus	0.97±0.14	1.19±0.05	1.44±0.24*

Values are represented as mean ± standard error. *, #: Significant difference ($P < 0.05$) compared with the control and 9.9 mg thiacloprid/kg body weight groups, respectively.

genotoxic effects comes from the manufacturer's data, which concluded that there was no proof of genotoxicity caused by THIA in certain *in vivo* and *in vitro* testing^[23]. The maternal body weight gain in the current study decreased significantly due to THIA exposure. Arfat *et al.*^[24] also stated that the exposure to the neonicotinoid insecticides "imidacloprid" decreased the body weight with significant toxicity symptoms in male albino mice. Our results exhibited a significant decrease in the uterus weights of the pregnant rats received 19.8 mg THIA/kg body weight compared with the control. The harmful effects of THIA on the body and reproductive organ weights may be due to the less consumption of food and water during the treatment. The treatment with THIA induced significant changes in rat pregnancy outcomes in the current study. It raised the resorption percentage and reduced the fetal and placental weights. In line with our findings, Gawade *et al.*^[25] demonstrated that pregnant rats exposed to imidacloprid led to post-implantation loss. Also, imidacloprid prompted developmental delays and deformations in chick embryo^[26]. Elevating evidence mentioned that neonicotinoids may

also have teratogenic effects. Abou Zeid^[27] reported that acetamiprid exposure during pregnancy decreased implantation rate and fetal weight in rats. Pfeil and Tasheva^[28] reviewed that rats exposed to THIA had an elevated incidence of resorptions and a reduction in fetal weight. Furthermore, THIA demonstrated higher values for trans-placental transfer efficiency^[29]. The maternal exposure to imidacloprid causes oxidative placental damage, which compromise its nutritional function and may lead to resorptions or growth retardation in offspring^[30]. A smaller placenta is likely to have decreased blood supply, resulting in significant fetal hypoxia and possibly stunted intrauterine growth^[31].

The current study showed that the administration of THIA caused histopathological alterations in maternal and fetal kidney and liver. Consequently, THIA is the same as imidacloprid disturbing liver and kidney functions. Animals treated with the neonicotinoid compounds like thiamethoxam, imidacloprid, and clothianidin showed inflammation and oxidative stress in organs such as the kidney, liver, and brain in rats and mice^[32-34]. Exposure to both doses of THIA elevated the MDA of both dams

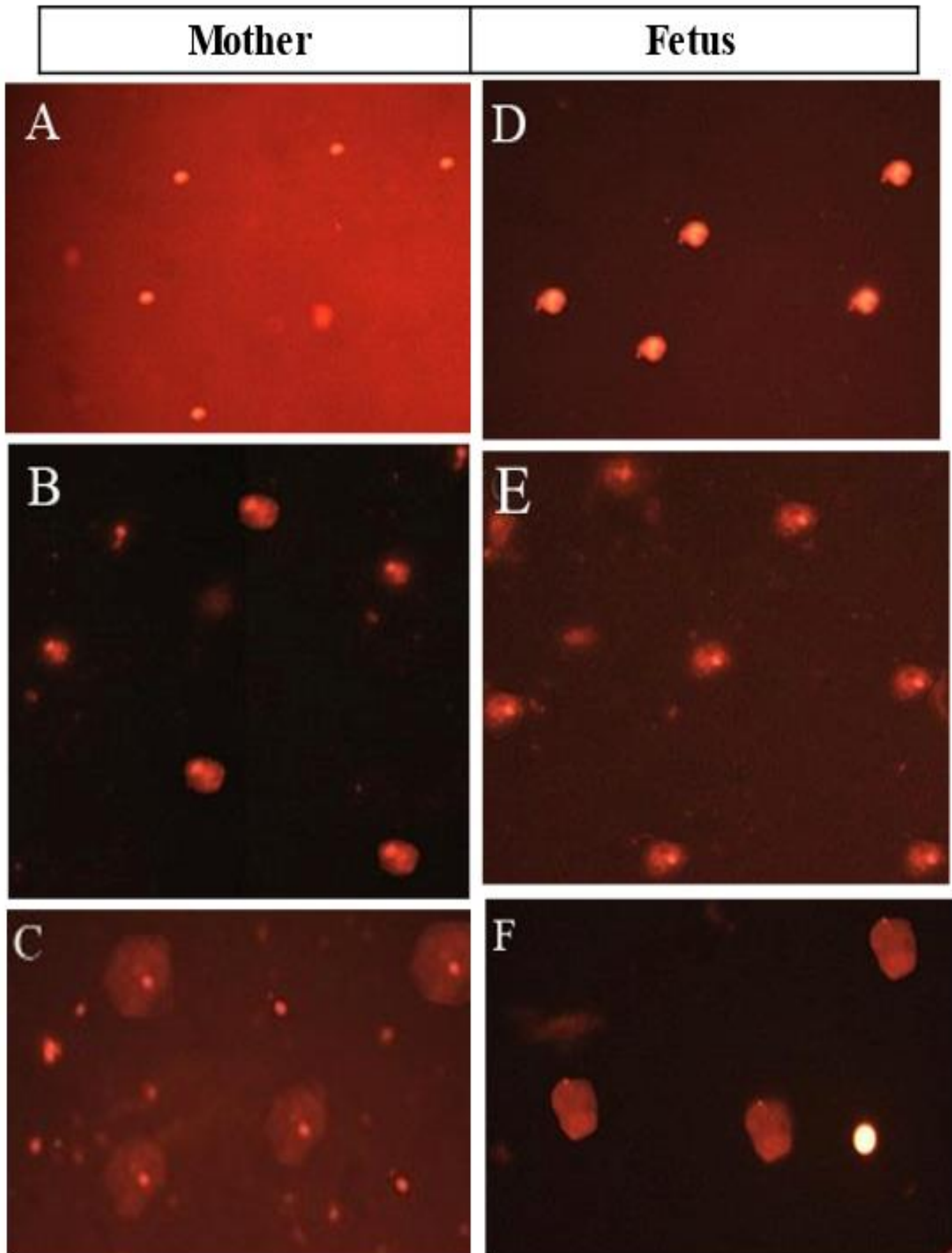


Figure 6: Photomicrographs of typical nuclei with varying degrees of DNA damage in mother and fetal liver tissues as comets caused by thiacloprid. **(A)** The control group of mother cells. **(B)** The 9.9 mg thiacloprid/kg body weight group of maternal cells. **(C)** The 19.8 mg thiacloprid/kg body weight group of maternal cells. **(D)** The control group of fetus cells. **(E)** The 9.9 mg thiacloprid/kg body weight group of fetus cells. **(F)** The 19.8 mg thiacloprid/kg body weight group of fetus cells (magnification = 400×).

and fetuses, decreased their antioxidant defense system (CAT, SOD, and GSH), and enhanced DNA damage. Other studies highlighted that dams exposed to imidacloprid increased the H₂O₂ and MDA levels, as well as decreased the GSH level and CAT activity, which was accompanied by fetal malformations that may be considered one of the leading reasons for oxidative tissue damage of the pregnant dams affecting their offspring^[34]. Further probes showed that the metabolism of pesticides may result in oxidative molecules, which may change the quantity and activity of antioxidant enzymes, resulting in oxidative damage^[9] and leading to cell apoptosis *via* activation of caspase-3 that may explain why THIA causes the atrophy of vital organs^[6]. In rats' plasma, lymphoid organs, kidney, liver, and brain tissues, oral dosing of imidacloprid enhanced the lipids peroxidation^[34]. Additionally, THIA led to oxidative stress in zebrafish, *Danio rerio*^[35]. Humans lymphocytes exposed to THIA *in vitro* exhibited DNA damage^[36]. THIA minimized the propagation in cultured bovine peripheral lymphocytes, decreased the expression of their GST, and stimulated cytotoxic/cytostatic effects^[37,38]. In addition, it minimized the viability of human hepatocellular and neuroblastoma carcinoma cells^[39]. THIA increased MDA and decreased GSH levels in the hepatic and renal tissues of rats causing nephrotoxicity and hepatotoxicity^[7] that may cause DNA damage. A significant reduction in the glutathione peroxidase activity was observed in brain tissue of mice exposed to THIA, as well as degeneration in the learning and memory functions^[40].

Insecticides dimethoate and lambda cyhalothrin caused injury in the bone marrow DNA of rats, 48 hours after application^[41]. Additionally, propoxin and diazinon caused DNA damage in the renal and hepatic tissues of rabbits following prolonged exposure^[42]. By employing the comet assay for the entire bone marrow and blood, another study found abnormalities in

the liver histopathology and a substantial elevation in DNA damage in rats treated with chlorpyrifos^[43]. In addition, lymphocytes collected from workers subjected to insecticides like deltamethrin and chlorpyrifos showed DNA damage^[43]. In the present study, THIA promoted notable DNA damage in the maternal and fetal hepatic tissues relative to the control group. The generation of ROS such as hydroxyl, oxygen free radicals, or hydrogen peroxide, which cause oxidative stress in different tissues, is the primary mechanism for pesticide toxicity that might attach to and cross biological membranes, harming DNA, RNA, and protein macromolecules^[44]. In conclusion, it was revealed that THIA exposure at two different doses had harmful effects on pregnant rats and their fetuses, suggesting an analogous potential for pregnant women and their fetuses in humans.

FUNDING

The authors confirm that no financial or other support was received during the time that this manuscript was being prepared.

COMPETING INTERESTS

The authors declare no competing interests.

Author's contributions

OIE: contributed to the collection and processing of data. ARO: writing, reviewing, and editing. AED: reviewed and approved the paper's final draught.

REFERENCES

- [1] Oya, N.; Ito, Y.; Ebara, T. *et al.* (2021). Cumulative exposure assessment of neonicotinoids and an investigation into their intake-related factors in young children in Japan. *Sci Total Environ*, 750: 141630 (DOI: 10.1016/j.scitotenv.2020.141630).
- [2] Houchat, J.-N.; Cartereau, A.; Le Mauff, A. *et al.* (2020). An overview on the effect of neonicotinoid insecticides on mammalian cholinergic

- functions through the activation of neuronal nicotinic acetylcholine receptors. *Int J Environ Res Public Health*, 17(9): 3222 (DOI: 10.3390/ijerph17093222).
- [3] Elumalai, P.; Yi, X.; Chen, Z. *et al.* (2022). Detection of neonicotinoids in agriculture soil and degradation of thiacloprid through photo degradation, biodegradation and photo-biodegradation. *Enviro Pollut*, 306: 119452 (DOI: 10.1016/j.envpol.2022.119452).
- [4] Saoudi, M.; Ben Slama-Ben Salem, R.; Ben Salem, M. *et al.* (2019). Beneficial effects of *Crataegus oxyacantha* extract on neurobehavioral deficits and brain tissue damages induced by an insecticide mixture of deltamethrin and chlorpyrifos in adult Wistar rats. *Biomed Pharmacother*, 114: 108795 (DOI: 10.1016/j.biopha.2019.108795).
- [5] Abou-Zeid, S. M.; Aljuaydi, S. H.; AbuBakr, H. O. *et al.* (2021). Astaxanthin mitigates thiacloprid-induced liver injury and immunotoxicity in male rats. *Mar Drugs*, 19(9): 525 (DOI: 10.3390/md19090525).
- [6] Hendawi, M. Y.; Alam, R. T. M. and Abdellatif, S. A. (2016). Ameliorative effect of flaxseed oil against thiacloprid-induced toxicity in rats: hematological, biochemical, and histopathological study. *Environ Sci Pollut Res Int*, 23(12): 11855-11863.
- [7] Kammoun, I.; Sellem, I.; Ben Saad, H. *et al.* (2019). Potential benefits of polysaccharides derived from marine alga *Ulva lactuca* against hepatotoxicity and nephrotoxicity induced by thiacloprid, an insecticide pollutant. *Environ Toxicol*, 34(11): 1165-1176.
- [8] EPA (2013). Thiacloprid; pesticide tolerances. *Federal Register*, 78(25): 8410-8416.
- [9] Lushchak, V. I.; Matviishyn, T. M.; Husak, V. V. *et al.* (2018). Pesticide toxicity: a mechanistic approach. *EXCLI J*, 17: 1101-1136.
- [10] Şekeroğlu, V.; Şekeroğlu, Z. A. and Kefelioğlu, H. (2013). Cytogenetic effects of commercial formulations of deltamethrin and/or thiacloprid on Wistar rat bone marrow cells. *Environ Toxicol*, 28(9): 524-531.
- [11] Şekeroğlu, V.; Şekeroğlu, Z. A. and Demirhan, E. (2014). Effects of commercial formulations of deltamethrin and/or thiacloprid on thyroid hormone levels in rat serum. *Toxicol Ind Health*, 30: 40-46.
- [12] Aydın, B. (2011). Effects of thiacloprid, deltamethrin and their combination on oxidative stress in lymphoid organs, polymorphonuclear leukocytes and plasma of rats. *Pestic Biochem Phys*, 100(2): 165-171.
- [13] Schwarzbacherova, V.; Wnuk, M.; Deregowska, A. *et al.* (2020). *In vitro* exposure to thiacloprid-based insecticide formulation promotes oxidative stress, apoptosis and genetic instability in bovine lymphocytes. *Toxicol In Vitro*, 61: 104654 (DOI: 10.1016/j.tiv.2019.104654).
- [14] Calderon-Segura, M. E.; Gomez-Arroyo, S.; Villalobos-Pietrini, R. *et al.* (2012). Evaluation of genotoxic and cytotoxic effects in human peripheral blood lymphocytes exposed *in vitro* to neonicotinoid insecticides news. *J Toxicol*, 612647 (DOI: 10.1155/2012/612647).
- [15] Kammoun, I.; Bkhairia, I.; Ben Abdallah, F. *et al.* (2017). Potential protective effects of polysaccharide extracted from *Ulva lactuca* against male reprotoxicity induced by thiacloprid. *Arch Physiol Biochem*, 123(5): 334-343.
- [16] Burdan, F.; Szumiło, J.; Dudka, J. *et al.* (2005). Morphological studies in modern teratological investigations. *Folia Morphol (Warsz)*, 64: 1-8.
- [17] Ohkawa, H.; Ohishi, N. and Yagi, K. (1979). Assay for lipid peroxides in animal tissues by thiobarbituric acid reaction. *Anal Biochem*, 95(2): 351-358.
- [18] Beutler, E.; Duron, O. and Kelly, B. M. (1963). Improved method for the

- determination of blood glutathione. *J Lab Clin Med*, 61: 882-888.
- [19] Aebi, H. (1984). Catalase *in vitro*. *Methods Enzymol*, 105: 121-126.
- [20] Nishikimi, M.; Rao, N. A. and Yag, K. (1972). The occurrence of superoxide anion in the reaction of reduced phenazine methosulfate and molecular oxygen. *Biochem Biophys Res Commun*, 46(2): 849-854.
- [21] Tice, R. R.; Agurell, E.; Anderson, D. *et al.* (2000). Single cell gel/comet assay: guidelines for *in vitro* and *in vivo* genetic toxicology testing. *Environ Mol Mutagen*, 35(3): 206-221.
- [22] Nandhakumar, S.; Parasuraman, S.; Shanmugam, M. M. *et al.* (2011). Evaluation of DNA damage using single-cell gel electrophoresis (comet assay). *J Pharmacol Pharmacother*, 2(2): 107-111.
- [23] Elbert, A.; Erdelen, C.; Kühnhold, J. *et al.* (2000). Thiacloprid, a novel neonicotinoid insecticide for foliar application. *Proc Brighton Crop Prot Conf-Pests and Diseases, BCPC, Farnham, Surrey, UK*, 21-26.
- [24] Arfat, Y.; Mahmood, N.; Tahir, M. U. *et al.* (2014). Effect of imidacloprid on hepatotoxicity and nephrotoxicity in male albino mice. *Toxicol Rep*, 1: 554-561.
- [25] Gawade, L.; Dadarkar, S. S.; Husain, R. *et al.* (2013). A detailed study of developmental immunotoxicity of imidacloprid in Wistar rats. *Food Chem Toxicol*, 51: 61-70.
- [26] Hussein, M.; Singh, V.; Hassan, M. A. *et al.* (2014). Malformations and teratogenic effects of imidacloprid on chick embryo. *Sch J Appl Med*, 2(1A): 67-72.
- [27] Abou Zeid, S. M. (2018). Developmental toxicity of acetamiprid in rats. *World J Pharm Sci*, 7(2): 113-126.
- [28] Pfeil R and Tasheva M (2006). Thiacloprid. Thiacloprid X-X JMPR, 451-556 (apps.who.int/pesticide-residues-jmpr-database/Document/140).
- [29] Zhang, H.; Bai, X.; Tao Zhang, T. *et al.* (2022). Neonicotinoid insecticides and their metabolites can pass through the human placenta unimpeded. *Environ Sci Technol*, 56(23), 17143-17152.
- [30] El-Borai, N. B.; Hadad, S. S. and Khalifa, H. K. (2019). Teratogenic effects of imidacloprid in rats: mechanistic role of oxidative stress. *Int J Pharmacol Toxicol*, 7(2): 35-43.
- [31] Houghton, P. E.; Mottola, M. F.; Plust, J. H. *et al.* (2000). Effect of maternal exercise on fetal and placental glycogen storage in the mature rat. *Can J Appl Physiol*, 25(6): 443-452.
- [32] Ford, K. A. and Casida, J. E. (2006). Unique and common metabolites of thiamethoxam, clothianidin, and dinotefuran in mice. *Chem Res Toxicol*, 19(11): 1549-1556.
- [33] Duzguner, V. and Erdogan, S. (2010). Acute oxidant and inflammatory effects of imidacloprid on the mammalian central nervous system and liver in rats. *Pestic Biochem Phys*, 97: 13-18.
- [34] Kapoor, U.; Srivastava, M. K.; Bhardwaj, S. *et al.* (2010). Effect of imidacloprid on antioxidant enzymes and lipid peroxidation in female rats to derive its No observed effect level (NOEL). *J Toxicol Sci*, 35(4): 577-581.
- [35] Wang, Y.; Li, X.; Yang, G. *et al.* (2020). Changes of enzyme activity and gene expression in embryonic zebrafish co-exposed to beta-cypermethrin and thiacloprid. *Environ Pollut*, 256: 113437 (DOI: 10.1016/j.envpol.2019.113437).
- [36] Kocaman, A. Y.; Rencüzoğulları, E. and Topaktaş, M. (2014). *In vitro* investigation of the genotoxic and cytotoxic effects of thiacloprid in cultured human peripheral blood lymphocytes. *Environ Toxicol*, 29(6): 631-641.
- [37] Galdíkova, M.; Šiviková, K.; Holečková, B. *et al.* (2015). The

- effect of thiacloprid formulation on DNA/chromosome damage and changes in GST activity in bovine peripheral lymphocytes. *J Environ Sci Health B*, 50(10): 698-707.
- [38] Galdíkova, M.; Holečkova, B.; Šiviková, K. *et al.* (2019). Evaluating the genotoxic damage in bovine whole blood cells *in vitro* after exposure to thiacloprid. *Toxicol In Vitro*, 61: 104616 (DOI: 10.1016/j.tiv.2019.104616).
- [39] Şenyıldız, M.; Kılınc, A. and Özden, S. (2018). Investigation of the genotoxic and cytotoxic effects of widely used neonicotinoid insecticides in HepG2 and SH-SY₅Y cells. *Toxicol Ind Health*, 34(6): 375-383.
- [40] Akkoç, H.; Acar, A.; Toprak, G. *et al.* (2020). Effects of sublethal doses of thiacloprid, a neonicotinoid insecticide, on learning and memory performance of mice. *Int J Pharmacol*, 16: 72-78.
- [41] Yahia, D.; Ali, M. F. and Abd El-Maguid, D. S. (2019). Estimation of bone marrow DNA damage induced by lambda cyhalothrin and dimethoate insecticides using alkaline comet assay. *J Adv Vet Res*, 9: 23-28.
- [42] Tsitsimpikou, C.; Tzatzarakis, M.; Fragkiadaki, P.; *et al.* (2013). Histopathological lesions, oxidative stress and genotoxic effects in liver and kidneys following long term exposure of rabbits to diazinon and propoxur. *Toxicology*, 307: 109-114.
- [43] Ferri, G. M.; Cavone, D.; Dambrosio, M. *et al.* (2019). Lymphocytes DNA damages and exposure to chlorpyrifos, deltamethrin, penconazole, copper oxichloride. *Biomark*, 24(2): 186-198.
- [44] Sule, R. O.; Condon, L. and Gomes, A. V. (2022). A common feature of pesticides: oxidative stress-the role of oxidative stress in pesticide-induced toxicity. *Oxid Med Cell Longev*, 2022: 5563759 (DOI: 10.1155/2022/5563759).

How to cite this article:

Dakrory, A. E.; Elsaed, O. I. and Omar, A. R. (2024). Effect of gestational exposure to neonicotinoid insecticide "thiacloprid" on Wistar rats and their fetuses. *Egyptian Journal of Zoology*, 82: 92-108 (DOI: 10.21608/ejz.2023.244904.1109).

تأثير التعرض في أثناء الحمل للمبيد الحشري النيونيكوتينويدي "ثياكلوبريد" على جردان ويستار وأجنتها

أحمد إمام دكروري، أمنية إبراهيم السعيد، أمل رمضان عمر

قسم علم الحيوان، كلية العلوم، جامعة القاهرة، الجيزة، جمهورية مصر العربية

الثياكلوبريد هو أحد المبيدات الحشرية في مجموعة النيونيكوتينويد، وهو أول مبيد حشري يحتوي على الكلورونيكوتينيل، وله تأثير كبير، وقد تم تطبيقه على العديد من المحاصيل لإدارة مجموعة متنوعة من أنواع الآفات. قد يستهدف الثياكلوبريد الكبد في المقام الأول، على الرغم من ظهور تقارير عن السمية الكلوية، وتشوهات جنينية، والتسبب في السرطان. تسعى الدراسة الحالية إلى التحقق من التأثير المشوه للأجنة، والمسبب للإجهاد التأكسدي، والتأثير السمي الحيني للثياكلوبريد بجرعة "1/40 و 1/20" من الجرعة المميتة للنصف "LD50" على أمهات الجردان الحوامل وأجنتها من اليوم السادس إلى اليوم العشرين من الحمل. أظهرت المجموعتان المعالجتان بالثياكلوبريد تشوهات تشمل الأجنة غير الموزعة بالتساوي عبر قرني الرحم، والأجنة الميتة، ومواقع الارتشاف في الرحم. ومن الناحية النسيجية، أظهرت أنسجة الكبد والكلى لدى الأم والجنين بعض التغيرات النسيجية المرضية. بالإضافة إلى ذلك، أظهرت أنسجة الكبد من كل من الأم والجنين زيادة ملحوظة إحصائياً ($P < 0.05$) في مستوى المالونداي ألدهيد (مما يدل على أكسدة الدهون)، وانخفاض ملحوظ إحصائياً ($P < 0.05$) في أنشطة الكاتلاز وديسموتاز الفائق الأوكسيد ومستوى الجلوتاثيون (مما يدل على خلل في نظام الدفاع المضاد للأكسدة)، مع ارتفاع ملحوظ إحصائياً ($P < 0.05$) في معامل المذنب (مما يشير إلى تلف الحمض النووي). نستنتج من هذه الدراسة، أن التعرض للثياكلوبريد خلال فترة الحمل لديه قدرة عالية لإحداث تأثيرات مشوهة للأجنة وسامة جينية، فضلاً عن الإجهاد التأكسدي، في الأمهات الحوامل وأجنتها. ووفقاً لنتائج الدراسة، قد تكون كل من الإناث الحوامل وأجنتها المعرضة لمادة الثياكلوبريد معرضة للخطر.