

Ameliorative Effects of Dietary Nanocurcumin Against Florfenicol Toxicity in *Clarias gariepinus*: A Study on the Biomarkers of Immunity and Oxidative Stress

Salwa Mansour^{1*}, Karima A. Bakry², Walaa F. A. Emeish², Zeinab Al-Amgad³,
Shimaa Henish⁴, Mervat Naguib⁵, Rehab H. Moneeb⁶

¹Zoology Department, Faculty of Science, South Valley University, Qena, Egypt

²Department of Fish Diseases, Faculty of Veterinary Medicine, South Valley University, Qena, Egypt

³General Authority for Veterinary Services, Qena Veterinary Directorate, Qena, Egypt

⁴National Inst. of Oceanography and Fisheries (NIOF), Egypt

⁵Department of Zoology, Faculty of Science, Assiut University, Assiut, Egypt

⁶Department of Zoology and Entomology, Faculty of Science, New Valley University, New Valley Egypt

*Corresponding Author: salwamansour305@yahoo.com

ARTICLE INFO

Article History:

Received: Nov. 19, 2023

Accepted: Dec. 5, 2023

Online: Dec. 23, 2023

Keywords:

Florfenicol,
Nanocurcumin,
Clarias gariepinus,
Antioxidant,
Immunoglobulin,
Histological alteration.

ABSTRACT

Diet quality has an important effect on the living organism's physiological biomarkers. This study aimed to investigate the modulation of the immune response and oxidative stress of *Clarias gariepinus* by the florfenicol (FFC) and nanocurcumin (NCur) as feed additives. Moreover, the ameliorative effects of NCur against FFC toxicity were assessed. Blood and serum biochemical parameters and histopathology of spleen and anterior kidney biopsies were examined after feeding. Four diet variants were formulated and used to feed the fish for 15 successive days; a basal (control), NCur, FFC and FFC combined with NCur. The results revealed that the FFC diet significantly reduced the hematological indices and induced changes in erythrocyte morphology, whereas leucocytes and mean corpuscular volume (MCV), and mean corpuscular hemoglobin (MCH) increased significantly. FFC significantly decreased superoxide dismutase (SOD), glutathione reductase (GSH), catalase (CAT), and immunoglobulin (Ig) levels and significantly increased malondialdehyde (MDA). Combination feeding of NCur and FFC restored some of the hematological changes, immune status, and minimized the oxidative damage induced by FFC. Additionally, it improved the histological aberrations observed in the fish spleen and anterior kidney. The current study revealed that NCur can be utilized as an ameliorative feed to reduce FFC-induced damage in catfish.

INTRODUCTION

In recent years, the number of studies examining how drugs affect the aquatic environment has increased. Due to the difficulties of contemporary aquaculture, the use of antibiotics is a necessary component. The antibiotics that have been licensed for use in aquaculture recently included FFC (USFWS, 2015). FFC is a broad-spectrum antibiotic that structurally related to the antibiotics chloramphenicol (CA) and thiamphenicol (TA) (Moore,

2007). Due to its high lipophilicity, it can treat intracellular infections and pass through various anatomical barriers (penetration across the blood) by providing concentrations that are high enough (Papich, 2016). Moreover, attributed to its broad spectrum of activity against Gram-positive and Gram-negative bacteria, including *Aeromonas salmonicida*, *A. hydrophyla*, *Vibrio anguillarum*, *Yersinia ruckeri*, and *Flavobacterium psychrophilum*, FFC has been frequently utilized to treat fish illnesses (Carraschi *et al.*, 2011).

Despite the advantages of using antibiotics like FFC in fish production, problems have been linked to their use, including the immunosuppression, growth restriction, the emergence of bacterial species that are resistant to antibiotics, and environmental problems such as drug residues (Saglam & Yonar, 2009; Tapia-Paniagua *et al.*, 2015). According to studies by Zaki *et al.* (2011) and Oliveira *et al.* (2013), FFC demonstrated immunotoxicity to aquatic organisms by inducing oxidative damage and triggering the generation of reactive oxygen species (ROS). Excessive ROS can result in enzyme inactivation, such as SOD, CAT, and glutathione peroxidase (GPx) in addition to oxidative damage as lipid peroxidation (LPO) (Ray *et al.*, 2012).

Additionally, multiple studies (Kori-Siakpere *et al.*, 2010; Reda *et al.*, 2013) have shown that long-term histopathological alterations in fish tissues treated with antibiotics are produced by biochemical factors. Cultured *Oreochromis niloticus* kept on oxytetracycline and FFC-supplemented diet showed variations in immunoglobulin M activities, showing that antibiotic residues have varied effects on immune, liver, and kidney functions (Reda *et al.*, 2013). In light of this, a key mechanism determining the toxicity of various antibiotics (Kladna *et al.*, 2012) and FFC (Ren *et al.*, 2014) appears to be associated to a modification in antioxidant defenses brought on by ROS accumulation.

According to Lestari and Indrayanto (2014), curcumin is the primary bioactive component of *Curcuma longa* rhizomes and accounts for 77% of the curcuminoids found in turmeric. In this respect, Amalraj *et al.* (2017) reported that curcumin has a number of biological benefits, including anti-inflammatory, anti-oxidant, and anti-microbial actions. In comparison to traditional bulk curcumin, curcumin in nanoparticle form exhibits an improved aqueous medium dispersion and absorption (Moniruzzaman & Min, 2020). We predicted that curcumin would help alleviate antibiotic-related negative indicators affecting our targeted fish based on these qualities. According to many researchers (Abdel-Tawwab *et al.*, 2021; Moghadam *et al.*, 2021), nano-sized feed additives increase the performance and welfare status of a variety of fish species. Therefore, the aim of the present study was to investigate the effects of FFC antibiotic and NCur as feed additives for *C. gariepinus* and clarify the ameliorative effect of NCur against FFC toxicity. The influence of such additives on the hematologic parameters, non-specific immune response, oxidative stress of *C. gariepinus*, and their histopathological effects were evaluated.

MATERIALS AND METHODS

Preparation of florfenicol diet

Florfenicol, a common antibiotic in aquaculture, was obtained from Arabcomed, Marcyrl Pharmaceutical Industries, Egypt. FFC was used as an additive in the fish diet at a dose (30mg/ kg biomass) of fish biomass per day. The dose of FFC used in this experiment were prepared, following the guildelines outlined by **Mansour *et al.* (2023)**.

Preparation of curcumin nanoparticles

Curcumin powder was obtained from SD-fine Chemicals Limited (SDFCL, India) and was characterized to be in a nano form by using the method mentioned by **Mansour *et al.* (2023)** to obtain 150ppm of NCur.

Experimental protocol

Four different diets, representing 4 diet experimental groups, were prepared. A control group was fed on basal diet that was obtained from Skretting Company, Egypt. The three other diets were formulated as a nanocurcumin (NCur) diet (basal diet with 150ppm of NCur), florfenicol (FFC) diet (basal diet with 30mg/ kg biomass of FFC), and FFC + NCur (basal diet with 30mg/ Kg biomass of FFC and 150ppm of NCur). All steps of this experiment were reviewed and approved by the Research Ethics Committee of the Faculty of Veterinary Medicine at South Valley University with the approval number (No. 44/06.09.2022). A live catfish, *C. gariepinus* (150.7± 4.6g) was purchased from a private fish farm and transported to the Fish Diseases Department Wet Lab., Faculty of Veterinary Medicine, South Valley University. The fish were acclimated to the laboratory conditions for 2 weeks in 600L tank. Moreover, the experiment was done using forty eight catfish, *C. gariepinus*, which were divided into 4 tanks (six fish per tank) in duplicate. Each group, consisting of 12 fish, was fed ad libitum with the designated diet once a day for 15 successive days. Throughout the experiment, the temperature was maintained at 26± 0.5°C and the dissolved oxygen level was determined at 7.5± 0.4 mg/ l, while the pH levels were 7.5± 0.3.

Blood analysis

After the blood samples collection on EDTA, routine hematological analyses were manually carried out, according to the method outlined by **Bates and Carter (2017)**. The analyses included: 1) Red blood cells (RBCs) parameters such as RBCs count ($10^6/\text{mm}^3$), hemoglobin (Hb) concentration (g/ dl), hematocrit value (HCT, %), mean corpuscular volume (MCV, μm^3), mean corpuscular hemoglobin (MCH, pg) and mean corpuscular hemoglobin concentration (MCHC, %), and 2) white blood cells count (WBCs). For RBCs and WBCs counts, anticoagulated blood was diluted at a ration of 1: 200 using Natt-Herrick solution in diluting pipette. The mixture was well mixed, and a drop was placed on the counting area of clean and dry Neubauer hemocytometer, which was covered with a cover slide. After allowing the cells to settle, RBCs were counted in 5 secondary squares. The final cells count (N) was multiplied by 10000 to obtain RBCs count ($10^6/\text{mm}^3$). For WBCs, anticoagulated blood was diluted 1: 20 using WBCs diluting pipette. Afterward, WBCs were counted in

primary squares, and the final number (N) was multiplied by 50 to obtain WBCs count ($10^6/\text{mm}^3$). Hb concentration was determined by using cyanmethemoglobin technique. Additionally, HCT was carried out by utilizing microhematocrit method using microhematocrit tubes and centrifuge, according to outlines of **Adebayo *et al.* (2007)**. All erythrocytes indices were calculated using the method of **Lavanya *et al.* (2011)**.

Furthermore, one drop of fresh anticoagulated blood was smeared on a dry and clean glass slide, dried, and fixed for 5min using absolute methanol. The smear was then stained by Hematoxylin and Eosin (H&E) stain for monitoring abnormalities in blood cells.

Estimation of oxidative stress parameters and immune assay

The activities of CAT and SOD were determined by using local reagent kits purchased from Biodiagnostic, Giza, Egypt. The serum GSH was calculated using the spectrophotometric technique described by **Beutler *et al.* (1963)**. Moreover, the test was carried out in accordance with the reagent kit instructions that were acquired from Biodiagnostic, Egypt. Serum Ig was conducted using the ELISA technique (Dynatech Microplate Reader Model MR 5000). Determination of MDA was performed, following the technique of **Ruiz-Larrea *et al.* (1994)**; the technique is based on the reaction with thiobarbituric acid (TBA), which gives a pink complex that is actually measured photometrically. Serum Ig was quantified using reagent kits (SG-10057) acquired from SinoGeneClon Biotech Co., Ltd., No. 9 BoYuan Road, YuHang District 311112, Hang Zhou, China.

Histopathology

Fresh tissues from the spleen and anterior kidney were extracted and fixed in 10% neutral buffered formalin. Histological sections were monitored, as outlined by **Carleton (1980)**. Photomicrographs of sections stained with H&E and Periodic Acid-Schiff (PAS) stain to detect mucopolysaccharides and glycogen content that were examined under microscope and imaged.

Statistical analysis

The obtained data were written as a mean \pm SEM and were analyzed through ANOVA. TUKEYs Post-Hoc test was employed for comparison between groups. The difference was accepted as a significant when $P < 0.05$. Statistical analyses were executed using (IBM-SPSS) program Version: 21.

RESULTS

1. Haematological parameters

The hematological parameters in control and treated fish are presented in Table (1). Fish fed on NCur diet showed insignificant increase in RBCs count, Hb, and HCT compared to the control group. However, those fed on FFC diet disclosed a significant decrease in the same three parameters. The deterioration in RBCs count and Hb was ameliorated by NCur when combined with FFC and only recovered around the control level. Regarding erythrocyte indices, MCV, and MCH increased significantly after feeding on FFC diet and rescued after

combination with NCur. WBCs showed a significant increase in FFC group, compared to the control group, while recovering to the control level in the FFC + NCur group.

2. Erythrocyte morphological changes

The blood smears of both control and NCur groups showed erythrocytes with normal shape and structure (Fig. 1A, B). RBCs of the *C. gariepinus* fed on FFC diets revealed variations in shape, and these morphological changes are described in Fig. (1C). Furthermore, in fish fed on FFC and NCur, the RBCs showed improvement with some alterations (Fig. 1D).

3. Antioxidant and immunity biomarkers

The activities of SOD, GSH and CAT in the serum sample of four different diets are shown in Fig. (2A, B, C). The FFC diet revealed significant effects on SOD, GSH and CAT activities, represented in their decrease compared to the control and NCur groups. Feeding NCur + FFC diet restored significantly the decreased GSH level to be as NCur group level. The decreased SOD activity was insignificantly increased when the catfish specimens were fed a combination of NCur and FFC, while CAT antioxidant in fish feeding NCur + FFC diet couldn't restore the CAT level. In lipid peroxidation that is represented by the MDA level, FFC treated group showed a significant increase in comparison to the control, as shown in Fig. (2D). Feeding NCur + FFC diet showed significant effect on the MDA level. Analysis of serum Ig showed a significant decrease in FFC treated group, as shown in Fig. (2E). Feeding NCur with FFC significantly restored the serum Ig level near to the control group. Additionally, NCur group showed a significant decrease in serum Ig level in comparison to the control group.

4. Histopathology

Microscopic findings

The microscopic findings in the present study exhibited remarked histological alterations induced after FFC administration at a high dose, compared with those findings in combined treated groups, which attenuated by NCur administration, as shown in Table (2).

Hematoxylin and eosin (H&E) stain

Spleen

The light microscopy of control spleen illustrated normal arrangement of the splenic pulps fundamentally composed of white and red pulps (Fig. 3A). In the footsteps of the control group, NCur-treated fish demonstrated normal histological arrangement of the splenic pulps (Fig. 3B). In FFC group, depletion of the lymphoid follicles was severely conducted in addition to the thrombotic vasculitis of the blood vessels (Fig. 3C). Meanwhile, FFC + NCur group suffered from mild lymphoid depletion of the white pulps, besides congested and thickened blood vessels (Fig. 3D).

Anterior kidney

Light microscopy of the anterior kidney of the control group illustrated intact nephritic tubules with healthy hematopoietic tissues (Fig. 4A). Likewise, the NCur group manifested intact tubular epithelium and lymphoid tissues (Fig. 4B). Necrosis with cytoplasmic vacuolation of the nephritic tubules, and severe dilatation and congestion of the renal blood

vessels in FFC group are displayed in Fig. (4C). The FFC + NCur group afforded degenerative changes and cytoplasmic vacuolation of the renal tubules (Fig. 4D).

Periodic Acid Schiff (PAS)

Spleen

Periodic Acid Schiff (PAS) stained spleen section of the control and NCur groups revealed heavily distributed glycogen content expressed by marked red staining (Fig. 5A, B). On the other hand, examination of splenic tissues of FFC group exhibited decrement in its glycogen content with pale stain color (Fig. 5C). With respect to FFC + NCur, it showed a moderate degree of glycogen content of splenic pulps with darkish red coloration (Fig. 5D).

Anterior kidney

Periodic Acid Schiff (PAS) stained renal section of the control catfish revealed normally expressed glycogen with deep red coloration (Fig. 6A). Similarly, the NCur fish group manifested piercing infiltration of polysaccharides (Fig. 6B). Contrariwise, the histological section of the anterior kidney of FFC group appeared weakly red colored (Fig. 6C). Regarding the combination of FFC & NCur, it showed moderate glycogen content of moderate red coloration (Fig. 6D).

Table 1. The effect of four different diets used to feed catfish for 15 successive days on blood parameters

Parameter Treatments	Control	NCur	FFC	FFC + NCur
RBCs (Million/ mm³)	2.9± .07 ^a	3.02± .13 ^a	2.3± .06 ^b	2.8± .07 ^a
Hb (g/ dl)	7.9± .08 ^a	8.2± .12 ^a	7.07± .08 ^b	7.8± .06 ^a
HCT (%)	29.1± 0.06 ^a	29.3± 0.1 ^a	26.5± 0.16 ^c	28.7± 0.17 ^b
MCV (µm³)	100.6± 2.2 ^a	97.4± 3.7 ^a	111.6± 2.5 ^b	104.3± 1.8 ^a
MCH (Pg)	27.3± .4 ^a	27.2± 0.7 ^a	29.8± 0.5 ^b	28.6± .04 ^a
MCHC (%)	27.1± 0.3 ^a	27.9± 0.4 ^a	26.7± 0.2 ^a	27.4± 0.06 ^a
WBCs (Thousands/ mm³)	32.2± 0.8 ^a	34.4± 0.4 ^a	36.8± 1 ^b	32.1± 1 ^a

The data represent the average of two experiments; data are presented as Means ± SEM (N= 4). Different letters in the same raw indicate significant difference at $P < 0.05$. NCur: Nanocurcumin (150ppm), FFC: Florfenicol (30mg/ kg biomass), RBCs: Red blood cells, Hb: Hemoglobin, Hct: Hematocrit, MCV: Mean corpuscular volume, MCH: Mean corpuscular hemoglobin, MCHC: Mean corpuscular hemoglobin concentration, WBCs: White blood cells, Lym: Lymphocytes, and Mono: Monocytes.

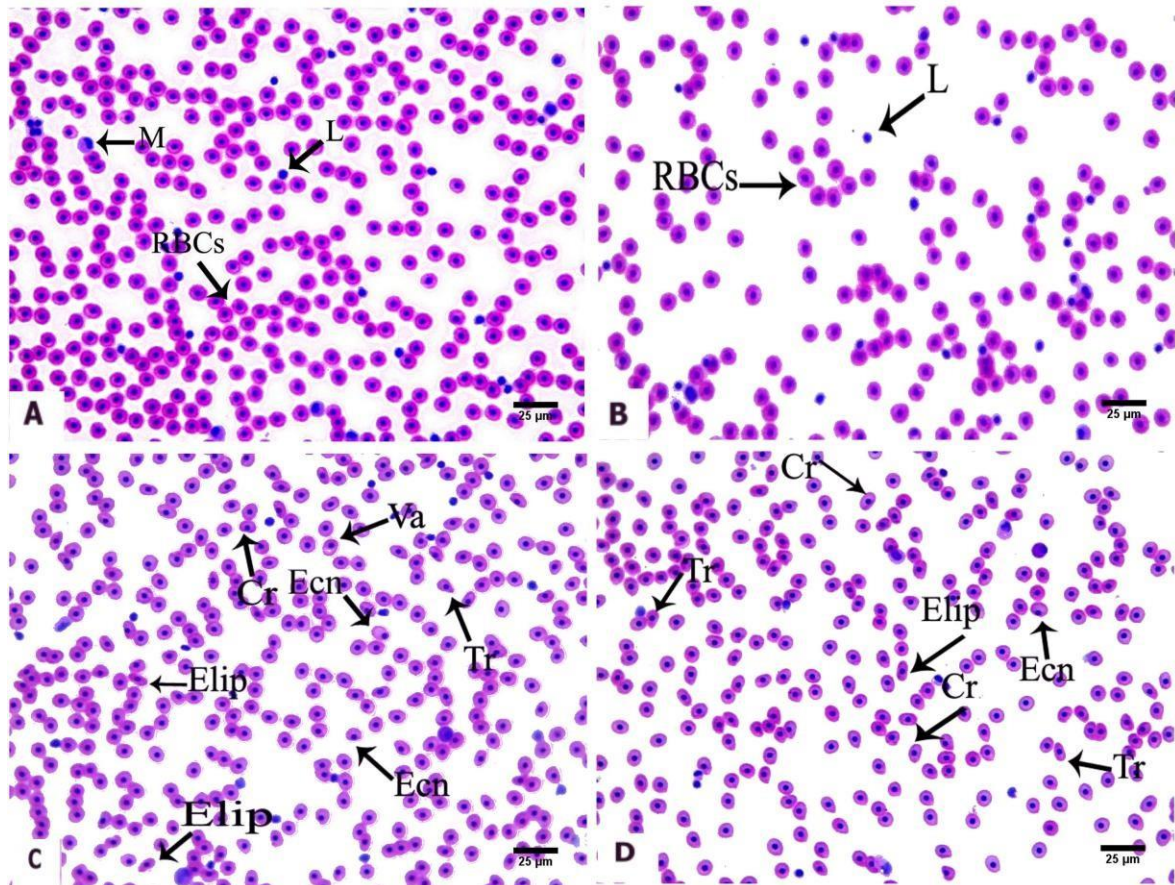


Fig. 1. H&E-stained blood smears of catfish fed on four different diets showing normal erythrocytes in control and NCur groups (A&B); Deformed erythrocytes in FFC group (C), Deformed erythrocytes in FFC + NCur group (D). Tr: Tear-drop cell, Cr: Crenated cell, Va: Vacuolated cells, Ecn: Eccentric nucleus, and Elip: Elliptocyte

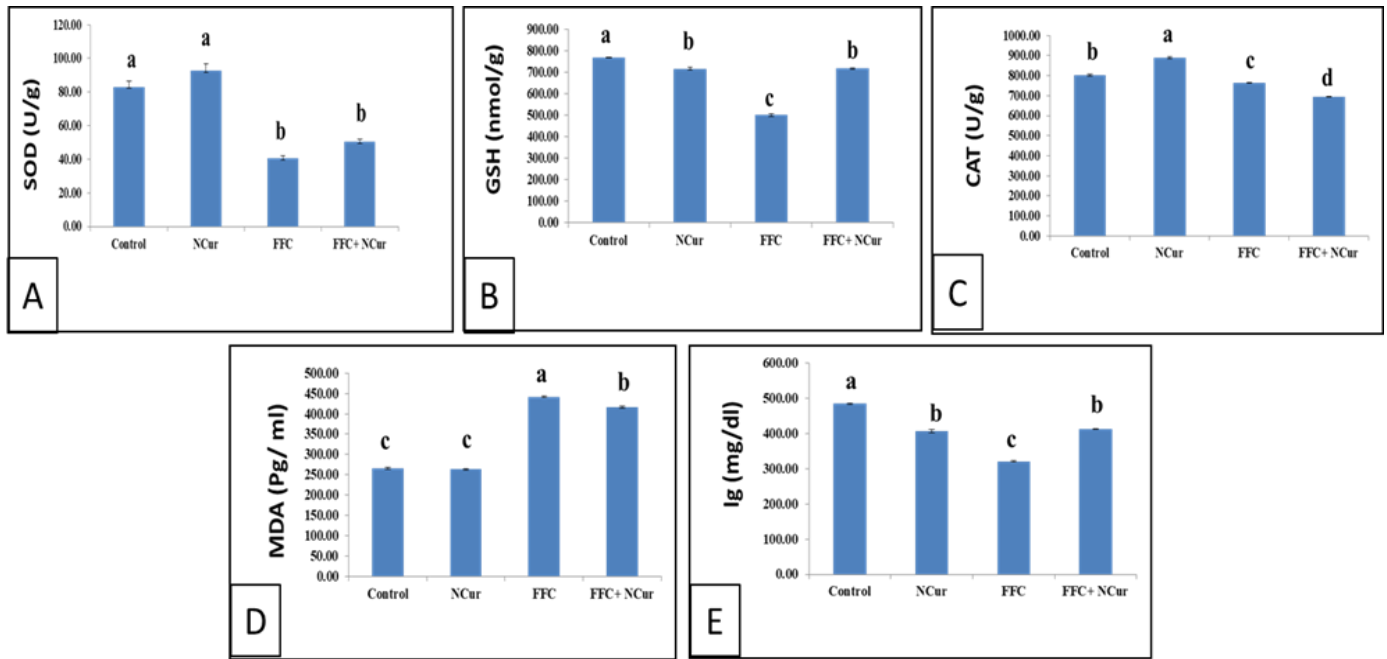


Fig. 2. The effect of four different diets used to feed catfish on serum antioxidant and immune parameters showing: (A) SOD, (B) GSH, (C): CAT, (D) MDA, and (E) Ig. The data are presented as Means \pm SEM (N= 4). Bars with different letters indicate significant difference at $P < 0.05$

Table 2. Histopathological scoring of anterior kidney and spleen of catfish fed on four different diets for 15 successive days

Histological lesion	Control	NCur	FFC	FFC + NCur
Anterior kidney				
Necrosis of renal tubules	-	-	+++	++
Depletion of hematopoietic tissues	-	-	+++	++
Cytoplasmic vacuolation and Degeneration of renal tubules	-	+	+++	++
Glycogen content	+++	+++	+	+
Hemorrhage with erythrocytes infiltration	+	+	+++	++
Perivascular lymphocytes infiltration	-	-	+++	+
Thickening of blood vessels	-	+	+++	+
Spleen				
Lymphoid depletion of white pulp and hematopoietic tissues	-	-	+++	++
Glycogen content	+++	+++	+	++
Hemorrhage of red pulp	+	+	+++	+
Melanomacrophages infiltration	+	-	++	++
Thickening and congestion of the blood vessels	-	-	+++	++

Score: absent (-), mild (+), moderate (++) and severe (+++). NCur: Nanocurcumin (150ppm), FFC: Florfenicol (30mg/ kg biomass).

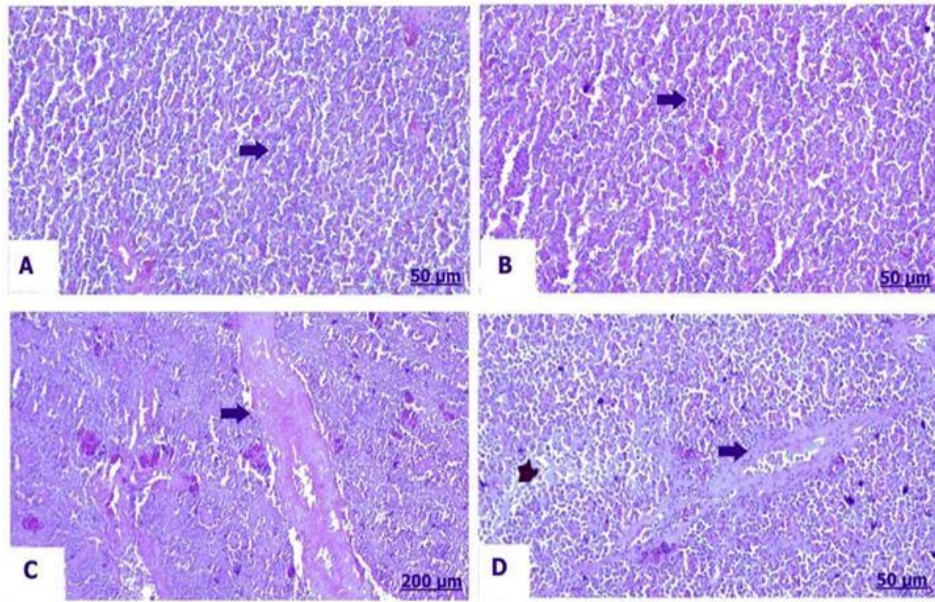


Fig. 3. H&E-stained transverse sections of the spleen of catfish fed on four different diets showing: (A) Control group showing normal architecture of splenic pulps, (B) NCur group showing healthy white and red pulps, (C) FFC group showing thrombotic vasculitis, and (D) FFC + NCur group showing moderate degree of congested and thickened blood vessels (arrow), besides lymphoid depletion (star). Scale bar = 50 & 200µm

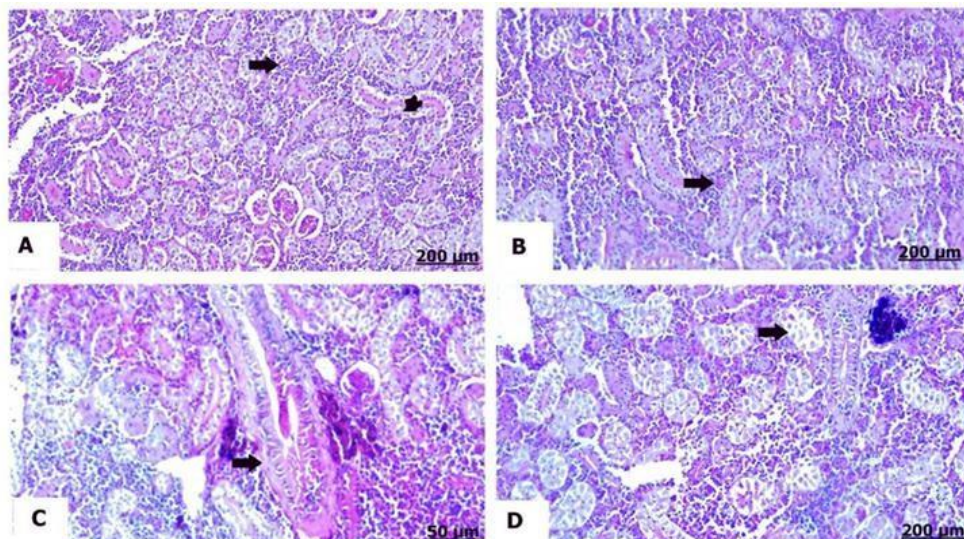


Fig. 4. H&E-stained transverse sections of the anterior kidney of catfish fed on four different diets showing: (A) Control group showing intact hematopoietic tissues (arrow) and nephritic tubules (star), (B) NCur group showing normal hematopoietic tissues, (C) FFC group showing severe congestion and dilatation of the renal blood vessels, and (D) FFC + NCur group showing degeneration with cytoplasmic vacuolation of the renal tubules. Scale bar = 50 & 200µm

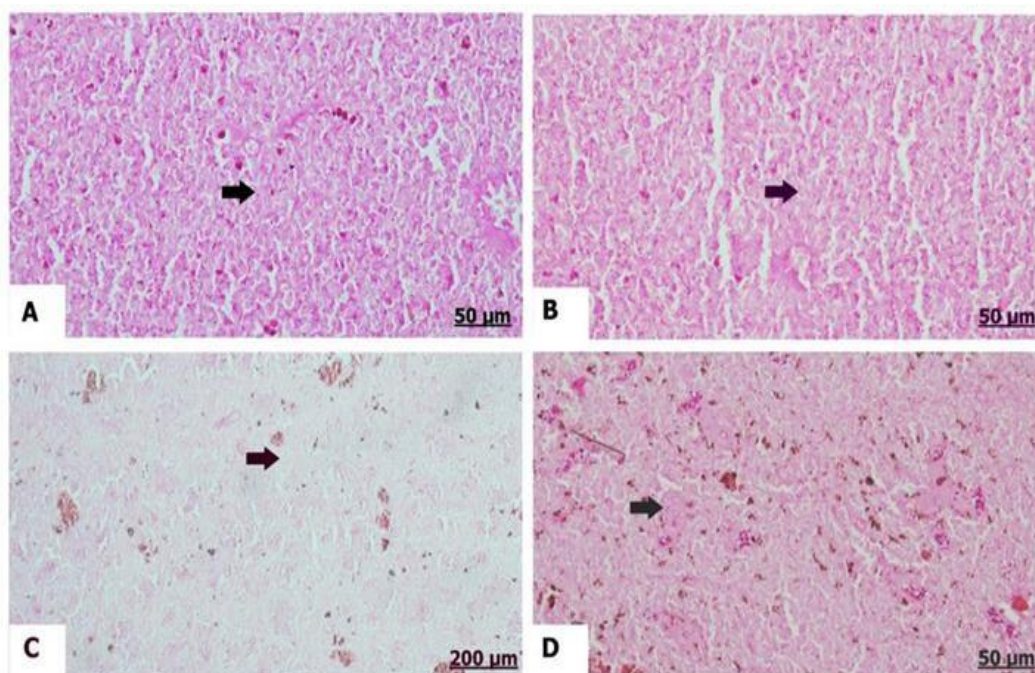


Fig. 5. Light photomicrograph of transverse sections stained with PAS of the spleen of catfish fed on four different diets showing: (A) Control group showing sharp distributed glycogen; (B) NCur group showing deeply stained red color of the glycogen; (C) FFC group showing depleted glycogen content, and (D) FFC + NCur group showing moderate glycogen with moderate stained red color. Scale bar= 50 & 200μm

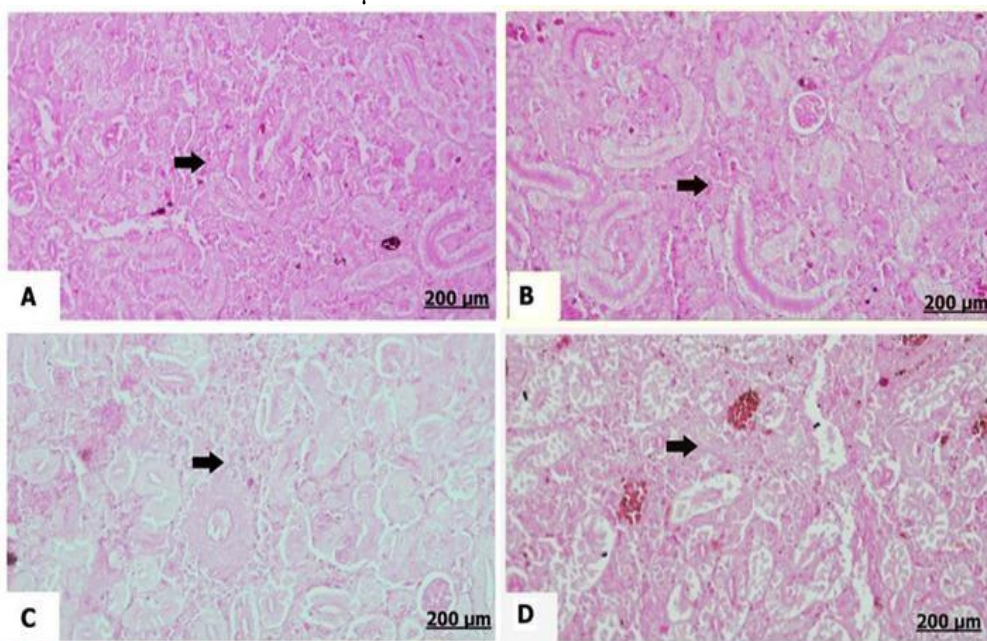


Fig. 6. Light photomicrograph of transverse sections stained with PAS of the anterior kidney of catfish fed on four different diets showing: (A) Control group showing normal glycogen distribution with darkish red color; (B) NCur group showing intense glycogen content; (C) FFC group showing weak infiltration of the glycogen content, and (D) FFC + NCur group showing moderate deposited glycogen content. Scale bar= 200μm

DISCUSSION

The prolonged abuse of FFC for treatment, prophylaxis, or as feed additives is associated with dangerous side effects, including alterations of hematological parameters (Cabello *et al.*, 2013; Shah *et al.*, 2016). The use of high dose of FFC in fish feed was associated with a decrease in RBCs count, Hb concentration, and HCT%, in addition to an elevation of MCV and MCH. The alteration of the previous parameters led to an oxidative stress stimulating mitochondrial dysfunction (Kuter & Tillotson, 2001), which resulted from the cytotoxic and genotoxic effect of FFC induced by chromosomal disparities (Botelho *et al.*, 2015). Furthermore, the high dose of FFC interfering the erythropoiesis involves hemopoietic toxicity. Subsequently, it deteriorates the heme synthesis in RBCs mitochondria (Abou-Khalil *et al.*, 1987; Bardhan *et al.*, 2022a). Erythropoietin hormone secreted from the kidney is the key factor in erythropoiesis in the bone marrow. It is reported that FFC has suppressive effect on erythropoietin hormones by degenerative changes of renal tissue and atrophy of bone marrow, moreover this is associated with an elevation of the iron-binding protein in the plasma, leading to the decrease in the amount of iron that is incorporated in erythropoiesis (Hu *et al.*, 2016). The decrease in Hb level was due to anemia resulting from deficiency in oxygen supply or due to the inhibition effect on the enzyme system which synthesizes Hb (Bardhan *et al.*, 2022a). Increasing in MCV and MCH values may be attributed to the presence of many irregular and swollen erythrocytes (Bojarski & Witeska, 2020). In our study, FFC group fish suffer from macrocytic hypochromic anemia due to a significant decrease in Ht, Hb, and RBCs, in addition to a significant increase in MCV and MCH, as recorded by Abubakar and Abdulsalami (2013) and Javed *et al.* (2016).

Undesirable effects of FFC extended to WBCs, with a high dose resulting in an increase in total leukocytic count, possibly due to a reduction in the antioxidant levels by FFC (Shiroma *et al.*, 2020) or as a protective response against the effect of FFC (Bardhan *et al.*, 2022a). Blood cell alterations observed in the FFC-fed fish suggest a cytotoxic effect of florfenicol. FFC reduces hemoglobin content, leading to a decrease in oxygen-carrying capacity, and induces morphological changes in the membrane of red blood cells (RBCs) (Botelho *et al.*, 2015; Bardhan *et al.*, 2022a). Additionally, oxidative stress and lipid peroxidation in fish tissues may increase erythrocyte alterations (Bardhan *et al.*, 2022b). NCur can rescue the adverse effects when combined with FFC; it improved the hematological parameters. This is attributed to the role of curcumin in promoting erythropoiesis (Abdel-Tawwab *et al.*, 2021). Dietary supplementation of curcumin or NCur improved the hematological parameters and promoted the health of the fish (Abdel-Tawwab *et al.*, 2021).

The antioxidant system plays a significant role in immunity and health, and several studies have found a beneficial correlation between the fish and shellfish immune responses and antioxidant activity. ROS are transformed into less reactive forms by the primary endogenous enzymes of this system, SOD, CAT, and GPx (Livingstone, 2001;

Abdel-Tawwab & Wafeek, 2017; Hoseinifar et al., 2020). These enzymes protect the cells from oxidative stress. Furthermore, lipid peroxidation produces MDA, which is a sign of an oxidative damage to lipids (**Ayala et al., 2014; Bradley-Whitman & Lovell, 2015**). The use of antibiotics in aquaculture has beneficial advantages; however, their inappropriate usage can also pose a number of risks and have negative consequences on the fish, especially what concerns the cells and their oxidative stress. These antibiotics' negative side effects are known to harm fish's immunological, circulatory, and metabolic systems, as well as their growth and development (**Yang et al., 2020**).

In this study, we observed modulation of the antioxidant enzymes in FFC feeding group represented by a lowering of the activity of SOD, GSH, CAT, in addition to a rise in the level of MDA. Decrease in SOD may have led to a significant buildup of superoxide anions. According to **Kono and Fridovich (1982)**, higher hydrogen peroxide (H_2O_2) levels might further reduce SOD activity. *Oncorhynchus mykiss* that received 7.5 and 15mg/ kg FFC for 10 days showed similar results of lowered SOD (**Elia et al., 2016**). According to **Chen et al. (2016)**, the oxidation of the sulfhydryl group by ROS to create combining oxidized disulfide compounds may be the cause of the reduction in GSH activity in *C. gariepinus* treated with FFC. According to **Farombi (2001)**, the low activities of CAT observed in *C. gariepinus* treated with FFC may be related to the increase of H_2O_2 and hydroxyl radical-inducing oxidative stress.

The present study found a higher MDA activity, suggesting that FFC may indeed cause hepatic oxidative stress. This was confirmed by the finding that tissue MDA levels directly demonstrate lipid peroxidation brought on by free radicals or disordered lipid metabolism (**Jin et al., 2013**). Serum Ig is a key element of the immune system and can be extremely important in phagocytosis, opsonization, and in neutralizing harmful pathogens (**Cuesta et al., 2004; Magnadottir, 2010**). In the current study, the decrease in the level of Ig induced by FFC treatment is a vital indicator of fish immunity. Studies have shown that FFC altered the antioxidant defense and immune response in *Gadus morhua* (**Caipang et al., 2009**) and in *Dicentrarchus labrax* (**Zhang et al., 2021**). Decline of Ig level in NCur group in the current study may be attributed to the relationship between curcumin and immunoglobulin levels which is complex and not fully understood (**Lee et al., 2013; Cui et al., 2016**). Previous study have shown that curcumin can decrease Ig levels, while others have shown that it can increase Ig levels. It is possible that the effect of curcumin on Ig levels depends on the individual and the specific type of Ig. Overall, the evidence suggests that curcumin may have a complex effect on Ig levels. Thus, more research is needed to determine the specific effects of curcumin on different types of Ig and in different populations.

Feeding NCur to *C. gariepinus* dramatically increased GSH and Ig levels while decreasing MDA as a reducing marker against FFC disorders. Curcumin's high polyphenol content, which might prevent oxidative damage by scavenging ROS and boosting GSH and Ig levels, may be responsible for its antioxidant capabilities. The

higher level of Ig in FFC + NCur group than that recorded in FFC group is connected to the activation of humoral immunity in *C. gariepinus*. NCur of ≥ 100 mg/ kg feed improved the non-specific immune response and antioxidant activity in the Nile tilapia under temperature stress (**El Basuini *et al.*, 2022**).

Histopathological findings recorded necrosis and cytoplasmic vacuolation of the nephritic tubules, as well as depletion of the splenic tissues in FFC groups. Similar results were discovered by **Gaikowski *et al.* (2012)**, who observed cellular degeneration which is distinguished by cytoplasmic vacuolation, besides the lymphoid depletion with decreased number of tissue lymphocytes. Furthermore, we could say that the damaging effect induced by FFC in fish was in turn of lipid peroxidation which is attributed to cell damage associated with oxidative stress and cytotoxicity that excites a series of cell components lesions (**Wang *et al.*, 2021**). Earlier, elevated MDA level was noticeable in fish species following FFC medication, which led to cellular oxidation and injury (**Limbu *et al.*, 2018**), and destroyed antioxidant enzymes system (**Shiroma *et al.*, 2020**), which probably disturbed and/or suppressed the FFC metabolism in the hepato-renal tissues. A decrease in the lymphoid tissue of the spleen was predominantly owing to mature lymphocytes damage resulting from concurrent exhaustion in necrobiotic changes and proliferative process of blast cell. The basic effect associated with commitment antibiotics toxicity on lymphoid tissues with compensatory increase in blast cells differentiation in response to cellular damage, that is, lowered mature lymphocytes and rise cell necrosis. Cell necrosis symbolizes primarily finding of cytotoxicity owing to FFC therapy in the fish (**Gaikowski *et al.*, 2012**). Phenicol antibiotic group could suppress immune response of teleost fish, with FFC being able to combine in the kidney and disturb cellular metabolism (**Shuang *et al.*, 2011**). Taken together, the combination of NCur and FFC ameliorated histological damages developed by FFC. The protective properties of curcumin on the damaged kidney turned into its antioxidant and free radical scavenging roles (**Khan *et al.*, 2019**). Similarly, curcumin restored the histological damage induced in the spleen by virtue of lead toxicity through its own immunomodulatory, antioxidant, and gene-regulating characters (**Emam *et al.*, 2023**).

CONCLUSION

High-dose florfenicol administration alters hematological indices, induces oxidative damage, suppresses fish immunity, and can deteriorate the integrity of splenic and renal tissues. This detrimental effect is significantly reversed by combining florfenicol with nanocurcumin in the fish diet. Consequently, precautions must be taken, especially when high concentrations of FFC are used in long-term treatments of *C. gariepinus* in aquaculture.

REFERENCES

- Abdel-Tawwab, M.; Shukry, M.; Farrag, F.A.; El-Shafai, N.M.; Dawood, M.A. and Abdel-Latif, H.M.** (2021). Dietary sodium butyrate nanoparticles enhanced growth, digestive enzyme activities, intestinal histomorphometry, and transcription of growth-related genes in Nile tilapia juveniles. *Aquaculture*, 536736467.
- Abdel-Tawwab, M. and Wafeek, M.** (2017). Fluctuations in water temperature affected waterborne cadmium toxicity: hematology, anaerobic glucose pathway, and oxidative stress status of Nile tilapia, *Oreochromis niloticus* (L.). *Aquaculture*, 477106-111.
- Abou-Khalil, S.; Abou-Khalil, W.H.; Whitney, P.L. and Yunis, A.A.** (1987). Importance of the mitochondrial amino acid pool in the sensitivity of erythroid cells to chloramphenicol: role of glycine and serine. *Pharmacology*, 35(6): 308-316.
- Abubakar, M.I. and Abdulsalami, S.A.** (2013). Induction of Microcytic-Hypochromic Anaemia in *C. gariepinus* (Burchell, 1822) Exposed to Sublethal Toxicity of 2, 3-Dichlorovinyl Dimethyl Phosphate (Sniper 1000EC) Under Laboratory Conditions. *Journal of Medical and Applied Biosciences*, 5(2): 62 - 72.
- Adebayo, O.; Fagbenro, O.; Ajayi, C.B. and Popoola, O.M.** (2007). Normal Haematological Profile of Parachanna obscura as a Diagnostic Tool in Aquaculture. *International Journal of Zoological Research*, 3193-199.
- Amalraj, A.; Pius, A.; Gopi, S. and Gopi, S.** (2017). Biological activities of curcuminoids, other biomolecules from turmeric and their derivatives—A review. *Journal of traditional and complementary medicine*, 7(2): 205-233.
- Ayala, A.; Muñoz, M.F. and Argüelles, S.** (2014). Lipid Peroxidation: Production, Metabolism, and Signaling Mechanisms of Malondialdehyde and 4-Hydroxy-2-Nonenal. *Oxidative Medicine and Cellular Longevity*, 2014360438.
- Bardhan, A.; Abraham, T.J.; Das, R. and Patil, P.K.** (2022a). Biological Responses of Nile tilapia *Oreochromis niloticus* as Influenced by Dietary Florfenicol. *Toxics*, 10(10): 571.
- Bardhan, A.; Abraham, T.J.; Singha, J.; Sar, T.K.; Rajisha, R.; Krishna, E.K.N.; Kumar, K.A. and Patil, P.K.** (2022b). Histopathological aberrations and oxidative stress responses in Nile tilapia *Oreochromis niloticus* as influenced by dietary florfenicol and its metabolites. *Aquaculture*, 559738447.
- Bates, I. and Carter, J.Y.** (2017). Haematology in Under-Resourced Laboratories, in: Bain, B.J., Bates, I., Laffan, M.A. (Eds.), *Dacie and Lewis Practical Haematology* (Twelfth Edition). Elsevier, pp. 546-560.
- Beutler, E.; Duron, O. and Kelly, B.M.** (1963). Improved method for the determination of blood glutathione. *The Journal of laboratory and clinical medicine*, 61882-888.
- Bojarski, B. and Witeska, M.** (2020). Blood biomarkers of herbicide, insecticide, and fungicide toxicity to fish-a review. *Environmental Science and Pollution Research*, 27(16): 19236-19250.
- Botelho, R.G.; Christofolletti, C.A.; Correia, J.E.; Ansoar, Y.; Olinda, R.A. and Tornisiello, V.L.** (2015). Genotoxic responses of juvenile tilapia (*Oreochromis niloticus*) exposed to florfenicol and oxytetracycline. *Chemosphere*, 132206-212.
- Bradley-Whitman, M.A. and Lovell, M.A.** (2015). Biomarkers of lipid peroxidation in Alzheimer disease (AD): an update. *Archives of Toxicology*, 89(7): 1035-1044.

- Cabello, F.C.; Godfrey, H.P.; Tomova, A.; Ivanova, L.; Dölz, H.; Millanao, A. and Buschmann, A.H.** (2013). Antimicrobial use in aquaculture re-examined: its relevance to antimicrobial resistance and to animal and human health. *Environ. Microbiol.*, 15(7): 1917-1942.
- Caipang, C.M.A.; Lazado, C.C.; Brinchmann, M.F.; Berg, I. and Kiron, V.** (2009). In vivo modulation of immune response and antioxidant defense in Atlantic cod, *Gadus morhua* following oral administration of oxolinic acid and florfenicol. *Comparative Biochemistry and Physiology, Part C: Toxicology & Pharmacology*, 150(4): 459-464.
- Carleton, H.M.** (1980). Carleton's Histological technique, in: Drury, R.A.B., Wallington, E.A. (Eds.), 5th ed. Oxford University Press, Oxford.
- Carraschi, S.P.; Shiogiri, N.S.; Venturini, F.P.; Cruz, C.; Girio, A.C.F. and Machado Neto, J.G.** (2011). Acute toxicity and environmental risk of oxytetracycline and florfenicol antibiotics to Pacu (*Piaractus mesopotamicus*). *Bol. Inst. Pesca*, 37(2): 115-122.
- Chen, Y.-Y.; Chen, J.-C.; Tayag, C.M.; Li, H.-F.; Putra, D.F.; Kuo, Y.-H.; Bai, J.-C. and Chang, Y.-H.** (2016). Spirulina elicits the activation of innate immunity and increases resistance against *Vibrio alginolyticus* in shrimp. *Fish & shellfish immunology*, 55690-698.
- Cuesta, A.; Meseguer, J. and Esteban, M.** (2004). Total serum immunoglobulin M levels are affected by immunomodulators in seabream (*Sparus aurata* L.). *Veterinary Immunology and Immunopathology*, 101(3-4): 203-210.
- Cui, J.; Lv, L.; Wang, Y.; Zhang, X.; He, X.; Wang, X.; Li, H.; Huang, W. and Zhang, Q.** (2016). Curcumin attenuates inflammatory responses and suppresses IgG production in collagen-induced arthritis mice. *Inflammation Research*, 9(1): 1-14.
- El Basuini, M.F.; Zaki, M.A.; El-Hais, A.M.; Elhanafy, M.G.; El-Bilawy, E.H.; Zaineldin, A.I.; Abdel-Aziz, M.F.; Abouelsaad, I.A.; El-Ratel, I.T. and Mzengereza, K.** (2022). Microbial, immune and antioxidant responses of Nile tilapia with dietary nano-curcumin supplements under chronic low temperatures. *Aquaculture and Fisheries*.
- Elia, A.C.; Pacini, N.; Fioravanti, M.L.; Dörr, A.J.M.; Zaccaroni, A.; Parmeggiani, A.M.; Gustinelli, A.; Mordenti, O.; Abete, M.C. and Prearo, M.** (2016). Assessment of detoxifying markers for florfenicol in rainbow trout liver. *Journal of Aquatic Animal Health*, 28(4): 258-265.
- Emam, M.A.; Farouk, S.M.; Aljazzar, A.; Abdelhameed, A.A.; Eldeeb, A.A. and Gad, F.A.** (2023). Curcumin and cinnamon mitigates lead acetate-induced oxidative damage in the spleen of rats. *Frontiers in Pharmacology*, 13(1072760).
- Farombi, E.O.** (2001). Antioxidant status and hepatic lipid peroxidation in chloramphenicol-treated rats. *The Tohoku Journal of Experimental Medicine*, 194(2): 91-98.
- Gaikowski, M.P.; Wolf, J.C.; Schleis, S.M.; Tuomari, D. and Endris, R.G.** (2012). Safety of Florfenicol Administered in Feed to Tilapia (*Oreochromis* sp.). *Toxicologic Pathology*, 41(4): 639-652.
- Hoseinifar, S.H.; Yousefi, S.; Van Doan, H.; Ashouri, G.; Gioacchini, G.; Maradonna, F. and Carnevali, O.** (2020). Oxidative stress and antioxidant defense in fish: the implications of probiotic, prebiotic, and synbiotics. *Reviews in Fisheries Science & Aquaculture*, 29(2): 198-217.

- Hu, D.; Han, Z.; Li, C.; Lv, L.; Cheng, Z. and Liu, S.** (2016). Florfenicol induces more severe hemotoxicity and immunotoxicity than equal doses of chloramphenicol and thiamphenicol in Kunming mice. *Immunopharmacology and Immunotoxicology*, 38(6): 472-485.
- Javed, M.; Ahmad, I.; Ahmad, A.; Usmani, N. and Ahmad, M.** (2016). Studies on the alterations in haematological indices, micronuclei induction and pathological marker enzyme activities in *Channa punctatus* (spotted snakehead) perciformes, channidae exposed to thermal power plant effluent. *SpringerPlus*, 5(1): 016-2478.
- Jin, Y.; Tian, L.X.; Zeng, S.L.; Xie, S.W.; Yang, H.J.; Liang, G.Y. and Liu, Y.J.** (2013). Dietary lipid requirement on non-specific immune responses in juvenile grass carp (*Ctenopharyngodon idella*). *Fish & Shellfish Immunology*, 34(5): 1202-1208.
- Khan, H.; Ullah, H. and Nabavi, S.M.** (2019). Mechanistic insights of hepatoprotective effects of curcumin: Therapeutic updates and future prospects. *Food and Chemical Toxicology*, 124182-191.
- Kladna, A.; Michalska, T.; Berczyński, P.; Kruk, I. and Aboul- Enein, H.Y.** (2012). Evaluation of the antioxidant activity of tetracycline antibiotics in vitro. *Luminescence*, 27(4): 249-255.
- Kono, Y. and Fridovich, I.** (1982). Superoxide radical inhibits catalase. *Journal of Biological Chemistry*, 257(10): 5751-5754.
- Kori-Siakpere, O.; Ikomi, R. and Ogbe, M.** (2010). Histopathological effects of sublethal concentrations of potassium permanganate on the African catfish: *Clarias gariepinus* (Burchell, 1822). *Journal of Aquatic Sciences*, 25(1): 73-84.
- Kuter, D.J. and Tillotson, G.S.** (2001). Hematologic effects of antimicrobials: focus on the oxazolidinone linezolid. *Pharmacotherapy*, 21(8): 1010-1013.
- Lavanya, S.; Ramesh, M.; Kavitha, C. and Malarvizhi, A.** (2011). Hematological, biochemical and ionoregulatory responses of Indian major carp *Catla catla* during chronic sublethal exposure to inorganic arsenic. *Chemosphere*, 82(7): 977-985.
- Lee, H.; Kim, H.; Lee, G.; Chung, H.S. and Bae, H.** (2013). Curcumin attenuates lupus nephritis upon interaction with regulatory T cells in New Zealand Black/White mice. *Br J Nutr*, 110(1): 69-76.
- Lestari, M.L.A.D. and Indrayanto, G.** (2014). Curcumin, in: Brittain, H.G. (Ed.), *Profiles of drug substances, excipients and related methodology*. Academic Press, pp. 113-204.
- Limbu, S.M.; Zhou, L.; Sun, S.-X.; Zhang, M.-L. and Du, Z.-Y.** (2018). Chronic exposure to low environmental concentrations and legal aquaculture doses of antibiotics cause systemic adverse effects in Nile tilapia and provoke differential human health risk. *Environment International*, 115205-219.
- Livingstone, D.R.** (2001). Contaminant-stimulated reactive oxygen species production and oxidative damage in aquatic organisms. *Mar. Pollut. Bull.*, 42(8): 656-666.
- Magnadottir, B.** (2010). Immunological Control of Fish Diseases. *Marine biotechnology*, 12(4): 361-379.
- Mansour, S.; Bakry, K.A.; Alwaleed, E.A.; Ahmed, H.; Al-Amgad, Z.; Mohammed, H.H. and Emeish, W.F.A.** (2023). Dietary Nanocurcumin Impacts Blood Biochemical Parameters and Works Synergistically with Florfenicol in African Catfish Challenged with *Aeromonas veronii*. *Fishes*, 8(6): 298.

- Moghadam, H.; Sourinejad, I. and Johari, S.A.** (2021). Growth performance, haemato- immunological responses and antioxidant status of Pacific white shrimp *Penaeus vannamei* fed with turmeric powder, curcumin and curcumin nanomicelles. *Aquaculture Nutrition*, 27(6): 2294-2306.
- Moniruzzaman, M. and Min, T.** (2020). Curcumin, curcumin nanoparticles and curcumin nanospheres: A review on their pharmacodynamics based on monogastric farm animal, poultry and fish nutrition. *Pharmaceutics*, 12(5): 447.
- Moore, E.** (2007). Florfenicol. *Journal of Exotic Pet Medicine*, 1(16): 52-54.
- Oliveira, R.; McDonough, S.; Ladewig, J.C.L.; Soares, A.M.V.M.; Nogueira, A.J.A. and Domingues, I.** (2013). Effects of oxytetracycline and amoxicillin on development and biomarkers activities of zebrafish (*Danio rerio*). *Environmental Toxicology and Pharmacology*, 36(3): 903-912.
- Papich, M.G.** (2016). Book Reviews : Saunders handbook of veterinary drugs. *Journal of the American Veterinary Medical Association*, 248 (12).
- Ray, P.D.; Huang, B.-W. and Tsuji, Y.** (2012). Reactive oxygen species (ROS) homeostasis and redox regulation in cellular signaling. *Cellular Signalling*, 24(5): 981-990.
- Reda, R.M.; Ibrahim, R.E.; Ahmed, E.-N.G. and El-Bouhy, Z.M.** (2013). Effect of oxytetracycline and florfenicol as growth promoters on the health status of cultured *Oreochromis niloticus*. *The Egyptian Journal of Aquatic Research*, 39(4): 241-248.
- Ren, X.; Pan, L. and Wang, L.** (2014). Effect of florfenicol on selected parameters of immune and antioxidant systems, and damage indexes of juvenile *Litopenaeus vannamei* following oral administration. *Aquaculture*, 432106-113.
- Ruiz-Larrea, M.B.; Leal, A.M.; Liza, M.; Lacort, M. and de Groot, H.** (1994). Antioxidant effects of estradiol and 2-hydroxyestradiol on iron-induced lipid peroxidation of rat liver microsomes. *Steroids*, 59(6): 383-388.
- Saglam, N. and Yonar, M.E.** (2009). Effects of sulfamerazine on selected haematological and immunological parameters in rainbow trout (*Onchorhynchus mykiss*, Walbaum, 1792). *Aquaculture Research*, 40(4): 395-404.
- Shah, J.; Qureshi, T.; Sayed, T.; Shah, Q.; Kalhor, I.; Arain, M.; Saeed, M.; Siyal, F. and Bhutto, Z.** (2016). Evaluation of Therapeutic and High Doses of Florfenicol on Some Hematological Indexes in Goat. *Asian Journal of Animal and Veterinary Advances*, 11637-642.
- Shiroma, L.S.; Soares, M.P.; Cardoso, I.L.; Ishikawa, M.M.; Jonsson, C.M. and Nascimento Queiroz, S.C.** (2020). Evaluation of health and environmental risks for juvenile tilapia (*Oreochromis niloticus*) exposed to florfenicol. *Heliyon*, 6(12): e05716.
- Shuang, G.; Yu, S.; Weixiao, G.; Dacheng, W.; Zhichao, Z.; Jing, L. and Xuming, D.** (2011). Immunosuppressive activity of florfenicol on the immune responses in mice. *Immunological Investigations*, 40(4): 356-366.
- Tapia-Paniagua, S.T.; Vidal, S.; Lobo, C.; de la Banda, I.G.; Esteban, M.; Balebona, M.d.C. and Moriñigo, M.** (2015). Dietary administration of the probiotic SpPdp11: effects on the intestinal microbiota and immune-related gene expression of farmed *Solea senegalensis* treated with oxytetracycline. *Fish & shellfish immunology*, 46(2): 449-458.
- USFWS** (2015). Approved drugs for use in aquaculture (2nd ed.). U.S. Fish and Wildlife Service's Aquatic Animal Drug Approval Partnership Program, American Fisheries Society's Fish Culture and Fish Health Sections, Association of Fish and Wildlife

Agencies, and Fisheries and Water Resources Policy Committee's Drug Approval Working Group.

Wang, X.; Han, C.; Cui, Y.; Li, S.; Jin, G.; Shi, W. and Bao, Y. (2021). Florfenicol causes excessive lipid peroxidation and apoptosis induced renal injury in broilers. *Ecotoxicology and Environmental Safety*, 207(111282): 16.

Yang, C.; Song, G. and Lim, W. (2020). A review of the toxicity in fish exposed to antibiotics. *Comparative Biochemistry and Physiology Part C: Toxicology & Pharmacology*, 237108840.

Zaki, M.M.; Eissa, A.E. and Saeid, S. (2011). Assessment of the immune status in Nile Tilapia (*Oreochromis niloticus*) experimentally challenged with toxogenic/septicemic bacteria during treatment trial with florfenicol and enrofloxacin. *World Journal of Fish and Marine Sciences*, 3(1): 21-36.

Zhang, Q.; Zhang, Y.; Zhang, X.; Rabbi, M.H.; Guo, R.; Shi, S.; Ma, Z. and Liu, Y. (2021). Effects of dietary florfenicol contained feeds on growth and immunity of European seabass (*Dicentrarchus labrax*) in flow-through and recirculating aquaculture system. *Aquaculture Reports*, 19100602.