



Manuscript ID: ZUMJ-2403-3292

DOI: 10.21608/ZUMJ.2024.279989.3292

**ORIGINAL ARTICLE**

## Nano fat Injection versus Platelet Rich Plasma with Glutathione Injection in the Treatment of Post-Acne Scars

Mohamed Salah Awad, \*Adham Mohammed Gouda, and Mohammed Adel Saqr

Plastic Surgery Department, Faculty of Medicine, Zagazig University, Zagazig, Egypt

**\*Corresponding author:**

Adham Mohammed Gouda

**Email:**

[dr.adham.meslam@gmail.com](mailto:dr.adham.meslam@gmail.com)

**Submit Date:** 28-03-2024

**Revise Date:** 08-04-2024

**Accept Date:** 12-04-2024

### ABSTRACT

**Background:** Comedones, papules, nodules, and scars are the hallmarks of acne vulgaris. In patients who are prone to scarring, scarring is a common consequence. There appears to be an improvement in skin texture and structural volumization with injections of Nanofat mixed with microfat. Platelet-rich plasma use in regenerating damaged tissues has attained a lot of interest. Glutathione has remarkable antioxidant properties and a lightening effect. It has also been found to decrease wrinkles and increase skin elasticity. Glutathione is used as monotherapy or in combination with PRP. This study aimed to investigate nanofat in treating post-acne scars compared to platelet-rich plasma added to glutathione injections.

**Methods:** This comparative clinical study included 24 patients complaining of post-acne scars, selected from the Plastic & Reconstructive Surgery Department, Zagazig University Hospitals. Nano-fat injection treatment was applied on the right side of the face, and PRP with glutathione injection was used on the left side of the face.

**Results:** Statistically significant differences were found between pre-and post-Goodman-Baron acne scar grading among the Nano-fat injection group and the PRP+ glutathione group ( $p=0.006, 0.009$ , respectively). Post-inflammatory hyperpigmentation was significantly higher among the nanofat group (45.8%) than among the PRP+ glutathione group (12.5%) ( $p=0.01$ ).

**Conclusions:** Injection of Nanofat could be an effective scar treatment leading to statistically significant improvements in scar appearance, PRP injection in combination with glutathione is also an effective treatment in improvement of post acne scars appearance. These therapeutic procedures provide a valuable tool for every plastic surgeon.

**Keywords:** Acne scar; Post acne scar; Nanofat; Platelet-rich plasma; glutathione.

### INTRODUCTION

Eighty percent of people between the ages of eleven and thirty-five and five percent of those aged thirty and up suffer acne. Many things come together to form acne, such as an overactive propionibacterium acnes, an increase in sebum production, activation of the androgen receptor, hyper cornification of the hair follicles, and an inflammatory reaction involving lymphocytes, macrophages, and neutrophils [1].

Comedones, papules, nodules, and scars are the hallmarks of acne vulgaris. Scarring is a common consequence in patients who are prone to scarring. Scars resulting from acne can be classified into several types: keloid, rolling, superficial macular, ice pick, boxcar, and hypertrophic [2]. While there are several options for treating acne scars, such as laser treatments, dermabrasion, chemical peels, fillers, and fat grafting, each has advantages and disadvantages [3].

Adipose tissue contains a wealth of crucial components for revascularization, including microvascular fragments, growth factors, cytokines, and Adipose-Derived Mesenchymal Stem Cells (AD-MSCs) [4]. According to Tonnard et al. [5], Nanofat is made by first mechanically emulsifying fat harvested by liposuction using small-bore luer-lock connectors and cellularly filtering the mixture through a 500 mm filter. This rapid method enables the separation of the Stromal Vascular Fraction (SVF) and some components of nonviable adipocyte cells. Compared to the conventional method of transplanting AD-MSCs for skin rejuvenation and epithelial tissue regeneration, the Nanofat graft was more straightforward and less expensive. It appears that injecting a mixture of Nanofat and microfat can improve skin texture and provide structural volumization [6].

There was a pathological correlation between the outcomes and an evaluation of the function of autologous Nanofat injection in improving the cosmetic look of post-traumatic scars. Ultimately, when it came to treating post-traumatic scars, autologous Nanofat injection yielded notable improvements from both a clinical and pathological aspect [7].

Photographs and a validated and standardized rating called the patient observer scar assessment scale (POSAS) were used to assess the efficacy of Nanofat grafting on scars caused by burns and other traumas to the face. Finally, scar renewal can be aided by injecting autologous emulsified Nanofat, which improves scar features and symptoms [8].

Platelet-rich plasma (PRP) is a product made from autologous blood that is concentrated in plasma volume and contains an abundance of platelets, growth factors, and chemo/cytokines. Platelet-rich plasma use for tissue regeneration and repair has been a hot topic since 1970 [9].

Glutathione has remarkable antioxidant properties and a lightening effect. It has also been found to decrease wrinkles and increase skin elasticity. Glutathione is used as monotherapy or in combination with PRP, vitamin E, ascorbic acid, etc [10].

This work aimed to investigate nanofat in treating post-acne scars and compare it with platelet-rich plasma with glutathione injection, one of the options for post-acne scar treatment.

## Methods

This comparative clinical study was carried out at the Plastic & Reconstructive Surgery Department, Faculty of Medicine, Zagazig University, on twenty-four participants aged eighteen to thirty years old after they provided written consent and exhibited post-acne scars from April 2023 to September 2023. The study was approved by The Institutional Review Board (IRB) at Zagazig University (IRB #10700/16-4-2023). The Declaration of Helsinki, the International Medical Association's guideline of ethics for studies involving humans, was followed in the conduct of this study.

The inclusion criteria were patients aged 18 - 30 years with post-acne scars with no active lesions.

The exclusion criteria are patients with any of the following conditions: a positive history of keloidal tendency, bleeding, or platelet disorder; patients who had any acute infection on their face, such as herpes and folliculitis; HIV, Hepatitis B virus, or any chronic illness; Skin Type V and Type VI on the Fitzpatrick scale; pregnant females; and those taking systemic isotretinoin drugs that induce hyperpigmentation in the last six months.

Patients underwent a thorough history-taking and a detailed general and local examination. Skin type, scar type (icepick, boxcar, and rolling), and scar severity were all evaluated during clinical evaluation of the type (grade 2, 3, or 4 according to the qualitative global acne scarring grading system).

The right side of the face was treated with nano-fat injection (Group (F) (I), and the left side was treated with PRP with glutathione injection (Group (G) (II).

### Nanofat Preparation and Injection

Anesthesia for local tumescent infiltration areas: The tumescent solution was prepared by combining 2 millilitres of 1% plain lidocaine, 0.1 millilitres of 1:1000 epinephrine, and 0.9 percent normal saline in a 100-milliliter bag. A tumescent infusion cannula attached to a 60-mL syringe was used to infiltrate the tissue, and the fluid was injected and dispersed evenly between the two sides.

**Release of the scar:** Before Nanofat injection, intraoperative fibrosis or manual surgical release was used to reduce scar tension and contracture, increase scar pliability, and make long linear scars less noticeable (Figure 1).

**Harvesting and preparation of the Nanofat:** The lateral thigh and abdomen were the primary locations for donor sites. A conventional fat harvesting solution was used for infiltration (900 ml NaCl 0.9 percent, Adrenalin; 1: 1,000,000). The microfat was extracted using a 2 mm × 20 cm cannula with sharp side holes 1 mm in diameter. It was connected to a 20 ml syringe under negative pressure, and the amount of microfat extracted varied from 10 to 20 ml based on the scar size. The microfat was mechanically emulsified by repeatedly moving the contents between two 10-milliliter syringes linked by a 1.4-millimeter female-to-female Luer-Lok connector until the fat melted and turned white. The fatty liquid underwent a second round of filtration using a Nanofilter following this emulsification procedure. "Nanofat" was the name given to this liquid.

**Injection of the Nanofat:** The face was sterilized using Povidone-iodine. The collected fluid was injected into the dermis and scar tissue using 27-G and 25-G sharp needles. The scar tissue's quality and hardness dictated the needle diameter. The injection succeeded when a yellowish discoloration of the skin was visible.

**Injection of Platelet-rich plasma:** Under aseptic conditions, ten to twenty millilitres of the patient's fresh blood were drawn into sodium citrate vacutainers. The centrifuge machine spins the tubes at 1500 rpm for 6 minutes. First, there's the "soft spin" centrifugation, which sorts the blood into three distinct layers: the RBC layer at the bottom (55 percent volume), the PPP layer at the top (40 percent volume), and the "buffy coat," an intermediate PRP layer that's just 5 percent volume. The buffy coat containing PPP was transferred to an additional test tube using the Finn pipette. The tube undergoes another round of centrifugation at 2500 RPM for 15 minutes, known as "hard spin." Platelets (PRP) can sink to the tube bottom in this way. The platelet-poor plasma (PPP) at upper layer was poured out, and the PRP-containing lower layer was transferred to a separate, clean tube. To prepare the platelet concentrate for injection into scar areas, 1 mL insulin syringes were filled with a calcium chloride activator that was nine parts PRP to 1 part calcium chloride (Figure 2). During the same process, a glutathione-loaded one-milliliter insulin syringe was injected (Figure 3).

**Clinical assessment:** Digital color portraits of the subjects' faces were captured using a Sony Cyber-shot digital camera (DSC-W380, Tokyo, Japan). Goodman-Baron qualitative acne scar scoring was assessed by measuring the pain level and patient satisfaction [8].

**Follow-up:** All patients were evaluated for six months after treatment.

### STATISTICAL ANALYSIS

SPSS version 29.0 was used for data processing to check, enter, and analyze the data. The student "t" test compares the means of two separate groups. In contrast, quantitative data is presented as means ± SD, and qualitative data is expressed as numbers and percentages. The quantitative variables in the two non-normally distributed data sets were compared using the Mann-Whitney test. In contrast, the qualitative variables were compared using the Chi-square test for association and difference (X<sup>2</sup>). The 5% significance level (P-value) was used as the cutoff for significant results, with a significance level of less than 0.05.

### RESULTS

The age of patients ranged from 18 to 30 years, with a mean of 25.5 years ± 4.6 SD. Most studied patients were female (62.5%), and (37.5%) were males. The mean duration of post-acne scars was 3.1 years ± 1.4 SD, ranging from 1 to 6 years (Table 1).

Before the intervention, we used the Goodman and Baron Scale to Grade acne. Twelve patients (50%) had a moderate type, eight patients (33.3%) had severe, and four patients (16.7%) had a mild type. Table (2) showed a statistically significant difference between Pre and Post Goodman-Baron acne scar grading among the glutathione group ( $P < 0.05$ ). As there were eight patients (33.3%) who had severe acne scars before and after treatment, only four patients still had severe acne scars, and the other four patients were classified as mild acne scars. Also, there were 12 patients (50%) with moderate acne scars before treatment; only five patients still had moderate acne scars after treatment. Six of the other seven patients had a mild scar, and one had a macular scar. Before treatment, there were four patients with mild acne scars; after treatment, three of them had macular scars.

Table (3) showed a statistically significant difference between Pre and Post Goodman-Baron

acne scar grading among the Nano-fat injection group ( $P < 0.05$ ). Of eight patients (33.3%) with severe acne scars before treatment, only two still had severe scars, and the other six patients were classified as mild acne scars. Also, there were 12 patients (50%) with moderate acne scars before treatment, while after treatment, only seven patients still had moderate acne scars; the other five patients two had mild scars, and the other three had macular scars. Before treatment, mild acne scar

was found among four patients; after treatment, two of them had macular scars.

Table (4) showed non-significant differences between the two groups in clinical improvement and patients' satisfaction ( $P > 0.05$ ).

Post-inflammatory hyperpigmentation was significantly higher among Group I (45.8%) in comparison to (12.5%) among Group II ( $P = 0.01$ ) (Table 5).

**Table 1:** Demographic data among studied participants

		Patients (n=24) (N. %)
Age	mean±SD (range)	25.5±4.6 (18 – 30)
Sex (N. %)	Female Male	15 (62.5%) 9 (37.5%)
Duration (years)	mean±SD (range)	3.1±1.4 (1-6)
Comorbidities	Absent Present	4 (16.7%) 20 (83.3%)
Family history	Absent Present	(36%) (64%)

**Table 2:** Goodman-Baron qualitative acne scar scoring among PRP + glutathione group

Variable	Pre-treatment (n=24)	Post-treatment (n=24)	P-value
Macular	0 (0%)	4 (16.7%)	<b>0.009</b>
Mild	4 (16.7%)	<b>11 (45.8%)</b>	
Moderate	<b>12 (50%)</b>	5 (20.8%)	
Severe	8 (33.3%)	4 (16.7%)	

Chi-Square test, Sig.:  $P < 0.05$ , Non-Sig.:  $P > 0.05$

**Table 3:** Goodman-Baron qualitative acne scar scoring among Nano-fat injection group

Variable	Pre-treatment (n=24)	Post-treatment (n=24)	P-value
Macular	0 (0%)	5 (20.8%)	<b>0.006</b>
Mild	4 (16.7%)	<b>10 (41.7%)</b>	
Moderate	<b>12 (50%)</b>	7 (29.2%)	
Severe	8 (33.3%)	2 (8.3%)	

Chi-Square test, Sig.:  $P < 0.05$ , Non-Sig.:  $P > 0.05$

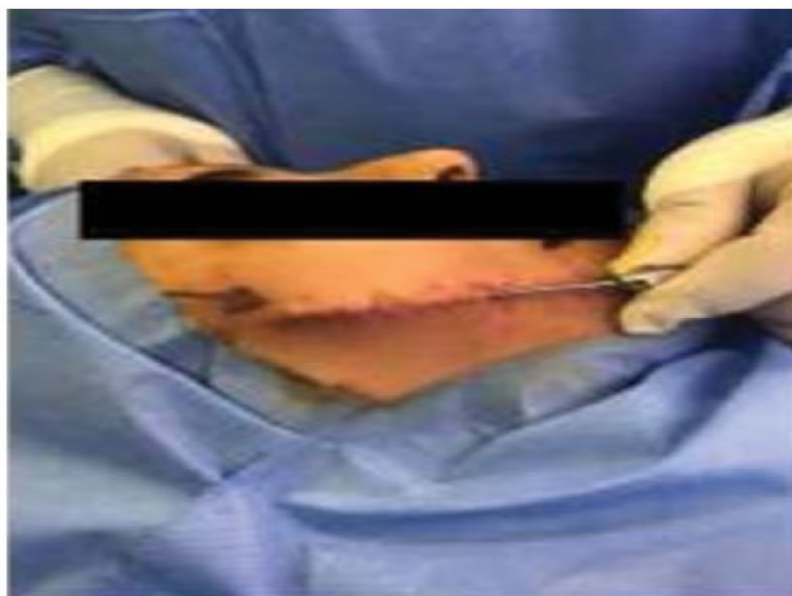
**Table 4:** Treatment efficacy among studied patients

Variable	Group 1 (F) (n=24)	Group 2 (G) (n=24)	P-value
<b>Clinical improvement</b>			
Minimal	1 (4.2%)	1 (4.2%)	0.8
Moderate	5 (20.8%)	8 (33.3%)	
Marked	11 (45.8%)	9 (37.5%)	
Excellent	7 (29.2%)	6 (25%)	
<b>Patients' satisfaction</b>			
Dissatisfied	2 (8.3%)	3 (12.5%)	0.5
Neutral	9 (37.5%)	6 (25%)	
Satisfied	8 (33.3%)	11 (45.8%)	
Highly satisfied	5 (20.8%)	4 (16.7%)	

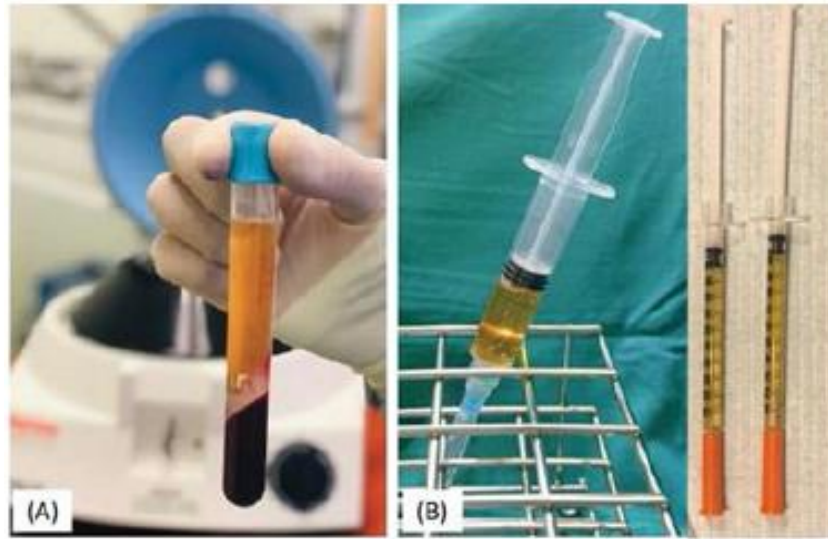
Chi-Square test, Sig.:  $P < 0.05$ , Non-Sig.:  $P > 0.05$

**Table 5:** Post-procedural adverse events among studied groups

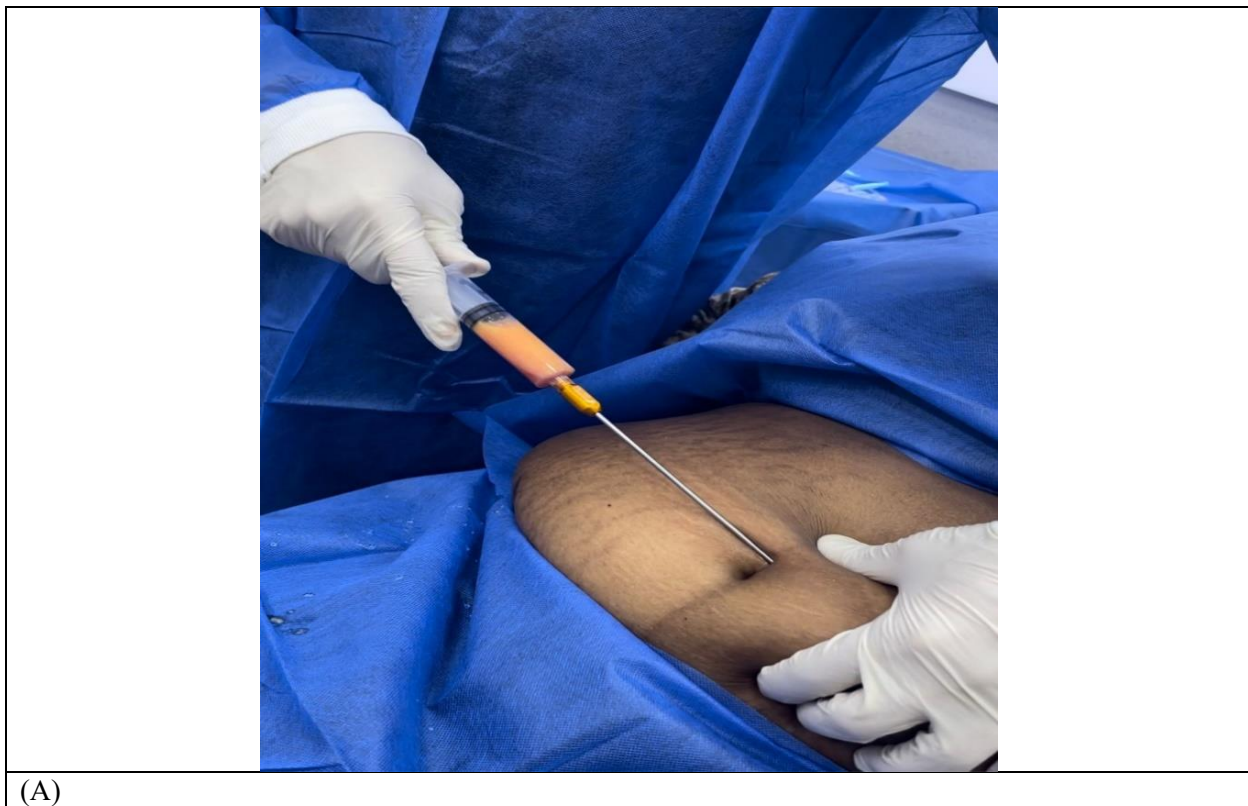
Variable	Group 1 (F) (n=24)	Group 2 (G) (n=24)	P-value
Mild pain	20 (83.3%)	17 (70.8%)	0.3
Transient edema	17 (70.8%)	12 (50%)	0.1
Bruising	21 (87.5%)	18 (75%)	0.3
Hyperpigmentation	11 (45.8%)	3 (12.5%)	<b>0.01</b>
Acneform eruption	8 (33.3%)	7 (29.2%)	0.8



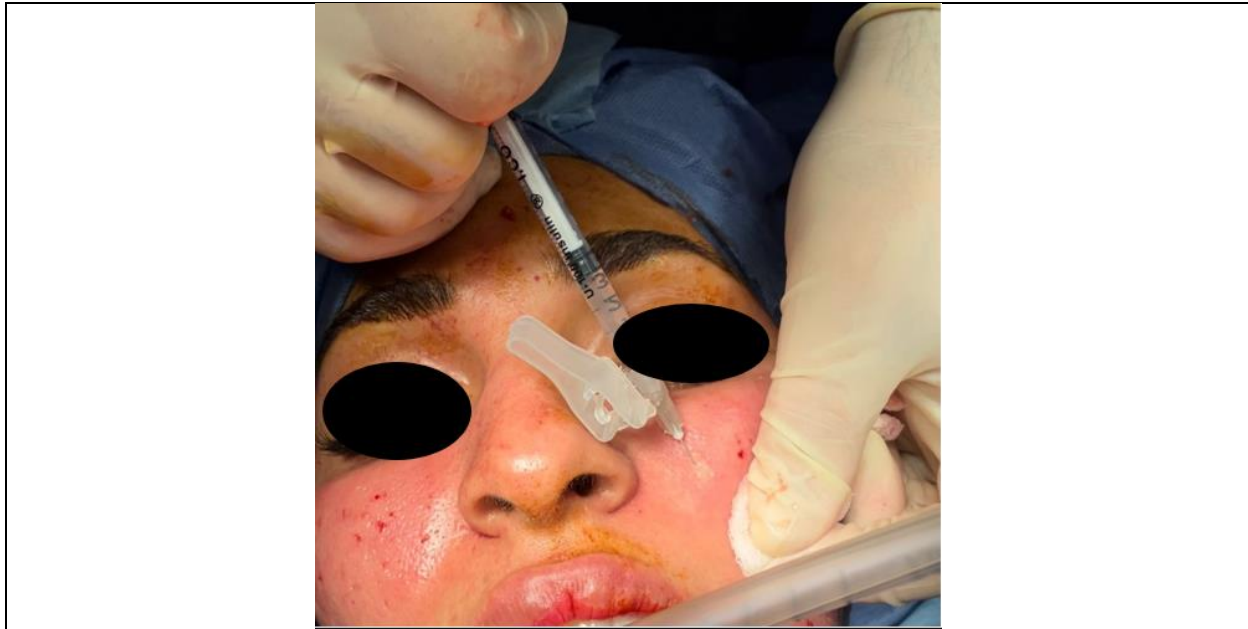**Figure (1):** Simple manual surgical release or feeling of fibrosis done intraoperatively at scar site



**Figure (2)**  
(A) Platelet-rich plasma after first centrifugation.  
(B) Platelet-rich plasma ready for injection.



(A)



(B)

**Figure 3:** (A): Harvesting of the fat from the abdomen as a donor site using a 2mm × 20 can cannula with sharp side holes 1 ml diameter, (B): Glutathione injection intradermally after loading in 1 ml insulin syringe.

### DISCUSSION

Cosmetic surgeons and doctors treat acne vulgaris more often than other skin conditions. Inflammatory breakouts and the scarring that follows can have a terrible effect on a person's mental health. In addition to decreasing social connections, those who have scars are more likely to acquire sadness, anxiety, humiliation, and aggressive tendencies. Trauma, burns, surgeries, and infections are among the several potential causes of scarring [11].

When it comes to acne scars, there is currently no gold standard treatment. A tiny amount of autologous platelet-rich plasma contains a platelet concentration that is four to seven times higher than baseline. Platelet-rich plasma starts a mild inflammatory response, which spurs the body's natural healing mechanisms and the production of growth factors, which in turn cause the development of new blood vessels, allowing for tissue regeneration [12].

PRP can be used as an adjuvant with various treatments for acne scars, including microneedling, lasers, vitamin C, and fat grafting [13]. When it came to scar treatment, Chawla. [14] discovered that PRP worked well as an adjunct therapy. The possibility of adipose tissue transplantation for regeneration was the subject of an international

research. Adipose-Derived Mesenchymal Stem Cells, microvascular fragments, growth factors, and cytokines are rich in adipose tissue and play a key role in revascularization, angiogenesis augmentation, and fibrosis reduction [15].

In 2013, Tonnard et al. [16] first introduced the prospect of nanofat, which involves extracting particulate fat, mechanically emulsifying it, and then filtering it to produce stromal vascular fraction (SVF) gel that is high in ADSCs. By repeating or improving Tonnard's nanofat preparation method, researchers have successively reported the preparation techniques of nanofat has the potential to aid in wound healing and tissue regeneration by releasing growth factors since it is a rich source of ADSCs.

The present study's ages ranged from 18 to 30 years, with a mean of 25.5 years ± 4.6 SD. Most studied patients were female (62.5%), and (37.5%) were males.

Also, Abd Elfatah et al. [8] assessed Nanofat grafting's efficacy in treating burn and trauma scars on the face and found that the patient's ages ranged between 16 and 38 years, with a mean age of 26.70. There were 12 females (60%) and eight males (40%).

However, Babu et al. [17] evaluated reviewed safety as well as efficacy of platelet rich plasma

compared to the CO2 laser in management of post acne scar. There were 7 females and 13 males in their study. The mean age of the subjects was  $27.05 \pm 5.28$  years.

In the present study, the mean duration of post-acne scars was 3.1 years  $\pm 1.4$  SD, ranging from 1 to 6 years. Regarding associated comorbidities among studied cases, 4 cases were known diabetics, and (52%) of patients had a positive family history. Also, Abd Elfatah et al. [8] found that the scar duration ranged from 1 to 30 years.

In the present study, skin type was assessed by the Fitzpatrick scale; most patients were grade II and III (74.9%). About half of the patients had Ice pick scars, 37.5% had boxcar scars, and 20.8% had rolling scars. This agreed with Tirmizi et al. [18], who found that most patients were grade II and III (64%). Also, Chuah and Goh. [19] revealed that ice pick scars accounted for 97% of patients, rolling scars accounted for 82%, boxcar scars accounted for 61%, and keloidal scars accounted for 15%. In addition, According to Adityan and Thappa [20], 65.57 % of the individuals they evaluated had ice-pick scars due to acne.

The present study graded the acne scars using the Goodman and Baron Scale before treatments. Four patients (16.7%) had a mild type, 12 patients (50%) had a moderate type, and eight patients (33.3%) had severe. In agreement with our study, in the Agrawal and Khunger [21] study, according to the Goodman and Baron qualitative grading system, 22% of patients had macular grade, 12% had mild, 29% had moderate, and 37% had severe. Consistent with our findings, Chuah and Goh [19] also noted that most of their patients had moderate-grade acne scarring (54%).

A statistically significant difference was revealed in the current study between Pre and Post Goodman-Baron acne scar grading among the PRP+ glutathione group ( $P < 0.05$ ).

This agreed with Gulanikar and Vidholkar. [22] the scar grade before and after PRP treatment was compared. It was found that 25 out of 30 patients (83.3%) had Grade 3 scars, while five (16.7%) had Grade 2 scars originally. Ten patients (33.3%) had Grade 3 scars after treatment, while twenty (66.7%) had Grade 2 scars ( $P < 0.0001$ ), a statistically significant finding.

In the same context, Sclafani [23] discovered that most patients who underwent autologous platelet-rich plasma (PRP) injections for skin rejuvenation

saw positive outcomes in treating acne scars. Skin tonicity, homogeneity, and texture were all improved in most cases [23,24]. GFs have a stimulatory action that allows collagen, fibroblasts, and keratinocytes to proliferate and rejuvenate the skin [25,26]. Interestingly, Ibrahim and Elgarhy [27] reported that After completing the medication period, three patients whose acne was actively worsening exhibited significant improvement. Previous research has shown that PRP has antimicrobial action against many bacteria, including methicillin-resistant *S. aureus*, *Candida albicans*, *Cryptococcus neoformans*, and *Escherichia coli*. This could explain the observed effect [28]. In addition, Intravia et al. [29] revealed that compared to the whole-blood control group, *S. aureus*, *Staphylococcus epidermidis*, methicillin-resistant *Staphylococcus aureus* (MRSA), and *Propionibacterium acnes* exhibited a substantial decrease in bacterial growth after 8 hours following PRP administration. Furthermore, platelet-rich plasma (PRP) can inhibit *Propionibacterium acnes*, speed up the process of re-epithelialization and collagen remodeling, and promote healing by reducing inflammation [13].

Thirty patients with atrophic facial scars from acne were divided into two groups and given microneedling with platelet-rich plasma on one side and vitamin C on the other. Each group had four sessions spaced one month apart. Of the 30 patients with scarring evaluations, 23 showed a reduction of one or two grades. Overall, microneedling with PRP produced superior outcomes than microneedling with vitamin C [14]. There was a significant difference on the right side between the qualitative assessment before and after the PRP injection, according to Mikhael et al. [30] ( $P$ -value  $< 0.001$ ). After injection, 25% were macular, 45% were mild, 15% were moderate, and 15% were severe, compared to 50.0% who had mild, 25% who had moderate, and 25% who had severe before injection.

The Present study showed a statistically significant difference between Pre and Post Goodman-Baron acne scar grading among the Nano-fat injection group ( $P < 0.05$ ). As there were eight patients (33.3%) who had severe acne scars before treatment, only two patients still had severe acne scars, and the other six patients were classified as mild acne scars. Also, 12 patients (50%) had moderate acne scars before treatment; after



treatment, only seven patients still had moderate acne scars. Two of the other five patients had mild scars, and the other three had macular scars. Before treatment, there were four patients with mild acne scars; after treatment, two of them had macular scars.

Before lipofilling may be used to treat acne scars, subcision must be performed to dissolve all adhesions. This will prevent any abnormalities or out-pouching of fat. According to Gu et al. [31], twenty patients who had acne scars and were injected with Nanofat subcutaneously showed a marked improvement.

A study by Azzam et al. [32] examined 22 patients suffering from acne scars. They compared a single session of autologous fat transfer to three sessions of fractional CO<sub>2</sub> laser. They found that fat transfer worked better for treating acne scars. Unfortunately, patients did not receive ongoing follow-up care.

The various cell types that comprise fat—adipocytes, fibroblasts, smooth muscle cells, endothelial cells, and preadipocytes—make it a dynamic and active tissue [33]. According to Mandili et al. [34], patients seeking effective skin rejuvenation and enhancement can use Nanofat and fat grafting, which provides long-lasting results without allergy testing. These benefits include decreasing the appearance of fine lines, wrinkles, and depressions in the skin and eliminating these issues. All eight patients in the trial reported a considerable improvement in the look of their scars, a decrease in scar size, and no side effects other than moderate pain (3/8; 37.5%).

The present study showed a statistically significant difference between Pre- and post-Goodman-Baron acne scar grading among the Nano-fat injection group and the PRP + glutathione group. However, there was no significant difference between the two modalities as regards acne scar score. Also, Pons et al. [35] found that PRP and Nanofat have the potential to be a game-changing method for treating severe acne inflammatory scarring.

Both intradermal PRP and autologous fat grafting were safe and effective in treating acne scars, according to Shetty et al. [36]. The results were significant ( $p < 0.001$ ) in both groups. However,  $p = 0.23$  indicates that neither treatment group was significantly different from the other.

Thirty patients with severely depressed acne scars on the cheeks were included in a recent

comparative study that assessed the effectiveness of Nanofat and Platelet-Rich Plasma infiltration independently and combined with fractional CO<sub>2</sub> laser resurfacing in improving the appearance of atrophic scars on the face. In conclusion, When used alone or in conjunction with fractional CO<sub>2</sub> laser resurfacing, subcutaneous infusion of Nanofat and PRP appears to be an effective method for improving atrophic scars [37].

The present study showed no significant difference between the two groups in clinical improvement ( $P < 0.05$ ). The majority of patients in Group 1 had shown marked and excellent clinical improvement (75%), while in Group 2, the percentage was (62.5%).

In a study by Lee et al. [38], fourteen patients who suffered from acne scars were subjected to a CO<sub>2</sub> laser treatment across the entire face twice. Following each session, a random selection was made to administer intradermal PRP to one side of the face and intradermal saline to the other. According to a quartile grading scale, the location treated with PRP showed higher clinical improvement.

The present study shows no significant difference between the two groups in patient satisfaction ( $P < 0.05$ ). Most patients in group 1 were highly satisfied and satisfied (54.1%), while they were (62.5%) in group 2.

This agreed Gulanikar and Vidholkar. [22] who asked the patients to rate their level of satisfaction on a scale from zero to four; sixteen patients (53.3%) provided a very good score of three, and fourteen patients (46.7%) gave a good score of two.

## CONCLUSIONS

Injection of Nanofat could be an effective scar treatment leading to statistically significant improvements in scar appearance, PRP injection in combination with glutathione is also an effective treatment in improvement of post acne scars appearance. These therapeutic procedures provide a valuable tool for every plastic surgeon.

**Conflict of Interest:** None.

## REFERENCES

- 1- Asilian A, Salimi E, Faghihi G, Dehghani F, Tajmirriahi N, Hosseini SM. comparison of Q-switched 1064-nm Nd: YAG laser and fractional CO<sub>2</sub> laser on improvement of atrophicfacial acne scar. J Res Med Sci 2011; 16: 1189-95

- 2- Faghihi G, Poostiyan N, Asilian A, Abtahi-Naeini B, Shahbazi M, Iraj F, et al. Efficacy of fractionated microneedle radiofrequency with and without adding subcision for the treatment of atrophic facial acne scars: A randomized split faces clinical study. *J Cosmet Dermatol* 2017; 10: 1-7.
- 3- Oh IY, Beom JK and Myeung NK. Depressed facial scars successfully treated with autologous platelet-rich plasma and lightening diode phototherapy at 830 nm. *Ann Dermatol* 2014; 26(3): 417-8.
- 4- Kucharzewski M, Rojczyk E and Wilemska-Kucharzewska K. Novel trends in application of stem cells in skin wound healing. *Eur. J. Pharmacol* 2019; 843: 307-15.
- 5- Tonnard P, Verpaele A, Peeters G. Nanofat grafting: basic research and clinical applications. *Plast Reconstr Surg* 2013; 132: 1017-26.
- 6- Wagh Milind S and Dixit V. Tissue expansion: Concepts, techniques and unfavourable results. *Indian journal of plastic surgery: IJPS* , 2013; 46: 333-48.
- 7- Rageh MA, El-Khalawany M and Ibrahim SM. Role of Nanofat injection in treating post-traumatic scars. *AIMJ*, 2021; 29-34.
- 8- Abd Elfatah MR, Hafez AA and Dahy AA. Evaluation of Nanofat injection in postburn and posttraumatic facial scars. *The Scientific AIMJ*, 2022; 6: 91-8.
- 9- Alser OH and Goutos L. The evidence behind the use of platelet-rich plasma (PRP) in scar management, a literature review. *Scars, Burns and Healing*, 2018; 3: 1-15.
- 10- Sonthalia S, Jha AK, Lallas A, Jain G, Jakhar D. Glutathione for skin lightening: a regnant myth or evidence-based verity? *Dermatol Pract Concept*. 2018;8(1):15-21.
- 11- Vincent AG, Kadakia S, Barker J, Mourad M, Saman M, Ducic Y. Management of Facial Scars. *Facial Plast Surg* 2019; 35: 666-71.
- 12- Langer C, Mahajan V. Platelet-rich plasma in dermatology. *JK Sci* 2014; 16(4): 147-50.
- 13- Zhu JT, Xuan M, Zhang YN, Liu HW, Cai JH, Wu YH, et al. The efficacy of autologous platelet rich plasma combined with erbium fractional laser therapy for facial acne scars or acne. *Mol Med Rep* 2013; 8: 233-7.
- 14- Chawla S. Split face comparative study of microneedling with PRP versus microneedling with Vitamin C in treating atrophic post acne scars. *J Cutan Aesthet Surg* 2014; 7: 209-12.
- 15- Kucharzewski M, Rojczyk E, Wilemska-Kucharzewska K, Wilk R, Hudecki J, Los MJ. Novel trends in application of stem cells in skin wound healing. *Eur J Pharmacol*. 2019; 843: 307-15.
- 16- Tonnard P, Verpaele A, Peeters G, Hamdi M, Cornelissen M, Declercq H. Nanofat grafting: basic research and clinical applications. *Plast Reconstr Surg*. 2013;132(4):1017-26.
- 17- Babu AM, Shetty VH, Goel S, Eram H. A comparative study of efficacy and safety of platelet rich plasma versus fractional co2 laser in the treatment of post acne scars. *Int J Res Dermatol* 2019; 5: 254-8.
- 18- Tirmizi SS, Iqbal T, Mansoor M, Farooq N, Ather S, Fatima F, et al. Role of Microneedling in Atrophic Post-Acne Scars: An Experience from a Tertiary Care Hospital. *Cureus*. 2021;13(1):e12578.
- 19- Chuah SY, Goh CL. The Impact of Post-Acne Scars on the Quality of Life Among Young Adults in Singapore. *J Cutan Aesthet Surg*. 2015;8(3):153-8.
- 20- Adityan B, Thappa DM. Profile of acne vulgaris--a hospital-based study from South India. *Indian J Dermatol Venereol Leprol*. 2009;75(3):272-8.
- 21- Agrawal DA, Khunger N. A Morphological Study of Acne Scarring and Its Relationship between Severity and Treatment of Active Acne. *J Cutan Aesthet Surg*. 2020;13(3):210-6.
- 22- Gulanikar AD, Vidholkar R. Efficacy of platelet-rich plasma in acne scars. *Clin Dermatol Rev* 2019; 3: 109-14.
- 23- Sclafani AP. Safety, efficacy, and utility of platelet-rich fibrin matrix in facial plastic surgery. *Arch Facial Plast Surg*. 2011;13(4):247-51.
- 24- Redaelli A, Romano D, Marcianó A. Face and neck revitalization with platelet-rich plasma (PRP): clinical outcome in a series of 23 consecutively treated patients. *J Drugs Dermatol*. 2010;9(5):466-72.
- 25- Ehrlich M, Rao J, Pabby A, Goldman M. Improvement in the Appearance of Wrinkles with Topical Transforming Growth Factor  $\beta$ 1 and L-Ascorbic Acid. *Dermatologic surgery: official publication for ASDS* 2006; 32: 618-25.
- 26- Gold M, Goldman M, Rao J, Carcamo A, Ehrlich M. Treatment of Wrinkles and Elastosis Using Vacuum-Assisted Bipolar Radiofrequency Heating of the Dermis. *Dermatologic surgery : official publication for ASDS* 2007; 33: 300-9.

- 27- Ibrahim MK, Ibrahim SM, Salem AM. Skin microneedling plus platelet-rich plasma versus skin microneedling alone in the treatment of atrophic post acne scars: a split face comparative study. *J Dermatolog Treat* 2018; 29: 281-6.
- 28- Burnouf T, Chou ML, Wu YW, Su CY, Lee LW. Antimicrobial activity of platelet (PLT)-poor plasma, PLT-rich plasma, PLT gel, and solvent/detergent-treated PLT lysate biomaterials against wound bacteria. *Transfusion*. 2013;53(1):138-46.
- 29- Intravia J, Allen DA, Durant TJ, McCarthy MB, Russell R, Beitzel K, et al. In vitro evaluation of the anti-bacterial effect of two preparations of platelet rich plasma compared with cefazolin and whole blood. *Muscles Ligaments Tendons J*. 2014;4(1):79-84.
- 30- Mikhael N W, Rezk S M, Abdel Khalik H A, Mowafy M. A. Serum total thiol level in Acne Vulgaris Patients and its relation to oxidative stress. *BJAS* 2021; 6(5): 191-7.
- 31- Gu Z, Li Y, Li H. Use of Condensed Nanofat Combined With Fat Grafts to Treat Atrophic Scars. *JAMA Facial Plast Surg*, 2018; 20(2): 128-35.
- 32- Azzam OA, Atta AT, Sobhi RM, Mostafa PI. Fractional CO(2) laser treatment vs autologous fat transfer in the treatment of acne scars: a comparative study. *J Drugs Dermatol*. 2013;12(1):7-13.
- 33- Raposio E, Guida C, Baldelli I, Benvenuto F, Curto M, Paleari L, et al. Characterization and induction of human pre-adipocytes. *In Vitro Toxicol* 2007; 21(2): 330-4.
- 34- Mandili A, Alsadi H.H.S, Khamis S, Alharbi Z. Nanofat, Microfat, Platelet Rich Plasma (PRP), Microneedling and Fractional CO2 Laser: A Regenerative Multimodality Approach and Protocol in Scar Management. *Archives of Clin. Med. Case Rep* 6 2022; 511-6.
- 35- Pons S, Jammot P, Galmiche S, Damecourt A, Las D, Blatière V, et al. Nanofat and Platelet-Rich Plasma injections used in a case of severe acne scars. *J Stomatol Oral Maxillofac Surg*. 2022;123(5):572-5.
- 36- Shetty VH, Bhandary SN, Bhandary R, Suvarna C. A comparative study of efficacy and safety of autologous fat grafting versus Platelet-rich plasma in the treatment of post-acne scars. *J Cosmet Dermatol*. 2021;20(11):3454-61.
- 37- Tenna S, Cogliandro A, Barone M, Panasiti V, Tirindelli M, Nobile C, et al. Comparative Study Using Autologous Fat Grafts Plus Platelet-Rich Plasma with or Without Fractional CO2 Laser Resurfacing in Treatment of Acne Scars: Analysis of Outcomes and Satisfaction With FACE-Q. *Aesthetic Plast Surg* 2017; 41: 661-6.
- 38- Lee JW, Kim BJ, Kim MN, Mun SK. The efficacy of autologous platelet rich plasma combined with ablative carbon dioxide fractional resurfacing for acne scars: a simultaneous split-face trial. *Dermatol Surg*. 2011;37(7):931-8.

#### Figure Legend

**Figure (1):** Simple manual surgical release or feeling of fibrosis done intraoperatively at scar site

**Figure 2:** (A) Platelet-rich plasma after first centrifugation. (B) Platelet-rich plasma ready for injection.

**Figure 3:** (A): Harvesting of the fat from the abdomen as a donor site using a 2mm × 20 can cannula with sharp side holes 1 ml diameter, (B): Glutathione injection intradermally after loading in 1 ml insulin syringe.

#### Citation

Awad, M., Gouda, A., Saqr, M. Nanofat Injection versus Platelet Rich Plasma with Glutathione Injection in the Treatment of Post-Acne Scars. *Zagazig University Medical Journal*, 2024; (5113-5123): -. doi: 10.21608/zumj.2024.279989.3292