



Manuscript ID: ZUMJ-2403-3217

DOI: 10.21608/zumj.2024.273788.3217.

ORIGINAL ARTICLE

Endoscopic Third Ventriculostomy versus Cerebrospinal Fluid Shunting in Hydrocephalus associated with Posterior Fossa Lesions in Adults; Comparative study

Hassan Abaza¹, Mohammad Abdulsalam², Ola A. Harb³, Mohamed Khaled El-Badawy¹

1. Department of Neurosurgery Faculty of Medicine, Zagazig University, Zagazig, Egypt.
2. Lecturer of Neurosurgery, Alahrar Teaching Hospital in Zagazig, GOTHI, Egypt
3. Department of Pathology, Faculty of Medicine Zagazig University, Zagazig, Egypt.

***Corresponding Author:**

Ahmed Massoud Hassanien
Mohamed

E-mail:

meseoozil@gmail.com

Submit Date :13-03-2024

Revise Date: 01-05-2024

Accept Date: 03-05-2024

Abstract

Background: There is not enough information available on how often hydrocephalus occurs in adult patients before and after surgery for tumors in the posterior fossa or the best way to manage it. To address this, a study was conducted to compare the effectiveness of two methods: endoscopic third ventriculostomy (ETV) and ventriculoperitoneal shunt (VPS), in reducing perioperative complications and persistent hydrocephalus in patients undergoing posterior fossa tumor surgery. **Methods:** A single-institution prospective study included 54 patients with 2nd obstructive hydrocephalus associated with posterior fossa tumors from November 2018 to June 2023. Different pathologies at different sites were encountered including cerebellar, cerebellopontine angle CPA, 4th ventricle, brain stem, and foramen magnum tumors. **Results:** A total of 54 patients; 38 ± 12.9 years, average (18 – 63) years were included in our study. Our patients were divided into two groups according to the modality of cerebrospinal fluid (CSF) diversion either ETV (23) patients or VPS (31) patients. Both ETV and VPS are valid management. **Conclusion:** The management of hydrocephalus due to posterior fossa tumors is still challenging. It should be handled carefully before attacking the tumors. Both ETV and VPS are valid modalities, but contemporarily, ETV by experienced hands is a safe and efficient alternative to VPS with low complication rates and better long-term outcomes.

Keywords: Posterior fossa tumor, Hydrocephalus. Endoscopic third ventriculostomy, Tumor-related hydrocephalus, ventriculoperitoneal shunt.

INTRODUCTION

Hydrocephalus is caused by different etiological factors and has several pathological mechanisms; CSF shunting is still considered the treatment of choice. The role of a shunt is to drain CSF from the cranial-spinal compartment into an extra-cranial compartment. Similarly, the ETV

improves the CSF circulation by bypassing the block to the

subarachnoid spaces[1]. It is widely recognized that obstructive hydrocephalus can occur as a complication of posterior fossa tumors, both before and after surgery.[2]. In adult patients undergoing surgery for posterior fossa tumors, the occurrence of hydrocephalus beforehand is 21.4%. [3, 4]. however, it increases in children to 71%–90% [5] However,

around one-third of patients with posterior fossa brain tumors may experience ongoing hydrocephalus or develop it after posterior fossa surgery. This will require a permanent diversion [3, 6]

The most common methods for managing secondary obstructive hydrocephalus associated with posterior fossa tumors in both children and adults are internal CSF diversion using ETV and external diversion using VPS.[7]. ETV is now a popular alternative to CSF shunting and entails the free flow of CSF between the ventricular system and basal cisterns by fenestration of the floor of the third ventricle, thus establishing CSF circulation through the prepontine cistern to reach the cortical subarachnoid space[8]. It has been found that preoperative shunting can lead to patients needing a permanent shunt or becoming dependent on one, which increases their risk of developing complications associated with permanent shunting. Some patients may recover after tumor resection while others may require permanent CSF shunting. Therefore, it is crucial to identify perioperative factors that can predict the need for permanent CSF shunting to prevent the unnecessary insertion of a VP shunt.[9]

METHODS

The Ethical Approval was obtained from the Ethical Committee at Zagazig University (IRB); in Egypt.

This study included 54 patients with 2^{ry} obstructive hydrocephalus associated with posterior fossa tumors from November 2018 to June 2023.

We excluded Patients having posterior fossa tumors without 2^{ry} obstructive hydrocephalus who are treated by direct tumor resection. The patients were divided into two groups according to the modality of CSF diversion either ETV (23 patients) using (LOTTA Karl Storz) rigid endoscope or VPS (31) patients.

We assessed the patients both clinically and radiologically during hospitalization and after discharge (a maximum of 3 months): In our study, success was determined by the resolution of hydrocephalus symptoms and signs throughout the follow-up period. We also noted any complications that may have occurred during CSF shunting or ETV. Radiological success was based on the resolution of preoperative radiological signs of hydrocephalus in

brain CT and/or MRI. We did not compare the long-term survival rates between the two groups as these factors were largely influenced by tumor type and location, as well as the extent of resection and craniotomy complications.

RESULTS

A total of 54 patients; mean age is 54 (37.9 ± 12.9) years, average (18 – 63) years, 37 males and 17 females were included in the study. Symptoms of increased intracranial pressure (ICP) (headache, nausea, vomiting, and diplopia) were encountered in 38 patients (70.4 %) 19 patients of them (50 %) underwent ETV and 19 VPS patients (50 %) were randomly selected. 8 patients (14.8 %) presented by disturbed conscious level (DCL), one patient (12.5 %) underwent ETV and seven patients (87.5 %) underwent VPS. Different pathologies at different sites were encountered including cerebellar, cerebellopontine angle CPA, 4th ventricle, brain stem, and foramen magnum.

The improvement of our patients was assessed both clinically and radiologically. Radiological improvement was assessed in the CT brain after CSF diversion and compared with the preoperative images. Clinical improvement was encountered in 47 patients (87 %) while 33 patients (61.1 %) have been improved radiologically (in both ETV and VPS groups) as shown in table (1).

Complications were encountered in 4 patients (30.8 %) in the ETV group versus 9 patients in the VPS group (69.2%). Five patients who had failed CSF diversion in both groups were managed by another diversion as VP shunting in the ETV group and, the patients who failed in the VPS group were managed by EVD and excision of the lesion. Mortality was encountered in 2 patients in the VPS group (one patient due to lung metastasis as a primary lesion complication, and another patient due to upward herniation as detailed in table (2).

Table (1): Demographic data (ETV vs VPS).

Items	Details	ETV group	VPS group	Total	value	Sig. P-value
Age No. (Mean ± SD)		23 (37.7 ±13)	31 (38.1 ±12)	54 (37.9 ± 12.9)	t-test = 0.12	0.9
Sex	- Male	11 (40.7%)	16 (59.3 %)	27 (50 %)	Chi-Square = .07	0.78
	- Female	12 (44.4%)	15 (55.6 %)	27 (50 %)		

Table (2): Clinical data.

Items	Details	ETV group	VPS group	Total	Chi-Square	Sig. P-value
Clinical presentation	▪ ICP	19 (50 %)	19 (50 %)	38 (70.4 %)	3.9	0.14
	▪ DCL	1 (12.5 %)	7 (87.5 %)	8 (14.8 %)		
	▪ Other	3 (42.6 %)	5 (62.5%)	8 (14.8 %)		

Table (3): Sites of the tumors.

Items	Details	ETV group	VPS group	Total	Chi-Square	Sig. P-value
Pathology	Cerebellar	8 (50 %)	8 (50 %)	16 (29.6 %)	0.79	0.93
	CPA	6 (42.9 %)	8 (57.1 %)	14 (25.9 %)		
	4 th Ventricle	4 (33.3 %)	8 (66.7 %)	12 (22.2 %)		
	Brain stem	3 (42.9 %)	4 (57.1 %)	7 (13 %)		
	Foramen Magnum	2 (40 %)	3 (60 %)	5 (9.3 %)		

Table (4): Improvement of the 2 groups.

Items	Details	ETV group	VPS group	Total	Chi-Square	Sig. P-value
Clinically Improved	Improved	22 (46.8 %)	25 (53.2 %)	47 (87 %)	2.6	0.1
	Not improved	1 (14.3 %)	6 (85.7 %)	7 (13 %)		
Radiologically Improved	Improved	15 (45.5 %)	18 (54.5 %)	33 (61.1 %)	0.28	0.59
	Not improved	8 (38.1 %)	13 (61.9 %)	21 (38.9 %)		

Table 1: Complications and the need for further diversion (ETV vs VPS).

Items	Details	ETV group	VPS group	Total	Chi-Square	Sig. P-value
Complications	No	19 (46.3 %)	22 (53.7 %)	41 (75.9 %)	0.98	0.32
	Complications	4 (30.8 %)	9 (69.2 %)	13 (24.1 %)		
	Mortality	0 (0 %)	2 (100 %)	2 (100 %)	1.54	0.21
Need for further diversion	Not Needed	22 (44.9 %)	27 (55.1 %)	49 (90.7 %)	1.15	0.28
	Needed	1 (20 %)	4 (80 %)	5 (9.3 %)		

Table 6: Complications.

Items	Descriptive	ETV	VPS	Total
	Not Complications	19 (46.3 %)	22 (53.7 %)	41 (75.9 %)
	CSF Leak	1 (100 %)	0 (0 %)	1 (1.6 %)
	Failure	1 (50 %)	1 (50 %)	2 (3.7 %)
	Infection	0 (0 %)	3 (100 %)	3 (5.6 %)
	IVH	0 (0 %)	1 (100 %)	1 (1.9 %)
	Malposition	0 (0 %)	1 (100 %)	1 (1.9 %)
	SDH	0 (0 %)	1 (0 %)	1 (1.9 %)
	Transit mutism	1 (100 %)	0 (0 %)	1 (1.9 %)
	Transient Neuro deficit	1 (50 %)	1 (50 %)	2 (3.7 %)
	Upward herniation	0 (0 %)	1 (100 %)	1 (1.9 %)

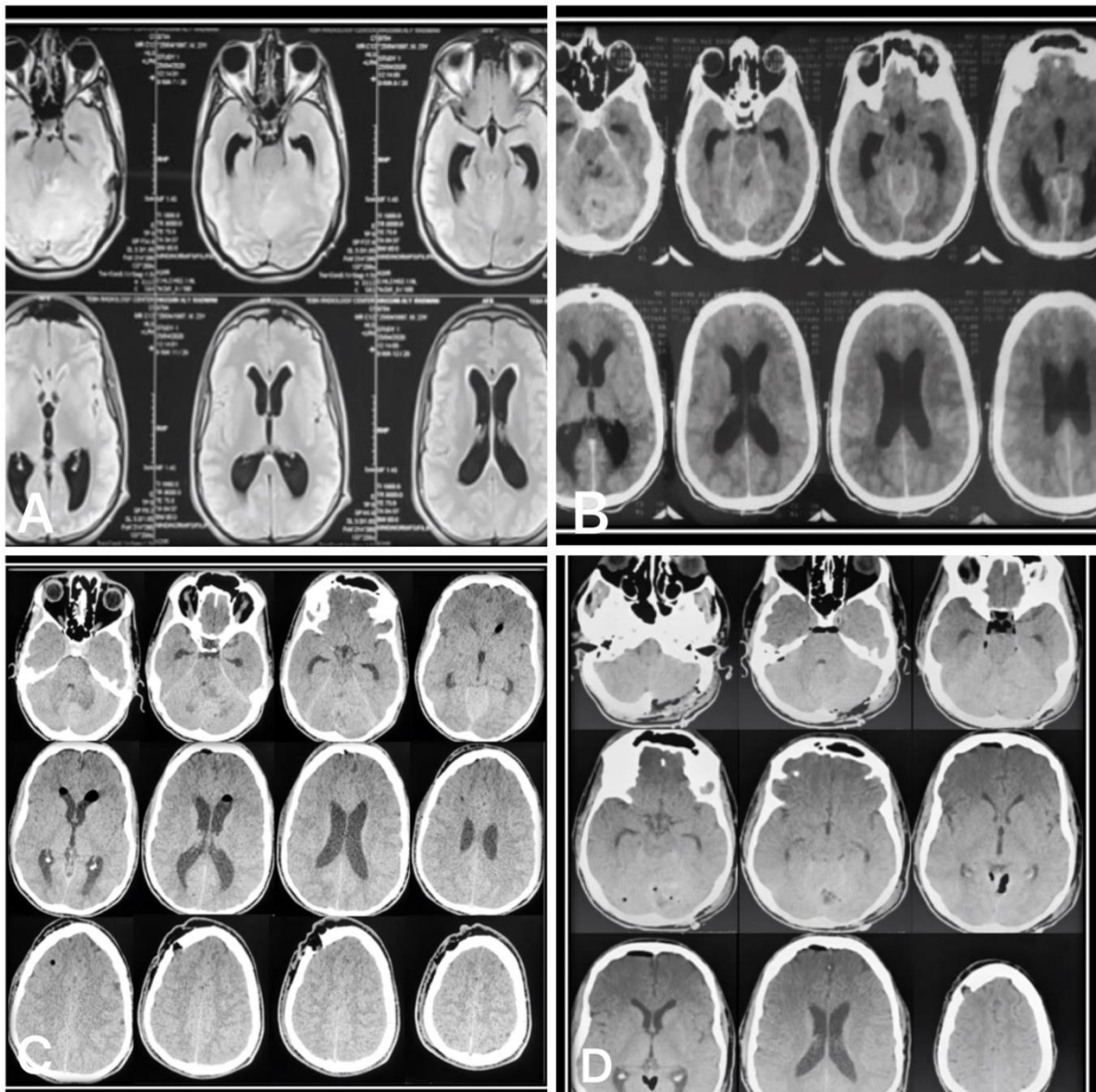


Figure (1): Preoperative MRI brain shows a posterior fossa mass and hydrocephalus, CT of the same patient, early postoperative CT shows good resolution of hydrocephalus after ETV prior to tumor excision surgery, CT after tumor excision shows complete resolution of hydrocephalus.

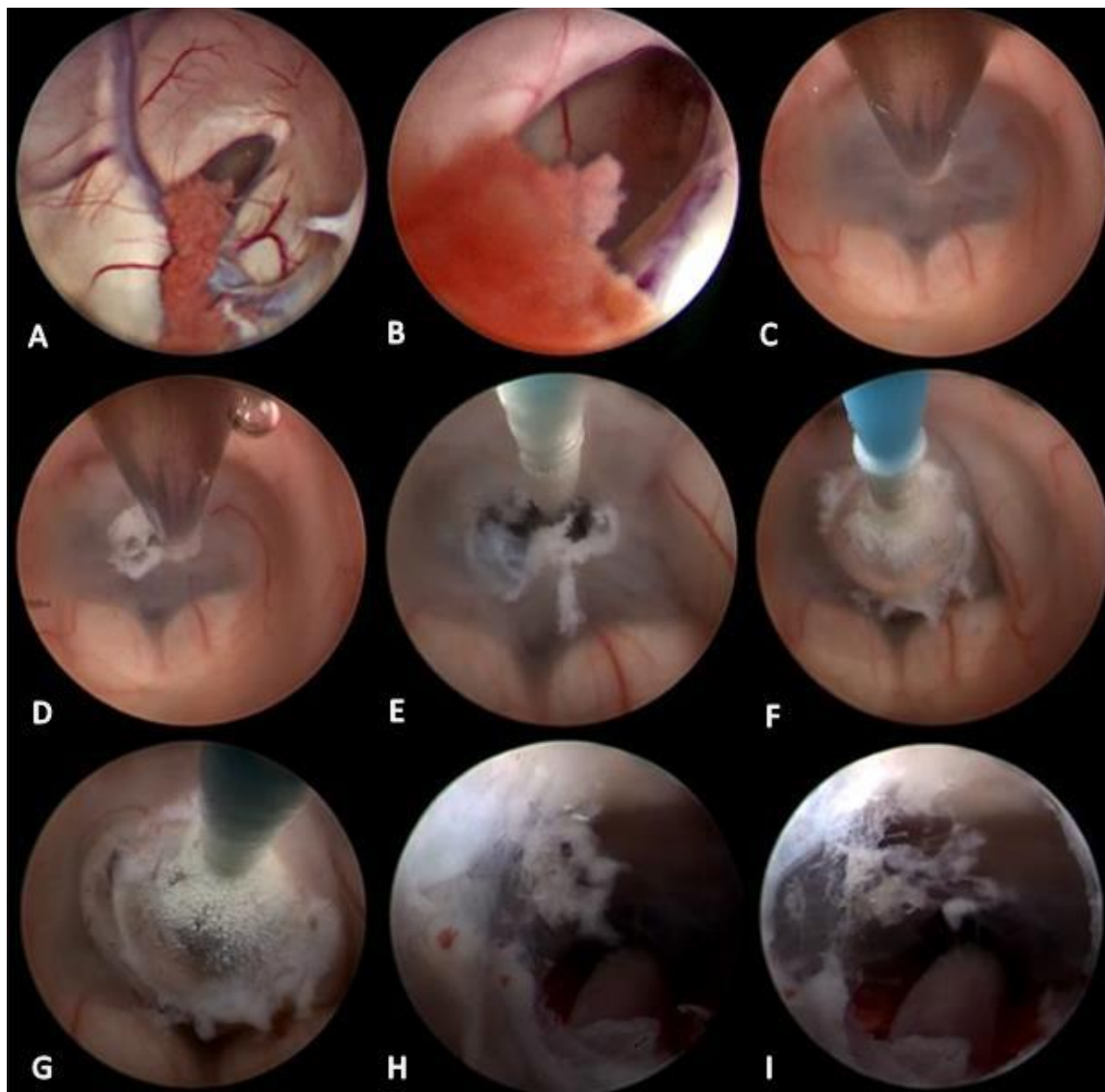


Figure (2): (A-B) the foramina of Monro through the right lateral ventricle. (C) floor of the 3rd ventricle; between the mammillary bodies and infundibular recess. (D) Fenestration of the floor of the 3rd ventricle. (E-G) Enlargement of the fenestration was done by inflating the balloon of a 3-Fr-Fogarty catheter. (H-I) Free flow of CSF through the ostium and visualization of the Basilar artery.

DISCUSSION

CSF shunting is one of the most common neurosurgical procedures performed and has been used for many years with excellent results in the treatment of multiple forms of hydrocephalus in both pediatric and adult. However, despite many advances in shunt technology over the years, the rate of shunt failure requiring revision or replacement has remained unacceptably high [10]. Culley *et al.*, reported that hydrocephalus existed preoperatively in approximately 80% of patients with tumors in the posterior fossa, and between 15-40% of patients after surgery. that required treatment for persistent hydrocephalus. Before, during, or after posterior fossa surgery, there was no agreement on how to manage hydrocephalus [11]. In addition, an ETV has only become

established over the last two decades as the preferred therapeutic option for obstructive hydrocephalus [12]. In the literature, approximately one-third of patients presented with posterior fossa tumors will eventually require a CSF diversion [11].

Girgis *et al.*, reported that the use of neuroendoscopy is comparable in both pediatric and adult. This highlights the potential benefit of neuroendoscopy in managing appropriate adult patients. As such, neuroendoscopy should be available in all neurosurgical centers and considered as a potential treatment option for suitable pediatric and adult patients [13]. In children, According to El-Ghandour's research in children, ETV proved to be superior due to its lack of mortality, shorter surgery duration, lower

incidence of morbidity, and procedure failure. Additionally, it has the advantage of being shunt-independent [14]. Although many patients who undergo tumor resection do not need long-term treatment for hydrocephalus, it is important to closely monitor the associated mortality and morbidity. Currently, ETV has been found to be a safe and effective treatment method, but shunt procedures are still necessary and commonly utilized [15].

In the past, when patients presented in a poor condition as a result of a delayed diagnosis, the placement of a preoperative VPS significantly reduced the morbidity and mortality [16], and postoperative permanent VPS was required in 40 % of patients within a month after the tumor surgery. Shunt malfunction, infections, tumor seeding, and many revisions were problems associated with VP shunting [17].

The management of hydrocephalus caused by posterior fossa tumors remains a topic of debate. In this study, selected patients who presented with hydrocephalus associated with posterior fossa tumors with strict criteria and thorough follow-up are considered to optimize the management of 2ry hydrocephalus associated with Posterior fossa tumors by correlating ETV versus VPS prior to or after surgery as regarding the patient's outcome (clinically and radiologically), complications, Failure and the further need for another CSF diversion. We tried to establish a consensus management protocol for decision-making; either ETV or VPS. Prior management of secondary hydrocephalus before surgery for posterior fossa tumors has been found to decrease the risk of postoperative hydrocephalus. This, in turn, reduces the risk of morbidity and mortality in patients [18]. This was adapted by Gnanalingham *et al.*, who noticed very few complications with patients who went to CSF diversion preoperatively [19].

Ostling and Raffel recommended removing the tumor as soon as possible when it is first detected, without relying on CSF diversion. This approach avoids shunt dependency, which some surgeons advocate despite the risk of failure, infection, and complications. However, if the tumor cannot be removed immediately, managing the resulting hydrocephalus becomes a critical and urgent concern.[20]. Before the removal of posterior fossa tumors, it was discovered that performing ETV can lower the chances of postoperative hydrocephalus. This, in turn, reduces the occurrence of morbidity and mortality in patients. Moreover, Frisoli *et al.*, recommended that ETV be performed prior to resecting posterior fossa tumors in order to lower

the likelihood of postoperative VP shunt placement. This should be considered for patients undergoing this type of surgery.[21]. Gautam and Kamble conclude that in 38 cases, ETV has been found to be a safe, efficient, and affordable option for treating obstructive hydrocephalus, resulting in positive results and fewer complications compared to the shunt procedure [22]. Marx *et al.*, conducted a study on 40 adult patients to confirm the safety and feasibility of ETV prior to posterior fossa tumor surgery. In cases where patients exhibited symptomatic hydrocephalus before tumor surgery, an ETV can be performed followed by early elective tumor surgery [23]. Also, Lima and Pratesi found no significant difference was discovered in costs between the groups that underwent ETV and VPS.[7].

We found Endoscopic Third Ventriculostomy (ETV) is not without its drawbacks, such as the potential for unsuccessful surgery, it is still a safer option compared to Ventriculoperitoneal Shunting (VPS). In the event that an ETV is unsuccessful, it can be attempted again or a shunting procedure can be performed.

Declaration of interest:

The authors report no conflicts of interest.

Funding information:

This study was not supported by any source of finding.

CONCLUSION

Managing hydrocephalus that's associated with posterior fossa tumors remains a difficult task. It should be handled carefully before attacking the tumors. Both ETV and VPS are valid modalities, but contemporarily, ETV by experienced hands is a safe and efficient alternative to VPS with low complication rates. ETV failure occurs as sooner than VPS failure, but the long-term treatment durability may be higher in the former.

REFERENCES

- [1] M. Czosnyka, Z. Czosnyka, S. Momjian, and J. D. Pickard, "Cerebrospinal fluid dynamics," *Physiol Meas*, vol. 25, no. 5, p. R51, 2004.
- [2] M. Gdk and M. M. zek, "Hydrocephalus in Pediatric Patients with Posterior Fossa Tumors," *Posterior Fossa Tumors in Children*, pp. 229–237, 2015.
- [3] S. Marx, M. Reinfelder, M. Matthes, H. W. S. Schroeder, and J. Baldauf, "Frequency and treatment of hydrocephalus prior to and after posterior fossa tumor surgery in adult patients," *Acta Neurochir (Wien)*, vol. 160, no. 5, pp. 1063–

1071, May 2018, doi: 10.1007/s00701-018-3496-x.

- [4] G. A. Bateman and M. Fiorentino, "Childhood hydrocephalus secondary to posterior fossa tumor is both an intra-and extraaxial process," *J Neurosurg Pediatr*, vol. 18, no. 1, pp. 21–28, 2016.
- [5] E. S. Molla and E. Hamza, "Management of secondary hydrocephalus associated with posterior fossa lesions in children (different modalities of treatment)," *Egyptian J Neurosurg*, vol. 31, no. 03, pp. 157–166, 2016.
- [6] M. C. Dewan, J. Lim, C. N. Shannon, and J. C. Wellons, "The durability of endoscopic third ventriculostomy and ventriculoperitoneal shunts in children with hydrocephalus following posterior fossa tumor resection: a systematic review and time-to-failure analysis," *J Neurosurg Pediatr*, vol. 19, no. 5, pp. 578–584, 2017.
- [7] B. O. de Lima and R. Pratesi, "Endoscopic third ventriculostomy has no higher costs than ventriculoperitoneal shunt," *Arq Neuropsiquiatr*, vol. 72, pp. 524–527, 2014.
- [8] F. Girgis, R. Diaz, W. Hader, and M. Hamilton, "Comparison of intracranial neuroendoscopic procedures in children versus adults," *Canadian Journal of Neurological Sciences*, vol. 42, no. 6, pp. 427–435, 2015.
- [9] R. M. Aljubour, A. K. Alomari, and A. F. Musharbash, "Risk factors for Ventriculoperitoneal shunting in children with posterior fossa tumor," *Journal Of The Royal Medical Services*, vol. 24, no. 1, pp. 45–49, 2017.
- [10] M. B. Janjua, C. E. Hoffman, and M. M. Souweidane, "Contemporary management and surveillance strategy after shunt or endoscopic third ventriculostomy procedures for hydrocephalus," *Journal of Clinical Neuroscience*, vol. 45, pp. 18–23, 2017.
- [11] D. J. Culley, M. S. Berger, D. Shaw, and R. Geyer, "An analysis of factors determining the need for ventriculoperitoneal shunts after posterior fossa tumor surgery in children," *Neurosurgery*, vol. 34, no. 3, pp. 402–408, 1994.
- [12] A. Demerdash *et al.*, "Endoscopic third ventriculostomy: A historical review," *Br J Neurosurg*, vol. 31, no. 1, pp. 28–32, 2017.
- [13] F. Girgis, R. Diaz, W. Hader, and M. Hamilton, "Comparison of Intracranial Neuroendoscopic Procedures in Children versus Adults," *Canadian Journal of Neurological Sciences*, vol. 42, no. 6, pp. 427–435, Sep. 2015, doi: 10.1017/cjn.2015.287.
- [14] N. M. F. El-Ghandour, "Endoscopic third ventriculostomy versus ventriculoperitoneal shunt in the treatment of obstructive hydrocephalus due to posterior fossa tumors in children," *Child's Nervous System*, vol. 27, pp. 117–126, 2011.
- [15] G. Tamburrini, B. L. Pettorini, L. Massimi, M. Caldarelli, and C. Di Rocco, "Endoscopic third ventriculostomy: the best option in the treatment of persistent hydrocephalus after posterior cranial fossa tumour removal?," *Child's Nervous System*, vol. 24, pp. 1405–1412, 2008.
- [16] J. Hekmatpanah and S. Mullan, "Ventriculo-caval shunt in the management of posterior fossa tumors," *J Neurosurg*, vol. 26, no. 6, pp. 609–613, 1967.
- [17] C. Di Rocco, L. Massimi, and G. Tamburrini, "Shunts vs endoscopic third ventriculostomy in infants: are there different types and/or rates of complications? A review," *Child's Nervous System*, vol. 22, pp. 1573–1589, 2006.
- [18] C. Sainte-Rose *et al.*, "Management of hydrocephalus in pediatric patients with posterior fossa tumors: the role of endoscopic third ventriculostomy," *J Neurosurg*, vol. 95, no. 5, pp. 791–797, 2001.
- [19] K. K. Gnanalingham, J. Lafuente, D. Thompson, W. Harkness, and R. Hayward, "The natural history of ventriculomegaly and tonsillar herniation in children with posterior fossa tumours—an MRI study," *Pediatr Neurosurg*, vol. 39, no. 5, pp. 246–253, 2003.
- [20] L. Ostling and C. Raffel, "Complications following preresection shunting in patients with posterior fossa tumors," *J Neurosurg Pediatr*, vol. 15, no. 1, pp. 1–3, 2015.
- [21] F. Frisoli, M. Kakareka, K. A. Cole, A. J. Waanders, P. B. Storm, and S.-S. Lang, "Endoscopic third ventriculostomy prior to resection of posterior fossa tumors in children," *Child's Nervous System*, vol. 35, pp. 789–794, 2019.
- [22] S. Gautam and S. Kamble, "Effi cacy and Safety of Endoscopic Third Ventriculostomy in Obstructive Hydrocephalus," 2017.
- [23] S. Marx *et al.*, "Endoscopic Third Ventriculostomy before Posterior Fossa Tumor Surgery in Adult Patients," *J Neurol Surg A Cent Eur Neurosurg*, vol. 79, no. 2, pp. 123–129, Mar. 2018, doi: 10.1055/s-0037-1608786.

Citation

Abaza, H., Abdulsalam, M., Harb, O., Elbadawy, M. Endoscopic Third Ventriculostomy versus Cerebrospinal Fluid Shunting in Hydrocephalus associated with Posterior Fossa Lesions in Adults; Comparative study. *Zagazig University Medical Journal*, 2024; (4233-4240): -. doi: 10.21608/zumj.2024.273788.3217