

# EVALUATION OF MINERALIZED PLASMATIC MATRIX AS A GRAFTING MATERIAL VERSUS BETA TRICALCIUM PHOSPHATE IN IMMEDIATE IMPLANT PLACEMENT OF MANDIBULAR MOLARS (A RANDOMIZED CONTROLLED CLINICAL TRIAL)

Moustafa M. Samy<sup>1\*</sup> BDS, Ahmed A. Sharara<sup>2</sup> PhD, Gaafar N. El Halawani<sup>3</sup> PhD

## ABSTRACT

**INTRODUCTION:** One of the recent grafting materials is mineralized plasmatic matrix (MPM). It is an autologous blood product with a high concentration of platelets and fibrin in addition to bone particles. Its fibrin, combined with the bone particles and the grafting material, can be shaped easily. MPM became favourable in improving treatment outcomes of dental implants due to the efficiency of bone formation.

**OBJECTIVES:** To compare clinically and radiologically the efficiency of MPM versus Beta- Tricalcium phosphate ( $\beta$ -TCP) in osseointegration during immediate placement of implant at the mandibular molar area.

**MATERIALS AND METHODS:** Randomized clinical trial done on sixteen patients, with strongly decayed mandibular molars. All patients were divided into 2 equal groups: In group A, 8 immediate implants were placed in mandibular molars using MPM as a graft in the peri-implant gap. While in group B, eight immediate implants were placed in mandibular molars using  $\beta$ -TCP as a graft in the peri-implant gap. Bone density, marginal bone loss, implant stability and peri-implant probing depth were evaluated clinically and radiologically after 6 months for all patients.

**RESULTS:** Group A showed statistically higher mean implant stability and bone density percent change after six months than group B. However the mean marginal bone loss was statistically lower. For both groups, during the six months follow up period, there was no significant difference regarding the peri-implant probing depth.

**CONCLUSION:** MPM enhances formation of bone in mandibular area and provides better bone density, implant stability and less marginal bone loss compared to  $\beta$ -TCP.

**KEYWORDS:** MPM; immediate implant; bone density; marginal bone loss; implant stability.

**RUNNING TITLE:** MPM graft in immediate mandibular implant.

1 BDS, 2014, Faculty of Dentistry, Pharos University, Alexandria, Egypt.

2 Professor of Oral and Maxillofacial Surgery, Department of Oral and Maxillofacial Surgery, Faculty of Dentistry, Alexandria University, Alexandria, Egypt.

3 Assistant Professor of Oral and Maxillofacial Surgery, Department of Oral and Maxillofacial Surgery, Faculty of Dentistry, Alexandria University, Alexandria, Egypt.

\* Corresponding Author:

E-mail: [moustafasamy92@gmail.com](mailto:moustafasamy92@gmail.com)

## INTRODUCTION

Successful dental implants have been used in replacing missed teeth long time ago. Alternative insertion and loading protocols have developed from the original protocols to reach quicker and less complicated surgical treatment timeframes. Schulte and Heimke published the first description of immediate insertion of a dental implant in an extraction socket, more than 30 years ago, in 1976 (1). The advantages of this treatment technique are: to decrease the number of surgical phases, a less treatment period, an ideal three dimensional implant positioning, greater alveolar bone preservation at the side of the tooth extracted and better aesthetics of the soft tissue (2).

In contrast, most cases of immediate implant are associated with a gap around the implant called

jumping gap. If this gap is greater than 2 mm, it is essential to use bone grafting materials to enhance bone formation around the implant (2). Autograft, allograft, xenograft, alloplast, and growth factors are different types of biomaterials that have been used for bone augmentation however there has been debate regarding the choice of the best graft material for many years (3).

Synthetic calcium phosphate bone grafts, which have exceptional biocompatibility among the bone graft materials, are frequently utilized as substitutes for autogenous bone, xenograft, or allograft materials. They have the advantages of being easily obtained, can be synthesized in different forms and don't transmit diseases (4).

Calcium phosphate grafting materials representative are hydroxyapatite (HA) and  $\beta$ -tricalcium phosphate ( $\beta$ -TCP). Since they resemble the inorganic component of bone in terms of structure and chemistry, these materials created interest for bone regeneration (4).

By releasing growth factors, platelet concentrates have been utilized to promote bone generation and improve healing. Vascular endothelial growth factor, platelet-derived growth factor, transforming growth factors  $\beta$ 1 and  $\beta$ 2 are types of the key growth factors found in large concentrations in platelets and are capable of promoting angiogenesis and cell proliferation (5).

Blood-derived products obtained by the centrifugation of the blood sample are known as platelet concentrates (6). Variety of preparations as platelet-rich plasma (PRP), platelet-rich fibrin (PRF) and plasma rich in growth factors (PRGF) have different techniques to be obtained (7). One of the most recent plasma derivatives used is Mineralized plasmatic matrix (MPM) (8).

Growth factors can be used in grafting procedures, which is beneficial and could replace the usage of the membranes. The MPM technique that depends on using the patient's plasma which have platelets and fibrin in a highly concentration liquid state combined with bone graft material is one technique of using growth factors. The shaping of the graft material is easy because of the ability of the fibrin to bind with bone (9).

Our aim in this study was to evaluate the effect of the MPM clinically and radiologically versus beta tricalcium phosphate in osseointegration during immediate placement of implant in mandibular molar.

## MATERIALS AND METHODS

Our study was done as a randomized controlled clinical trial with a 1:1 allocation ratio that was carried out after obtaining approval of the Research Ethics Committee at the Faculty of Dentistry, Alexandria University, on 21/12/2021. Ethics Committee No: 0350-12/2021. A consent form was signed by all patients before the procedure at Alexandria University's Faculty of Dentistry's Oral and Maxillofacial Surgery Department, to ensure and confirm their understanding of the risks they might be subjected to during the intervention and the outcome of the procedure.

### Patients

The study was done on sixteen patients of both gender, who complained from badly decayed molars. Patients were recruited from the outpatient clinic of Alexandria Main University Hospital. This trial was designed and reported according to CONSORT guidelines (10).

### Sample randomization

Patients were divided randomly into 2 equal groups through the website (Randomizer.org). **Group A (Study Group):** eight immediate dental implant

procedures were performed for 8 patients followed by application of MPM graft. **Group B (Control group):** eight immediate dental implant procedures were performed for 8 patients followed by application of beta tricalcium phosphate bone graft. The inclusion criteria were patients with age 20-40 years, with non-restorable mandibular molars indicated for extraction, with good oral hygiene and adequate keratinized gingiva (KG) (>2 mm). While the exclusion criteria were patients with acute periapical pathosis, patients under chemotherapy or radiotherapy, pregnancy or lactating period, patients with bad oral hygiene, systemic disease affecting bone metabolism and heavy smokers.

### Materials

- Easy D Implant System (General implants, Deutschland, Germany).
- Osstell (Osstell, Goteborg, Sweden).
- Adbone@TCP bone graft (Medbone@, Sintra, Portugal).
- Vacutest kima 10 mm vacuum plain plastic tube (Vacutest kima, Arzergrande, Italy).
- Centrifuge (800-1 Centrifugal machine, China)

### Methods

#### Pre-surgical assessment

##### Clinical examination

The patients were evaluated by taking full personal, dental and medical histories regarding hypertension, past investigations, drug history, drug allergy or any medications. Soft tissue was examined for any suppuration, discharge and swelling. The inter-arch Space was measured by a millimeter ruler. The occlusion was checked according to the normal maximum intercuspation. The gingival biotype was checked by the periodontal probe.

##### Radiographic examination

**Cone beam computed tomography (CBCT)** was done for evaluating the quality and quantity of the existing bone and for determining the length and the diameter of the proposed dental implant. (Figure 1)

##### Mineralized plasmatic matrix preparation technique (11)

Mineralized plasmatic matrix was prepared by collecting 10 ml of the patient blood in a vacuum plain plastic tube. After 15 minutes of centrifugation at 2500 rpm a yellow plasma liquid was found on the top of the sample that was separated from red blood cell found at the bottom. The yellow plasma was collected by using a plastic syringe and delivered to the cup that contains the bone graft (beta tri calcium phosphate). The MPM was formed in the cup after few seconds of mixing. (Figure 4)

##### Surgical phase

In the 2 groups, with the use of periostomes and small elevators, atraumatic extraction was done and the roots were gently removed by the forceps to preserve the buccal plate of bone. Removing any debris by curettaging the socket and copious

irrigation with saline. Using the periodontal probe to check the integrity of the extraction socket. Osteotomies were done in sequential steps and the implants were placed adequately. The implants were seated into their final position sub-crestal at least 3mm below cemento-enamel junction of neighboring tooth by using torque wrench attached to the implant and then the cover screw was placed. For group A, MPM graft was placed in the space surrounding the implant while for group B,  $\beta$ -TCP grafting mixture was placed in the space surrounding the implant. For both groups, after removing the cover screw, the ostell was used to measure the primary stability. Healing abutments were placed and then securing the grafting material with proper suturing. (Figures 2, 3)

### Post-surgical phase

Postoperative care (13): Both groups were given postoperative instructions and comprehensive oral hygiene care, including: Avoid rinsing for 24 hours after surgery. Application of cold fomentation post-operative for 24 hours with 10-minute interval per hour. Soft, high protein, caloric diet and fluids for 2 weeks postoperatively.

Postoperative medication (12): both groups were prescribed medications including: Clavulanic acid 125mg + Amoxicillin 875mg (Augmentin®, GlaxoSmithKline, UK) every 12 hours for 7 days. Non-Steroidal Anti Inflammatory drugs (Cataflam: Diclofenac potassium 50mg: Novartis. Switzerland) every 8 hours after meals for 4 days. Chymotrypsin +Trypsin 300 E.A.U (Alphintern: Chemotrypsin 300 E.A.U (14microkatal) +Trypsin 300 E.A.U (5microkatal): Amoun Pharmaceutical Co. S.A.E) every 8 hours before meals for 5 days. Mouth wash 0.12% chlorhexidine (Hexitol: Chlorhexidine 125mg/100ml concentration 0.125%: Arabic drug company, ADC) daily for 2 weeks. After 1 week of surgery, the sutures were removed.

### Follow up phase.

#### I. Clinical follow up

- **Implant stability (14):** implant stability meter (Osstell™) with Smart peg was used immediately postoperative (primary stability) and after 6 months to measure the implant stability. (Figure 5)
- **Peri-implant probing depth (15):** It was measured after 6 months by periodontal probe by measuring 6 points; three on the buccal surface (mesio-buccal, buccal, disto-buccal) and three on the lingual surface (mesio-lingual, lingual, disto-lingual) then calculating the mean of them.

#### II. Radiographic follow up

Immediate postoperative and after 6 months, CBCT was requested for evaluating the bone density and the crestal bone loss. (Figure 6)

- **Bone density (16)**

For measuring the bone density around the implant, OnDemand3D™ was used (OnDemand 3D™ software Cybermed Inc, Headquater: 6-26, Yuseong-daero 1205beon-gil, Yuseong-gu,

Daejeon, Korea E-mail: info@ondemand3d.com). OnDemand3D™ software have bone density measurement option that auto convert the grayscale to numerical value in HU. Measurements were taken pre-operatively, immediate post-operatively, 6 months post-operatively as follows:

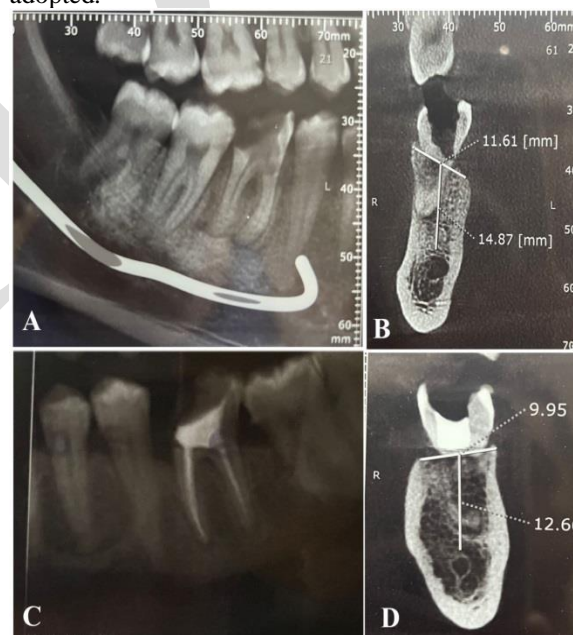- Choosing bone density in the task section found at the task bar.
- After choosing the required area, bone density was measured automatically by the system with mean, minimum and maximum reading and the standard deviation displayed.

- **Crestal bone loss (17)**

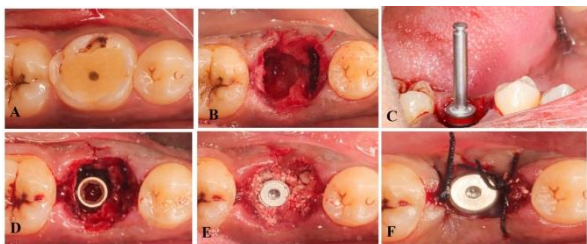
For measuring the crestal bone loss, distal and mesial crestal bone levels were calculated from the CBCT by using OnDemand3D™. The crestal bone loss has been measured by comparing the bone level in the CBCT immediate post operative and the CBCT after six months. For statistical analysis, the mean of the data of the two sides at each interval was calculated and tabulated.

### Statistical analysis

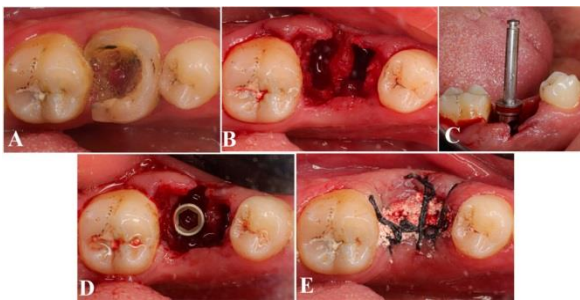
Data were collected and analyzed using Statistical Package for Social Science (SPSS) program (ver 25).(18). Kolmogorov-Smirnov test of normality revealed significance in the distribution of most of the variables, so the non-parametric statistics was adopted.



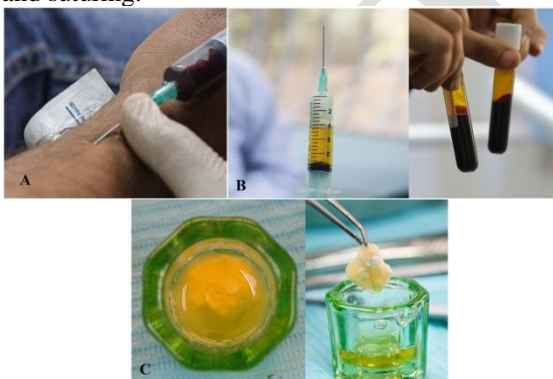**Figure (1):** Pre-operative radiographic examination. (A) Pre-operative Panoramic examination (group I). (B) Pre-operative CBCT (group I). (C) Pre-operative panoramic examination (group II). (D) Pre-operative CBCT.




**Figure (2):** Surgical phase for group I. (A) Preoperative clinical view. (B) Atraumatic extraction. (C) Final drill. (D) Implant insertion. (E) The defect covered with MPM (F) Suturing.



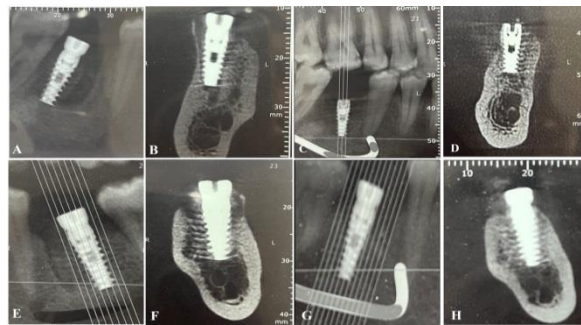
**Figure (3):** Surgical phase for group II. (A) Showing preoperative clinical view. (B) Atraumatic extraction. (C) Final drill (D) Showing implant insertion. (E) The defect covered with beta TCP and suturing.



**Figure (4):** MPM preparation (A) Showing collecting venous blood sample. (B) Showing the resultant product after centrifuging. (C) Showing prepared material (MPM).



**Figure (5):** Showing checking implant stability using Osstell®.



**Figure (6):** Post-operative follow up phase: (A) Immediate post-operative panoramic view (group I). (B) Immediate post-operative CBCT (group I). (C) Panoramic view after 6 months (group I). (D) CBCT after 6 months (group I). (E) Immediate post-operative panoramic view (group II). (F) Immediate post-operative CBCT (group II). (G) Panoramic view after 6 months (group II). (H) CBCT after 6 months (group II)

**RESULTS**

In the result section, Data will be presented as minimum, maximum, median (25<sup>th</sup> – 75<sup>th</sup> percentile).

**Biodata**

This study included sixteen patients; in eight of them MPM was placed as a graft around the immediate implant, while in the other eight patients, β-TCP was placed as a graft around the immediate implant.

**Clinical evaluation**

**Implant stability**

Immediate postoperatively, the implant stability in the MPM group ranged from 41.00 to 65.00 with a median [25<sup>th</sup> –75<sup>th</sup> percentile] of 58.00 [47.50-64.00], while in the β-TCP group, it ranged from 51.00 to 70.00 with a median of 62.50 [58.00-67.00]. Six months postoperatively, the implant stability in the MPM group ranged from 68.00 to 76.00 with a median of 70.50 [69.50-73.50], while in the β-TCP group, it ranged from 64.00 to 76.00 with a median of 70.00 [66.50-75.50]. The implant stability was not significantly different between the two studied groups immediately and six months postoperatively ( $p=.224$ ,  $p=.557$ ; respectively). In both MPM and β-TCP groups, implant stability after six months was statistically significantly higher compared with immediate postoperatively ( $p=.012$  and  $p=.012$ , respectively). The implant stability percentage change (immediate postoperatively vs. six months postoperative) of patients in the MPM group ranged from 9.23 to 70.73 with a median of 24.86 [15.02-46.78], while in the β-TCP group, it ranged from 6.56 to 27.27 with a median of 10.81 [8.97-20.44]. The implant stability percentage change of the MPM group was statistically significantly higher compared with the β-TCP group. ( $p=.046$ ) (Table 1).

**Peri-Implant Probing Depth**

In the MPM group, the Peri-Implant Probing Depth ranged from 2.00 to 4.00 mm with a median of 2.50 [2.00-3.00] mm, while in the β-TCP group, it ranged from 2.00 to 4.00 mm with a median of 3.00 [3.00-4.00] mm. There was no statistically significant difference in Peri-Implant Probing Depth between the two studied groups. ( $p=.103$ ).

**Radiographic evaluation**

**Marginal Bone Loss**

In the MPM group, the marginal bone loss ranged from 0.10 to 0.40 mm with a median of 0.30 [020-0.30] mm, while in the □-TCP group, it ranged from 0.30 to 0.40 mm with a median of 0.35 [0.30-0.400] mm. Marginal bone loss in the □-TCP group was statistically significantly higher compared with the MPM group ( $p=.040$ ) (Table 2).

**Bone density**

Immediately postoperative, the bone density in the MPM group ranged from 420.00 to 815.00 HU with a median of 637.50 [570.00 707.00] HU, while in the □-TCP group, it ranged from 635.00 to 815.00 HU with a median of 745.00 [695.00-775.00] HU.

After six months, in the MPM group it ranged from 760.00 to 980.00 HU with a median of 850.00 [820.00-895.00] HU, while in the β-TCP group, it ranged from 710.00 to 990.00 HU with a median of 815.00 [790.00-925.00] HU.

There was no statistically significant difference in bone density between the two studied. Immediately and six months postoperatively ( $p=.058$ ,  $p=.635$ ; respectively).

In MPM group, bone density after six months was statistically significantly higher compared with preoperatively ( $p<.001$ ). While in □-TCP, bone density after six months was statistically significantly higher compared with both preoperatively and immediately postoperatively ( $p<.001$  and  $p=.001$ , respectively).

Bone density percentage change (preoperatively vs. six months postoperative) in the MPM group ranged from 21.60 to 115.50% with a median of 31.79 [22.74-49.97] %, while in the TCP group, it ranged from 8.11 to 20.99% with a median of 15.35 [11.83-16.81] %. The bone density percentage change (preoperatively vs. six months postoperative) of the MPM group was statistically significantly higher compared with the TCP group. ( $p=.001$ ) (Table 3)

**Table (1):** Comparison of the implant stability at different times of measurements in the two studied groups

Implant stability	Group		Test of significance <i>p</i>
	MPM (n=8)	□-TCP (n=8)	
<b>Immediately postoperative</b>			
- Min. – Max.	41.00-65.00	51.00-70.00	$Z_{(MW)}=1.216$ $p=.224$ NS
- Median	58.00	62.50	
- Percentile 25 <sup>th</sup> – Percentile 75 <sup>th</sup>	47.50-64.00	58.00-67.00	
<b>Six months postoperatively</b>			
- Min. – Max.	68.00-76.00	64.00-76.00	$Z_{(MW)}=0.587$ $p=.557$ NS
- Median	70.50	70.00	
- Percentile 25 <sup>th</sup> – Percentile 75 <sup>th</sup>	69.50-73.50	66.50-75.50	
<b>Test of significance P</b>	$\chi^2_{(WSR)}=2.524$ $p=.012^*$	$\chi^2_{(WSR)}=2.527$ $p=.012^*$	
<b>Implant stability percentage change (%)</b>			
- Min. – Max.	9.23-70.73	6.56-27.27	$Z_{(MW)}=1.995$ $p=.046^*$
- Median	24.86	10.81	
- Percentile 25 <sup>th</sup> – Percentile 75 <sup>th</sup>	15.02-46.78	8.97-20.44	

n: number of patients

Min-Max: Minimum – Maximum

$Z_{(MW)}$ : Z test of Mann-Whitney U test

WSR: Wilcoxon Signed Ranks Test

\*: Statistically significant ( $p<.05$ )

NS: Statistically not significant ( $p\geq.05$ )

**Table (2):** Comparison of marginal bone loss (mm) in the two studied groups

Marginal Bone Loss (mm)	Group		Test of significance <i>p</i>
	MPM (n=8)	□-TCP (n=8)	
- Min. – Max.	0.10-0.40	0.30-0.40	$Z_{(MW)}=2.056$ $p=.040^*$
- Median	0.30	0.35	
- Percentile 25 <sup>th</sup> – Percentile 75 <sup>th</sup>	0.20-0.30	0.30-0.40	

n: number of patients

Min-Max: Minimum – Maximum

$Z_{(MW)}$ : Z test of Mann-Whitney U test

WSR: Wilcoxon Signed Ranks Test

\*: Statistically significant ( $p<.05$ )

NS: Statistically not significant ( $p\geq.05$ )

**Table (3):** Comparison of bone density (HU) at different times of measurements in the two studied groups

Bone density (HU)	Group		Test of significance <i>p</i>
	MPM	□-TCP	
<b>Preoperative</b>			
- Min. – Max.	400.00-800.00	630.00-850.00	$Z_{(MW)}=2.049$ $p=.040^*$
- Median	632.50	735.00	
- Percentile 25 <sup>th</sup> – Percentile 75 <sup>th</sup>	560.00-695.00	690.00-780.00	
<b>Postoperative</b>			
- Min. – Max.	420.00-815.00	635.00-815.00	$Z_{(MW)}=1.895$ $p=.058$ NS
- Median	637.50	745.00	
- Percentile 25 <sup>th</sup> – Percentile 75 <sup>th</sup>	570.00-707.50	695.00-775.00	
<b>Six months postoperatively</b>			
- Min. – Max.	760.00-980.00	710.00-990.00	$Z_{(MW)}=0.474$ $p=.635$ NS
- Median	850.00	815.00	
- Percentile 25 <sup>th</sup> – Percentile 75 <sup>th</sup>	820.00-895.00	790.00-925.00	
<b>Friedman Test of significance P</b>	$\chi^2(df=2)=15.548$ $p<.001^*$	$\chi^2(df=2)=13.867$ $p=.001^*$	
<b>Preoperative vs. postoperative percentage change (%)</b>			
- Min. – Max.	0.00-5.00	-5.88 - 1.43	$Z_{(MW)}=2.001$ $p=.045^*$
- Median	1.94	0.71	
- Percentile 25 <sup>th</sup> – Percentile 75 <sup>th</sup>	0.74-2.75	0.00-1.36	
<b>After six months vs. preoperative percentage change (%)</b>			
- Min. – Max.	21.60-112.50	8.11-20.99	$Z_{(MW)}=3.361$ $p=.001^*$
- Median	31.79	15.35	
- Percentile 25 <sup>th</sup> – Percentile 75 <sup>th</sup>	22.74-49.97	11.83-16.81	
<b>Six months vs. postoperative percentage change (%)</b>			
- Min. – Max.	20.25-102.38	6.67-23.75	$Z_{(MW)}=2.995$ $p=.003^*$
- Median	29.84	15.10	
- Percentile 25 <sup>th</sup> – Percentile 75 <sup>th</sup>	21.39-46.74	10.64-18.12	

n: number of patients

Min-Max: Minimum – Maximum

Z(MW): Z test of Mann-Whitney U test

□2: Chi Square of Friedman test

\*: Statistically significant ( $p < .05$ )

NS: Statistically not significant ( $p \geq .05$ )

## DISCUSSION

In this study, MPM was prepared following the protocol presented by Perisse et al. in 2012 (20) and modified by ElMoheb in 2014 (21) to obtain a homogeneous product of mixing of two phases: the plasma phase and the mineral phase of bone graft. Due to the bond that existed between the graft particles and the fibrin network, the created MPM had a specific physical form. During adaptation to the host bed, this form always preserved all the graft particles, which illustrates how strongly the particles were bonded together. Without the aid of any firm fixing device, MPM can maintain the created form, resist displacement, and maintain its integrity due to this unique form. Another unique feature of MPM is its capability to stick to the bone surface after adaptation, which further increases its stability in the recipient bed (22).

Measuring peri implant probing depth after 6 months postoperatively, no statistically significant difference between the two groups was found as the mean in the MPM group was  $2.62 \pm 0.74$  and in  $\beta$ -TCP group was  $3.25 \pm 0.71$ . These results agreed with Winitzky et al. (23) who stated that the mean of the peri-implant probing depth was  $4.0 \pm 1.8$  mm in a retro-prospective long-term follow-up of single implants in the anterior maxilla retrospective research on 42 patients.

The current clinical trial assessed primary stability and its progression to secondary stability after 6 months. As a result of this study, there was a statistically significant increase in the mean ISQ (primary vs sixth month) with the MPM when compared with  $\beta$ -TCP. At the immediate post-operative phase, the mean of the implant stability value in the MPM group was  $55.63 \pm 9.61$  and at the 6<sup>th</sup> month post-operative was  $71.38 \pm 3.02$ . In the  $\beta$ -TCP group immediately postoperative phase was  $62.00 \pm 6.52$  and at the 6<sup>th</sup> months post-operative was  $70.50 \pm 4.78$ . These findings agreed with Huwiler et al. (24) who found that the mean ostell measurement increased with the integration and healing phase of the implant and also matched with Sultan et al and Elbokle et al. (25,26) in their study of measuring implant stability of 14 patients with immediate implant placement grafted by autogenous bone graft VS nanohydroxyapatite bone graft VS MPM, they stated that MPM showed better results regarding implant stability.

The crestal bone loss was significantly different between both groups 6<sup>th</sup> months post-operatively with a mean of  $0.26 \pm 0.09$  in the MPM group and  $0.35 \pm 0.05$  in  $\beta$ -TCP group. This finding matches

with what Sghaireen et al. (27) found in 2020 in their study that compared implant stability, crestal bone loss and bone density using MPM versus allograft material. Patients were selected from a stratified group and received two implants. MPM was selectively inserted in the surgical gap around one implant on one side and on the other side an allograft was inserted in a cross-over design clinical experiment. In the MPM side the mean crestal bone loss was  $0.53 \pm 0.69$  mm while it was  $0.57 \pm 0.27$  in the other side. According to this result the MPM group had lesser crestal bone loss than allograft group with a statistically significant difference.

According to our study findings, there was a significant statistical increase in percent change of bone density in the MPM group than  $\beta$ -TCP after six months when bone density was measured using CBCT. The current study findings in relation to bone density are consistent with those made by Sultan et al. and Elbokle et al. in their study comparing MPM VS autogenous bone graft VS nanohydroxyapatite bone graft on bone density, who discovered that MPM had positive effects on bone density (25,26). Additionally, it agrees with Cinar et al., who studied how MPM affected new bone formation and volume stability over time in maxillary sinus augmentation VS  $\beta$ -TCP and found that MPM can considerably enhance new bone formation in comparison to  $\beta$ -TCP (28).

In our study, regarding percent change in peri-implant bone density, there was a significant difference between both groups as the mean in the MPM group was  $39.82 \pm 27.83$  and in the  $\beta$ -TCP group was  $14.77 \pm 5.55$ . The result of Sghaireen et al. (27) in 2020 who compared implant stability, bone density and bone loss using MPM against allograft material was in line with our finding. They found that the mean value of bone density at the MPM group after 4-5 months was  $665.2 \pm 236.5$  HU while it was  $557.8 \pm 201.2$  HU in the side of the allograft material. Bone density was significantly higher at the MPM group.

According to our study, we found that MPM enhances the new bone formation in the posterior mandibular molar area without the need of collagen membrane. This finding was in line with Abdelfadil et al. study in 2020 who evaluated the horizontal ridge augmentation by MPM with and without membrane coverage in sixteen edentulous spaces (29). Three CBCT were obtained at different time; preoperative, immediately post-operative and six months postoperative to evaluate the alveolar ridge and the resorption of the grafting material at 3 predetermined points all over the site where the future dental implant placed. They found that the horizontal ridge augmentation was successful without using collagen membrane when MPM was used as a grafting material.

## CONCLUSIONS

Within the limitations of our study, it was concluded that MPM enhances formation of bone in mandibular area and provides better bone density, implant stability and less marginal bone loss compared to  $\beta$ -TCP.

## CONFLICT OF INTEREST

The authors declare that they have no conflicts of interest.

## FUNDING STATEMENT

The authors received no specific funding to conduct this study.

## REFERENCES

- Schulte W, Heimke G. [The Tubinger immediate implant]. *Quintessenz*. 1976;27:17–23.
- Chen ST, Wilson TG, Hammerle CH. Immediate or early placement of implants following tooth extraction: review of biologic basis, clinical procedures, and outcomes. *Int J Oral Maxillofac Implants*. 2004;19 Suppl:12–25.
- Starch-Jensen T, Jensen JD. Maxillary sinus floor augmentation: a review of selected treatment modalities. *J Oral Maxillofac Res*. 2017;8:e3.
- Yoo HS, Bae JH, Kim SE, Bae EB, Kim SY, Choi KH, et al. The Effect of Bisphasic Calcium Phosphate Block Bone Graft Materials with Polysaccharides on Bone Regeneration. *Materials (Basel)*. 2017;10:17.
- Froum SJ, Wallace SS, Tarnow DP, Cho SC. Effect of platelet-rich plasma on bone growth and osseointegration in human maxillary sinus grafts: three bilateral case reports. *Int J Periodontics Restorative Dent*. 2002;22:45–53.
- Ortega-Mejia H, Estrugo-Devesa A, Saka-Herrán C, Ayuso-Montero R, López-López J, Velasco-Ortega E. Platelet-rich plasma in maxillary sinus augmentation: Systematic review. *Materials (Basel)*. 2020;13:622.
- Yelamali T, Saikrishna D. Role of platelet rich fibrin and platelet rich plasma in wound healing of extracted third molar sockets: a comparative study. *J Maxillofac Oral Surg*. 2015;14:410-6.
- Nadon F, Chaput B, Perisse J, De Beraill A, Lauwers F, Lopez R. Interest of mineralized plasmatic matrix in secondary autogenous bone graft for the treatment of alveolar clefts. *J Craniofac Surg* 2015;26:2148-51.
- Amine K, Gharibi A, Hsaine A, Kissa J. Effect of bone regeneration with mineralized plasmatic matrix for implant placement in a esthetic zone. *Case Rep Dent* 2017;2639564:2017.
- Moher D, Hopewell S, Schulz KF, Montori V, Gøtzsche PC, Devereaux PJ, et al. CONSORT 2010 explanation and elaboration: updated guidelines for reporting parallel group randomised trials. *J Clin Epi*. 2010;63:e1-37.
- Perisse J, Bouzekri H, Mazzoni L, Caveriviere P, Betito M, MarchoM, et al. Aspect Clinique et histologique des matrices plasmaticques mineralisees (MPM): nouveau protocole du PRF. *La lettre de la stomatology*. 2012;23-5. Available at: <https://journal-stomato-implanto.com/content/aspect-clinique-et-histologique-des-matrices-plasm-atiques-min%C3%A9ralis%C3%A9es-mpm-nouveau>.
- Bratzler DW, Dellinger EP, Olsen KM, Perl TM, Auwaerter PG, Bolon MK, et al. Clinical practice guidelines for antimicrobial prophylaxis in surgery. *Am J Health Syst Pharm* 2013;70:195-283.
- Hattingh A, Hommez G, De Bruyn H, Huyghe M, Vandeweghe S. A prospective study on ultra-wide diameter dental implants for immediate molar replacement. *Clin Implant Dent Relat Res*. 2018;20:1009-15.
- Herrero-Climent M, Santos-García R, Jaramillo-Santos R, Romero-Ruiz MM, Fernández-Sahrmann P, Schoen P, Naenni N, Jung R, Attin T, Schmidlin PR. Peri-implant bone density around implants of different lengths: A 3-year follow-up of a randomized clinical trial. *J Clin Periodontol* 2017;44:762-8.
- John V, Shin D, Marlow A, Hamada Y. Peri-Implant Bone Loss and Peri-Implantitis: A Report of Three Cases and Review of the Literature. *Case Rep Dent* 2016;2016:2491714.
- IBM Corp. IBM SPSS Statistics for Windows, Version 25.0. Armonk, NY: IBM Corp.;2017.
- Chiapasco M, Zaniboni M, Boisco M. Augmentation procedures for the rehabilitation of deficient edentulous ridges with oral implants. *Clin Oral Implants Res*. 2006;17:136-59
- Périsse J, de Béraill A, Lauwers F, Lopez R. Interest of mineralized plasmatic matrix in secondary autogenous bone graft for the treatment of alveolar clefts. *J Craniofac Surg* 2015;26:2148-51.
- El Moheb M. The use of Growth Factors Fibrin Network to enhance architecture. Mechanical and biological aspects of the graft particles. *Int J Pre Clin Dent Res* 2014;1:41-4.
- El Moheb M, Bader AZ, Mohad GS, Santosh P, Abeer S, Basel B, et al. Mineralized Plasmatic Matrix to Enhance the bone grafting technique. *J Hard Tissue Biol*. 2017;26:289-92.
- Winitsky N, Olgart K, Jemt T, Smedberg JI. A retro-prospective long-term follow-up of Brånemark single implants in the anterior maxilla in young adults. Part 1: Clinical and radiographic parameters. *Clin Implant Dent Relat Res* 2018;20:937-44.
- Huwiler MA, Pjetursson BE, Bosshardt DD, Salvi GE, Lang NP. Resonance frequency analysis in relation to jawbone characteristics and during early healing of implant installation. *Clin Oral Implants Res*. 2007;18:275-80.
- Sultan OI, Chehata IM, Hossam AM. Implant stability parameters & bone density values of different graft materials with immediately

- placed dental implants. *Egypt Dent J.* 2018;64:3135-48.
25. Elbokle NN, Sultan OI, Chehata IM, Hossam AM. Effect Of Bone Regeneration With Platelets Rich Fibrin Versus Mineralized Plasmatic Matrix For Immediate Implant Placement. *Egypt Dent J.* 2017; 63:3057-67.
26. Sghaireen M, Alzarea B, Alam M, Ganji K, Alhabib S, Shrivastava D, et al. Clinical report implant stability, bone graft loss and density with conventional and mineralized plasmatic matrix bone graft preparations (A Randomized Crossover Trial). *J Hard Tissue Biol* 2020;29:273-8.
27. Cinar IC, Gultekin BA, Saglanmak A, Yalcin S, Olgac V, Mijiritsky E. Histologic, Histomorphometric, and Clinical Analysis of the Effects of Growth Factors in a Fibrin Network Used in Maxillary Sinus Augmentation. *Int J Environ Res Public Health.* 2020;17:1918.
28. Abdelfadil E, Aboelmaaty W. Mineralized Plasmatic Matrix for Horizontal Ridge Augmentation in Anterior Maxilla with and without a Covering Collagen Membrane. *Open Dent J* 2020;14:743-51.

ADJ