

Role of Strain Histogram Elastography using Endoscopic Ultrasound for Differentiating Malignant from Benign Pancreatic Masses

Hany R. ElKholly^a, Hossam A. Bayoumi^a, Hussein H. Okasha^b, Ahmed F. Alzohery^a

^a Department of Hepatology , Gastroenterology and Infectious Diseases, Faculty of Medicine Benha University, Egypt.

^b Department of Internal Medicine Faculty of Medicine, Cairo University, Egypt.

Corresponding to: Ahmed F. Alzohery, Department of Hepatology, Gastroenterology and Infectious Diseases, Faculty of Medicine Benha University, Egypt.

Email:

ahmedfathyalzohery@proton.me

Received: 1 April 2024

Accepted: 15 May 2024

Abstract

Background: For the differential diagnosis of localized pancreatic masses, endoscopic ultrasonography (EUS) and EUS-guided fine-needle aspiration (EUS-FNA) are currently the methods of choice. By assessing tissue stiffness, elastography, a minimally invasive approach, improves the accuracy of identifying solid pancreatic lesions using qualitative and quantitative (strain ratio and strain histogram (SH)) methods. This study aimed to assess the reliability of the SH EUS-based technique for the diagnosis of patients with pancreatic masses. **Methods:** This cross-sectional study was conducted on fifty patients attending Kasr Al-Ainy Hospital. All patients fulfilling the inclusion criteria, were enrolled in the study after ethical approval obtained from the hospital ethical committee of Benha Faculty of Medicine. The patients presented variably with obstructive jaundice, abdominal pain, and cachexia and were investigated with abdominal ultrasound, computed tomography (CT) of the abdomen and pelvis, magnetic resonance imaging (MRI), and full laboratory tests. After fulfilling the criteria of our study, patients underwent EUS with strain histogram elastography and fine needle aspiration with histopathological examination where 35 specimens were found malignant, and 15 specimens were found benign. **Results:** SH Elastography can significantly predict malignant tumors with an area under the curve (AUC) of 0.914, P value <0.001, and at a cutoff value ≤ 56 with 94.2% sensitivity, 60.0% specificity, 84.6% positive predictive value (PPV), and 81.8% negative predictive value (NPV).

Conclusion: SH showed high sensitivity in pancreatic malignant tumor detection but with moderate specificity.

Keywords: Endoscopic ultrasound; EUS-FNA; Elastography; Strain histogram; Pancreatic cancer.

Introduction

Pancreatic lesions represent a significant clinical challenge due to their diverse etiologies and potential for malignancy. The ability to accurately differentiate between benign and malignant pancreatic masses is pivotal for guiding appropriate management strategies, optimizing patient outcomes, and avoiding unnecessary interventions. Over the years, a multitude of imaging techniques have been developed to enhance the diagnostic accuracy of pancreatic lesions. Among these, endoscopic ultrasound (EUS) has emerged as a valuable modality, offering high-resolution imaging and the potential for real-time tissue characterization (1).

EUS, coupled with fine-needle aspiration (FNA), has traditionally played a crucial role in obtaining cytological and histological specimens for definitive diagnosis. However, this approach is not without limitations, such as the potential for inconclusive results due to inadequate sample acquisition or challenges in differentiating between benign and malignant lesions based solely on cytology. Consequently, there has been a growing interest in exploring adjunctive imaging techniques that can provide additional diagnostic information and enhance the accuracy of pancreatic lesion characterization (2).

Elastography, a relatively novel approach, has gained prominence in recent years as a promising technique for assessing tissue stiffness and differentiating between benign and malignant lesions. Strain elastography utilizes tissue deformation in response to external compression to generate color-coded maps that reflect tissue stiffness variations. This method has demonstrated

utility in various organs, including the breast, liver, and thyroid. Given the inherent differences in tissue stiffness between benign and malignant lesions, strain elastography presents an opportunity to enhance the diagnostic precision of pancreatic lesion differentiation (3).

While several studies have investigated the role of elastography in the assessment of pancreatic lesions, there remains a need to explore more refined techniques to extract quantitative data from elastographic images. The strain histogram (SH) approach, which involves the quantification of strain values across a range of tissue areas, offers a potentially more objective and reliable means of evaluating tissue stiffness variations. By employing this technique in conjunction with EUS, it is possible to create SHs that provide a comprehensive representation of tissue stiffness distribution within a lesion (4).

The purpose of this study was to assess the reliability of the SH endoscopic ultrasonography (EUS)-based technique for the diagnosis of patients with pancreatic masses.

Patients and methods

This cross-sectional study was conducted on fifty patients attending Kasr Al-Ainy Hospital from November 2020 to October 2023. All patients fulfilling the inclusion criteria were enrolled in the study after ethical approval was obtained from the hospital ethical committee of Benha Faculty of Medicine.

Inclusion Criteria: The study enrolled patients aged 18 years and older who presented with symptoms indicative of pancreatic masses, such as obstructive jaundice, abdominal pain, or cachexia. All participants had confirmed pancreatic masses on at least one imaging modality—ultrasound, CT, or MRI—prior to enrollment. Eligibility also required patients to be medically fit for sedation and endoscopic procedures, including EUS.

Exclusion criteria were patients unfit for deep sedation by Propofol injection, bleeding disorders (platelets less than 50,000, prothrombin time more than 16 second or INR more than 2) contraindicating EUS-FNA.

Patients variably presented with obstructive jaundice, abdominal pain, and cachexia. **Comprehensive imaging and laboratory investigations were performed as follows:**

Abdominal Ultrasound: Used as a preliminary imaging technique to assess the size, location, and characteristics of pancreatic masses. It helped in identifying the presence of any cystic components or calcifications within the lesions.

Computed Tomography (CT) of the abdomen and pelvis: Performed using a triphasic approach, which includes non-contrast, arterial phase, and venous phase scans. This comprehensive CT imaging was crucial for assessing the local extent of the pancreatic masses, the involvement of surrounding structures, vascular encasement, and the presence of distant metastases.

Magnetic Resonance Imaging (MRI): Conducted with and without contrast enhancement to provide detailed soft tissue contrast and better characterization of the

pancreatic lesions. MRI was particularly useful in distinguishing between solid and cystic components of the masses and in evaluating the ductal anatomy and bile duct involvement.

Following these preliminary assessments, patients who met the study criteria underwent endoscopic ultrasound (EUS) with strain histogram elastography and fine needle aspiration (FNA) for histopathological examination. This procedure confirmed the nature of the lesions, with 35 specimens found to be malignant and 15 benign.

All studied cases were subjected to the following: Detailed history taking, including [age, gender, comorbidity (diabetes mellitus, hypertension, others)]. **Clinical general and local abdominal examination: straining** (organomegaly, abdominal pain, others). **Routine laboratory investigations:** Routine full labs and tumor markers: Carbohydrate antigen (CA) 19-9, Carcinoembryonic Antigen (CEA) and alpha-fetoproteins]. Abdominal US and Triphasic CT/ MRI.

Premedication: EUS was performed under light sedation. Every patient received 100 mg of propofol. Sometimes, local pharyngeal anesthesia (xylocaine spray) was done.

The echoendoscope: linear scanning (Echoendoscope, Pentax EG-3870UTK).

Generally, the endoscope was introduced and guided to the second part of the duodenum. The endoscopic ultrasound examinations were performed during gradual withdrawal. The pancreas was examined through the known 4 stations. The examined lesion was first classified as

benign or malignant based on the conventional B mode images.

Characteristics of patients with malignant lesions compared to patients with inflammatory lesions according to EUS: Malignant lesions: A focal mass with diameter more than 3cm, most common site is pancreatic head causing obstructive jaundice. The malignant lesion can invade nearby vessels, malignant lymph nodes and metastasis may occur, most malignant lesions had had elastography grade 3 and 4.

Chronic pancreatitis: diffuse enlargement of the pancreas with dilated pancreatic duct, exaggerated lobular pattern, fibrous strands, and calcifications. Pancreatic cysts or pancreatic duct stones may occur. pancreatitis has elastography grade 1 and 2.

Elastography images were recorded using (Echoendoscope, Pentax EG-3870UTK) attached to Hitachi Avius US machine under Propofol deep sedation.

Endoscopic ultrasound (EUS) was performed using a linear scanning echoendoscope (Pentax EG-3870UTK), with patients under light sedation provided by propofol. The examination covered the known four stations of the pancreas during a gradual withdrawal from the duodenum (5). Lesions were initially classified based on conventional B-mode images. Criteria for classifying lesions as malignant included the presence of a focal mass with a diameter greater than 3 cm, commonly located in the pancreatic head, causing obstructive jaundice and potential invasion of nearby vessels. Malignant features also included the presence of malignant lymph nodes and potential metastases, with these lesions often exhibiting higher elastography grades (3 and 4) indicative of increased tissue stiffness (5).

In contrast, chronic pancreatitis was identified by features such as diffuse enlargement of the pancreas, dilated pancreatic ducts, exaggerated lobular patterns, fibrous strands, and calcifications, typically showing lower elastography grades (1 and 2), which indicate softer tissue consistency (6).

Elastography images were recorded and analyzed using the integrated software on the Hitachi Avius ultrasound machine (Echoendoscope, Pentax EG-3870UTK), which automatically calculated the strain histogram values from manually selected regions of interest within the lesions. The classification and quantification approach for the strain histograms were based on existing literature that correlates specific elastographic patterns with histopathological findings (7).

The SH ratio was calculated by a special software for each patient. After the elastography measurements FNA was performed (Echotip, Cook Endoscopy and Echotip procore-Cook endoscopy) in all patients with pancreatic masses (8).

Final diagnosis achieved by: Surgical exploration, major vessel involvement, FNA, distant metastasis, in the patients with negative cytology. Finally, the patients with pancreatic masses were divided into two groups according to cytology/ histology and clinical course after a follow-up period of six months. The first group represents patients with verified pancreatic malignancy and the second group represents patients with mass-forming pancreatitis.

Statistical analysis

Statistical analysis was conducted using SPSS v27 (IBM©, Chicago, IL, USA). The

Shapiro-Wilks test and histograms evaluated the normality of data distribution. Parametric data were expressed as means and standard deviations and analyzed using unpaired t-tests, while non-parametric data were presented as medians and interquartile ranges and analyzed using the Mann-Whitney U test. Qualitative data were expressed as percentages and analyzed using the Chi-square test or Fisher's exact test when appropriate. The diagnostic performance of strain histogram elastography was assessed by calculating the area under the ROC curve (AUC), sensitivity, specificity, positive predictive value (PPV), and negative predictive value (NPV), with results detailed and visualized in Figure 1.

Approval Code: Ms. 18. 8. 2022

Results

The studied patients, the age of the studied patients ranged from 18 – 77 years with a mean of 57.1 ± 11.85 years. Among the studied patients, 31 (62%) were males and 19 (38%) were females with 21 of males had malignant lesions and 10 were benign and 14 of the females had malignant lesions and 5 females were benign. Of the studied patients, 11 (22%) patients had special habits, 10 (20%) patients were smokers, and 1 (2%) patient was alcoholic. Error! Reference source not found.

In this study, 70% of cases were malignant which were adenocarcinoma, and the remaining 30% cases were diagnosed as benign lesions with pancreatitis taking the upper hand in diagnosis by reaching 4 (8%) cases, autoimmune pancreatitis was found in 3 (6%) patients, NET was found in 3 (6%) patients, SPPN was found in 3 (6%) patients, IPMN was found in 1 (2%) patient

and microcystic cystadenoma were found in 1 (2%) patient. **Table 2**

Detected Mass Data and Tumor Type and Staging of the Studied Patients:

In this study involving 50 patients, the mass characteristics and staging were detailed as follows. The mean length of the masses was 32.0 mm (standard deviation, SD: 15.06 mm) with a range from 15 to 63 mm, and the mean width was 39 mm (SD: 18.7 mm) ranging from 14 to 83 mm. Regarding the mass location, 19 masses (38%) were located in the head of the pancreas, 5 (10%) in the body, 6 (12%) at the head and uncinate process, 4 (8%) in the body and tail, another 4 (8%) spanning the head, body, and tail, with single masses (2% each) found at the tail, swollen pancreatic head, uncinate process, and at the junction of the neck and body. Additionally, there were solitary instances (2% each) of focal pancreatitis vs mass, head and body vs solid pseudopapillary neoplasm (SPPN), and neck and body SPPN.

Tumor type analysis revealed that 15 patients (30%) had benign tumors, whereas 35 patients (70%) had malignant tumors. Staging of malignant tumors was as follows: T2N1 in 3 patients (6%), T2N0 in 2 (4%), T3N1 in 14 (28%), T4N1 in 7 (14%), T3N1M1 in 2 (4%), T4N1M1 in 3 (6%), T3N2 in 1 (2%), T3N0 in 2 (4%), and T4N2 in 1 (2%).

SH Elastography can significantly predict malignant tumors with AUC of 0.914, P value <0.001 , and at cutoff value ≤ 56 with 94.2% sensitivity, 60.0 % specificity, 84.6 % PPV and 81.8% NPV. CA 19-9 can significantly predict malignant tumors with AUC of 0.927, P value <0.001 , and at cutoff value >40 U/mL with 97.14% sensitivity,

93.33% specificity, 97.1% PPV and 93.33% NPV. Bilirubin can significantly predict malignant tumors with AUC of 0.766, P value <0.001, and at cutoff value >1.5 mg/dL with 62.86% sensitivity, 86.67% specificity, 90.9% PPV and 46.4% NPV. Age can significantly predict malignant tumors with AUC of 0.823, P value <0.001, and at cutoff value >57 years with 71.43% sensitivity, 86.67% specificity, 92.6% PPV and 56.5% NPV. Amylase and lipase were insignificant predictors of malignant tumors. **Table 3 and Figure 1**

Detected mass data and tumor type and staging of the studied patients are shown in Age was significantly higher in patients with malignant tumor compared to those with benign tumor. Special habits and associated comorbidities (chronic disease) were insignificantly different, while regarding clinical presentation, patients with malignant

tumor had significantly increased complain as weight loss, jaundice and clinical signs as cachexia compared to those with benign tumor. **Table 4**

CA 19-9 and bilirubin levels were significantly higher in malignant group while amylase and lipase were significantly lower in malignant group compared to benign group. There was a significant different between both group regarding radiological findings and the EUS diagnosis. SH Elastography was significantly lower in malignant group compared to benign group (32.5 ± 13.6 vs. 66.7 ± 21.16, P<0.001). **Table 5**

Detected mass data (mass length, width and location) were insignificantly different between both groups. There was a significant different between both group regarding the tumor staging (P=0.035). **Table 6**

Table 1: Baseline characteristics and chronic diseases of the studied patients

Parameters		n=50
Age (years)	Mean ± SD	57.1 ± 11.85
Sex	Male	31 (62%)
	Female	19 (38%)
Special habits	No abnormality	39 (78%)
	Smoker	10 (20%)
	Alcoholic	1 (2%)
Chronic diseases		
DM		5 (10%)
HTN		7 (14%)
DM & HTN		3 (6%)
IHD & HTN		1 (2%)
Rheumatoid arthritis		1 (2%)
Hypothyroidism		1 (2%)
No abnormality		32 (64%)
Clinical presentation		
Cachexia		6 (12%)
Jaundice		12 (24%)
Tenderness		18 (36%)
Hepatomegaly		2 (4%)

DM: diabetes mellitus, HTN: hypertension, IHD: ischemic heart disease

Table 2: Laboratory investigations, radiological findings, EUS diagnosis, histopathology and SH Elastography of the studied groups

		n=50
Laboratory investigations		
ALT (U/L)	Mean ± SD	106.7 ± 87.46
	Range	21 - 393
	Median (IQR)	83 (52.5 – 110)
AST (U/L)	Mean ± SD	82.1 ± 68.1
	Range	14 - 265
	Median (IQR)	59.5 (39 – 82)
Bilirubin (mg/dL)	Mean ± SD	2.6 ± 2.06
	Range	0.9 - 8
	Median (IQR)	1.45 (1 - 3.975)
Amylase (U/L)	Mean ± SD	74.8 ± 73.96
	Range	24 - 420
	Median (IQR)	48 (37 – 74)
Lipase (U/L)	Mean ± SD	68.1 ± 66.36
	Range	23 - 380
	Median (IQR)	45.5 (37 - 67.75)
CA 19-9 (U/mL)	Mean ± SD	124.1 ± 182.51
	Range	15 - 952
	Median (IQR)	72.5 (39 - 95.75)
Radiological findings		
Detected by CT	13 (26%)	
Detected by MRI	29 (58%)	
Detected by ultrasound	5 (10%)	
Detected by PET/CT	1 (2%)	
Detected by EUS	2 (4%)	
EUS findings and description		
Head mass	24 (48%)	
Body mass	6 (12%)	
Chronic pancreatitis	4 (8%)	
Body mass vs WOPN	1 (2%)	
Microcystic cystadenoma	1 (2%)	
Adenocarcinoma vs chronic pancreatitis	4 (8%)	
Body mass vs SPPN	1 (2%)	
Head mass vs SPPN	1 (2%)	
Head mass vs pancreatitis	1 (2%)	
Histopathology		
Adenocarcinoma	35 (70%)	
Autoimmune pancreatitis	3 (6%)	
Chronic pancreatitis	4 (8%)	
NET	3 (6%)	
SPPN	3 (6%)	
IPMN	1 (2%)	
Microcystic cystadenoma vs SPPN	1 (2%)	
SH Elastography		
Mean ± SD	42.7 ± 22.54	
Range	11 - 99	
Median (IQR)	39.5 (25.25 - 54.25)	

EUS: endoscopic ultrasound, SPNN: solid pseudopapillary neoplasm, IPMN: intraductal papillary mucinous neoplasm, NET: neuroendocrine tumor, WOPN: walled-off pancreatic necrosis. SPNN: solid pseudopapillary neoplasm, IPMN: intraductal papillary mucinous neoplasm, NET: neuroendocrine tumor. IQR: interquartile range, CA 19-9: cancer antigen 19-9, ALT: alanine transaminase, AST: aspartate transaminase

Table 3: Diagnostic accuracy of different markers for prediction of malignant tumors in all the studied patients

	Cut off	Sensitivity	95% CI	Specificity	95% CI	PPV	NPV	AUC	P value
SH Elastography	≤56	94.29	80.8-99.3	60.00	32.3-83.7	84.6	81.8	0.914	<0.001*
CA 19-9 (U/mL)	>40	97.14	85.1 - 99.9	93.33	68.1 - 99.8	97.1	93.3	0.927	<0.001*

CA 19-9: cancer antigen 19-9, CI: confidence interval, PPV: positive predictive value, NPV: negative predictive value, AUC: area under the curve, *: statistically significant as P value<0.05.

Table 4: Characteristics, chronic diseases, complaints and clinical signs of the studied groups regarding the tumor type.

		Malignant (n=35)	Benign (n=15)	P value
Age (years)		61.1 ± 9.36	47.9 ± 12.19	<0.001*
Gender	Male	21(42%)	10(20%)	0.218
	Female	14(28%)	5(10%)	
Special habits	No abnormality	27 (77.14%)	12 (80%)	0.244
	Smoker	8 (22.86%)	2 (13.33%)	
	Alcoholic	0 (0%)	1 (6.67%)	
Chronic diseases	DM	5 (14.29%)	0 (0%)	0.184
	HTN	5 (14.29%)	2 (13.33%)	
	DM & HTN	3 (8.57%)	0 (0%)	
	IHD & HTN	1 (2.86%)	0 (0%)	
	Rheumatoid arthritis	0 (0%)	1 (6.67%)	
	Hypothyroidism	0 (0%)	1 (6.67%)	
	No abnormality	21 (60%)	11 (73.33%)	
Clinical presentation	Jaundice	16 (45.71%)	0 (0%)	0.001*
	Abdominal tenderness	12 (34.29%)	14 (93.33%)	0.465
	Cachexia	5 (14.29%)	1 (6.67%)	0.001*
	Hepatomegaly	2 (5.71%)	0 (0%)	0.458

DM: diabetes mellitus, HTN: hypertension, IHD: ischemic heart disease. *: statistically significant as P value <0.05

Table 3: Laboratory investigations, radiological findings, EUS diagnosis and SH Elastography of the studied groups regarding the tumor type

		Malignant (n=35)	Benign (n=15)	P value
Laboratory investigations				
ALT (U/L)	Mean ± SD	114.4 ± 90.47	88.7 ± 79.98	0.346
	Range	21 - 393	21 - 356	
	Median (IQR)	83 (57 - 142.5)	82 (41 - 98.5)	
AST (U/L)	Mean ± SD	89.9 ± 72.69	63.8 ± 53.77	0.218
	Range	14 - 265	23 - 238	
	Median (IQR)	67 (43.5 - 100.5)	41 (36.5 - 77.5)	
Bilirubin (mg/dL)	Mean ± SD	3.1 ± 2.22	1.2 ± 0.37	0.002*
	Range	1 - 8	0.9 - 2	
	Median (IQR)	2.7 (1 - 4.6)	1 (1 - 1.4)	
Amylase (U/L)	Mean ± SD	54.2 ± 30.04	122.9 ± 115.8	0.002*
	Range	24 - 194	31 - 420	
	Median (IQR)	46 (37 - 65.5)	65 (40.5 - 172.5)	
Lipase (U/L)	Mean ± SD	49.4 ± 17.78	111.6 ± 108.38	0.002
	Range	23 - 100	28 - 380	
	Median (IQR)	42 (37 - 60.5)	69 (37.5 - 118)	
CA 19-9 (U/mL)	Mean ± SD	160.8 ± 207.99	38.5 ± 17.7	<0.001*
	Range	15 - 952	24 - 100	
	Median (IQR)	88 (68 - 113)	37 (31 - 38.5)	
Radiological findings				
Detected by CT		4 (11.43%)	9 (25.71%)	0.003*
Detected by MRI		26 (74.29%)	3 (8.57%)	0.003
Detected by ultrasound		3 (8.57%)	2 (5.71%)	0.003
Detected by PET/CT		1 (2.86%)	0 (0%)	0.003
Detected by EUS		1 (2.86%)	1 (2.86%)	0.561
SH Elastography				
Mean ± SD		32.5 ± 13.6	66.7 ± 21.16	<0.001*
Range		11 - 59	35 - 99	

IQR: interquartile range, CA 19-9: cancer antigen 19-9, ALT: alanine transaminase, AST: aspartate transaminase, CT: computed tomography, MRI: magnetic resonance imaging, MRCP: magnetic resonance cholangiopancreatography, PET/CT: positron emission tomography/ computerized tomography. EUS: endoscopic ultrasound, SPNN: solid pseudopapillary neoplasm, IPMN: intraductal papillary mucinous neoplasm, NET: neuroendocrine tumor, WOPN: walled-off pancreatic necrosis *: statistically significant as P value<0.05

Table 4: Detected mass data of the studied groups regarding the tumor type

		Malignant (n=35)	Benign (n=15)	P value
Detected mass data				
Mass length	Mean ± SD	32.3 ± 14.2	31.2 ± 17.41	0.809
	Range	15 - 63	15 - 60	
Mass width	Mean ± SD	40.4 ± 18.12	35.6 ± 20.21	0.408
	Range	14 - 83	14 - 65	
Mass location				
Head		15 (42.86%)	4 (26.67%)	0.083
Body		4 (11.43%)	1 (6.67%)	0.049
Head and uncinata		6 (17.14%)	0 (0%)	0.092
Body and tail		3 (8.57%)	1 (6.67%)	0.482
Head, body, and tail		1 (2.86%)	3 (20%)	0.406
Tail		1 (2.86%)	0 (0%)	0.582
Swollen pancreatic head		2 (5.71%)	2 (13.33%)	0.885
Neck		0 (0%)	2 (13.33%)	0.753
Uncinate		1 (2.86%)	0 (0%)	0.764
Neck and body		1 (2.86%)	0 (0%)	0.729
Head and body vs SPPN		0 (0%)	1 (6.67%)	0.845
Focal pancreatitis vs mass		1 (2.86%)	0 (0%)	0.648
Neck and body SPPN		0 (0%)	1 (6.67%)	0.652

SPPN: solid pseudopapillary neoplasm. *: statistically significant as P value<0.05

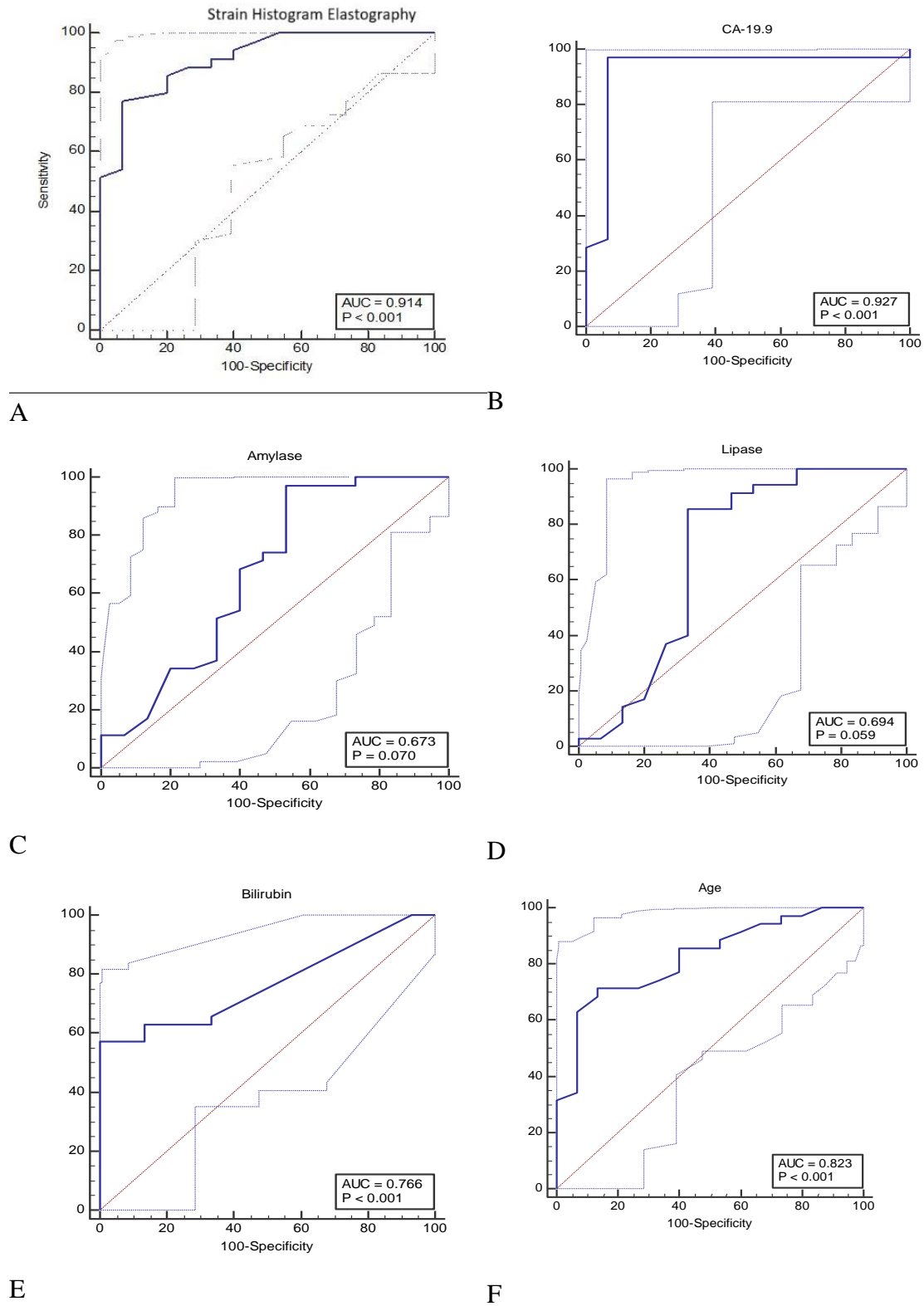


Figure 1: ROC curve analysis of (A) SH Elastography, (B) CA19-9, (C) Amylase, (D) Lipase, (E) Bilirubin, (F) Age for prediction of malignant tumors in all the studied patients.

Discussion

Pancreatic cancer is the seventh leading cause of cancer related death worldwide, EUS plays an important diagnosing role and for staging of pancreatic cancer. EUS and EUS-guided fine-needle aspiration (EUS-FNA) are currently considered procedures of choice for the differential diagnosis of focal pancreatic masses. Although the accuracy is excellent, with sensitivity higher than 80%–85% and specificity close to 100%, there are still false-negative results, especially for the patients with underlying chronic pancreatitis, with sensitivity values that might drop below 75%. As minimally invasive procedure, elastography increase the accuracy of diagnosing solid pancreatic lesion in the form of qualitative and quantitative (strain ratio and SH) methods by measuring tissue stiffness, thus differentiate malignant and benign solid focal lesions.

In this study we focused on SH, to analyze the SH, the color image of the elastography is converted into the gray scale (value) of 256 tones.

It ranged from 0 to 255 with 0 representing the blue area (hard) and 255 representing the red area (soft). The distribution of the gray scale is then calculated into various parameters including (mean, standard deviation, skewness, and kurtosis, etc.). The correlations of these parameters with the degree of pancreatic fibrosis with increasing fibrosis, the mean and standard deviation decrease, while skewness and kurtosis increase (9).

In some reports (10), the histograms were performed separately from the individual red/green/blue color as the researchers evaluated the usefulness of SH elastography in differentiating malignant pancreatic masses from normal pancreas and found a very promising result with 100% sensitivity and 100% specificity for malignancy detection.

However, a limitation of this study was the selection of the control group, since the authors used normal pancreas as control group compared with the group with malignant pancreatic diseases but did not use patients with pancreatic masses or chronic pancreatitis as control group.

In a similar published study about SH in differentiating pancreatic masses (7), the results based on a cut off value for SH elastography was 51, accuracy was 69%, sensitivity 93 and specificity 45%, SH elastography variable is close to the cut off value in our study which is 56 with accuracy 66%, sensitivity 94 and specificity 60%, we conclude that SH elastography is highly sensitive with moderate specificity.

In three published studies (11, 12, and 13) where data analysis was done in an extended neural network analysis with automatic differentiation of benign from malignant lesions, based on a cut-off of 175 sensitivity reached 91.4%, 84.8% and 93.4%, the specificity was 87.9%, 76.2% and 66.0%, with overall accuracy of 89.7%, 81.5% and 85.4%.

Our investigation represents quantitative elastography analysis with SH of pancreatic masses using commercially available integrated ultrasound machine software.

This software also uses a scale from 0 to 255, but the scale is reversed with 0 representing the hardest tissue structure and 255 the softest. It is possible to compare the cut-off value from the previous studies with the cut-off value computed in our study, expressed in the same way, the mean value from the previous studies becomes 80, which is close to 56.

In a large multicentric prospective study including 258 patients, a study, (12) used SH accompanied with contrast enhanced endoscopic ultrasound trying to make a diagnostic algorithm in focal pancreatic masses with negative cytopathology after EUS-FNA. It was a retrospective study including 50 consecutive patients with focal pancreatic masses which underwent EUS examinations with negative EUS-FNA. RTE-EUS and CEH-EUS were performed sequentially in all patients. The sensitivity, specificity and accuracy of these methods were calculated separately.

Regarding SH it was calculated in the same way done by the previous mentioned studies done where the cut off value was 175 which corresponds to 80 on the reversed scale from 0-255 (13). For the diagnosis of possible malignancy, the sensitivity, specificity and accuracy of SH were: 97.7%, 77.4%, and 84% respectively, these

results were nearly similar to contrast enhanced endoscopic ultrasound which were: 89.5%, 80.7%, and 84%, respectively.

While in 25 cases with chronic pancreatitis the specificity of contrast enhanced endoscopic ultrasound was raised to 100%, finally it was concluded that the proposed algorithm with sequential use of elastography followed by CEH-EUS could be a good clinical tool in the set of patients with negative EUS-FNA results for the differentiation between benign and malignant focal pancreatic masses.

A study about SH and combined contrast-enhanced power doppler, was done on 54 patients where 21 with chronic pancreatitis and 33 with pancreatic adenocarcinoma. The patients were classified as having hypovascular or hypervascular focal masses as well as mixed or hard focal pancreatic masses. Combined analysis of both CEPD and RTSE assumed that the patients with pancreatic cancer had hypo vascular hard focal masses (contrast-enhanced PDVI 20% and mean elastography hue histogram 175). Consequently, the sensitivity, specificity and accuracy were 75.8%, 95.2% and 83.3%, respectively (14).

The sensitivity, specificity and accuracy for EUS-FNA were 87.9%, 100%, 92%, respectively, also, it was specified that 4 patients with pancreatic head mass larger 3cm were false negative EUS-FNA cytology, but they were hypovascular by CEPD and high values of the average hue histogram (>175) (14). All the 4

patients were suggested to have pancreatic adenocarcinoma despite negative EUS-FNA cytology results. It was concluded that combined CEPD with SH is a promising method toward differentiating focal pancreatic masses.

In a prospective single center study on 62 patients with solid pancreatic lesions done in 2017 (15), calculating the diagnostic accuracy of CEH-EUS, QE-EUS and their combination. Final diagnosis was 45 patients with pancreatic adenocarcinoma, 3 patients with neuroendocrine tumor, 10 patients with inflammatory mass, 2 patients with pancreatic metastasis, 1 patient with autoimmune pancreatitis, and 1 patient with mucinous cystadenocarcinoma.

Overall accuracies for determination of malignancy using QE-EUS, CEH-EUS, their combination and EUS-FNA were 98.4% (95% confidence interval (CI): 91.4–99.7), 85.5% (95% CI: 74.7–92.2), 91.9% (95% CI: 82.5–96.5), and 91.5% (95% CI: 83.6–99.5), respectively (15).

However, A strain ratio >10 and a mean SH value <50 were identified as optimal cutoff values for classification of malignant lesions. He also stated that there was a case of autoimmune pancreatitis with a strain ratio of 43.2, SH of 22.7. Finally, He concluded that the combination of QE-EUS and CEH-EUS is a useful tool for the differential diagnosis of SPT. However, this combination does not significantly increase the diagnostic accuracy of either of the techniques performed alone.

Conclusion

Strain histogram elastography shows high sensitivity in detection of pancreatic malignant tumors but moderate specificity. Minimal improvements in specificity and accuracy were achieved using the SH ratio. EUS SH is a very useful indicator in differentiating of solid pancreatic lesions as well as it can be used as a guide to repeat FNA when first EUS-FNA is not conclusive and elastography appear to be blue denoting hard consistency suggesting pancreatic adenocarcinoma.

References

1. Granata V, Grassi R, Fusco R, Setola SV, Palaia R, Belli A, et al. Assessment of ablation therapy in pancreatic cancer: the radiologist's challenge. *Frontiers in Oncology*. 2020;10:560952.
2. Facciorusso A, Gkolfakis P, Tziatzios G, Ramai D, Papanikolaou IS, Triantafyllou K, et al. Comparison between EUS-guided fine-needle biopsy with or without rapid on-site evaluation for tissue sampling of solid pancreatic lesions: A systematic review and meta-analysis. *Endoscopic ultrasound*. 2022;11:458-65.
3. Paulis G, De Giorgio G, Paulis A. Ultrasound Elastography as a Diagnostic Tool for Peyronie's Disease: A State-of-the-Art Review. *Diagnostics*. 2024;14:665.
4. Iglesias-Garcia J, de la Iglesia-Garcia D, Lariño-Noia J, Dominguez-Muñoz JE. Endoscopic Ultrasound (EUS) Guided Elastography. *Diagnostics (Basel)*. 2023;13.
5. Okasha HH, Delsa H, Alsawaf A, Hashim AM, Khattab HM, Abdelfatah D, et al. Role of endoscopic ultrasound and endoscopic ultrasound-guided tissue acquisition in diagnosing hepatic focal

- lesions. *World J Methodol.* 2023;13:287-95.
6. Kamat R, Gupta P, Rana S. Imaging in chronic pancreatitis: State of the art review. *Indian J Radiol Imaging.* 2019;29:201-10.
 7. Opačić D, Rustemović N, Kalauz M, Markoš P, Ostojić Z, Majerović M, et al. Endoscopic ultrasound elastography strain histograms in the evaluation of patients with pancreatic masses. *World J Gastroenterol.* 2015;21:4014-9.
 8. Watanabe S, Miyoshi J, Toki M, Kambayashi K, Kitada S, Nosaka T, et al. Effectiveness of introducing a 20-gauge core biopsy needle with a core trap in EUS-FNA/B for diagnosing pancreatic cancer. *BMC Gastroenterol.* 2021;21:8.
 9. Itoh A, Ueno E, Tohno E, Kamma H, Takahashi H, Shiina T, et al. Breast disease: clinical application of US elastography for diagnosis. *Radiology.* 2006;239:341-50.
 10. Schrader H, Wiese M, Ellrichmann M, Belyaev O, Uhl W, Tannapfel A, et al. Diagnostic value of quantitative EUS elastography for malignant pancreatic tumors: relationship with pancreatic fibrosis. *Ultraschall Med.* 2012;33:E196-e201.
 11. Săftoiu A, Vilmann P, Gorunescu F, Gheonea DI, Gorunescu M, Ciurea T, et al. Neural network analysis of dynamic sequences of EUS elastography used for the differential diagnosis of chronic pancreatitis and pancreatic cancer. *Gastrointest Endosc.* 2008;68:1086-94.
 12. Săftoiu A, Iordache S, Gheonea DI, Popescu C, Maloș A, Gorunescu F, et al. Combined contrast-enhanced power Doppler and real-time sonoelastography performed during EUS, used in the differential diagnosis of focal pancreatic masses (with videos). *Gastrointestinal Endoscopy.* 2010;72:739-47.
 13. Săftoiu A, Vilmann P. Role of endoscopic ultrasound in the diagnosis and staging of pancreatic cancer. *J Clin Ultrasound.* 2009;37:1-17.
 14. Săftoiu A, Vilmann P, Hassan H, Gorunescu F. Analysis of endoscopic ultrasound elastography used for characterisation and differentiation of benign and malignant lymph nodes. *Ultraschall Med.* 2006;27:535-42.
 15. Iglesias-Garcia J, Lindkvist B, Lariño-Noia J, Abdulkader-Nallib I, Dominguez-Muñoz JE. Differential diagnosis of solid pancreatic masses: contrast-enhanced harmonic (CEH-EUS), quantitative-elastography (QE-EUS), or both? *United European Gastroenterol J.* 2017;5:236-46.

To cite this article: Hany R. ElKholi, Hossam A. Bayoumi, Hussein H. Okasha, Ahmed F. Alzohery. Role of Strain Histogram Elastography using Endoscopic Ultrasound for Differentiating Malignant from Benign Pancreatic Masses. *BMFJ* 2024;41(5):337-351.