

# EVALUATION OF ATRAUMATIC AXIAL TOOTH EXTRACTION USING BENEX SYSTEM IN IMMEDIATE IMPLANT IN MAXILLARY ANTERIOR TEETH. (PROSPECTIVE CLINICAL TRIAL)

Germiné I. Mabrouk<sup>1\*</sup> BDS, Magued H. Fahmy<sup>2</sup> PhD,  
Adham A. El-Ashwah<sup>3</sup> PhD, Yehia A. El-mahallawy<sup>4</sup> PhD

## ABSTRACT

**OBJECTIVE:** The aim of this study was to assess the practicability and clinical results of an atraumatic extraction method for maxillary anterior teeth using the Benex extraction system with immediate implant placement.

**MATERIALS AND METHODS:** Twelve dental implants placed immediately in ten adult patients having maxillary anterior tooth or remaining root indicated for extraction. All patients were operated under local anesthesia, with atraumatic extraction using Benex extraction system followed by immediate implant placement. Clinical and radiographic evaluation was performed and implant stability assessment was performed using radiofrequency analysis.

**RESULTS:** Twelve extractions were conducted successfully and followed by immediate implants placement in ten patients. None of the placed implants showed any complications in the clinical follow up period. Final prosthetic placement was conducted after 6 months with a mean reported pink esthetic score of  $10.50 \pm 0.80$ , and implant stability analysis reported an increase in the achieved Implant stability quotient by  $8.83 \pm 5.25$ . Radiographic analysis of the crestal alveolar bone width reported a mean decreased in crestal bone width by  $0.25 \pm 0.15$  mm. The labial plate thickness analysis reported an increase in the bone thickness at the apical and middle levels, while a statistically insignificant decrease was reported at the coronal level.

**CONCLUSION:** Axial tooth extraction technique using Benex extraction system is a practicable modality with a favorable execution without socket expansion or jeopardizing remaining wall integrity. This minimally invasive extraction modality allowed for immediate implant placement with favorable clinical and radiographic outcomes.

**KEYWORDS:** benex system, tooth extraction, immediate implant, bone healing.

**RUNNING TITLE:** Benex extraction system for immediate implant placement in maxillary anterior.

1 BDS, 2014, Faculty of Dentistry, Pharos University, Alexandria, Egypt

2 Professor of Oral and Maxillofacial Surgery, Faculty of Dentistry, Alexandria University, Alexandria, Egypt

3 Professor & Head of Oral and Maxillofacial Surgery Department, Faculty of Dentistry, Alexandria University, Alexandria, Egypt

4 Lecturer of Oral and Maxillofacial Surgery, Faculty of Dentistry, Alexandria University, Alexandria, Egypt

\* Corresponding Author:

E-mail: [Germinemabrouk@gmail.com](mailto:Germinemabrouk@gmail.com)

## INTRODUCTION

Extraction is a common dental procedure, and a patient may experience pain postoperatively, with varying degrees of severity. This variance is a consequence of the degree of trauma sustained during the procedure (1).

Consequently, lessening the severity of trauma is required to maintain the characteristics of the hard and soft tissues surrounding the tooth being removed, which influences treatment, prognosis, and outcome (2).

Among the most discussed subjects in dentistry research is post extraction healing of the socket. Healing is the process by which the body repairs injured tissue. Any interruption in this normal inflammatory-mediated processes can be regarded as postoperative complications (3-5). A blood clot quickly forms in the socket following a non-

surgical tooth extraction, usually within two to seven days, which is then completely filled by granulation tissue growth. Also, Epithelialization begins within 24 hours and lasts 1-5 weeks (6).

The normal closed exodontia process consists of socket expansion with severe traumatic event for the alveolar process and risk of fracture and consequent loss of the remaining socket walls. This is a common finding in the maxillary incisors, where socket preservation procedures is usually mandated (7).

Several atraumatic tooth extraction methods are available in the literature, among which is the atraumatic axial tooth extraction. The Benex extraction system introduced by Benno Syfrig in 2003, is a method for gently extracting teeth longitudinal, providing both excellent bone preservation and special tissue protection (8, 9).

By extracting the tooth axially from its socket, the Benex extraction technique makes it possible to remove teeth without unnecessarily expanding the socket. This eliminates the need for flap surgery and offers a less invasive extraction while conserving as much soft tissue as possible in addition to bone (8, 9). Numerous factors contribute to atraumatic extraction perceived benefits. It retains the structure of the soft and hard tissues, shortens the period of therapy, and improves the aesthetics (10-13).

In contemporary dentistry, one of the main objectives of implant-prosthetic treatment is functional and cosmetic rehabilitation, and there is an increasing need for quick and less invasive implant operations. Patients can receive the intended short treatment durations through the creation of clinical procedures for Implant loading and insertion early or immediately (14). However, extracting teeth and managing the alveolae that remain after extraction are the initial steps in the conversion of a hopeless tooth to an implant-supported replacement (14). Modern dentistry is shifting towards socket regeneration and prevention in light of the harm that results from tooth extractions as well as their possible consequences (15).

The literature has little information about the healing process following the use of an axial tooth extraction technique. Thus, the purpose of this study is to appraise the employment of the Benex extraction system in the exodontia of maxillary anterior teeth and assessing its impact on hard and soft tissue following the extraction and immediately inserting dental implants into newly created sockets reduces the duration of treatment and provides certain functional and cosmetic benefits. The null hypothesis of the current study is that the utilization of the atraumatic extraction by Benex system followed by immediate implant placement may not provide better clinical and radiographic outcomes of the soft and hard tissues of the maxillary anterior teeth.

## PATIENTS AND METHODS

### Study design

The study was a prospective clinical trial. The study is a single arm clinical trial following the CONSORT guidelines. The study was conducted following ethical approval from the local institutional committee board (IRB number: 0597-01/2023). The declaration of Helsinki guidelines were thoroughly followed during the conduction of this study, and all of the enrolled patients signed a detailed informed consent before embarking in this study. The sample size was calculated based on Shu-xin et al. (2016) (16) to detect a standardized effect size in bone width using GPower version 3.1.9.2 and found to be estimated number of 10 patients with drop off value.

Patients were selected from those admitted to the Alexandria University Faculty of Dentistry clinics,

and the procedure was performed in the oral and maxillofacial surgery clinics, Faculty of Dentistry, Alexandria University. Adult patients of no gender predilection with a non-restorable maxillary anterior tooth with a type I extraction socket after radiographic assessment was enrolled in this study. As immediate implant was planned, those with osteointegration compromising conditions were excluded from this study.

### Preoperative assessment

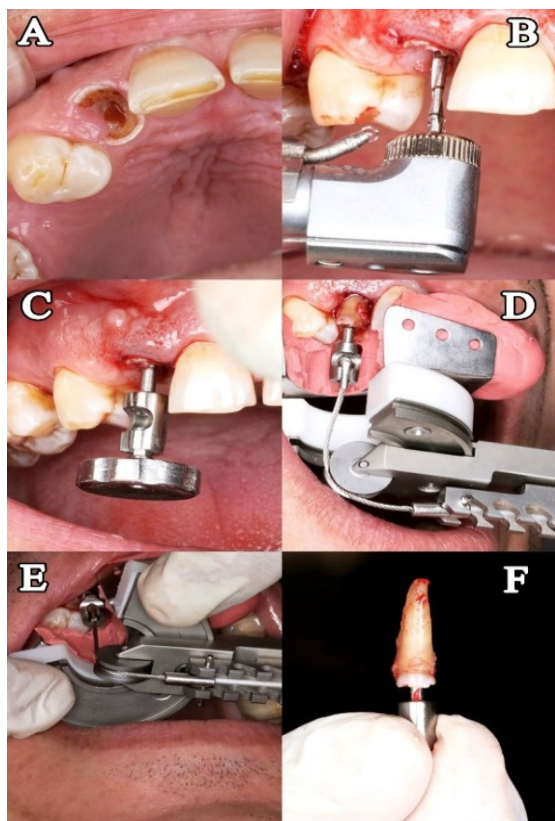
All of the personal history, past medical and dental history, general examination, and chief complains were recorded, along with analysis of parafunctional habits and a thorough intraoral examination. Radiographic examination was conducted using a Cone Beam Computer Tomography (CBCT) for assessment of socket type and implant size (Vatech, Green X, Korea).

### Clinical procedure

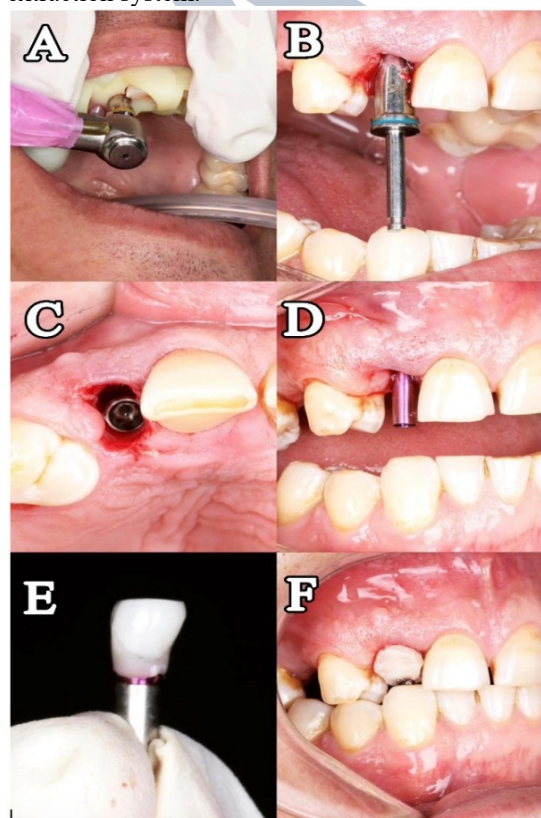
Patients were operated under local anesthesia with 4% Articaine hydrochloride diluted 1:100000 (Septodont, Saint-Maur-des-Fosse's, France.). The Benex extraction system was used for Atraumatic axial tooth Extraction in all of the cases (Benex<sup>®</sup>, Luzem, Switzerland.). Periotome was used to cut the coronal portion of the sharpey's fibers for at least 2 mm of supragingival tissue (Nordent, EIK Grove village, IL, US). The diamond-coated twist drill was used to drill the tooth at the centre of the root for a minimal depth of 7 mm. The driver guide was used to insert the extraction screw in the prepared screw channel with the determined diameter. After the screw has been put in, the quadrant support disc with the putty material was placed on nearby crowns and the traction rope was positioned above the roller and secured to the extraction side's notch after being inserted into the extraction screw. The hand screw of the Benex device was turned in clockwise direction to complete the extraction in a longitudinal direction (Figure 1). Socket debridement was performed followed by sequential implant osteotomy preparation according the pre-planned width and implant was torqued immediately into the fresh socket of the recently extracted tooth (Vitronex-V-line, Milano, Italy) (Figure 2).

After implant insertion, assessment of the primary integration was performed using radiofrequency analysis with the Osstell ISQ instrument (Integration diagnostic Ltd. Company, Sävedalen, Sweden). This was followed by the creation of a customized temporalization for the maintenance of the extraction socket. An emergence profile was created using the light-cured composite underneath the provisional temporary restoration. This was followed by contouring and polishing. To minimize pressure on the site of surgery the provisional restoration was kept out of occlusion. Regular postoperative and oral hygiene instructions were

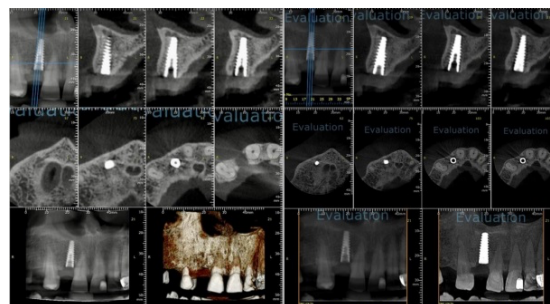given to the patients along with antibiotic course for 5 days (Amoxicillin 875 mg+ Clavulanic acid 125 mg:GlaxoSmithKline, UK).



**Figure (1):** Atraumatic extraction with Benex extraction system.



**Figure (2):** Immediate implant placement.



**Figure (3):** CBCT immediate after implant placement & 6 months postoperative.

#### Prosthetic Phase

After 6 months from the implant placement, patients were prepared for final restoration insertion. This was performed after secondary stability analysis using Osstell ISQ instrument.

#### Clinical Follow-Up Assessment (17, 18)

All patients were recalled for a clinical follow-up period at 7, 14, and 21 days postoperative. A final assessment was done after 6 months at the time of final restoration insertion. Clinical assessment comprised of postoperative pain analysis using Visual Analogue Scale (VAS), and wound healing assessment where the implant site was checked for pain, swelling, discomfort, redness, warmth, pus discharge, and any other infection-related signs and symptoms.

After final prosthesis insertion by 1 month, the esthetic outcome of soft tissue around the inserted implant-supported single crowns in the anterior zone was assessed by the pink esthetic score (PES) was introduced by Furhauser et al (19). The PES comprises of seven factors each is assigned a score. Curvature of the facial mucosa, level of the facial mucosa, mesial papilla, distal papilla, root convexity, soft tissue color, and texture are all assessed and given a score of 2, 1, or 0, and a total score is aggregated to a range from 0 to 14.

The implant stability quotient was measured during the operative stage, and the secondary stability quotient was measured 6 months post-operative for loading of implant prosthesis. ISQ values between 55-80 are optimal for implant success, ISQ values greater than 54 are regarded as appropriate for loading early (20).

#### Radiographic Assessment

Radiographic assessment in this study was conducted using a 6 months postoperative Cone Beam Computed Tomography (CBCT) and comparing the values with the preoperative record. The assessment was conducted using the tools on the "On Demand 3D App." Software. The width of the crestal alveolar process was assessed by determining the Bucco-palatal ridge dimensions changes in the 6 months' CBCT scan when compared to the preoperative one (21). Furthermore, the overall survival of the labial plate of bone after the atraumatic exodontia procedure



and immediate implant placement was evaluated by the assessment of the labial plate of bone thickness in the 6 months' scan and comparing it with the preoperative CBCT record. The distance was measured from the root surface to the outer buccal bone surface in the preoperative CBCT record. Measurements was conducted on the cross-sectional CBCT cut at three levels; crestal labial thickness, middle labial thickness, and apical labial thickness. The same measurements were assessed on the 6 months' CBCT scan taking the measurements from the outer surface of the implant to the outer surface of the remaining labial plate. Difference between the 6 months' implant reading and the preoperative root measurements was calculated for each patient and analyzed (22).

**Statistical analysis**

All of the obtained data were fed to the computer and analyzed using IBM Statistical Package for Social Science (SPSS) software version 20.0 (Armonk, NY: IBM Corp). The Shapiro-Wilk test was used to verify the normality of distribution. Paired t-test was utilized for normally distributed quantitative variables, while the Wilcoxon signed ranks test was utilized for abnormally distributed quantitative variables. Friedman test was utilized for abnormally distributed quantitative variables. Significance of the obtained results was judged at the 5% level.

**RESULTS**

A total of ten patients, seven females and three males, with ages ranging from 29 to 47 years old and a mean age of  $38.10 \pm 5.80$  years, participated in the current study. The ten patients were presented by twelve maxillary anterior tooth indicated for extraction and replaced immediately with implants. In all of the twelve extractions, the Benex system was effective in axial tooth exodontia atraumatically and in a longitudinal direction, which was followed by Immediate implant placement and provisionalization.

Clinical assessment of postoperative pain reported that all patients experienced a full resolution of the little discomfort that had persisted during the first few postoperative days. The change in the perceived postoperative pain across the follow-up period was statistically significant ( $P < 0.001^*$ ). Regarding the wound healing, none of the ten patients or the 12 implants site reported any signs of infection. Wound healing at the extraction and immediate implant placement sites was uneventful. The pink aesthetic score (PES) assessment of the soft tissue around single implant restorations reported a mean value of  $10.50 \pm 0.80$ , with a range from 8.0 to of 12.0.

Regarding the implant stability analysis, the mean reported ISQ value at implant placement setting was  $73.25 \pm 3.60$ , with a range from 69.0 to 79.0. During final restoration fabrication after 6 months,

the mean reported ISQ value was  $82.08 \pm 3.99$ , with a range from 76.0 to 88.0. The difference between the two measurements reported a statistically significant increase with a mean value of  $8.83 \pm 5.25$ , ( $P < 0.001$ ) (Table 1).

Radiographic analysis was conducted for the evaluation of crestal bone width and labial bone thickness. Prior to surgery, the coronal crestal bone width had a mean value of  $6.77 \pm 0.93$  mm,. On other hand, the mean reported crestal bone width in the 6 postoperative months' records was  $6.52 \pm 0.83$ . the change in the 6 months' crestal bone width was statistically significant with a mean value of  $0.25 \pm 0.15$  mm ( $P < 0.001$ ) (Table2).

Labial bone thickness analysis at the apical aspect of the implant reported a statistically insignificant increase in the 6 months' scan, with a mean value of  $0.02 \pm 0.09$  mm ( $P = 0.455$ ). At the middle labial plate level, the reported mean value was  $0.40 \pm 0.30$  mm, with a statistically significant increase in the 6 months' scan ( $P = 0.005^*$ ). The coronal bone thickness reported a statistically insignificant decrease in the 6 months' scan, with a mean value of  $0.19 \pm 0.43$  mm ( $P = 0.161$ ) (Table 3) (Figure 3).

**Table 1:** Implant Stability Quotient (ISQ) comparison between the primary measured and 6 months' postoperative measurement at final prosthesis insertion

| ISQ            | Baseline     | 6months'     | t      | p       |
|----------------|--------------|--------------|--------|---------|
| Min. – Max.    | 69.0 – 79.0  | 76.0 – 88.0  | 5.824* | <0.001* |
| Mean ± SD.     | 73.25 ± 3.60 | 82.08 ± 3.99 |        |         |
| Difference (+) | 8.83 ± 5.25  |              |        |         |

IQR: Inter quartile range SD: Standard deviation  
 t: Paired t-test  
 p: p value for comparing between the studied groups  
 \*: Statistically significant at  $p \leq 0.05$

**Table 2:** Crestal bone width comparison between the preoperative and 6 months' postoperative radiographic records (n = 12).

| Crestal bone width | 'reoperative | 6months     | t      | p       |
|--------------------|--------------|-------------|--------|---------|
| Min. – Max.        | 5.24 – 8.25  | 5.23 – 7.77 | 5.585* | <0.001* |
| Mean ± SD.         | 6.77 ± 0.93  | 6.52 ± 0.83 |        |         |
| Difference (-)     | 0.25 ± 0.15  |             |        |         |

IQR: Inter quartile range  
 SD: Standard deviation  
 t: Paired t-test  
 p: p value for comparing between the studied groups  
 \*: Statistically significant at  $p \leq 0.05$

**Table 3:** Labial bone thickness comparison between the preoperative and 6 months' postoperative radiographic records (n = 12).

| Labial Bone Thickness | Preoperative | 6months'    | Test     | p      |
|-----------------------|--------------|-------------|----------|--------|
| <b>Apical</b>         |              |             |          |        |
| Min. – Max.           | 0.56 – 3.82  | 0.66 – 3.70 |          |        |
| Mean ± SD.            | 1.19 ± 0.86  | 1.22 ± 0.83 | Z= 0.747 | 0.455  |
| Difference (+)        | 0.02 ± 0.09  |             |          |        |
| <b>Middle</b>         |              |             |          |        |
| Min. – Max.           | 0.45 – 2.70  | 0.67 – 2.46 |          |        |
| Mean ± SD.            | 1.22 ± 0.70  | 1.62 ± 0.58 | Z= 2.824 | 0.005* |
| Difference (+)        | 0.40 ± 0.30  |             |          |        |
| <b>Coronal</b>        |              |             |          |        |
| Min. – Max.           | 0.60 – 1.34  | 0.70 – 2.06 |          |        |
| Mean ± SD.            | 1.19 ± 0.46  | 1.01 ± 0.24 | t= 1.503 | 0.161  |
| Difference (-)        | 0.19 ± 0.43  |             |          |        |

IQR: Inter quartile range      SD: Standard deviation

t: Paired t-test      Z: Wilcoxon signed ranks test

p: p value for comparing between the studied groups

\*: Statistically significant at  $p \leq 0.05$

## DISCUSSION

Axial tooth extraction is a method that aims to minimize trauma to both hard and soft tissues during tooth extraction. This method has several advantages in implant dentistry, such as preserving the gingival tissues, minimizing the risk of loss of bone, and reducing the risk of implant failure. The preservation of these tissues can help to ensure that the implant is positioned in an optimal prosthetic location and that there is sufficient quantity and quality of bone to support the implant (4).

Immediate provisionalization has been suggested as an option to preserve tissue volume and shape, reduce treatment costs and duration, and achieve effective treatment of atraumatic extraction (23). The present study is designed to assess the feasibility and suitability of the Benex extraction system in atraumatic extraction for the placement of immediate implant in maxillary anterior teeth. The study was conducted on ten patients that requires twelve extractions of maxillary anterior teeth and immediate implant placement

The individuals who were chosen did not have any uncontrolled systemic illnesses or disorders that may affect the implant's healing process during surgery. Bornstein et al. in 2009 (24) performed a study, where They examined the possibility that systemic illnesses, whether treated or not, might raise the likelihood of implant failure and, consequently, lower the success and survival rates of dental implants. Additionally, people who smoke heavily were not included in this study. This was in

response to a study conducted in 2014 by Gomez de Diego et al., (25) who concluded that smokers have a higher risk of dental implant loss after reviewing the most recent scientific literature to assess the applications and limitations of dental implants in individuals with impaired health.

In order to determine the postoperative healing signs and symptoms as well as the impact on bone width and density, this study aims to test the feasibility and usefulness of an atraumatic extraction approach employing the Benex extraction system in immediate implant placement in maxillary front teeth. Less applied trauma is required to protect the hard and soft tissue characteristics surrounding the tooth being removed, since This affects the prognosis, outcomes, and planning of the treatment (1).

This study opted for immediate implant placement because when a tooth is extracted, the surrounding bone lacks stimulation, which can lead to bone loss. By placing an implant directly after extraction, the patient will most likely have adequate bone mass to support a dental implant. This can help preserve gum tissue, bone, and reduce pain (14).

Conventional extraction techniques have a history of harming the surrounding hard and soft tissues in addition to causing postoperative pain (26). Traditional extraction methods such as the use of elevators, which causes interproximal bone loss, or forceps, which releases the tooth from its socket and frequently causes socket expansion and bone loss (27).

Because of the hard tissue injury, this makes it difficult to preserve the integrity of the socket. and that is make the future prosthetic replacement very difficult. That is why we use in our study an atraumatic extraction by Benex extraction system trying to preserve soft and hard tissue for easy replacement of future prosthetic after the implant placement (16).

Bortoluzzi et al. in 2012, Sjögren et al. in 2010, and Al Khateeb in 2008 ,they conducted in their study that the pain after extraction is the most common complication (1, 28, 29). To avoid the postoperative pain after exodontia, and in order to maintain gingival architecture, bone, and the ability to install implants right away, we must proceed with an atraumatic extraction procedure. The linked hard and soft tissue around the tooth must be preserved with the least amount of stress during a hopeless tooth extraction. This has a major influence on treatment planning, results, and prognosis (2).

Periotome has been utilized in our work as an atraumatic extraction method followed by the use of Benex extraction system to remove the tooth from its socket without damaging the osseous housing and this technique help to reduce the postoperative pain by preserving the soft and hard tissue after extraction (30). The use of Periotome was limited to the coronal sharp's fibers only which facilitated the longitudinal extraction processes by the Benex

system, this might help create an environment that is fully supportive of implant insertion. The pain level in our study was recorded by the visual analogue scale VAS scale for the ten patients. During the first several days following surgery, all patients had mild pain, which went away entirely within 14 days. The differences were statistically significant between preoperative and after 14 days post-operative ( $P < 0.001$ ).

The conduction of the atraumatic extraction was successfully performed in all of the twelve extractions in the ten patients, and twelve immediate implants were placed in this study. After six months, all twelve implants had undergone successful excellent osseointegration with no evidence of pain, discomfort, or periapical radiolucency. This may be the result of the atraumatic surgical procedure, patient following the instructions after surgery, and taking the necessary precautions during implant placement.

Examining the aesthetics of single implant restorations using more objective methods has been addressed recently. The assessment of soft tissue aesthetics surrounding an implant is done using the Pink Aesthetic Score (PES), this was introduced by Furhauser et al. in 2005 (19). Since then, researchers that seek to more scientifically assess and document the aesthetic results of implant restorations, especially in the anterior maxilla, have employed these evaluation techniques (31).

In our study, we use the customized healing abutment after placing the immediate implant into the freshly extracted socket to preserve the gingival contour in the esthetic zone in the anterior region to obtain a good Pink Esthetic Score results that to evaluate the overall appearance of implant restorations (32). The atraumatic extraction procedure along with the immediate temporalization and custom fabrication of the emergence profile helped in the maintenance of the Esthetics aspects of the implant in the final restoration, which is an imperative demand in cases with anterior maxillary teeth replacement. This is demonstrated by the favourable clinical outcome of the PES after implant insertion, which reported a mean value of  $10.50 \pm 0.80$ . A similar outcome was reported by Elaskary et al (2023) (22). They reported a mean PES score of 10.28. According to Furhauser et al (2005), a PES score of 10-12 yielded an acceptable and pleasing outcome

Javed et al. in 2013 examined the variables influencing osseointegration and implant stability. The study concluded by emphasizing that the primary stability and success rate of implant osseointegration may be strongly impacted by bone amount and quality, and the surgical approach used by the surgeon (33).

In this study, the average implant stability quotient value at the time of surgery was  $73.25 \pm 3.60$ , suggesting satisfactory primary stability. Six

months later, the average implant stability quotient value was  $82.08 \pm 3.99$ , demonstrating a statistically significant improvement in implant stability. The surgical method and implant positioning are responsible for this respectable primary stability.

According to research conducted by Marco Ciccù et al. in 2013 tooth extraction is more technique-sensitive and it is not affected by the bone quality surround the tooth nor the applied amount of strength (34). Simultaneously, it is thought that an excessive force greater than the extension of the socket causes an alveolus fracture, particularly in older people whose bone is thick and sclerotic.

The overall survival of the labial plate of bone after the atraumatic exodontia procedure and immediate implant placement was evaluated by the assessment of the labial plate of bone thickness in the 6 months' scan and comparing it with the preoperative CBCT record. Elaskary et al (2023) conducted a similar evaluation methodology for the assessment of immediate implant in the anterior maxillary region (22). The labial bone thickness analysis was conducted at three different cross-sectional radiographic levels.

In this study the mean reported labial bone thickness difference at the 6 months' postoperative scan was  $+0.02 \pm 0.09$ ,  $+0.40 \pm 0.30$ , and  $-0.19 \pm 0.43$  at the apical, middle, and coronal aspects respectively. This results come in accordance with several other reports that assessed the labial bone thickness after immediate implant placement (22). Elaskary et al (2023) (22) reported a mean loss of  $0.18 \pm 0.5$  at the middle aspect and  $0.38 \pm 0.29$  mm at the coronal aspect. Chu et al., (2021) reported a similar outcome but in the one year analysis (35). The gain at the middle and apical portion demonstrates the favorable preservation that occurred during the extraction process to the labial plate of bone during the extraction processes along with the favorable effect of the use of immediate implant. On the other hand, the insignificant bone loss reported at the coronal aspect and reduction in its coronal dimension is inevitable due to the bundle bone resorption.

Since crestal bone loss surrounding dental implants has been a significant predictor of the prognosis and long-term survival of dental implants, this evaluation has been the focus of a great deal of study. In 2013 Raes and colleagues inserted implant in a new extraction socket with immediate loading had an average circumferential bone level of 0.21 mm surrounding them after a year, according to an assessment utilizing CBCT. Their results indicate that CBCT is very accurate (36). In research evaluating the crestal bone loss in immediate implant implantation at one month, three months, and six months using standardized digital periapical radiographs, Tadi et al. in 2014 found an average loss of 0.80 mm at one month, 1.03 mm at three months, and 1.23 mm at six months (37). Further



research was carried out by Huber. et al. in 2012 to analyze the changes in crestal bone level of implants placed in fresh extraction sockets, They found that after a year, there was a mean loss of 0.49 mm (38).

In this study, the mean coronal crestal bone width value preoperatively was  $6.77 \pm 0.93$ , while the mean coronal crestal bone width value six months postoperatively was  $6.52 \pm 0.83$ . After six months, these reductions ( $0.25 \pm 0.15$ ) in the crestal bone width for all implants were evident. Between preoperative and six months postoperative, there were statistically significant alterations ( $P < 0.001$ ).

Thus, there are several benefits, including financial and time savings, to employing the immediate implant following atraumatic extraction. As a result, the dental implant operation was quick, painless, and safe, with the added benefit of preserving both hard and soft tissue. Since the gingiva and bone are preserved during extraction and implant implantation, neither membrane nor bone grafts are required.

Although longitudinal atraumatic axial extraction could be achieved, the Benex system do not comes with its limitations. The utilization of this extraction system may be limited to the anterior teeth and those with a regular straight morphological root configuration. Furthermore, differences between patients in their healing power could act as a confounding factor in this study, although measures were done to limit the cohort of the study

Axial tooth extraction technique using Benex extraction system is a practicable modality with a favourable execution that could be easily implemented in the extraction of anterior teeth. It provides a minimally invasive procedure with minimal pain experience and favourable clinical outcome. Immediately placed implants showed favourable clinical and radiographic outcomes owing to the lack of socket expansion and the maintenance of the integrity of the remaining walls.

#### CONFLICT OF INTEREST

The authors deny any conflicts of interest.

#### FUNDING

No specific funding was received for this work.

#### REFERENCES

1. Al-Khateeb TH, Alnahr A. Pain experience after simple tooth extraction. *J Oral Maxillofac Surg.* 2008;66:911-7.
2. Kubilius M, Kubilius R, Gleiznys A. The preservation of alveolar bone ridge during tooth extraction. *Stomatologija.* 2012;14:3-11.
3. Srinivas B, Das P, Rana MM, Qureshi AQ, Vaidya KC, Ahmed Raziuddin SJ. Wound Healing and Bone Regeneration in Postextraction Sockets with and without Platelet-rich Fibrin. *Ann Maxillofac Surg.* 2018;8:28-34.
4. Muska E, Walter C, Knight A, Taneja P, Bulsara Y, Hahn M, et al. Atraumatic vertical tooth extraction: a proof of principle clinical study of a novel system. *Oral Surg Oral Med Oral Pathol Oral Radiol.* 2013;116:e303-10.
5. Rakhshan V. Common risk factors for postoperative pain following the extraction of wisdom teeth. *J Korean Assoc Oral Maxillofac Surg.* 2015;41:59-65.
6. Pippi R. Post-Surgical Clinical Monitoring of Soft Tissue Wound Healing in Periodontal and Implant Surgery. *Int J Med Sci.* 2017;14:721-8.
7. Nitzan DW. On the genesis of "dry socket". *J Oral Maxillofac Surg.* 1983;41:706-10.
8. Dietrich T, Krug R, Krastl G, Tomson PL. Restoring the unrestorable! Developing coronal tooth tissue with a minimally invasive surgical extrusion technique. *Br Dent J.* 2019;226:789-93.
9. Hong B, Bulsara Y, Gorecki P, Dietrich T. Minimally invasive vertical versus conventional tooth extraction: An interrupted time series study. *J Am Dent Assoc.* 2018;149:688-95.
10. Fugazzotto PA. Success and failure rates of osseointegrated implants in function in regenerated bone for 72 to 133 months. *Int J Oral Maxillofac Implants.* 2005;20:77-83.
11. Fugazzotto PA. Implant placement at the time of mandibular molar extraction: description of technique and preliminary results of 341 cases. *J Periodontol.* 2008;79:737-47.
12. Fugazzotto PA, Shanaman R, Manos T, Shtetman R. Guided bone regeneration around titanium implants: report of the treatment of 1,503 sites with clinical reentries. *Int J Periodontics Restorative Dent.* 1997;17:292, 3-9.
13. Fugazzotto PA. Guided bone regeneration at immediate implant insertion and loading: a case report. *Implant Dent.* 2004;13:223-7.
14. Chen ST, Wilson TG, Jr., Hämmerle CH. Immediate or early placement of implants following tooth extraction: review of biologic basis, clinical procedures, and outcomes. *Int J Oral Maxillofac Implants.* 2004;19 Suppl:12-25.
15. Steiner GG, Francis W, Burrell R, Kallet MP, Steiner DM, Macias R. The healing socket and socket regeneration. *Compend Contin Educ Dent.* 2008;29:114-6, 8, 20-4 passim.
16. Ren SX, Hu XL, Li JH, Jiang X, Lin Y. [A minimally invasive extraction technique using Benex Extraction System in flapless immediate implant placement in anterior teeth]. *Shanghai Kou Qiang Yi Xue.* 2016;25:334-9.
17. Bodian CA, Freedman G, Hossain S, Eisenkraft JB, Beilin Y. The visual analog scale for pain: clinical significance in postoperative patients. *Anesthesiology.* 2001;95:1356-61.
18. Juodzbaly G, Wang HL. Soft and hard tissue assessment of immediate implant placement: a case series. *Clin Oral Implants Res.* 2007;18:237-43.
19. Fürhauser R, Florescu D, Benesch T, Haas R, Mailath G, Watzek G. Evaluation of soft tissue around single-tooth implant crowns: the pink

- esthetic score. *Clin Oral Implants Res.* 2005;16:639-44.
20. Gupta G. Implant Stability Quotient (ISQ): A Reliable Guide for Implant Treatment. In *Current Concepts in Dental Implantology-From Science to Clinical Research.* IntechOpen. 2022.
  21. Behnia H, Motamedian SR, Kiani MT, Morad G, Khojasteh A. Accuracy and reliability of cone beam computed tomographic measurements of the bone labial and palatal to the maxillary anterior teeth. *Int J Oral Maxillofac Implants.* 2015;30:1249-55.
  22. Elaskary A, Ghallab N, Thabet A, Shemais N. The bone shielding versus dual-zone concept in treating thin-walled fresh extraction sockets with immediate implant placement: Soft and hard tissue changes. A randomized clinical trial. *Clin Implant Dent Relat Res.* 2024;26:66-77.
  23. Turkyilmaz I, Suarez JC, Company AM. Immediate implant placement and provisional crown fabrication after a minimally invasive extraction of a peg-shaped maxillary lateral incisor: a clinical report. *J Contemp Dent Pract.* 2009;10:E073-80.
  24. Bornstein MM, Cionca N, Mombelli A. Systemic conditions and treatments as risks for implant therapy. *Int J Oral Maxillofac Implants.* 2009;24 Suppl:12-27.
  25. Gómez-de Diego R, Mang-de la Rosa Mdel R, Romero-Pérez MJ, Cutando-Soriano A, López-Valverde-Centeno A. Indications and contraindications of dental implants in medically compromised patients: update. *Med Oral Patol Oral Cir Bucal.* 2014;19:e483-9.
  26. Pozzi A, Gallelli L. Pain management for dentists: the role of ibuprofen. *Ann Stomatol (Roma).* 2011;2:3-24.
  27. Levitt D. Atraumatic extraction and root retrieval using the periosteal elevator: a precursor to immediate placement of dental implants. *Dent Today.* 2001;20:53-7.
  28. Bortoluzzi MC, Manfro AR, Nodari RJ, Jr., Presta AA. Predictive variables for postoperative pain after 520 consecutive dental extraction surgeries. *Gen Dent.* 2012;60:58-63.
  29. Sjögren A, Arnrup K, Jensen C, Knutsson I, Huggare J. Pain and fear in connection to orthodontic extractions of deciduous canines. *Int J Paediatr Dent.* 2010;20:193-200.
  30. Sharma SD, Vidya B, Alexander M, Deshmukh S. Periosteal elevator as an Aid to Atraumatic Extraction: A Comparative Double Blind Randomized Controlled Trial. *J Maxillofac Oral Surg.* 2015;14:611-5.
  31. Cho HL, Lee JK, Um HS, Chang BS. Esthetic evaluation of maxillary single-tooth implants in the esthetic zone. *J Periodontal Implant Sci.* 2010;40:188-93.
  32. Suphangul S, Rokaya D, Kanchanasobhana C, Rungsiyakull P, Chaijareenont P. PEEK Biomaterial in Long-Term Provisional Implant Restorations: A Review. *J Funct Biomater.* 2022;13.
  33. Javed F, Ahmed HB, Crespi R, Romanos GE. Role of primary stability for successful osseointegration of dental implants: Factors of influence and evaluation. *Interv Med Appl Sci.* 2013;5:162-7.
  34. Ciccù M, Bramanti E, Signorino F, Ciccù A, Sortino F. Experimental study on strength evaluation applied for teeth extraction: an in vivo study. *Open Dent J.* 2013;7:20-6.
  35. Chu SJ, Saito H, Levin BP, Baumgarten H, Egbert N, Wills MJ, et al. Outcomes of a 1-Year Prospective Single-Arm Cohort Study Using a Novel Macro-Hybrid Implant Design in Extraction Sockets: Part 1. *Int J Periodontics Restorative Dent.* 2021;41:499-508.
  36. Raes F, Renckens L, Aps J, Cosyn J, De Bruyn H. Reliability of circumferential bone level assessment around single implants in healed ridges and extraction sockets using cone beam CT. *Clin Implant Dent Relat Res.* 2013;15:661-72.
  37. Tadi DP, Pinisetti S, Gujjalapudi M, Kakaraparthi S, Kolasani B, Vadapalli SH. Evaluation of initial stability and crestal bone loss in immediate implant placement: An in vivo study. *J Int Soc Prev Community Dent.* 2014;4:139-44.
  38. Huber S, Rentsch-Kollár A, Grogg F, Katsoulis J, Mericske R. A 1-year controlled clinical trial of immediate implants placed in fresh extraction sockets: stability measurements and crestal bone level changes. *Clin Implant Dent Relat Res.* 2012;14:491-500.