

Indications and Surgical Techniques for Corneal Transplantation in Mansoura Ophthalmic Center. A 4 years retrospective analytic study

Eman A. Megahed¹, Eman M. Elhefny², Tarek A. Mohsen², Rania K. Farag².

¹; M.B., B. Ch, Ophthalmology resident in ministry of health

²; Department of ophthalmology, Faculty of Medicine-Mansoura University, Egypt

Corresponding author: Dr. Eman A. Megahed, Mansoura Ophthalmic Center, Faculty of Medicine, Mansoura University, Egypt. Tel: 01141592902; Email: dr.emanmegahed89@gmail.com

Received: 31-12-2023, Accepted: 3-2-2024, Published online:16-6-2024

EJO(MOC) 2024;4(2):80-90.

Short title: Surgical Techniques for Corneal Transplantation in MOC

ABSTRACT:

Purpose: to evaluate indications and surgical techniques for corneal transplantation for patients who had undergone keratoplasty, within 4 years duration in Mansoura Ophthalmic Center.

Patients and methods: This was a retrospective analytic study conducted on patients attended to Mansoura Ophthalmic Center, Mansoura University, Egypt within the period from September 2017 to September 2021 and undergone keratoplasty in Mansoura ophthalmic center including (PKP, DALK and DMEK). Data including medical and family history taking and complete personal history. Pre-operative full ophthalmic data including visual acuity assessment, anterior segment examination, Fundus examination. Post-operative ophthalmological examination within the first follow up including uncorrected and Best-corrected distance visual acuity, slit-lamp examination, fundus examination if possible.

Results: The current study was conducted on 190 eyes from 190 cases who had undergone keratoplasty within a period from September 2017 to September 2021. Their mean age was 35.2 years, ranging from 10 to 76 years. They were 78 males (41.1%) and 112 females (58.9%). Keratoconus was the most common indication for keratoplasty (60.0%) followed by Corneal opacity after mechanical trauma in 25 eyes (13.2%). PKP was the most common procedure in our study done for 115 eyes (60.50%) followed by DALK done in 70 eyes (36.8%).

Conclusion: Keratoconus was the most common indication for keratoplasty. PKP was the most prevalent technique in patients undergoing corneal transplantation performed in MOC. DALK was the first choice for keratoplasty in ectatic corneal diseases such as keratoconus with healthy endothelium, while PKP was the second surgical treatment. Corneal opacity which caused by mechanical trauma, chemical injury or post infectious keratitis was the second indication for keratoplasty, in which PKP was the technique for keratoplasty or triple procedure in cases with traumatic cataract. DMEK was the preferred technique in eyes with post-operative corneal decompensation. PKP was the choice in eyes with graft rejection, corneal stromal dystrophy and post LASIK ectasia.

Keywords: Corneal Transplantation, Penetrating Keratoplasty, Deep Anterior Lamellar Keratoplasty, Descemet's Stripping Automated Endothelial Keratoplasty.

INTRODUCTION

Keratoplasty is the most successful organ transplantation in the human body as cornea is devoid of vasculature. It is a useful procedure for achieving corneal clarity and improves vision in most patients. It is being done for (therapeutic, tectonic and optical) causes¹.

Indications for corneal transplantation have changed over time and differ based on location such as the city and country; moreover, allocation of resources is based on the epidemiology of corneal pathologies in each region. For example, bullous keratopathy is reported to be the most common indication for corneal transplantation in developed countries and infectious

corneal diseases and corneal scars are more prevalent in developing countries².

Corneal transplantation procedures are broadly classified as full-thickness penetrating keratoplasty and partial lamellar corneal surgeries which include anterior lamellar keratoplasty [superficial anterior lamellar keratoplasty (SALK), automated lamellar therapeutic keratoplasty (ALTK) and deep anterior lamellar keratoplasty (DALK)] and posterior lamellar keratoplasty [Descemet stripping automated endothelial keratoplasty (DSAEK) and Descemet membrane endothelial keratoplasty (DMEK)]³.

The cornea is the most anterior layer of the eye. It consists of transparent and avascular tissue and is responsible for allowing transmission of light⁴.

The human cornea is comprised of six layers: the corneal epithelium, anterior limiting membrane (Bowman's membrane), corneal stroma, Dua's Layer, posterior limiting lamina (Descemet's membrane) and the corneal endothelium⁵.

The first total penetrating keratoplasty was described in 1951 by Ramon Castroviejo as a method for replacing a large area of diseased cornea and adjacent sclera with donor tissue. The primary aim of this procedure is the tectonic repair of large perforations or other extensive corneal pathologies and restoration of integrity of the globe. Because of its size, frequently involving adjacent sclera and indications for surgery (infections, corneal ulcerations, injuries, and immune disorders), total penetrating keratoplasties are associated with a high risk of complications. The use of steroids and other immunosuppressive agents significantly reduces the rate of immunological graft rejections. Causative and complimentary intensive medication is necessary to avoid surgical treatment failure, which would lead to severe visual loss or even loss of the eye globe⁶.

Corneal transplantation techniques are the result of a culmination of ideas, experimentation, and perseverance over centuries. Developments in the practical achievement of corneal transplantation are marked by development of anesthesia in the late 19th century the recognition of the immunological phenomenon of corneal graft rejection and the increasing availability of antibiotics in the 1940s and corticosteroids in the 1950s. The final ingredients were the introduction of nylon sutures by Ethicon specifically for

keratoplasty in the 1960s and the introduction of surgical microscopes into ophthalmology in the late 1960s which resulted in the modern era of keratoplasty⁷.

This study was conducted to evaluate indications and surgical techniques for corneal transplantation for patients who had undergone keratoplasty, within 4 years duration in Mansoura Ophthalmic Center.

PATIENTS AND METHODS:

This was a retrospective analytic study conducted on patients attending Mansoura Ophthalmic Center, Mansoura University, Egypt within the period from September 2017 to September 2021. The study was approved by Mansoura Medical Research Ethics Committee. Faculty of Medicine, Mansoura University (code number MS. 21.10.1699).

The study included 190 eyes of 190 patients who had undergone keratoplasty within the period of 4 years from September 2017 to September 2021 including (PKP, DALK and DMEK).

The following data which were collected of patients who had undergone keratoplasty; demographic data including medical and family history taking and complete personal history including age, sex, history of ocular surgery, neurologic, metabolic or systemic disease.

Pre-operative full ophthalmic data including visual acuity assessment, best corrected visual acuity using Log MAR, measurement of intraocular pressure using Goldmann Applanation tonometer in possible cases, anterior segment examination using Slit lamp biomicroscope which was used to assess (corneal examination- depth of anterior chamber- state of iris- pupillary reaction, shape, regularity, lens morphology). Fundus examination by indirect ophthalmoscope when possible, Causes of surgical interference of keratoplasty.

Investigation includes B-scan US by NIDEK us-4000, VEP and ERG by ROLAND CONSULT German, Pentacam by pentacam HR, Oculus, Wetzlar if possible, Anterior segment OCT.

Surgical procedure: -

Steps of Penetrating Keratoplasty performed in MOC:

- Following the establishment of anesthesia, an eyelid speculum was inserted, and the patient's eye was secured using a scleral fixation ring or sutures. The host corneal diameter was measured to determine the appropriate size

for the donor button. The donor button was trephined aiming for 0.25-0.5 mm larger than the host trephination.

- The host cornea was trephined and anterior chamber filled with viscoelastic.
- The donor tissue was placed in endothelial side down to the recipient eye.
- The cornea was sutured in place with either interrupted or continuous sutures.
- Postoperative topical antibiotics, steroid and lubricant eye drops were used.

Steps of Descemet's Membrane Endothelial Keratoplasty performed in MOC

- Following the establishment of anesthesia, an eyelid speculum was inserted, desepitheliation for better visualization. Two to four paracentesis sites and a temporal corneal incision were created, and the anterior chamber was filled with air. Scoring and stripping Descemet membrane following peripheral marking.
- Complete descemetorhexis was done through the main wound.
- Creating an inferior peripheral iridectomy, removing air and injecting BSS.
- Unscrolling the DMEK graft which was secured by filling the anterior chamber by air.

Steps of Deep Anterior Lamellar Keratoplasty (DALK) performed in MOC

- DALK is a partial-thickness cornea transplant procedure that involves selective transplantation of the corneal stroma, leaving the native Descemet membrane and endothelium in place.
- A trephine of an appropriate diameter was used to make a partial-thickness incision into the patient's cornea, followed by pneumodissection (type I or II) or manual dissection of the anterior stroma.
- This was followed by placement of a graft prepared from a full-thickness punch in which the donor endothelium-Descemet membrane complex has been removed. The intention was to preserve the patient's Descemet membrane and endothelium. Similar to PK, the graft was secured with interrupted and/or running sutures.

Post-operative ophthalmological examination within first follow up including uncorrected and Best-corrected distance

visual acuity, slit-lamp examination including conditions of cornea and depth of AC, fundus examination by indirect ophthalmoscope if possible.

Statistical Analysis

The collected data was revised, coded, and tabulated using Statistical package for Social Science (IBM Corp. Released 2017. IBM SPSS Statistics for Windows, Version 25.0. Armonk, NY: IBM Corp.). Mean, standard deviation (\pm SD) were used for numerical data. Frequency and percentage were used for non-numerical data. ANOVA (Analysis of variance) Test was used to assess the statistical significance of the difference between more than two study group means. Chi-Square test was used to examine the relationship between two qualitative variables. A p value is considered significant if <0.05 at confidence interval 95%.

RESULTS:

The current study was conducted on 190 eyes from 190 cases who had undergone keratoplasty within a period from September 2017 to September 2021. Their mean age was 35.2 years, ranging from 10 to 76 years. They were 78 males (41.1%) and 112 females (58.9%) (Table 1).

Among all studied eyes, 109 eyes had no history of ocular surgery or trauma (57.4%). While 3 eyes (1.6%) had history of previous keratoplasty, History of cataract extraction and IOL implantation was found in 6 eyes (3.2%), History of intra corneal rings implantation was found in 10 eyes (5.3%), history of membrane graft after resistant ulcer was found in 24 eyes (12.6%), History of LASIK was found in 5 eyes (2.6%), History of blunt trauma found in 18 eyes (9.5%), and History of penetrating trauma by sharp objects followed by Iry repair found in 7 eyes (3.7%), history of chemical injury was found in 8 eyes (4.2%) (Table 2)

Pre operative visual acuity among all studied eyes using Log MAR. It was 2.7 in one eye (0.5%), 2.2 in 11 eyes (5.8%), 1.98 in 63 eyes (33.2%), 1.8 in 51 eyes (26.8%), 1.5 in 27 eyes (14.2%), 1.3 in 13 eyes (6.8%), 1 in 18 eyes (9.5%), 0.8 in 4 eyes (2.1%), 0.6 in 2 eyes (1.1%). IOP was within normal range in 120 eyes (63.2%), while it could not be assessed in 70 eyes (table 3).

VEP results among all studied eyes were normal optic nerve function in 137 eyes (72.1%). While optic nerve function defect was found in 53 eyes (27.9%). ERG results among all studied eyes were normal ERG in 136 eyes (71.6%), reduction

in retinal function was found in 48 eyes (25.3%), abnormal rod response was found in 6 eyes (3.2%) (table 4).

Keratoplasty procedures among all studied eyes were DALK which was done for 70 eyes (36.8%), DMEK was done for 5 eyes (2.6%), PKP was done for 107 eyes (56.3%). PKP+ Cataract extraction +IOL implantation (Triple procedure) was done for 8 eyes (4.2%) (Table 5).

Among all studied eyes, 114 eyes had keratoconus, out of them 50 eyes (26.3%) were subjected to PKP, 64 eyes (33.7%) were subjected to DALK, 57 eyes had corneal opacity, out of them 45 eyes (23.7%) were subjected to PKP, 8

eyes (4.2%) were subjected to PKP +Cataract extraction+ IOL implantation And 4 eyes (2.1%) were subjected to DALK, 6 eyes had post-operative corneal decompensation, out of them 5 eyes (2.6%) were subjected to DMEK, one eye (0.5%) was subjected to PKP; 5 eyes had corneal dystrophy, out of them, 4 eyes (2.1%) were subjected to PKP, one eye(0.5%) was subjected to DALK; 3 eyes had graft rejection, all were subjected to PKP; 5 eyes had Post LASIK ectasia, out of them, 4 eyes (2.1%) were subjected to PKP and one eye (0.5%) was subjected to DALK (table 6) and (figure 1).

Table 1. Patients' features.

Parameter		Eyes (n=190)	
Age (years)	Mean \pm SD	35.2 \pm 14.1	
	range	10-76	
Gender	Male	N, %	78 41.1%
	Female	N, %	112 58.9%

Table 2: History of ocular surgery or trauma among all studied eyes.

History of ocular surgery or trauma	Eyes (n=190)	%
Previous keratoplasty	3	1.6%
History of cataract extraction and IOL implantation	6	3.2%
History of intracorneal rings implantation	10	5.3%
History of membrane graft after resistant ulcer	24	12.6%
History of LASIK	5	2.6%
History of mechanical trauma	Blunt	18 9.5%
	Penetrating followed by Iry repair	7 3.7%
History of chemical injury	8	4.2%
No history of ocular surgery or trauma	109	57.4%

Table 3: Visual acuity and IOP among all studied eyes by Goldman Applanation Tonometer.

	Eyes (n=190)	%
Visual acuity		
2.7	1	0.5%
2.2	11	5.8%
1.98	63	33.2%
1.8	51	26.8%
1.5	27	14.2%
1.3	13	6.8%
1	18	9.5%
0.8	4	2.1%
0.6	2	1.1%
IOP		
	Eyes (n=190)	%
within normal range	120	63.2%
Can't be assessed	70	36.8%

Table 4: VEP among all studied eyes.

	Eyes (n=190)	%
VEP results		
Normal optic nerve function	137	72.1%
Optic nerve function defect	53	27.9%
ERG results		
Normal	136	71.6%
reduction in retinal function	48	25.3%
abnormal rod response	6	3.2%

Table 5: Keratoplasty procedures among all studied eyes.

Keratoplasty procedure		Eyes (n=190)	%
DALK		70	36.8%
DMEK		5	2.6%
PKP	PKP	107	56.3%
PKP	PKP + Cataract extraction +IOL implantation (Triple procedure)	8	4.2%

Table 6: Indications and types of operations among all studied eyes

Diagnosis	Eyes (n=190)	Operation	Eyes (n=190)	%
Keratoconus	114	PKP	50	26.3%
		DALK	64	33.7%
		PKP	45	23.7%
Corneal opacity	57	PKP+cataract extraction+IOL implantation	8	4.2%
		DALK	4	2.1%
Post operative corneal decompensation	6	DMEK	5	2.6%
		PKP	1	0.5%
Corneal stromal dystrophy	5	PKP	4	2.1%
		DALK	1	0.5%
Graft rejection	3	PKP	3	1.6%
Post LASIK ectasia	5	PKP	4	2.1%
		DALK	1	0.5%

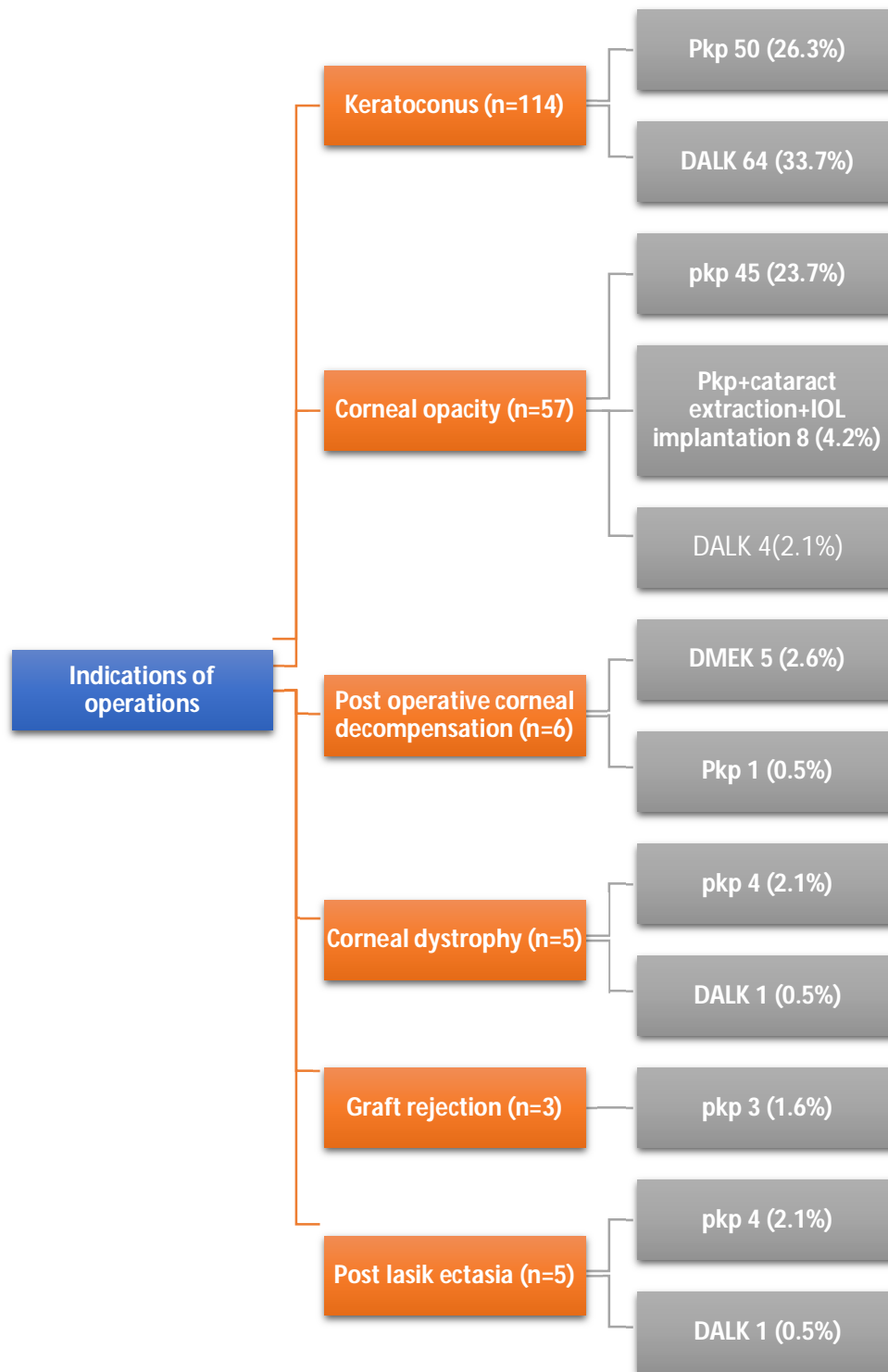


Figure (1): Indications and types of operations among all studied eyes.

DISCUSSION:

Corneal disease is the third leading cause of blindness worldwide after cataracts and glaucoma. Corneal transplantation or keratoplasty is the most commonly performed and also the most successful allogenic transplant worldwide⁸.

Corneal transplantation can be classified on the basis of indication for which it is being done (therapeutic, tectonic and optical). Similarly, there are different techniques, which are used for replacing selective anterior or posterior diseased part of cornea with a normal donor cornea³.

The present study was a retrospective analytic study conducted on 190 eyes from 190 cases who had undergone keratoplasty within a period from September 2017 to September 2021.

The present study showed that the mean age was 35.2 years, ranging from 10 to 76 years. They were 78 males (41.1%) and 112 females (58.9%). Mean age in the present study was less than previous study by Jamali et al who found that the mean age of patients was 52 years due to large number of elderly patients with corneal ulcers which were the leading indication for keratoplasty and bullous keratopathy, and young patients with keratoconus. Subjects with anterior segment dysgenesis (Peter's anomaly) were the youngest and patients with bullous keratopathy (BK) were the oldest².

Bittencourt et al showed that the mean age of the patients was 47.4 ± 23 years, with a minimum age of 5 years and a maximum age of 87 years, and in 39.6% of the transplants, the patients were 60 years old or older. Regarding gender, a little more than half of the transplant recipients were female (50.4%)⁹.

A study carried out in 2006 by Netto et al. showed that 59.6% of the patients were male and 40.3% were female, with an average age of 37 years (ranging from 3 to 83 years)¹⁰.

The present study showed that males had higher frequency of postsurgical corneal decomposition and corneal stromal dystrophy when compared to females. While females had higher frequency of keratoconus, corneal opacity, graft rejection and post LASIK ectasia. Although, there was no significant differences between both genders regarding indications.

Soh, Kocaba¹¹ showed that female predominance in

keratoplasty patients probably reflects the large increase in cases treated for Fuchs endothelial corneal dystrophy (FECD), which has a strong female predominance and is also a known contributor to the development of pseudophakic bullous keratopathy (PBK).

Among all studied eyes in our study, 109 eyes had no history of ocular surgery or trauma (57.4%). While, previous keratoplasty was found in 3 eyes (1.6%), History of cataract extraction and IOL implantation was found in 6 eyes (3.2%), History of intra corneal rings implantation was found in 10 eyes (5.3%), history of membrane graft after resistant ulcer was found in 24 eyes (12.6%), History of LASIK was found in 5 eyes (2.6%), History of blunt trauma found in 18 eyes (9.5%), and history of penetrating trauma by sharp object followed by Iry repair found in 7 eyes (3.7%). And history of chemical injury in 8 eyes (4.2%).

Regarding Visual acuity among all studied eyes. It was 2.7 in one eye (0.5%), 2.2 in 11 eyes (5.8%), 1.98 in 63 eyes (33.2%), 1.8 in 51 eyes (26.8%), 1.5 in 27 eyes (14.2%), 1.3 in 13 eyes (6.8%), 1 in 18 eyes (9.5%), 0.8 in 4 eyes (2.1%), 0.6 in 2 eyes (1.1%).

Vale et al showed that 80 patients (87.9%) presented legal blindness (<20/400) before surgery, 6 (6.6%) subnormal vision (20/200-20/60) and 5 (5.5%) normal vision (20/50-20/20)⁸.

The present study showed that IOP was within normal range in 120 eyes (63.2%), while it could not be assessed in 70 eyes (36.8%).

Regarding clinical Lens examination recorded among all studied eyes was clear lens in 65 eyes (34.2%), senile cataract was detected in 36 eyes (18.9%), traumatic cataract was detected in 8 eyes (4.2%), PCIOL was noticed in 6 eyes (3.2%). while it can't be assessed in 75 eyes (39.5%).

Cataract surgery, with intraocular lenses, can cause corneal endothelial lesions with pseudophakic bullous keratopathy¹³.

According to a study conducted in the state of Rio de Janeiro, the loss of endothelial tissue after cataract surgery is 2.5 to 8 times the annual loss in cases in which surgery was not performed, and the average duration between cataract surgery and the pseudophakic bullous keratopathy is 11.87 months¹⁴.

Regarding VEP among studied eyes. normal optic nerve function was found in 137 eyes (72.1%). While optic nerve

function defect was found in 53 eyes (27.9%). ERG results among all studied cases were normal ERG in 136 eyes (71.6%), reduction in retinal function was found in 48 eyes (25.3%), abnormal rod response was found in 6 eyes (3.2%)

VEP test was considered to be the only objective visual examination currently available in ophthalmology. Furthermore, flash VEP is the only objective examination in patients with low VA¹⁵. Thuangtong et al.,¹⁶ showed that both P2 amplitude and a-wave have a good visual prognostic value in patients' who underwent PK. The authors compared results to the fellow healthy eye¹⁶.

The Pentacam refractive indices include a combination of tomographic, topometric, and pachymetric parameters. the use of elevation, pachymetry, and sagittal curvature maps is recommended in a step-wise approach to evaluating a surgical candidate¹⁷.

In our study, Pentacam was done for 119 eyes with keratoconus and post LASIK ectasia and can't be done for other cases 71 eyes.

The present study revealed that the most common indication for keratoplasty was keratoconus (60%) followed by corneal opacity (30%), postoperative corneal decomposition (3.2%), Corneal dystrophy (2.6%), Graft rejection (1.6%), And post LASIK ectasia (2.6%).

Similarly, Kanavi et al reported the indications of PKP nationwide in Iran from 1997 to 2003; their results revealed that keratoconus was the most common indication, followed by corneal opacities and scars, PBK, corneal dystrophies, ABK, and re-graft in descending order¹⁸. Zare et al reported that the leading indication for corneal transplantation at Labbafinejad Medical Center, Tehran, Iran, from 2004 to 2009 was keratoconus, but bullous keratopathy was the second most common indication, followed by previous failed grafts, infectious corneal ulcers, corneal scars, trachoma keratopathy and corneal dystrophies¹⁹.

Keratoconus was the most common indication and remained at the top of the list over the 6 years period²⁰.

Studies conducted in western countries reported that FED was as an important indication, with a rate of 9.3% to 23.2%²¹.

The present study showed that fundus examination among all studied eyes was myopic fundus in 34 eyes (17.9%), normal findings was found in 36 eyes (18.9%), diabetic

retinopathy was found in one eye (0.5%). While it can't be assessed in 119 eyes (62.6%)

Regarding Keratoplasty procedures among all studied eyes in our study were DALK which was done for 70 eyes (36.8%), DMEK was done for 5 eyes (2.6%), PKP was done for 107 eyes (56.3%), PKP-cataract extraction and IOL implantation (triple operation) was done for 8 eyes (4.2%).

Similarly, Jamali et al showed that PKP was the most common technique of corneal transplantation (68.7%), followed by DALK (16.3%) and DSAEK (14.9%)².

Szkodny showed that the most common technique was penetrating keratoplasty (69,54%), then lamellar grafts both anterior and posterior (19,63%)²².

Data for 95 countries of 116 countries (82%), representing 173 637 grafts (94%), were available. Keratoplasties were defined as either penetrating keratoplasty or lamellar grafts, with no distinction between anterior and endothelial grafts. The median rate of penetrating keratoplasty was 90%⁸.

Among all studied eyes in our study, keratoconus mostly managed with DALK, while corneal opacity, graft rejection, corneal dystrophy and Post LASIK ectasia managed mainly with PKP. post-operative corneal decompensation managed mainly with DEMK.

Similarly, Zare et al showed that PKP was the dominant technique for infectious corneal ulcers, DALK has become the dominant technique for keratoconus. PKP is the main surgical approach for failed grafts and corneal scars¹⁹.

Regarding Post-operative ophthalmic finding at the first follow up visit was corneal graft edema which was mild (iris details clearly visible) in 158 eyes (83.2%), moderate in 32 eyes (16.8%). AC was formed in 70 eyes (36.8%), shallow in 120 eyes (63.2%). Lens was clear in 93 eyes (48.9%), Cataract was recorded in 51 eyes (26.8%). PCIOL in 14 eyes (7.4%), can't be assessed in 32 eyes (16.8%) Tension was formed in 90 eyes (47.4%) while soft in 100 eyes (52.6%).

Studies conducted on patients who underwent Descemet stripping automated endothelial keratoplasty to evaluate early clinical outcomes were the graft dislocation rate (13%), and the graft failure rate (16%)²³.

Feizi, Javadi²⁴ showed that the outcomes and complications of deep anterior lamellar keratoplasty were

intraoperative Descemet's membrane perforation, the Urrets Zavalía syndrome, graft epithelial problems, sub epithelial graft rejection, high intraocular pressure, and traumatic wound dehiscence and suture-related complications included loosening sutures, suture-tract vascularization and suture-associated abscesses.

CONCLUSION

Keratoconus was the most common indication for keratoplasty. PKP was the most prevalent technique in patients undergoing corneal transplantation performed in MOC.

DALK was the first choice for keratoplasty in ectatic corneal diseases such as keratoconus with healthy endothelium, while PKP was the second surgical treatment.

Corneal opacity which caused by mechanical trauma, chemical injury or post infectious keratitis was the second indication for keratoplasty, in which PKP was the technique for keratoplasty or triple procedure in cases with traumatic cataract.

DMEK was the preferred technique in eyes with post-operative corneal decompensation.

PKP was the choice in eyes with graft rejection, corneal stromal dystrophy and post LASIK ectasia

The limitations of this study include the retrospective design; this is taking of insufficient data and inability to collect all the needed information during the follow up of the patients.

ACKNOWLEDGEMENT: None

Data Availability: The authors declare that all data supporting the findings of this study are available within the article and its supplementary information file.

Competing interests: The authors declare no competing interests.

Corresponding author

Correspondence to: Eman A. Megahed
Email: dr.emanmegahed89@gmail.com

Affiliations

Eman A. Megahed. M.B., B. Ch, Ophthalmology resident in ministry of health, Egypt, Daqahlia governorate, Egypt.

Ethics declarations: All procedures performed in the study followed the 1964 Helsinki declaration and its later amendments, University Ethics Committee approved the project.

Conflict of interest

Eman A. Megahed, Eman M. Elhefny, Tarek A. Mohsen, Rania K. Farag. All authors have no conflicts of interest that are directly relevant to the content of this review.

Funding: No sources of funding were used to conduct this review.

Reviewer disclosures: No relevant financial or other relationships to disclose.

Declaration of interest: No financial affiliations or financial involvement with any organization or entity with a financial competing with the subject matter or materials discussed in the review.

REFERENCES:

1. Roozbahani, M., K.M. Hammersmith, P.K. Nagra, J.F. Ma, and C.J. Rapuano, Therapeutic penetrating keratoplasty: a retrospective review. *Eye & Contact Lens*, 2018. 44: p. S433-S441.
2. Jamali, H. and A.R. Gholampour, Indications and Surgical Techniques for Corneal Transplantation at a Tertiary Referral Center. *J Ophthalmic Vis Res*, 2019. 14(2): p. 125-130.
3. Singh, R., N. Gupta, M. Vanathi, and R. Tandon, Corneal transplantation in the modern era. *The Indian journal of medical research*, 2019. 150(1): p. 7-22.
4. Khosravimelal S, Mobaraki M, Eftekhari S, Ahearme M, Seifalian A M and Gholipourmalekabadi M (2021): Hydrogels as emerging materials for cornea wound healing. *Small*; 17: (30), 2006335.
5. Farjo A A, Brumm M V, Soong H K and Hood C T (2018): Corneal anatomy, physiology, and wound healing. *Ophthalmology E-Book*; 155.
6. Krysik K, Wroblewska-Czajka E, Lyssek-Boron A, Wylegala E A and Dobrowolski D (2018): Total Penetrating Keratoplasty: Indications, Therapeutic Approach, and Long-Term Follow-Up. *Journal of Ophthalmology*; 2018: 9580292.
7. Crawford A Z, Patel D V and McGhee C N (2013): A brief history of corneal transplantation: From ancient to modern. *Oman journal of ophthalmology*; 6: (Suppl 1), S12.

8. Gain, P., R. Jullienne, Z. He, M. Aldossary, S. Acquart, F. Cognasse, and G. Thuret, Global Survey of Corneal Transplantation and Eye Banking. *JAMA Ophthalmology*, 2016. 134(2): p. 167-173.
9. Bittencourt, J.L., Í.d.M.V. Gatti, C.F. Lessa, L.R.N. Cirillo, M.G. Ierardi, M.P. Garcia, L.A. de Brito Martins, F.L.A. Fonseca, and V.L. Lima, Epidemiological profile and study on waiting lists for corneal transplants in a tertiary hospital. *ABCS Health Sciences*, 2020. 45(Suppl. 3): p. e020107-e020107.
10. Calix Netto, M.J., E.D. Giustina, G.Z. Ramos, R.F.C. Peccini, M. Sobrinho, and L.B.d. Souza, Major indications for corneal penetrating keratoplasty at a reference service in São Paulo state (Sorocaba-SP, Brazil). *Arquivos Brasileiros de Oftalmologia*, 2006. 69: p. 661-664.
11. Soh, Y., V. Kocaba, M. Pinto, and J.S. Mehta, Fuchs endothelial corneal dystrophy and corneal endothelial diseases: East meets West. *Eye*, 2020. 34(3): p. 427-441.
12. Vale, I., R.B. Trevisol, I.L.I. de Oliveira, T. Matsuo, and E. Hoyama, Epidemiological profile of corneal transplant surgeries at Londrina Eye Hospital (HOFTALON), Brazil. *Investigative Ophthalmology & Visual Science*, 2021. 62(8): p. 970-970.
13. Santhiago, M.R.d., L.A.M. Monica, N. Kara-Junior, B.d.A.F. Gomes, P.M. Bertino, M.G.G. Mazurek, Y. Yamane, and S.H.S. Meirelles, Profile of patient with aphakic/pseudophakic bullous keratopathy attended at public hospital. 2009. 68(4): p. 201-205.
14. Macedo, A.C., C. Ishirara, D. Fairbanks, V.V. Neto, and J.R.C.L. Rehder, Micropuncture with radiofrequency for the treatment of symptomatic bullous keratopathy. *Rev Bras Oftalmol.*, 2010. 69(3): p. 152-158.
15. Contestabile, M.T., S.M. Recupero, D. Palladino, M. De Stefanis, S. Abdolrahimzadeh, F. Suppressa, and C. Balacco Gabrieli, A new method of biofeedback in the management of low vision. *Eye (Lond)*, 2002. 16(4): p. 472-80.
16. Thuangtong, A., P. Samsen, N. Ruangvaravate, and C. Supiyaphun, Visual prognostic value of ocular electrophysiology tests in corneal transplantation. *J Med Assoc Thai*, 2012. 95 Suppl 4: p. S50-5.
17. Motlagh, M.N., M. Moshirfar, M.S. Murri, D.F. Skanchy, H. Momeni-Moghaddam, Y.C. Ronquillo, and P.C. Hoopes, Pentacam® Corneal Tomography for Screening of Refractive Surgery Candidates: A Review of the Literature, Part I. *Med Hypothesis Discov Innov Ophthalmol*, 2019. 8(3): p. 177-203.
18. Kanavi, M.R., M.A. Javadi, and M. Sanagoo, Indications for penetrating keratoplasty in Iran. *Cornea*, 2007. 26(5): p. 561-3.
19. Zare, M., M. Javadi, B. Einollahi, F. Karimian, A. Rafie, S. Feizi, and A. Azimzadeh, Changing indications and surgical techniques for corneal transplantation between 2004 and 2009 at a tertiary referral center. *Middle East African Journal of Ophthalmology*, 2012. 19(3): p. 323-329.
20. Eidizadeh, M., L. Ebadi-Soflou, and A.S. Khoushabi, Indications for penetrating keratoplasty in Iranian patients. *Oman Journal of Ophthalmology*, 2021. 14(3): p. 144.
21. Dobbins, K.R., F.W. Price, Jr., and W.E. Whitson, Trends in the indications for penetrating keratoplasty in the midwestern United States. *Cornea*, 2000. 19(6): p. 813-6.
22. Szkodny, D., E. Wróblewska-Czajka, A. Wylęgała, and E. Wylęgała, Indications and techniques of corneal transplants performed in one center in Southern Poland, in the years 2001–2020. *PloS one*, 2022. 17(11): p. e0276084.
23. Gupta, P.K., A. Bordelon, D.T. Vroman, N.A. Afshari, and T. Kim, Early outcomes of Descemet stripping automated endothelial keratoplasty in pseudophakic eyes with anterior chamber intraocular lenses. *American journal of ophthalmology*, 2011. 151(1): p. 24-28.
24. Feizi, S., M.A. Javadi, M. Najafi, M. Abolhosseini, and S.-M. Moshtaghion, Outcomes of big-bubble deep anterior lamellar keratoplasty for pediatric keratoconus. *International ophthalmology*, 2020. 40: p. 1253-1259.