

ORIGINAL ARTICLE

Juxtaposed Atrial Appendage in Congenital Heart Diseases: Evaluation by multi-slice CT a retrospective study.

Doaa M Badawy ^{1*}, Asmaa Alsayed Hasan¹, Asmaa Mohammed Ismail ², Sayed Anwar Sayed³, S Romeih⁴.

1 Department of Human Anatomy and Embryology, Faculty of Medicine, Aswan University

2 Department of Pediatric, Faculty of medicine, Aswan University

3 Department of Human Anatomy and Embryology, Faculty of Medicine, Assuit University

4 Department of Cardiology, Faculty of medicine, Tanta University

ABSTRACT

<p>Keyword: JAA, Cardiac anomalies, CT, Complex CHDs.</p> <p>*Corresponding author: Doaa Muhammed Mahmoud Badawy</p> <p>E-mail: doaamammed87@gmail.com.</p> <p>Mobile: 01111875996</p>	<p>Background: A rare congenital cardiac anomaly is a juxtaposition of atrial appendages; JAA is a marker for cyanotic CHDs. The study aims to describe and detect the incidence of JAA in congenital heart disease and if there is an association between its presence and the complexity of CHDs. Patients and Methods: a retrospective, cross-sectional, single-center analysis of all patients diagnosed with congenital heart disease who underwent MSCT examination in Aswan Heart Center from 2012 to March 2021. Results: Our study included 2029 patients with CHD, 70 (3.5%) had JAA and 1959 (96.5%) had normal arrangement of atrial appendage The majority of patients diagnosed as transposition of great arteries (TGA); were 24 patients, followed by 18 patients diagnosed as double outlet right ventricle (DORV), 9 patients diagnosed as tricuspid atresia (TA), 9 patients diagnosed as tetralogy of Fallot (TOF), 5 patients of JAA associated with DIL, finally 5 patients of JAA associated with simple CHD. Conclusion: JAA was diagnosed in 3.5 % of patients referred for MSCT; Left-JAA is more frequent than right-JAA The lesion-specific incidences and associated lesions were similar to previous studies. The presence of JAA on MSCT angiography associated with several cyanotic CHDs.</p>
--	--

INTRODUCTION

JAA is described as two atrial appendages that are close to each other rather than encircling the roots of the major arteries and is present in 0.28–1.1% ¹

Developmentally, it's a consequence of ectopic origin of the atrial appendage ². Right-JAA is created during cardiac embryogenesis when the left-sided appendage comes to sit on the right of the vascular pedicle due to excessive torsion of the cardiac tube, while under torsion leads to left-JAA ³

Dixon's original classification of JAA is based on how close or far away from the main arteries. Depending on whether both appendages are located on the left or right of the great arteries, it focuses primarily on the anatomical positions of the appendages and ignores their morphology, whereas Van Praagh's classification took into account these appendages' morphologies and discovered that the right appendage is broad, triangular, and more trabeculated, while the left one is

thin, slender, and finger-like.^{4, 5} Furthermore, when it comes to situs inversus and in heterotaxy syndromes, morphological definition beats Dixon's classification⁶.

JAA serves as a marker for cyanotic CHDs⁷. With a 6:1 incidence rate, left-JAA is more common and associated with more distorted anatomy than right-JAA.⁸

Left-JAA associated with complex cardiac anomalies, most commonly with transposition of great arteries (TGA) and these patients are likely to have coexistent right ventricular inflow stenosis or atresia², while obstruction of the left atrial outlet or the aortic outflow tract is more frequently linked to right-JAA⁶.

PATIENT AND METHODS

Study site and population: The study is a retrospective, cross-sectional, single-center analysis of all patients diagnosed with congenital heart disease who underwent MSCT examination in Aswan Heart Center from 2012 to March 2021.

MSCT examination: The examination was performed with retrospective ECG gating and tube modulation to reduce the radiation dose.

Image analysis: MSCT data sets were evaluated using axial, sagittal, coronal, and interactive multi-planar reconstructions as well as maximum intensity projections and interactive volume-rendering images were generated in ventricular diastole. The presence, type, and location of atrial appendages were recorded.

- 1. Juxtaposed atrial appendage:** A review of the axial images was the most important step in image analysis with a thorough presence, type, and spatial position of JAA. The location was characterized as based on an atrial wall (superior, inferior, right lateral, or left lateral wall) and further subdivided into anterior, posterior, superior, or inferior position at the respective wall where applicable. The appendages were analyzed in terms of form. A complete form was considered present when the entire appendage was juxtaposed, while a partial form was recognized when the appendage exhibited a bifid configuration with part of the appendage, usually of small size, in the normal position and part in juxtaposed position⁹.
- 2. Congenital heart disease presented with JAA:** The MSCT examinations were evaluated for the presence of any other congenital abnormality.

Statistical analysis: Data were presented as number, percentage

RESULTS

Our study included 2029 patients with CHD, 70 (3.5%) had JAA and 1959 (96.5%) had normal arrangement of atrial appendage. From those 70 patients with JAA; 15 (21.4 %) had Rt. JAA, 55 (78.6 %) had left-. JAA. In addition to the sidedness of JAA as right & left-JAA, there is another classification according to the form into complete and partial JAA. In our study there were 32 (45.7 %) with complete form, and 38 (54.3%) with partial form.

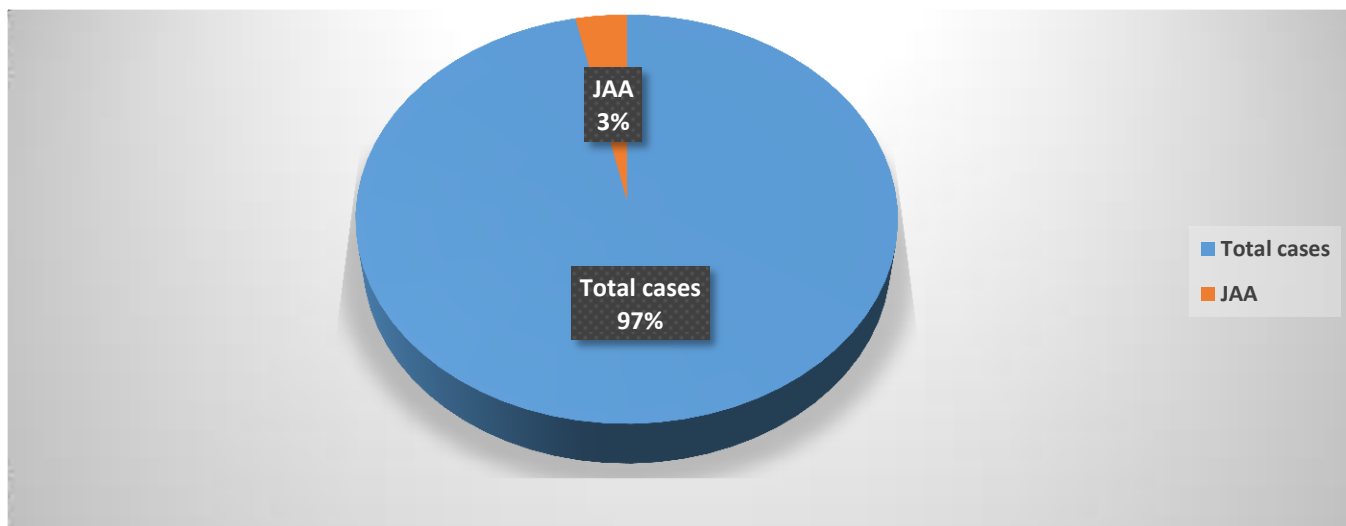


Figure (1): Incidence of JAA

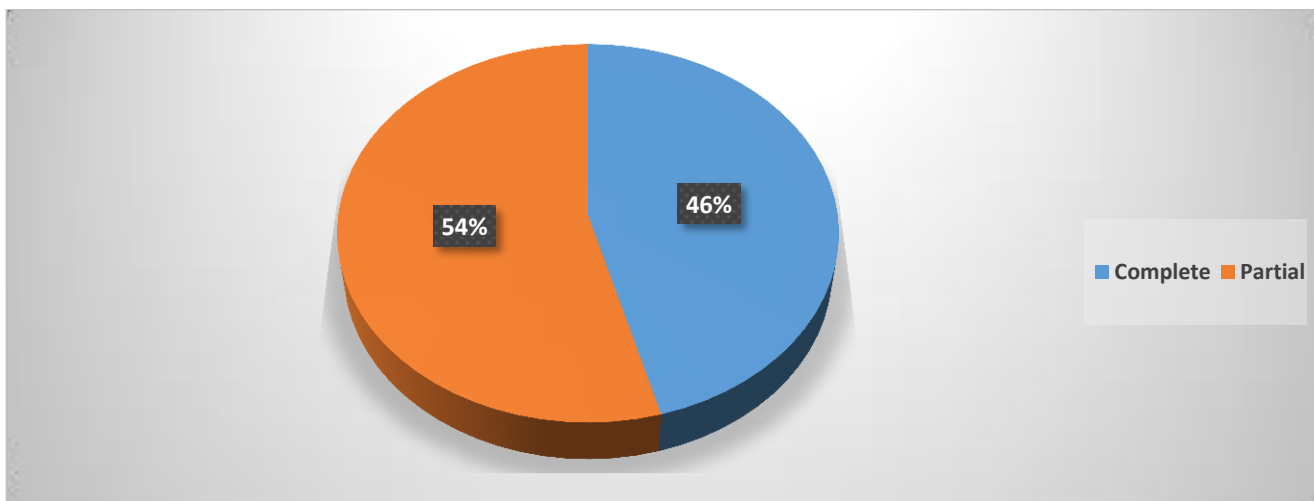


Figure (2): Ratio between complete & partial JAA

Majority of patients diagnosed as transposition of great arteries (TGA); they were 24 (34.3%) with JAA diagnosed as TGA, followed by 18 (25.7%) diagnosed as double outlet right ventricle (DORV), 9 (12.9%) diagnosed as tricuspid atresia (TA), 9 (12.9%) diagnosed as tetralogy of Fallot (TOF), 5 (7.1%) of JAA associated with DIL, finally 5 (7.1%) of JAA associated with simple CHD.

Table (1): JAA associated with diagnosis

Number of patients	Diagnosis	JAA
TGA (24 patients)		
10	TGA with VSD and PS	9 patients left-JAA-Partial 1 patient right-JAA-Complete
10	D TGA with VSD	6 patients left-JAA-Partial 4 patients left-JAA-Complete
4	Isolated TGA with intact ventricular septum (IVS)	4 patients left-JAA-Complete
DORV (18 patients)		

11	DORV mal-posed great vessels with pulmonary stenosis	2 patients right-JAA-Partial 4 patients left-JAA-Partial 5 patients left-JAA-Complete
4	DORV with pulmonary atresia	1 patient left-JAA-Partial 3 patient left-JAA-Complete
3	DORV with mal-posed great vessels (Taussing bing Anomaly)	2 patient left-JAA-Complete 1 patient left-JAA-Partial
Tricuspid atresia (9 patients)		
6	TA with TGA	4 patients left-JAA-Complete 2 patients left-JAA-Partial
1	TA with normal related GV	1 patient left-JAA-Complete
2	TA with congenitally corrected TGA	2 patients left-JAA-Complete
TOF (9 patients)		
8	TOF	7 patients right- JAA-Partial 1 patients right-JAA-Complete
1	TOF with common atrioventricular canal (CAVC)	1 patient right-JAA-Partial
Single ventricle (5 patients)		
5	Double outlet left ventricle (DILV)	3 patients left-JAA-Complete 2 patients left-JAA-Partial
Isolated simple cardiac defect (5 patients)		
1	Bicuspid aortic valve (BAV)	Right-JAA-Partial
1	Patent ductus arteriosus (PDA)	Right-JAA-Complete
1	Atrial septal defect (ASD)	Right-JAA-Complete
1	Dextrocardia	Left-JAA-Complete
1	Common atrioventricular canal (CAVC)	Left-JAA-Partial

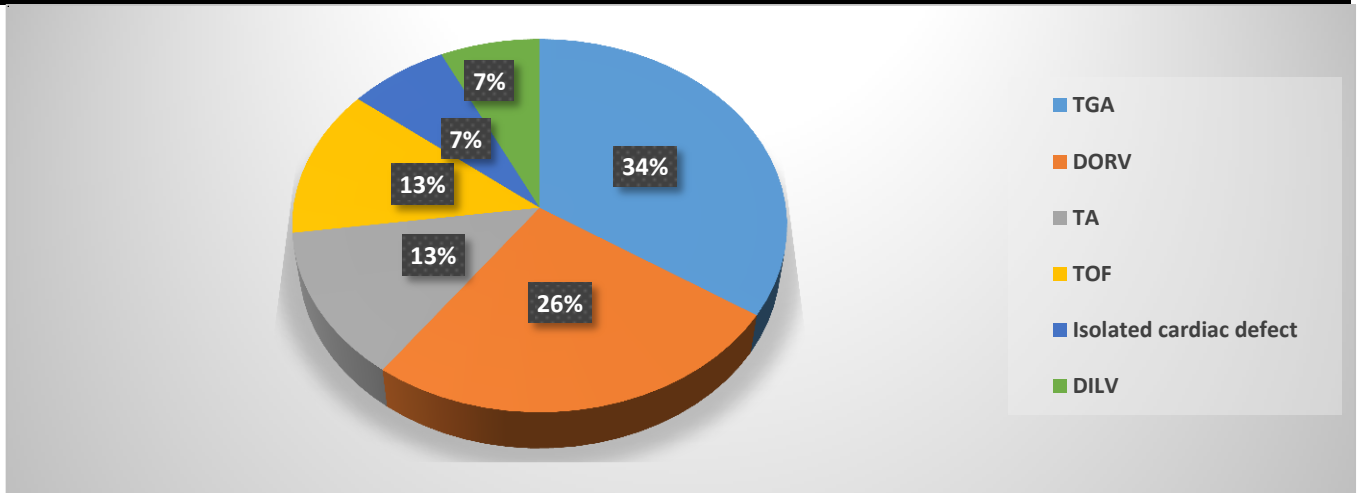


Figure (3): JAA associated congenital anomalies

DISCUSSION

The most common JAA-associated conotruncal anomaly in our study was TGA (24/70) (34.3%); (TGA with VSD and PS; D TGA with VSD; isolated TGA with IVS); followed by DORV (18/70) (25.7%); (DORV mal-posed great vessels with PS; DORV with PA; DORV with mal-posed great vessels (Taussing bing anomaly); then, TOF (9/70) (12.9%); and TA (9/70) (12.9%), DILV (5/70)

(7.1%). Our research on outflow tract abnormalities was comparable to earlier autopsy, echocardiography, and MDCT studies.^{1, 3, 5, 7, 8, 10, 11, 12, 13, 14}

Mehlhuish and Van Praagh¹⁰ discussed CHDs associated with JAA; they noted complete TGA, with dextro-transposition of the great arteries (d-TGA) ranking first and occurring in 50% to 90% of cases; they also noted TA, which occurred in 30% to 40% of cases respectively; their findings were higher than ours because we reported TGA and TA associated with JAA in proportions of 34.3% and 12.9%, respectively. JAA is frequently observed in hypoplastic RV and bilateral conus, according to other reports. A CAVC was the only abnormality that was less prevalent, which is consistent with our findings as we only reported one incidence of CAVC.

Becker, Becker¹¹ in most cases reported, JAA was accompanied by TGA and ventricular inversion. Mathew et al.³ reported that JAA commonly associated with anomalies include VSD (88%), ASD (78%), bilateral conus (77%), small or absent RV (71%), and pulmonary or aortic outflow obstruction (52%, 38%). Their finding was higher than ours as we reported DORV (25.7%); DILV (7.1%).

Left-JAA, on the other hand, is associated with CHDs such as TA, complex DORV, and single ventricle⁸. This is in our agreement as all cases of TA and single ventricle, and most cases of DORV are associated with left-JAA. Oku et al.¹² reported that the most commonly associated conotruncal anomalies are TGA, and DORV, their findings were in accord with ours as the commonest conotruncal anomalies are TGA, followed by DORV respectively. Also, they reported anatomically corrected malposition of the great arteries, and JAA was found in 42% of cases of ACMGA. In our series, no such correlation was found.

In 35 postmortem cases of left-JAA, Van Praagh et al.⁵ found that outflow tract abnormalities were present in 100% of cases, TGA was present in 18/35% of cases, DORV was present in 10% of cases, and transposed aorta with pulmonary atresia was present in 4% of cases. In addition, they noted 7 cases of aortic/subaortic stenosis or atresia, 12 cases of left atrial outlet obstruction, including mitral atresia, and right-JAA. In our series, no such correlation was found. In contrast, the right-JAA is usually connected with the normal segmental layout in the study by Anjos et al.¹³, which was detected in (3) cases, the DORV in (2) cases, and the double inlet right ventricle in (2) cases.

Frescura and Thiene⁷ found 15 cases of left-JAA, with complete TGA having the highest occurrence (60%) and TA coming in second (33%); dextro-mesocardia was present in 46 cases, and hypoplastic RV was seen in 73 cases. They reported two right-JAA cases, one with mitral and pulmonary atresia and the other with LAI, aortic atresia, and DORV. Their outcomes were higher than ours, with TGA (34.3%), TA (12.9%), Dextrocardia (22.9%), and DILV (7.1%). On contrary, Anjos et al.¹³ reported 49 hearts with JAA; the common malformations were TA (39%), complete TGA (30%), and DORV (17%). Similarly, Lai et al.¹ reported that 22 patients with JAA were diagnosed on echocardiography. The highest incidence of JAA was found in the TA lesion, followed by DORV, TGA, and dextrocardia. In 77.3% of JAA cases, abnormal conotruncal anatomy was present, but only in 93.3% (14/15) of patients with left-JAA and only in (3/7) of those with right-JAA. 36.4% of JAA cases had atrial outlet obstruction, including 40% (6/15) of left-JAA patients and 2.7% of right-JAA patients. Atrioventricular situs-alignment disharmony was evident in more patients with right-JAA (3/7) than with left-JAA (1/15), suggesting that right-JAA was more frequently linked with complex atrioventricular architecture. Those previous results are not in accord with ours; TGA (34.3 %), DORV (25.7 %), and TA (12.9 %).

Recently, 129 cases of JAA were reported by Verma et al.¹⁴. DORV, which was present in 58.1% (75/129) of the patients in their series, was the most frequent outflow tract malformation, followed by TGA, which was present in 20.1% (25/129) of the patients, Transposed aorta with Pulmonary Atresia, which was present in 19.4% (25/129) of the patients, and TOF, which was present in

0.77% (1/129) of the patients. Other birth defects were dextrocardia (19.4%) (24/129), hypoplastic RV (38.8%, 50/129), and TA (31.8, 41/129). DORV (60.5%), TGA (20.2%), and transposed aorta with pulmonary atresia (18.5%) are more common than left-JAA outflow tract malformations (100%) and left-JAA abnormalities in general. Outflow tract abnormalities, DORV, transposition of the aorta with pulmonary atresia, and TOF are more common in right-JAA (40%) than in left-JAA. Three patients (3/129) (2.3%) had a double inlet left ventricle. Those results are higher than ours as we reported DORV (25.7 %), TA (12.9%), but lower than ours TGA (34.3 %), Dextrocardia (22.9 %), TOF (12.9%), DILV (7.1%).

We noted all cases that diagnosed as DILV in ours and in study by Verma et al. associated with left-JAA. We reported (9/70) cases of TOF (12.9%); we noted (8/9) of these patients of right-JAA type only one patient with LJAA type. Also, we noted all TOF cases of partial-JAA

The embryological origin of the anomalies that make up TOF is a misalignment of the outflow tract and the ventricles in the primitive heart. Due to the misalignment, the aortic root then overrides the inter-ventricular septum which fail to fuse, creating a VSD^{15, 16, 17}. The outflow tract becomes narrow due to both the misalignment factor as well as hypertrophy of the septo-parietal trabeculations^{17; 18}. This could explain the association of TOF with partial right-JAA; possibly there is a link between the embryological origin of TOF and right-JAA; as we know atrial appendages are located on either side of the arterial pedicle, encircling the great arteries. Normally; the left border of the right ventricular outflow tract or the superior lateral aspect of the pulmonary trunk is overlapped by the pointed tip of the LAA, which has a flattened, tubular structure with crenellations and points on either end^{19, 20}. In TOF; the aortic root is positioned further towards the right than in a normal heart (dextroposition) and the aortic valve is rotated clockwise which may be in turn pulls the tip of the left appendage and partially displaces the LAA to the right side, which may explain the strong association between TOF and partial-right-JAA.

The association of JAA to conotruncal anomalies could be explained by linking opinions given on the development of JAA with the embryological pathogenesis of conotruncal anomalies. As conotruncal anomalies are regarded as the consequence of impaired development of the outflow portion of the embryonic heart loop. Two main theories on the pathophysiology of TGA have been put are based on embryology and human autopsy findings. One concentrates on the OFT's rotating movement, while the other is concerned with its septation.

DORV and TGA are caused by the arrest or inversion of the OFT rotation, which is caused by hypoplasia or dysplasia of the subpulmonic conus in conjunction with an enlargement or persistence of the subaortic conus.^{5, 21, 22} Also, defective conotruncal rotation is observed in human autopsied hearts with dextroposed aorta including TOF, DORV, and TGA²³.

According to the infundibular theory, Wenner²⁴ supposed left-JAA develops as a result of the underdevelopment of torsion in the primitive cardiac, which coincides with an aberrant persistence of the subaortic conus²¹. This opinion could be supported by Melhuish and Van Praagh (1968) is reported 13 cases of TGA, (7/13) had left-JAA, and (1/13) had right-JAA. Similarly, Charuzi et al.⁹ found that TGA was less commonly associated with right-JAA than with left-JAA (69 to 93 %). Leu et al.²⁵ found that left-JAA is most commonly associated with TGA and these patients are likely to have coexistent right ventricular inflow stenosis or atresia. Even with concordant VA connections, the high prevalence of bilateral or subaortic infundibulum in left-JAA^{26, 27, 28} cannot alone explain this malformation.

In the autopsy series published by Van Praagh and colleagues, they discovered that right-JAA was associated with a hypoplastic LV and a normal conus, whereas left-JAA was seen with a hypoplastic RV and abnormal conus. They speculated that there may be a link between the abnormal conus and underdevelopment of the right ventricular inlet, either atretic or hypoplastic tricuspid valve, or hypoplastic RV, and the displaced RAA to the left.^{5, 10}

This study found the majority diagnosed as TGA (23/24) had left-JAA, representing (96%) of TGA cases, and (1/24) had right-JAA (4%). This may explain the coexistence of TGA with left-JAA. Since the auricles are never juxtaposed during normal development, our findings are in agreement with those of the last-named authors regarding the variety of ventricular and conal anomalies associated with juxtaposition.

JAA is accompanied by other almost predicted anatomical defects rather than being reported as an isolated congenital cardiac deformity²⁹. So, it is of an anatomical curiosity if it is isolated and does not produce a severe hemodynamic disturbance in heart function. Only a few cases of isolated JAA have been reported^{6, 30, 31, 32}. We reported 5 cases of JAA with an isolated, simple congenital cardiac defect; A case of right-JAA with bicuspid aortic valve with aortic stenosis, a case of right-JAA with a large ASD, a case of right-JAA with PDA, a case of left-JAA with dextrocardia, a case of left JAA with CAVC. Previously, Becker et al.¹¹ reported a case with right-JAA with ASD and a bicuspid pulmonary valve. Boutayeb et al.³⁰ reported a case of right-JAA with a bicuspid aortic valve and severe aortic stenosis, Kumar et al.³² reported a case of right-JAA with VSD, and Cleuziou et al.³¹ discovered a case of right-JAA with a VSD. Anderson et al.¹⁸ reported a case of right-JAA with ASD

Additionally, we reported (9/70) cases of JAA had TA (12.9%); we noted all TA cases were of left-JAA type. This could be explained by Lai et al.¹ as in their reported cases of atrial outlet obstruction, the affected atrium was invariably connected to the adjacent appendage.

Cases of JAA that had tricuspid atresia (TA), But even if about 40% of cases of JAA had TA^{10, 13, 25} less than 20% of cases of TA are associated with JAA³⁴ which are consistent with our results as we reported TA associated with JAA (12.9%). Those previous results are contradicted by those done by^{1, 5, 13, 14} as their incidence of cases of JAA had TA was higher than ours. In the study by Anjos et al.¹³ they reported the common malformation was TA (39%) ranked first. Similarly, Lai et al.¹ reported that TA was the lesion with the highest incidence of JAA. Van Praagh et al.⁵ reported TA in (31.4%) of cases. Recently, Verma et al.¹⁴ reported TA in (32.2%) of patients.

Dalldorf et al.,³³ reported left-JAA (38/49) and right-JAA (11/49). Left-JAA was seen in 22% of TA, 6% of d-TGA, 1% of l-TGA, and 5% of DORV.

By linking that opinion to our note, as a result of the presence of TA; the affected atrium is RA, and the corresponding appendage as a result juxtaposed to the left. This opinion could be supported by the following studies that reported 12 cases of right-JAA, 10 cases reviewed by Becker, Becker¹¹, one case each by Wagner et al.²⁹, and Charuzi et al.⁹. TA was not reported in them which agreed with our results that all reported cases of TA had left-JAA. This is in agreement with a study by Dalldorf et al.³³ which reported Left-JAA (38/49); left-JAA was seen in 22% of TA. Another opinion could explain our note; The left-sided juxtaposed position of RAA causes the tricuspid valve annulus to shift leftward, which also resulted in overriding of the tricuspid annulus to the LV–aorta axis.^{1, 25}

CONCLUSION:

JAA was diagnosed in 3.5 % of patients referred for MSCT. Left-JAA is more frequent than right-JAA. The lesion-specific incidences and associated lesions were similar to previous studies.

The presence of JAA on MSCT angiography shows that several cyanotic CHDs are present, especially cono-truncal anomalies. JAA was more commonly associated with cono-truncal anomalies most commonly TGA (34.3%), followed by DORV (25.7%), then equally TA (12.9%) and TOF (12.9%). Finally, DILV (7.1%).

JAA could be associated with simple CHDs (7.1%) and mostly in association with right-JAA type.

In cases of TOF, it's frequently seen in association with partial right-JAA. In cases of TA, it is 100 % to be definitely of left-JAA type.

REFERENCES

1. **Lai WW, Ravishankar C, Gross RP, Kamenir SA, Lopez L, Nguyen KH, Griep RB, Parness IA.** Juxtaposition of the atrial appendages: a clinical series of 22 patients. *Pediatric cardiology.* 2001 Mar; 22:121-7.
2. **Nath MP, Makhija N, Kiran U, Dhawan N, Velayoudam D.** Left juxtaposed atrial appendages in a patient with dextrocardia and tricuspid atresia: TEE images. *Annals of Cardiac Anaesthesia.* 2011 May 1;14(2):150-1.
3. **Mathew R, Replogle R, Thilenius OG, Arcilla RA.** Right juxtaposition of the atrial appendages. *Chest.* 1975 Apr 1;67(4):483-6.
4. **Dixon AS.** Juxtaposition of the atrial appendages: two cases of an unusual congenital cardiac deformity. *British Heart Journal.* 1954 Apr;16(2):153.
5. **Van Praagh S, O'Sullivan J, Brili S, Van Praagh R.** Juxtaposition of the morphologically right atrial appendage in solitus and inversus atria: a study of 35 postmortem cases. *American Heart Journal.* 1996 Aug 1;132(2):382-90.
6. **Singhi AK, Pradhan P, Agarwal R, Sivakumar K.** Juxtaposed atrial appendages: a curiosity with some clinical relevance. *Annals of Pediatric Cardiology.* 2016 May 1;9(2):186-9.
7. **Frescura C, Thiene G.** Juxtaposition of the atrial appendages. *Cardiovascular Pathology.* 2012 May 1;21(3):169-79.
8. **Bakhru S, Gupta P, Patil S, Koneti NR.** Right Juxtaposition of the Atrial Appendages. *Journal of The Indian Academy of Echocardiography & Cardiovascular Imaging.* 2020 May 1;4(2):206-8.
9. **CHARUZI Y, SPANOS PK, AMPLATZ K, EDWARDS JE.** Juxtaposition of the atrial appendages. *Circulation.* 1973 Mar;47(3):620-7.
10. **Melhuish BP, Van Praagh R.** Juxtaposition of the atrial appendages: a sign of severe cyanotic congenital heart disease. *British Heart Journal.* 1968 Mar;30(2):269.
11. **BECKER AE, BECKER MJ.** Juxtaposition of atrial appendages associated with normally oriented ventricles and great arteries. *Circulation.* 1970 Apr;41(4):685-8.
12. **Oku H, SHIROTANI H, YOKOYAMA T, KAWAI J, NISHIOKA T, NORITAKE S, SHINOHARA T, NAKAMURA Y, SUNAKAWA A, OKA H, SAGA T.** Anatomically corrected malposition of the great arteries: case reports and a review. *Japanese Circulation Journal.* 1982 Jun 20;46(6):583-94.
13. **Anjos RT, Ho SY, Anderson RH.** Surgical implications of juxtaposition of the atrial appendages: a review of forty-nine autopsied hearts. *The Journal of Thoracic and Cardiovascular Surgery.* 1990 May 1;99(5):897-904.
14. **Verma M, Pandey NN, Kumar S, Ramakrishnan S, Jagia P.** Juxtaposition of atrial appendages: evaluation of cardiovascular morphology and associated anomalies on multidetector computed tomography angiography. *Journal of Cardiac Surgery.* 2022 May;37(5):1145-52.
15. **Tan JL, Gatzoulis MA, Ho SY.** Aortic root disease in tetralogy of Fallot. *Current opinion in cardiology.* 2006 Nov 1;21(6):569-72.
16. **Bailliard F, Anderson RH.** Tetralogy of fallot. *Orphanet journal of rare diseases.* 2009 Dec; 4:1-0.
17. **Schleich JM, Abdulla T, Summers R, Houyel L.** An overview of cardiac morphogenesis. *Archives of cardiovascular diseases.* 2013 Nov 1;106(11):612-23.
18. **Anderson RH, Weinberg PM.** The clinical anatomy of tetralogy of Fallot. *Cardiology in the Young.* 2005 Feb;15(S1):38-47.

19. **Beigel R, Wunderlich NC, Ho SY, Arsanjani R, Siegel RJ.** The left atrial appendage: anatomy, function, and noninvasive evaluation. *JACC: Cardiovascular imaging.* 2014 Dec;7(12):1251-65.
20. **Ho SY, Cabrera JA, Sanchez-Quintana D.** Left atrial anatomy revisited. *Circulation: Arrhythmia and Electrophysiology.* 2012 Feb;5(1):220-8.
21. **Goor DA, Dische R, Lillehei CW.** The conotruncus: I. Its normal inversion and conus absorption. *Circulation.* 1972 Aug;46(2):375-84.
22. **Anderson RH, Wilkinson JL, Arnold R, Becker AE, Lubkiewicz K.** Morphogenesis of bulboventricular malformations. II. Observations on malformed hearts. *British Heart Journal.* 1974 Oct;36(10):948.
23. **Lomonico MP, Bostrom MP, Moore GW, Hutchins GM.** Arrested rotation of the outflow tract may explain tetralogy of Fallot and transposition of the great arteries. *Pediatric Pathology.* 1988 Jan 1;8(3):267-81.
24. **Wenner O. Beiträge zur Lehre der Herzmißbildungen.** *Virchows Archiv für pathologische Anatomie und Physiologie und für klinische Medizin.* 1909 Apr;196(1):127-68.
25. **Leu MR, Chiu S, Hung CR, Wu MH.** Surgical implications of juxtaposed atrial appendages and the associated anomalies. *The Annals of thoracic surgery.* 1992 Jul 1;54(1):134-6.
26. **Freedom RM, Harrington DP.** Anatomically corrected malposition of the great arteries. Report of 2 cases, one with congenital asplenia; frequent association with juxtaposition of atrial appendages. *British Heart Journal.* 1974 Feb;36(2):207.
27. **Van Praagh R, Pérez-Trevino C, Reynolds JL, Moes CA, Keith JD, Roy DL, Belcourt C, Weinberg PM, Parisi LF.** Double outlet right ventricle {S, D, L} with subaortic ventricular septal defect and pulmonary stenosis: Report of six cases. *The American Journal of Cardiology.* 1975 Jan 1;35(1):42-53.
28. **Thiene G, PA P, Maddalena F, Gallucci V.** Malposizione anatomicamente corretta delle grandi arterie.
29. **WAGNER HR, ALDAY LE, VLAD P.** Juxtaposition of the atrial appendages: a report of six necropsied cases. *Circulation.* 1970 Jul;42(1):157-63.
30. **Boutayeb A, Kenassi F, Bensouda A, Marmade L.** Isolated right juxtaposition of the atrial appendages in adult with bicuspid aortic valve stenosis. *World Journal for Pediatric and Congenital Heart Surgery.* 2017 Sep;8(5):635-6.
31. **Cleuziou J, Kemmer J, Sauer U, Pringsheim M.** Juxtaposition of the atrial appendages in a patient with a simple ventricular septal defect. *JTCVS techniques.* 2021 Jun 1; 7:233-5.
32. **Kumar V, Singh RS, Jaswal V.** Right juxtaposition of atrial appendages with isolated ventricular septal defect. *Eur. J. Anat.* 2019;23(3):223-6.
33. **Dalldorf K, Parness I, Ezon D.** Juxtaposition of the Atrial Appendages: A Large Echocardiographic Series. *Pediatric Cardiology.* 2022 Jun;43(5):1094-103.
34. **Tandon R, Edwards JE.** Tricuspid atresia: a re-evaluation and classification. *The Journal of Thoracic and Cardiovascular Surgery.* 1974 Apr 1;67(4):530-42.