

# Evaluation of the role of endoanal ultrasonography in preoperative assessment of perianal fistula

Abdrabou N. Mashhour, Haitham S. Omar, Ahmed S. Marzouk, Mohamed M. Raslan, Ahmed Farag

Department of General Surgery, Faculty of Medicine, Cairo University, Cairo, Egypt

Correspondence to Abdrabou Nagdy Mashhour, MD, Department of General Surgery, Kasralainy Hospital, Cairo, Egypt  
Tel: +01002682592,  
e-mail: mailto:mashhour24@yahoo.com

**Received** 04 March 2015

**Accepted** 16 March 2015

**The Egyptian Journal of Surgery**  
2015, 34:122–126

## Background

Although anal fistula are encountered commonly in surgical practice and have been studied extensively, some complex forms still continue to represent a difficult surgical challenge for many surgeons. The corner stone and the main aim of treatment for an anal fistula is to permanently eliminate abscess formation and achieve healing at the same time preserving anal function and continence. Therefore, precise preoperative assessment of perianal fistulae is crucial to achieving optimal surgical results.

## Patients and methods

In this prospective comparative study, 60 patients were enrolled during the period from December 2012 to June 2014. Endoanal ultrasonography (EAUS) (two-dimensional/three-dimensional) with or without H<sub>2</sub>O<sub>2</sub> enhancement was used for the preoperative assessment of perianal fistulae and abscesses, and the degree of accuracy and its agreement with the surgical findings were estimated. Primary fistulous tract and its relation to the sphincter complex, side tracts, internal opening, and any associated sepsis were determined by EAUS; the reviewers were blinded to the findings of the assessment.

## Results

In classification of the primary tract, there was agreement between EAUS and surgical findings in 47 of the 60 (78.3%) patients. In terms of the presence of an internal opening, the corresponding figures were 53 (88%) cases. In assessment of the secondary (side) tracts by EAUS, 55 (91.7%) patients were diagnosed accurately. In terms of the diagnosis of the presence or absence of abscess cavity or collection in the cases, EAUS diagnosed 53 (88.3%) patients accurately.

## Conclusion

EAUS with its recent innovations of three-dimensional technique and H<sub>2</sub>O<sub>2</sub> enhancement is an excellent modality when planning for fistula surgery, especially with experienced and well-trained operators.

## Keywords:

endoanal ultrasonography, fistula, hydrogen peroxide, internal opening, primary tract

Egyptian J Surgery 34:122–126  
© 2015 The Egyptian Journal of Surgery  
1110-1121

## Introduction

Inspection and digital examination with or without anesthesia are basic diagnostic methods. However, digital examination may fail to detect complex fistulae or to localize the internal opening. It is now well established that preoperative imaging modalities can alert the surgeon to fistula components that might otherwise be missed [1,2]. Among these modalities are fistulography and computed tomography, which have been disappointing and provide insufficient data for surgery planning; in addition, fistulography has been shown to be inaccurate in many instances. In recent years, MRI has emerged as the leading contender for the preoperative classification of fistula in ano. Endoanal ultrasonography (EAUS) is increasingly being used in the preoperative evaluation of anal fistulae. Initial EAUS evaluation was not satisfactory, [3] but the diagnostic accuracy of EAUS has improved with technical advancements in ultrasonography,

including the use of hydrogen peroxide (H<sub>2</sub>O<sub>2</sub>) as a contrast agent and three-dimensional (3D) image reconstruction [4,5].

The image is no longer limited to the axial plane in 3D-EAUS. Instead, it is possible to cut across any part of the data set in the coronal, sagittal, or oblique plane. This property is expected to be useful in tracing the tract and internal opening [6].

The aim of this work is to evaluate the role of EAUS in the preoperative assessment of perianal fistulae and abscesses through its agreement with the surgical findings as a reference standard.

## Patients and methods

This prospective comparative study included 60 patients who were enrolled from the Colorectal Unit,

General Surgery Department, Kasr Al-Ainy Hospital, Faculty of Medicine, Cairo University, and from referrals from private clinics during the period from December 2012 to June 2014. The inclusion criteria were patients diagnosed with and having symptoms of any type of perianal fistula, whether it was high or low, recurrent or not. Patients with intolerable pain or those in acute pain, or those who could not tolerate or refused to undergo EAUS, and those who did not sign the consent form were excluded from the study. All patients signed a written informed consent before inclusion in the study. The age of the patients included ranged from 18 to 65 years (mean age 39 years); patients of both sexes were included (55 men and five women). Clinical assessment of history [age, occupation, presentation, history of anorectal diseases (e.g. anorectal abscess), history of previous anorectal surgery (e.g. abscess drainage or fistulotomy), ...] and physical examination were performed in all patients to exclude patients who did not fulfill the criteria. A total of 60 patients who were suspected of having fistula in ano were subjected to routine labs and underwent a preoperative digital examination and 10-MHz anal endosonography (BK Medical US Scanner 1202; BK Medical, Herlev, Denmark). Primary fistulous tract and its relation to the sphincter complex, side tracts, internal opening, and any associated sepsis were determined by reviewers blinded to the findings of both assessments. The results obtained were compared with the intraoperative findings as a standard reference to assess the accuracy of each modality. Postoperative antibiotics, analgesics, and sitz baths were prescribed and follow-up was performed on a weekly basis until complete healing of the perianal wound. All scans were performed using the BK Medical Systems Flex Focus 1202 scanner and the BK 2052 probe (BK Medical), which is used in the Kasr Al-Ainy Colorectal Unit. The patient underwent an enema to clear the rectum and after a digital rectal examination, a rigid rotating probe with a 360° radius and an ultrasound frequency between 6 and 16 MHz was introduced into the rectum with the patient in a left lateral position. The probe was then slowly withdrawn so that the pelvic floor and subsequently the sphincter complex could be seen. The diameter of the probe is small enough to minimize any distortion of the anal canal. The ultrasound was performed systematically from the upper third to the lower third of the anal canal. Manual two-dimensional (2D)-EAUS was performed first to confirm the diagnosis, followed by computerized 0.2-mm sections along a 6-cm length, and then the 3D-EAUS image was subsequently reconstructed using specialized software provided by the manufacturer. 3D-EAUS was performed at a frequency of 13 MHz, which provides a focal range of 5–25 mm, an axial resolution of 0.3 mm, and a lateral resolution of 1.2 mm. When the diagnosis

was unclear, examination was repeated while instilling diluted (3%) H<sub>2</sub>O<sub>2</sub> from a 10 ml syringe into a flexible cannula (16–21 G cannula for intravenous injection made in Egypt) through the external opening. Only 44 out of 60 (73.3%) patients underwent H<sub>2</sub>O<sub>2</sub>-enhanced endosonography; the remaining 16 (26.7%) patients did not undergo H<sub>2</sub>O<sub>2</sub>-enhanced endosonography because of either closed external opening or intolerance of the patient to the dye (H<sub>2</sub>O<sub>2</sub>).

#### Two-dimensional ultrasonography

We evaluated the visualization of the internal fistula opening empty or with injection of H<sub>2</sub>O<sub>2</sub>. H<sub>2</sub>O<sub>2</sub> was not injected if the external opening was closed or if the patient could not tolerate the injection, and was used selectively in those with acute sepsis. The primary fistulous tract was classified following a modified Parks classification [7] as:

- (1) Not visualized.
- (2) Intersphincteric: the tract crosses the intersphincteric space without crossing fibers of the external anal sphincter (EAS).
- (3) Low transsphincteric: the tract crosses the EAS or both sphincters in the most distal two-thirds of the anal canal.
- (4) High transsphincteric: the tract crosses both sphincters in the high third of the anal canal.
- (5) Suprasphincteric: the tract crosses the intersphincteric space surrounding the upper edge of the puborectalis.
- (6) Extrasphincteric: the tract is found to be outside the EAS. Other data obtained with this technique were the presence of secondary tracts (linear or circular) and the existence or not of perianal cavities and abscesses.

#### Three-dimensional ultrasonography

A 3D ultrasound was then performed without removing the probe, which allowed us to obtain sagittal and coronal images of the anal canal. We reassessed the site of the internal fistula opening, the primary tract of the fistula, and the possible secondary tracts and abscesses, corroborating and improving the information obtained from the 2D-EAUS. We classified the fistulae using the 3D-US according to their primary tract as follows:

- (1) Not visualized.
- (2) Intersphincteric: the tract crosses the intersphincteric space without crossing EAS fibers.
- (3) Low transsphincteric: affects less than 66% of the EAS.
- (4) High transsphincteric: affects 66% or more of the EAS.

- (5) Suprasphincteric: the tract crosses the intersphincteric space surrounding the upper edge of the puborectalis.
- (6) Extrasphincteric: the tract is found to be outside the EAS. Once the examination was completed, the images were recorded and could be carefully reviewed at any point to obtain the required information (Fig. 1).

**Surgery**

Fistula surgery was performed after investigations had been carried out, with an average time gap of 3–5 days; the surgeons involved were blinded to the EAUS findings.

**Results**

**Demographic and descriptive data**

The study was carried out on 60 patients.

*Sex distribution*

The study included 55 (91.7%) men and five (8.3%) women.

*Age distribution*

Age distribution is as shown in Table 1.

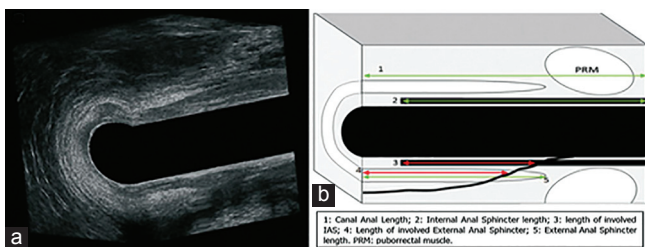
**Clinical data**

At the time of the study, all patients had perianal fistulae because of a cryptoglandular etiology, with no cases with Crohn’s disease.

All types of fistulae were included, whether high or low, recurrent or nonrecurrent cases. The types of fistulae (according to surgical findings) were as follows: 26 (43.3%) patients had intersphincteric fistula, 18 (30%) patients had transsphincteric fistula, nine (15%) patients had suprasphincteric fistula, and seven (11.7%) patients had extrasphincteric fistula (Fig. 2).

Analysis of the results obtained from our study (2013–2014) indicated the following:

**Figure 1**



High posterior transsphincteric fistula. (a) Three-dimensional endoanal ultrasonography (3D-EAUS) image of a sagittal section taken from the left. (b) Diagram of the 3D-EAUS measurements.

*Internal opening*

In terms of the diagnosis of the internal opening of the perianal fistula, our study showed that the EAUS had accurately diagnosed 53 (88.3%) cases out of 60, whereas seven (11.7%) cases were diagnosed inaccurately as shown in (Table 2).

*Main (primary) tract*

With respect to the diagnosis of the main (primary) tract, 47 (78.3%) cases were diagnosed accurately by the EAUS, whereas 13 (21.7%) cases were diagnosed inaccurately as shown in (Table 3).

*Secondary (side) tracts*

In terms of the diagnosis of the secondary (side) tracts by the EAUS, 55 (91.7%) cases were diagnosed accurately, whereas five (8.3%) cases were diagnosed inaccurately as shown in Table 4.

**Table 1 Age distribution**

	N	Minimum	Maximum	Mean	SD
Age	60	18	65	39.53	10.998

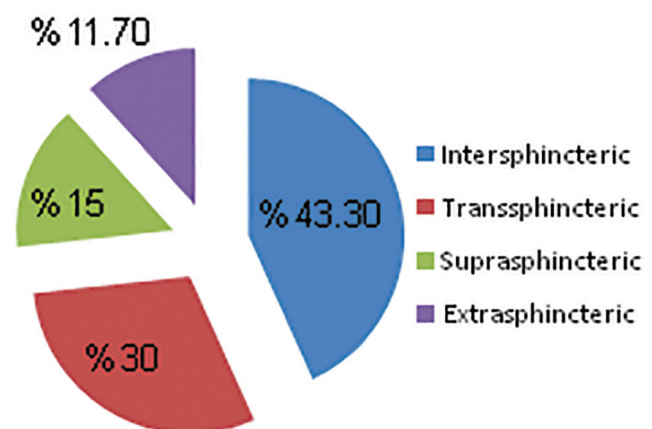
**Table 2 Accuracy of endoanal ultrasonography in the detection of the internal opening**

Valid	Frequency (%)
Inaccurate	7 (11.7)
Accurate	53 (88.3)
Total	60 (100)

**Table 3 Accuracy of endoanal ultrasonography in the detection of the main tract**

Valid	Frequency (%)
Inaccurate	13 (21.7)
Accurate	47 (78.3)
Total	60 (100)

**Figure 2**



Percentage of type of fistulae in the study.

### Abscess cavity (collection)

With respect to the diagnosis of the presence or absence of abscess cavity or collection in the cases, the EAUS diagnosed 53 (88.3%) cases accurately and seven (11.7%) cases inaccurately as shown in Table 5.

## Discussion

Different diagnostic methods are available for the preoperative evaluation of perianal fistulas. Accurate preoperative assessment of perianal fistulas is necessary for planning the most suitable surgical procedure and enables the surgeon to inform the patient of the type of surgery and its possible complications; it also decreases the rates of postoperative recurrence because of missed pathology. Currently, the main techniques used are EAUS and MRI. EAUS is a safe and economical technique that can also be used in patients who cannot undergo MRI because of claustrophobia, obesity, or metallic implants (such as pacemakers). Conventional EAUS has limited value in visualizing fistula tracts. EAUS combined with H<sub>2</sub>O<sub>2</sub> as a contrast medium improves visualization and provides an accurate preoperative assessment of fistulas [8–10].

3D-EAUS is a new technique. 3D-EAUS enables axial images of the anal canal to be reconstructed in the coronal and sagittal planes. The use of 3D images provides more information on the anatomy of anorectal disorders [11].

In 2009, Kim and Park [6] published their study in the *World Journal of Gastroenterology* in which 61 patients were included in this prospective study to evaluate the effectiveness of 3D-EAUS in the assessment of anal fistulae with and without H<sub>2</sub>O<sub>2</sub> enhancement; the results obtained were – as in our study – compared with the operative findings as the reference standard. The results of our study seem

**Table 4 Accuracy of endoanal ultrasonography in the detection of the secondary tract**

Valid	Frequency (%)
Inaccurate	5 (8.3)
Accurate	55 (91.7)
Total	60 (100)

**Table 5 Accuracy of endoanal ultrasonography in the detection of abscess cavity**

Valid	Frequency (%)
Inaccurate	7 (11.7)
Accurate	53 (88.3)
Total	60 (100)

to be in agreement with the results of the study by Kim and Park to a large extent. In their study, the accuracy of 3D-EAUS in detecting the primary tract was 84% (in our study, it was 78.3%); the accuracy in detecting secondary tracts was 81.8% (in our study, it was 91.7%); and the accuracy in detecting localization of the internal opening was 84.2% (in our study, it was 88.3%) [6].

In agreement with our results, Ratto *et al.* [12] carried out a prospective study of 102 patients with primary cryptogenic anal fistula and reported an overall intraoperative concordance rate (with respect to preoperative EAUS) of 94% for the primary tract (78.3% in our study), 91% for the internal opening (88.3% in our study), 96% for the secondary tract (91.7% in our study), and 100% for abscess (88.3% in our study) [12].

Again, our results are very much in agreement with the results of Gustafsson *et al.*'s [13] study published in June 2001, in which 23 patients underwent preoperative 0.5-T body coil MRI and 10 MHz EAUS that included propping in six patients. The results of both techniques were compared against the surgical findings as a reference method [13].

In the classification of the primary tract in Gustafsson *et al.*'s [13] study, there was agreement between EAUS and surgical findings in 14 (61%) cases (in our study it was 78.3%). In terms of the localization of the internal opening, there was agreement in 17 (74%) cases in their study (in our study it was 88%), and in judging the presence of an extension or an abscess, there was agreement in 15 (65%) cases in their study (in our study it was 88.3%).

Finally, similar to any research or study carried out before, we acknowledge that our study may have some limitations. It did not include many patients with complex fistulae; because of low prevalence of high type fistulae or fistulae because of Crohn's disease, it was difficult to draw clear conclusions on how adequate EAUS was in detecting high type or complex fistula.

Another limitation of our study was the involvement of more than one colorectal surgeon in the surgeries of fistula, with different levels of experience and technical approaches, thus influencing the results of the present study. Most previous reports, similar to our study, have considered surgical results as the reference standard. However, surgery as a gold standard has been questioned as studies have shown that EAUS can detect fistula tracts that are not seen on surgical exploration [14].

In our study, we did not use H<sub>2</sub>O<sub>2</sub> (as an enhancing agent in endosonography) in all cases because of technical difficulties or patient intolerance; thus, this may have biased our results to some extent.

## Conclusion

EAUS combined with H<sub>2</sub>O<sub>2</sub> and 3D technique enables greater visualization of perianal fistulas and therefore provides more information than conventional EAUS. Therefore, the EAUS may be considered the preferred examination technique in the study of anal fistulas, especially as EAUS is more economical and can be used in patients who cannot undergo MRI such as in obese patients or patients with metallic implants such as pacemakers or patients known to be claustrophobic.

Other advantages that make the EAUS the modality of choice are its rapidity (takes <10 min) and portability (can be performed in the operating room). Also, no radiation hazards are encountered with EAUS, as in computed tomography or conventional fistulography.

## Acknowledgements

### Conflicts of interest

None declared.

## References

- Buchanan GN, Halligan S, Bartram CI, Williams AB, Tarroni D, Cohen CR. Clinical examination, endosonography, and MR imaging in preoperative assessment of fistula in ano: comparison with outcome-based reference standard. *Radiology* 2004; 233:674–81.
- Lindsey I, Humphreys MM, George BD, Mortensen NJ. The role of anal ultrasound in the management of anal fistulas. *Colorectal Dis* 2002; 4:118–122.
- Choen S, Burnett S, Bartram CI, Nicholls RJ. Comparison between anal endosonography and digital examination in the evaluation of anal fistulae. *Br J Surg* 1991; 78:445–7.
- West RL, Dwarkasing S, Felt-Bersma RJ, Schouten WR, Hop WC, Hussain SM, Kuipers EJ. Hydrogen peroxide-enhanced three-dimensional endoanal ultrasonography and endoanal magnetic resonance imaging in evaluating perianal fistulas: agreement and patient preference. *Eur J Gastroenterol Hepatol* 2004; 16:1319–24.
- Cheong DM, Noguera JJ, Wexner SD, Jagelman DG. Anal endosonography for recurrent anal fistulas: image enhancement with hydrogen peroxide. *Dis Colon Rectum* 1993; 36:1158–60.
- Kim Y, Park YJ. Three-dimensional endoanal ultrasonographic assessment of anal fistula with and without H<sub>2</sub>O<sub>2</sub> enhancement. *World J Gastroenterol* 2009; 15:4810–4815.
- Parks AG, Gordon PH, Hardcastle JE. A classification of fistula-in-ano. *Br J Surg* 1976; 63:1–12.
- Sudol-Szopinska I, Jakubowski W, Szczepkowski M. Contrast-enhanced endosonography for the diagnosis of anal and anovaginal fistulas. *J Clin Ultrasound* 2002; 30:145–50.
- Sloots CE, Felt-Bersma RJ, Poen AC, Cuesta MA. Assessment and classification of never operated and recurrent cryptoglandular fistulas-in-ano using hydrogen peroxide enhanced transanal ultrasound. *Colorectal Dis* 2001; 3:422–6.
- Ratto C, Gentile E, Merico M, Spinazzola C, Mangini G, Sofo L, Doglietto G. How can the assessment of fistula-in-ano be improved? *Dis Colon Rectum* 2000; 43:1375–82.
- West RL, Sloots CE, Felt-Bersma RJ, Kuipers EJ. 3D transanal ultrasonography: better imaging in an extra visualization plain. *Gastroenterology* 2002; 122:A331.
- Ratto C, Grillo E, Parello A, *et al.* Endoanal ultrasound-guided surgery for anal fistula. *Endoscopy* 2005; 37:722–728.
- Gustafsson UM, Kahvecioglu B, Aström G, Ahlström H, Graf W. Endoanal ultrasound or magnetic resonance imaging for preoperative assessment of anal fistula: a comparative study. *Colorectal Dis* 2001; 3:189–97.
- West RL, Zimmerman DD, Dwarkasing S, Hussain SM, Hop WC, Shouten WR, Felt-Bersma RJ. Prospective comparison of hydrogen peroxide-enhanced three-dimensional endoanal ultrasonography and endoanal magnetic resonance imaging of perianal fistulas. *Dis Colon Rectum* 2003; 46:1407–1415.