

Effect of biliary stenting for unextractable choledocholithiasis

Hassan A. Abdallah

Department of General Surgery, Faculty of Medicine, Aswan University, Aswan, Egypt

Correspondence to Hassan A. Abdallah, MD, Department of General Surgery, Faculty of Medicine, Aswan University, Aswan, Egypt. Tel: +20 882 321 117/+20 100 112 1370; fax: 0972430312; e-mail: endoscopyercp@yahoo.com

Received 11 November 2017

Accepted 1 December 2017

The Egyptian Journal of Surgery

2018, 37:104–109

Introduction

Large choledocholithiasis is associated with higher rates of failed extraction with conventional endoscopic techniques. Alternative methods such as electrohydraulic lithotripsy and extracorporeal shock wave lithotripsy, laser lithotripsy, and dissolving solutions can remove 90% of difficult common bile stones. However, these methods are indicated only in special situations and require experience and additional equipment that may not be available in every center.

Aim

The aim of this study was to investigate the efficacy of biliary stenting in the treatment of endoscopically unextractable common bile duct (CBD) stones.

Patients and methods

A total of 46 patients with endoscopically unextractable CBD stones underwent placement of a plastic biliary stent. After 6 months, a second endoscopic retrograde cholangiopancreatography (ERCP) was performed and endoscopic stone removal was again attempted. Differences in stone size and CBD diameter before and after biliary stenting were compared. The complete stone removal rate after treatment was determined.

Results

The second ERCP procedure showed that the bile stone disappeared in 11 (23.91%) patients. Decreased stone size with complete stone removal was achieved in 29 (63.04%) patients. No significant changes were observed in the sizes of CBD stones and stone extraction eventually failed in six (13.04%) patients. Thus, in a total of 40 (87%) patients with unextractable stones, successful stone extraction was performed during the second ERCP.

Conclusion

Temporary biliary stenting has an established place in the management of large CBD stones and can facilitate stone extraction by a basket or a balloon catheter in the second ERCP.

Keywords:

biliary stenting, common bile duct stone, endoscopic retrograde cholangiopancreatography

Egyptian J Surgery 37:104–109

© 2018 The Egyptian Journal of Surgery

1110-1121

Introduction

Common bile duct (CBD) stones are found in ~7–12% patients who undergo cholecystectomy for symptomatic cholelithiasis and are the most common reasons for endoscopic retrograde cholangiopancreatography (ERCP) in the pericholecystectomy setting [1].

They vary in size from rather small (~1–2 mm) to very large (>3 cm). ERCP with endoscopic sphincterotomy and basket or balloon extraction are well-established therapeutic techniques for the treatment of choledocholithiasis [2].

Biliary stenting may be used as a temporizing measure to maintain biliary drainage when extraction techniques have failed to remove CBD stones completely, particularly in frail, elderly, and high-risk patients [3]. Importantly, the short-term use of biliary stenting has been shown to be associated with a reduction in stone size or fragmentation and serves as a bridge treatment to secondary intervention, thereby

leading to successful stone removal at follow-up ERCP [4].

Although several studies have reported that therapeutic ERCP plus stent placement is safe and effective for the elderly, there are still some conflicting results on the effectiveness and safety of this technique in patients with difficult CBD stones. The data are still limited on whether biliary stenting can decrease the size of large CBD stones [5].

Although success rates of removal of CBDs are 85–90%, the large (≥ 15 mm) calculi, the shortness (≤ 36 mm) and narrow angle ($\leq 135^\circ$) of distal CBD, impacted calculi, and anatomical difficulties are factors that contribute toward the failure of endoscopic stone extraction during

This is an open access article distributed under the terms of the Creative Commons Attribution-NonCommercial-ShareAlike 3.0 License, which allows others to remix, tweak, and build upon the work noncommercially, as long as the author is credited and the new creations are licensed under the identical terms.

ERCP [6]. These are known as 'difficult common bile stones' and cannot be removed using standard methods. Alternative methods such as electrohydraulic lithotripsy and extracorporeal shock wave lithotripsy, laser lithotripsy, and dissolving solutions can remove 90% of them. However, these methods are indicated only in special situations and require experience and additional equipment that may not be available in every center. Furthermore, these techniques are not without cost, morbidity, mortality, and significant reduction in quality of life [7].

Many authors have found that stenting, in addition to providing biliary drainage, also has a very positive effect on the size or fragmentation of large or multiple bile duct stones, with a very high percentage of clearance of stones [8].

In this study, we aimed to investigate the efficacy of biliary stenting on the treatment of difficult CBD stones. We attempted to answer the question of whether a transient biliary stenting plays a role in the reduction or fragmentation of large CBD stones.

Patients and methods

This randomized study was carried out at the Department of General Surgery, Aswan University Hospital, Egypt. From October 2015 to January 2017, 46 patients with CBD stones refractory to conventional endoscopic removal, including basket extraction and balloon sweeping, underwent endoscopic placement of a straight plastic biliary stent. Patients stented for other etiologies such as malignant tumors and benign biliary strictures were

not included in the analysis. A difficult CBD stone was defined as a large and impacted CBD stone that could not be removed endoscopically, either by basket or by balloon extraction. Extracorporeal or intracorporeal lithotripsy was not used for stone removal in this study (Fig. 1).

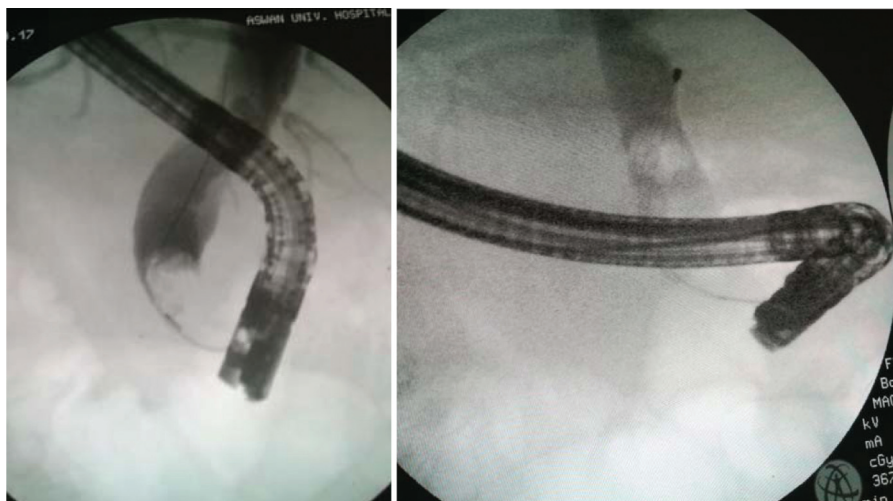
ERCP was performed to all patients under general anesthesia. Endoscopic sphincterotomy was performed in every patient, and basket and balloon extraction was attempted, but failed. In 46 patients, plastic stents were placed for temporary biliary drainage before further endoscopic attempts at duct clearance. The plastic stents were placed extending the proximal end above the stones and with the distal stent end in the duodenum (Fig. 2).

Information on age, sex, comorbidities, number of CBD stones, the largest diameter of the stone, diameter of CBD, and stent sizes was recorded.

After 6 months, a second ERCP was performed. CBD diameter, and CBD stone size and number were measured again for comparison with the values at the initial ERCP. Endoscopic stone removal was attempted again using conventional endoscopic procedures. No oral dissolution agent or associated medications for bile duct stone were prescribed to any patient.

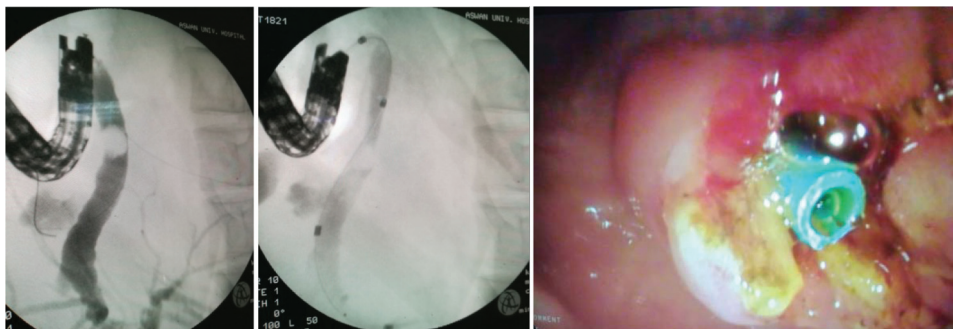
Outcomes were the rate of spontaneous stone passage and the rate of stone extraction after the endoscopic insertion of a biliary stent in patients with unextractable CBD stones. Other factors (e.g. age, sex, the diameter of the largest stone, stone multiplicity, length of the

Figure 1



Cholangiogram showing a large and impacted common bile duct stone that could not be removed endoscopically by basket.

Figure 2



Cholangiogram showing stenting for a large common bile duct stone.

stent, stent diameter, and follow-up period) that may affect the success of stone removal after stent insertion were also investigated.

Statistical analysis

Data were analyzed using the SPSS 23 data program. Stone sizes, diameters of CBDs, stone indices, and differences were analyzed using the Mann–Whitney *U*-test. Receiver operating characteristic curve analysis was carried out to determine the specificity and sensitivity, whereas the χ^2 -test, Fisher's exact test, and univariate and multivariate analyses were used for determination of other data. Values of *P* less than 0.05 were considered statistically significant.

Results

The patients included 11 men and 35 women. The characteristics of the patients, clinical presentations, and concomitant chronic diseases are shown in Table 1.

Endoscopic placement of a biliary plastic stent was successful in all patients. After 6 months of stenting, the second ERCP procedure yielded the following:

- (1) The bile stone disappeared in 11 (23.91%) patients.
- (2) Decreased stone size with complete stone removal was achieved using only the basket and retrieval balloon catheter, without other additional procedures, in 29 (63.04%) patients (Fig. 3).
- (3) No significant changes in the sizes of CBD stones were observed, and the stone extraction eventually failed in six (13.04%) patients, who later underwent elective surgery for CBD exploration and surgical removal of the retained stones.

In terms of the complications of ERCP, only four patients developed complications in the form

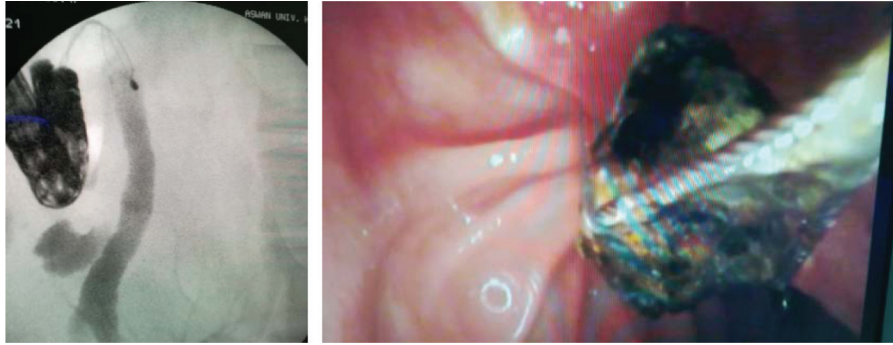
Table 1 Characteristics of patients according to procedure

Characteristics	N=46 [median (minimum–maximum)]
Age (years)	56.0 (33.0–79.0)
Sex [n (%)]	
Male	11 (23.91)
Female	35 (76.08)
Proportion of abnormal LFTs [n (%)]	42 (91.30)
Diameter of CBD (mm)	19 (12–29)
Diameter of stones (mm)	18 (10–29)
Number of stones [n (%)]	
Single	31 (67.39)
Multiple	15 (32.60)
Length of stent (cm)	7 (5–12)
Stent diameter (Fr)	10 (7–10)
Duodenal diverticulum [n (%)]	7 (15.21)
Previous cholecystectomy [n (%)]	9 (19.56)
Comorbidity [n (%)]	
Ischemic heart disease	1 (2.17)
Liver cirrhosis	2 (4.34)
Hypertension	4 (8.69)
Diabetes mellitus	7 (15.21)
Hepatitis	4 (8.69)
Chronic renal insufficiency	3 (6.52)
Pulmonary disease	2 (4.34)
At presentation [n (%)]	
Cholangitis	8 (17.39)
Pancreatitis	2 (4.34)
Post-ERCP complications [n (%)]	3 (6.52)

CBD, common bile duct; ERCP, endoscopic retrograde cholangiopancreatography; LFT, liver function test.

of recurrent cholangitis because of an occluded plastic stent (in three patients) and acute post-ERCP pancreatitis (in one patient). Post-ERCP pancreatitis was completely resolved under conservative medical treatment. Therapeutic ERCP and exchange of the occluded plastic stent were carried out for the treatment of patients with recurrent

Figure 3



Cholangiogram showing decreased stone size with complete stone removal that was achieved using only the basket after 6 months of biliary stenting.

Table 2 Common bile duct stone size changes after biliary plastic stenting in 46 patients

Items	Managed by stenting [n (%)]	Initial size of the stones [median (minimum–maximum)] (mm)	Stones' size poststenting [median (minimum–maximum)] (mm)	P value
Complete disappearance of stone	11 (23.91)	14 (10–17)	0.0	<0.000***
Decreased stone size	29 (63.04)	19 (10–28)	9 (6–13)	<0.001**
Unchanged stones	6 (13.04)	26 (23–29)	26 (23–29)	1

cholangitis before the scheduled stent exchange (Tables 2 and 3).

Discussion

Choledocholithiasis is one of the most common gastrointestinal diseases encountered in clinical therapeutic endoscopy practice. Primary stones are softer than secondary stones, and this difference may increase the chance of endoscopic success in primary calculi [9].

Periampullary diverticula are observed in 15.21% of the patients undergoing duodenoscopy. In patients undergoing ERCP, there are still some conflicting results on whether or not periampullary diverticula affect successful biliary cannulation. However, recent publications support the theory that periampullary diverticula do not decrease the rate of successful endoscopic treatment [10].

It has been reported that the impacted CBD stones and stone sizes are predictive of endoscopic treatment that leads to potential difficulty in bile duct clearance [11]. When assessed according to the success of the treatment, patients with successful endoscopic clearance had fewer percentages of impacted stones than the unsuccessful group, although this was not considered as a factor that affects the treatment success in our study because of the small number of cases.

When CBD stones cannot be removed with conventional endoscopic methods, a temporary

biliary stenting may be inserted to prevent impaction and to provide a bridge for surgical treatment. It has been reported that this method, in addition to providing biliary drainage, also reduces stone size by stent–stone friction force. Mechanical friction between the stone and the plastic stent may cause fragmentation. Because the plastic stent is easily mobile with body movements and gut peristalsis, this friction is more than expected. It is believed that the mechanical grinding of the stones against the biliary stents increases stone fragmentation, reduces the size of the biliary stones, and creates space around and between the stones, potentially facilitating extraction during the second ERCP session. In addition, the powerful stenting drainage could improve the solubility of bile and prevent calcium bilirubinate from precipitating in the bile duct [12].

In a study carried out by Chan *et al.* [13] plastic biliary stents were deployed in 46 patients whose CBD stones could not be extracted during the first ERCP session. However, during the next ERCP session, in 28 (60.9%) of these patients, successful removal of their stones was achieved. This is in agreement with the present study, which indicated that 29 (63.04%) patients showed decreased stone size with complete stone removal during the next ERCP session.

In the present study, we observed that leaving the stent inside the CBD for an average of 6 months resulted in the complete disappearance of stone in 11 (23.91%) of 46 patients. Katsinelos *et al.* [14] reported that CBD

Table 3 Comparison of the characteristics of patients according to the outcome of the study treatment

Characteristics	Successful stone removal (n=40) [median (minimum–maximum)]	Unsuccessful stone removal (n=6) [median (minimum–maximum)]	P value
Age (years)	49 (33–62)	58 (44–79)	<0.04*
Sex [n (%)]			
Male	9 (22.5)	4 (66.67)	<0.000***
Female	31 (77.5)	2 (33.33)	
Proportion of abnormal LFTs	36 (90.0)	6 (100)	0.683 (NS)
Diameter of CBD (mm)	17 (12–24)	22 (16–29)	<0.001**
Diameter of stones (mm)	19 (10–28)	26 (23–29)	<0.02*
Number of stones [n (%)]			
Single	27 (67.5)	4 (66.67)	0.647 (NS)
Multiple	13 (32.5)	2 (33.33)	
Length of stent (cm)	7 (5–12)	7 (5–10)	0.362 (NS)
Stent diameter (Fr)	10 (8.5–10)	10 (7–10)	0.895 (NS)
Duodenal diverticulum	5 (12.5)	2 (33.33)	<0.003*
Previous cholecystectomy	9 (22.5)	0	<0.02*
Comorbidity [n (%)]			
Ischemic heart disease	1 (2.50)	0	<0.04*
Liver cirrhosis	2 (5.0)	0	
Hypertension	3 (7.50)	1 (16.67)	
Diabetes mellitus	5 (12.50)	2 (33.33)	
Hepatitis	3 (7.50)	1 (16.67)	
Renal insufficiency	2 (5.0)	1 (16.67)	
Pulmonary disease	2 (5.0)	0	
Post-ERCP complications [n (%)]			
Cholangitis	2 (5.0)	1 (16.67)	<0.01*
Pancreatitis	1 (2.50)	0	
Impacted stones	5 (12.5)	2 (33.33)	<0.000***

ERCP, endoscopic retrograde cholangiopancreatography; LFT, liver function test.

stones of 11 (44%) of 25 patients were completely removed not in the first, but in the second ERCP procedure. In another study, plastic biliary stents were deployed in 40 patients, and 65 days later, no stones were found in 37 (93%) of 40 patients [15].

Similar to the studies reported by Jain *et al.* [15], we removed the CBD stones of 40 (86.95%) of 46 patients successfully in the next ERCP session.

In our study, a decrease in stone size was observed in 29 (63.04%) patients. When the findings were grouped according to the results of endoscopic treatment, the reduction in the size of the stones and fragmentation was higher in the successful endoscopic treatment group ($P < 0.05$).

Also in agreement with our study, Krishnan *et al.* [16] and Aslan *et al.* [7] also found a significant reduction in stone size ($P < 0.011$ and 0.001, respectively).

Lauri *et al.* [17] reported that stones with less than 10 mm diameter can be removed by conventional endoscopic methods. However, stone extraction is possible in only 12% of patients when

the stone diameter exceeds 15 mm and the chances of successful endoscopic therapy decrease with stone diameters of at least 18 mm. The receiver operating characteristic curve analysis in our study showed that the chance of success of endoscopic therapy may increase in patients with CBD stones with diameters less than 22 mm.

The brown pigment stones were more prominent in the successful endoscopic stone treatment group according to previous stenting. This is in agreement with Li *et al.* [18], who showed that brown pigment stones are soft and are characterized as easily crushed, in contrast to black pigment stones and cholesterol stones, which are often hard and more difficult to reduce in size. Because of these particular features, the brown pigment stones disintegrate easily after the temporary placement of a plastic stent.

In the present study, there were no significance differences ($P > 0.05$) in stent diameter in relation to successful stone removal. This is in agreement with Ye *et al.* [3], who reported no significant stent occlusion for both a 10 Fr stent and a 6–7 Fr stent. Also, even if stent occlusion occurs, stents may still

maintain continuous drainage of the bile duct by a 'wicking' phenomenon, with bile flowing around and between the stents. The other reasons considered in selecting 7 and 8.5 Fr stents were ease of operation and reduced trauma to the bile duct, particularly for elderly, fragile patients. It is known that the plastic stent clog after 3 to 4 months, but the bile duct patency is maintained by passing around the stent. However, it seems to be promising that larger stents (i.e. 10 Fr) may improve outcomes.

Hui *et al.* [19] reported cholangitis in 63.2% of their patients after ERCP. Early complications, including bleeding and pancreatitis, and late complications (mostly cholangitis) were reported in 28 and 34% of patients, respectively, in another study by Ye *et al.* [3]. In a study of 83 patients by Ang *et al.* [20], plastic biliary stenting caused cholangitis, biliary pancreatitis, obstructive jaundice, and biliary colic in 71, 3.6, 21.4, and 3.6% of patients, respectively, during a mean follow-up duration of 19 months (range: 1–103 months).

In the present study, three (6.5%) patients had cholangitis after ERCP: two (5.0%) patients in successful stone removal group and one (16.67%) patient in unsuccessful stone removal group with significance difference ($P < 0.01$). This is in agreement with Consolo *et al.* [21], who reported that the most significant drawback of a biliary endoprosthesis is the risk of recurrent cholangitis, which is reported in 3.5–40% of patients.

The current study did have some limitations similar to those in the other studies that included a limited number of patients. A multicenter study for a larger population should be carried out in the future.

Conclusion

These data suggested that for CBD stones, which are considered to be difficult to remove, temporary biliary stenting within an average of 6 months has an established role in the management of large and multiple CBD stones and will facilitate stone extraction by a basket or a balloon catheter in the second ERCP procedure. It is a minimally invasive and effective method for stone removal in all patients with unextractable CBD stones irrespective of whether they are fit for surgery or not. Endoscopic placement of a biliary stent also functions as a bridge for surgery.

Financial support and sponsorship

Nil.

Conflicts of interest

There are no conflicts of interest.

References

- Darwish OMM, El-Shweikh SA, El-Bedewy MM, Enaba ME. Role of biliary stenting in management of large or multiple common bile duct stones. *Tanta Med J* 2017; 45:51–55.
- Samardzic J, Latic F, Kraljic D, Pitlovic V, Mrkovic H, Miskic D *et al.* Treatment of common bile duct stones – is the role of ERCP changed in era of minimally invasive surgery? *Med Arh* 2010; 64: 187–188.
- Ye X, Huai J, Sun X. Effectiveness and safety of biliary stenting in the management of difficult common bile duct stones in elderly patients. *Turk J Gastroenterol* 2016; 27:30–36.
- Pisello F, Geraci G, Li Volsi F, Modica G, Sciume C. Permanent stenting in 'unextractable' common bile duct stones in high risk patients. A prospective randomized study comparing two different stents. *Langenbecks Arch Surg* 2008; 393:857–863.
- Horiuchi A, Nakayama Y, Kajiyama M. Biliary stenting in the management of large or multiple common bile duct stones. *Gastrointest Endosc* 2010; 71:1200–1203 e2.
- Hong D, Zhu H, Huang K. Endoscopic sphincterotomy plus endoprosthesis in the treatment of large or multiple common bile duct stones. *Dig Endosc* 2011; 23:240–243.
- Aslan F, Arabul M, Celik M, Alper E, Unsal B. The effect of biliary stenting on difficult common bile duct stones. *Prz Gastroenterol* 2014; 9:109–115.
- Joyce AM, Heiss FW. Endoscopic evaluation and therapies of biliary disorders. *Surg Clin North Am* 2008; 88:1221–1240.
- Horiuchi A, Nakayama Y, Kajiyama M, Kato N, Kamijima T, Graham Y, *et al.* Biliary stenting in the management of large or multiple common bile duct stones. *Gastrointest Endosc* 2010; 71:1200–1203.
- Pantheris V, Vezakis A, Filippou G. Influence of juxtaepapillary diverticula on the success or difficulty of cannulation and complication rate. *Gastrointest Endosc* 2008; 68:903–910.
- Lee SH, Park JK, Yoon WJ. How to predict the outcome of endoscopic mechanical lithotripsy in patients with difficult bile duct stones? *Scand J Gastroenterol* 2007; 42:1006–1010.
- Trikudanathan G, Arain MA, Attam R, Freeman ML. Advances in the endoscopic management of common bile duct stones. *Nat Rev Gastroenterol Hepatol* 2014; 11:535–544.
- Chan AC, Ng EK, Chung SC. Common bile duct stones become smaller after endoscopic biliary stenting. *Endoscopy* 1998; 30: 356–359.
- Katsinelos P, Galanis I, Pilpilidis I. The effect of indwelling endoprosthesis on stone size or fragmentation after long-term treatment with biliary stenting for large stones. *Surg Endosc* 2003; 17:1552–1555.
- Jain SK, Stein R, Bhava M. Pigtail stents: an alternative in the treatment of difficult bile duct stones. *Gastrointest Endosc* 2000; 52:490–493.
- Krishnan A, Ramakrishnan R, Venkataraman J. Endoscopic management and role of interim plastic biliary stenting in large and multiple pigmented common bile duct stone. *Euroasian J Hepatogastroenterol* 2013; 3:89–93.
- Lauri A, Horton RC, Davidson BR. Endoscopic extraction of bile duct stones: management related to stone size. *Gut* 1993; 34:1718–1721.
- Li KW, Zhang XW, Ding J, Chen T, Wang J, Shi WJ. A prospective study of the efficacy of endoscopic biliary stenting on common bile duct stones. *J Dig Dis.* 2009; 10:328–331
- Hui CK, Lai KC, Ng M. Retained common bile duct stones: a comparison between biliary stenting and complete clearance of stones by electrohydraulic lithotripsy. *Aliment Pharmacol Ther* 2003; 17:289–296.
- Ang TL, Fock KM, Teo EK. An audit of the outcome of longterm biliary stenting in the treatment of common bile duct stones in a general hospital. *J Gastroenterol* 2006; 41:765–771.
- Consolo P, Scalisi G, Crinò SF, Tortora A, Giacobbe G, Cintolo M, *et al.* Oldest biliary endoprosthesis in situ. *World J Gastrointest Endosc* 2013; 5:356–358.