

# Endovenous radiofrequency ablation of lower extremity varicose veins: short-term outcomes of the initial experience

Ashraf G. Taha, Ahmed H.B. Elbadawy, Ayman E. Hasaballah

Department of Vascular and Endovascular Surgery, Faculty of Medicine, Assiut University, Assiut, Egypt

Correspondence to Ashraf G. Taha, MD, Department of Vascular and Endovascular Surgery, Assiut University Hospitals, 71526 Assiut, Egypt. Tel: +20 100 001 3141; fax: 088 2333327; e-mail: ashraf.g.taha@gmail.com

Received 5 December 2017

Accepted 17 January 2018

The Egyptian Journal of Surgery  
2018, 37:185–190

## Context

Radiofrequency ablation (RFA) has proven acceptable efficacy and safety in the treatment of truncal varicose veins. Faulty technique may, however, result in primary failure or serious complications, especially during the early time points of the surgeon's learning curve.

## Aim

The aim of the present study was to evaluate the safety and effectiveness of RFA procedures in the treatment of great saphenous vein reflux during the initial experience in endovenous thermal ablation.

## Materials and methods

A retrospective review was conducted on 47 patients with varicose veins of clinical, etiological, anatomical, physiological (CEAP) class 2–6 who received RFA at the Department of Vascular and Endovascular Surgery, Assiut University Hospitals, to treat refluxing great saphenous veins between 2014 and 2016. Outcome measures were technical success rate and perioperative complications. Short-term outcomes included complete occlusion of the ablated veins and symptom improvement at 1 year.

## Results

RFA achieved a technical success rate of 97.9%. Perioperative complications were paresthesia (10.6%), ecchymosis (6.4%), phlebitis (6.4%), and hyperpigmentation (2.1%). No skin thermal injuries, hematomas, deep venous thrombosis, or endovenous heat-induced thrombosis were detected.

One-year complete occlusion rate was 87%. Vascular clinical severity score and venous disability score improved at 1 year to  $1.08 \pm 0.85$  versus  $4.03 \pm 1.88$  ( $P < 0.0001$ ) and  $0.60 \pm 0.545$  versus  $1.55 \pm 0.552$  ( $P < 0.0001$ ), respectively, compared with preoperative values. All treated CEAP-6 patients showed complete healing of their ulcers postoperatively.

## Conclusion

RFA is an effective and safe procedure, with satisfactory technical success, closure rates, and symptom improvement. The procedure could be performed in centers with initial experience in endovenous thermal ablation, provided careful commitment to the procedure steps and guiding supervision.

## Keywords:

Initial experience, radiofrequency ablation, varicose veins, venous reflux

Egyptian J Surgery 37:185–190  
© 2018 The Egyptian Journal of Surgery  
1110-1121

## Introduction

Chronic venous disease (CVD) is a common health problem that affects approximately one-quarter of the adult population [1]. The increasing morbidity of untreated varicose vein disease can extend from the usual symptoms such as cosmetic disfigurement, leg pain, and edema to the most serious complications such as bleeding varices and venous ulcers. After decades of considering open surgery [ligation of the saphenofemoral junction (SFJ) and stripping of the great saphenous vein (GSV)] as the sole treatment of venous truncal reflux, the advent of the less invasive endovenous ablation has become the recommended first-line treatment of saphenous vein reflux if the patient is candidate for vein ablation [2–4].

Radiofrequency ablation (RFA) has many advantages over the conventional surgery as it can be safely performed in an office-based setting under local anesthesia with less postoperative pain, faster return to full activity [5], and excellent success rates [6]. RFA, however, has shown to have higher rates of primary failure and superficial thrombophlebitis than surgery [5,7,8], and it may develop serious complications such as skin burns especially during the learning curve of the surgeon's experience [9]. Therefore, the aim of the present study was to evaluate safety and effectiveness of

This is an open access journal, and articles are distributed under the terms of the Creative Commons Attribution-NonCommercial-ShareAlike 4.0 License, which allows others to remix, tweak, and build upon the work non-commercially, as long as appropriate credit is given and the new creations are licensed under the identical terms.

RFA procedures in the treatment of GSV reflux during our initial experience.

## Materials and methods

### Study setting

The present study is a retrospective review of the vascular registry at Assiut University Hospital (a tertiary referral hospital). The study was approved by the Institutional Review Board of the Faculty of Medicine, Assiut University. All study patients were informed and consented to the RFA procedure upon presentation for treatment.

### Patients

The study included all patients with symptomatic lower extremity varicose veins of clinical, etiological, anatomical, physiological (CEAP) [10] class 2–6 who received endovenous RFA at the Department of Vascular and Endovascular Surgery, Assiut University Hospital, to treat refluxing GSVs between 2014 and 2016.

All patients underwent detailed clinical examination at the outpatient clinics to evaluate the severity of symptoms [including a baseline venous clinical severity score (VCSS) and venous disability score (VDS) assessment] [11]. Duplex ultrasound (DUS) examination of the superficial and deep venous systems in both lower limbs was done by the vascular surgeon to measure diameters of the GSV and their reflux time. Patients with suspected abdominal or pelvic venous pathology, deep venous reflux, superficial or deep venous thrombosis, reflux time shorter than 0.5 s, or saphenous vein diameters less than 5 mm or more than 12 mm were excluded from RFA. The study also excluded patients who received previous varicose vein procedures, GSVs that are located within 10 mm distance under the skin, and patients with duplication of the GSV or concomitant reflux in the short or in the anterior accessory saphenous veins.

### Procedural technique

Under direct supervision of experienced vascular surgeons in endovenous thermal ablation, all RFA procedures in the study were performed by vascular surgeons with a recent experience in endovenous thermal ablation. According to our protocol, RFA is done under local infiltration anesthesia in the operating rooms. We do not use a preoperative prophylactic heparinization. While patients are in supine position, an ultrasound (US)-guided puncture to the GSV is achieved percutaneously below or at the knee

level using a micropuncture needle. Over a soft guidewire, a 7-French (F) sheath is secured into the GSV. RFA catheter (ClosureFast; VNUS Medical Technologies, San Jose, California, USA) is advanced from the knee level toward the groin. With the aid of US imaging, the catheter tip is positioned 2–3 cm distal to the SFJ. Tumescence anesthesia (500 ml of 0.9% saline, 50 ml of 1% xylocaine with 1 : 100000 epinephrine, 5 ml of 8.4% sodium bicarbonate 1%) is then injected with a spinal needle around the vein and along the segment to be ablated. The desirable amount of the injected tumescence anesthesia and its precise location in the saphenous compartment are guided by the US imaging.

While the vein is compressed by the DUS transducer probe, the vein is ablated in a groin-to-knee direction. The RF catheter heats a 7-cm segment of the vein to 120° in a 20-second cycle. The most proximal segment is treated with two heating cycles, whereas each distal segment is treated once. At the end of the procedure, a completion US examination of the ablated vein is done to confirm a complete closure of the vein and to exclude any thrombus protrusion into the deep veins. RFA was supplemented with phlebectomy of the small varicosities that were marked preoperatively.

### Postoperative care

At the end of the procedure, a thigh-high class-3 graded compression stocking is applied. The patient is discharged to home on the same day. The patient is advised to ambulate early after the procedure and to use the stocking day and night for 2 days and then by day only for an additional week.

### Follow-up

The first follow-up clinical and DUS examination is typically scheduled on the seventh postoperative day and then after 6 and 12 months postoperatively. Day 7 follow-up is aimed to assess technical success defined as complete ablation of the GSV starting at the 2 cm segment distal to the SFJ till the end of the treated vein with complete absence of color flow Doppler signals.

Partial technical failure is considered when the GSV is completely occluded with a residual patent vein stump of 3 cm or longer distal to the SFJ.

DUS follow-up (sixth and 12th month) examination of the treated vein is categorized into one of the following grades: (1) complete occlusion of the treated vein, (2) asymptomatic recanalization, where the treated vein shows one or more competent recanalization segments without clinical recurrence of varicose veins, (3)

symptomatic recanalization, where the recanalization segment(s) were found to be incompetent or associated with clinical recurrence of varicose vein, and (4) complete recanalization of the treated vein. Finally, 12-month VCSS and VDS assessments for included patients were performed.

### Endpoints

Our primary end point is achievement of total closure of the ablated GSV (technical success). Failure to access the vein percutaneously or to pass the guidewire, or detection of postoperative residual patent vein segment of 5 cm length (or longer) is considered a technical failure and will be excluded from the follow-up analysis. Delayed patency of a vein segment after an initially successful occlusion is considered a recanalization.

Secondary endpoints included complications (sensory affection and wound and skin problems), improvement in VCSS and VDS values, appearance of varicose veins on follow-up, or the requirement for re-intervention to treat residual or recurrent varicose veins.

### Statistical analysis

Statistical analysis was performed using SPSS 24.0 (SPSS Inc., Chicago, Illinois, USA). Descriptive statistics were used, with continuous variables expressed as mean±SD or median and interquartile range, and categorical variables as frequencies and percentages. Student's *t*-test was used to test the difference between the mean of VCSS and VDS score preoperatively and 1 year after the intervention. A value of *P* less than 0.05 was considered to be statistically significant. Freedom from any recanalization or symptom recurrence was assessed by Kaplan–Meier estimation.

## Results

Between March 2014 and March 2016, 44 patients (47 limbs) underwent RFA procedures to treat symptomatic reflux of the GSV. All limbs that needed stab phlebectomies (*n*=22) were performed during the same RFA session. Baseline characteristics and CEAP classification for study patients are shown in Table 1.

Successful GSV closure using RFA was achieved in 46 limbs resulting in a technical success rate of 97.9%. Technical failure occurred in one limb, and the patient was successfully treated with surgical ligation of the SFJ and stripping of the GSV after 5 weeks.

Our perioperative complications (Table 2) included postoperative paresthesia in five (10.6%) limbs,

ecchymosis in three (6.4%), phlebitis in three (6.4%), and hyperpigmentation in one (2.1%). There was no postprocedural deep venous thrombosis, endovenous heat-induced thrombosis (EHIT), pulmonary embolism, or procedure-related mortality. None of the patients experienced postprocedural skin thermal injuries, hematomas, infections, or required hospitalization beyond the day of intervention.

A total of 38 (40 limbs) patients completed the 1-year follow-up. Symptom relief at 1 year was judged by the significant improvement in VCSS and VDS scores as compared with their preoperative values (1.08±0.85 vs. 4.03±1.88, *P*<0.0001, and 0.60±0.545 vs. 1.55±0.552, *P*<0.0001, respectively). All five patients with active venous ulcers showed a complete ulcer healing on follow-up, with a mean ulcer healing time of 2 months.

Follow-up DUS examination was done to the treated limbs to assess the rate of GSV recanalization after

**Table 1 Baseline patient characteristics and distribution according to clinical, etiological, anatomical, physiological classification**

Characters	<i>n</i> (%)
Number of patients (limbs)	44 (47)
Number of bilateral procedures	3
Age (mean±SD) (years)	33.19±8.1
Sex	
Males	26 (59.1)
Females	18 (40.9)
Side	
Right	26 (55.3)
Left	21 (44.7)
GSV diameter (mm)	
Mean±SD	7.85±1.18
Median (IQR)	8 (1)
CEAP class	
Varicose veins (C2)	28 (59.6)
Swelling (C3)	7 (14.9)
Hyperpigmentation and/or lipdermatosclerosis (C4)	6 (12.8)
Healed ulcer (C5)	1 (2.1)
Active ulcer (C6)	5 (10.6)

CEAP, clinical, etiological, anatomical, physiological; GSV; great saphenous vein; IQR, interquartile range.

**Table 2 Periprocedural complications of radiofrequency ablation-treated limbs**

	<i>n</i> (%)
Postoperative paresthesia	5 (10.6)
Ecchymosis	3 (6.4)
Phlebitis	3 (6.4)
Hyperpigmentation	1 (2.1)
Skin burns	0 (0)
Heat-induced deep vein thrombosis	0 (0)
Pulmonary embolism	0 (0)
Mortality	0 (0)

**Table 3 Outcome of radiofrequency ablation-treated limbs on duplex follow-up examination**

Follow-up time point	Number (at risk)	Any recanalization (limbs)	Symptom recurrence	Additional treatment
Seventh day	46	0	0	No
6 months	42	2	1	Foam sclerotherapy
12 months	40	4	2	Foam sclerotherapy

RFA procedures (Table 3). At 6 months, 40 limbs (of 42) continued to have total occlusion of the treated GSV. Of the two GSV recanalizations, one limb was symptomatic with recurrent leg varicosities (Fig. 1) and was successfully treated with duplex-guided foam sclerotherapy. The other limb showed an asymptomatic recanalization of a vein segment that did not require any further treatment.

At 1 year, 36 limbs of the examined 40 limbs maintained a complete closure of the GSV, resulting in a cumulative complete occlusion rate of 87% (Table 3, Fig. 2). Two limbs showed asymptomatic reflux in recanalized vein segments (grade 2) and required no additional treatment. The remaining two limbs showed recurrent varicosities (Fig. 1) owing to recanalization of vein segments (grade 3) and were all treated with duplex-guided foam sclerotherapy.

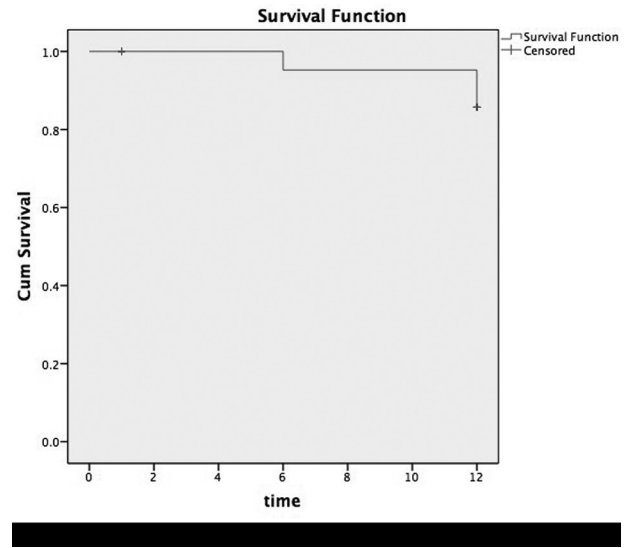
Overall, throughout all time points of follow-up in the study, there were six limbs that were found to have delayed recanalization after an initially successful RFA procedure. Of those, only three limbs that had grade 3 recanalization associated with symptom recurrence and were successfully retreated with duplex-guided foam sclerotherapy.

**Discussion**

Endovenous thermal ablation of incompetent GSV has been met with widespread consideration by vascular interventionists. Newer catheter generations, improved technical expertise, and available patient reimbursement all contributed to increased number of these minimally invasive procedures. The scientific evidence for the treatment of refluxing GSV in patients with CVD strongly recommends endovenous thermal ablation in preference to surgery as demonstrated in clinical practice guidelines of the Society of Vascular Surgery, the American Venous Forum [3], the European Society for Vascular Surgery [4], and NICE guidelines [12].

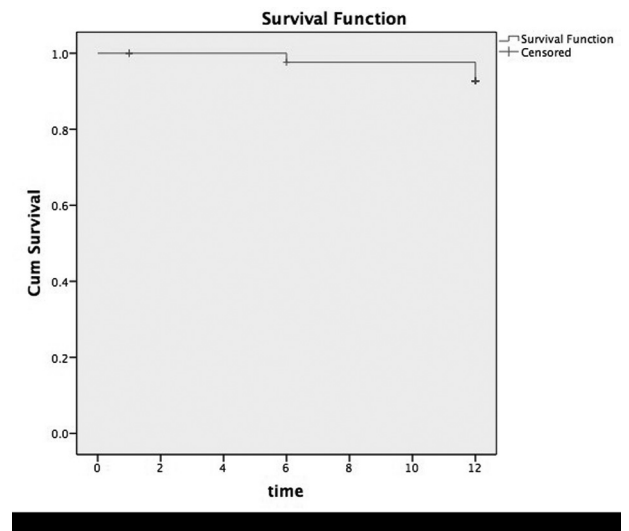
The current study is a retrospective analysis of patients presented with CVD who underwent RFA of incompetent GSV at a tertiary referral hospital. The aim was to evaluate short-term outcomes of this technique performed by interventionists in early time

**Figure 1**



Kaplan–Meier survival curve demonstrating probability of great saphenous vein recanalization associated with symptom recurrence.

**Figure 2**



Kaplan–Meier survival curve demonstrating probability of great saphenous vein freedom from any recanalization.

points of their learning curve. However, all procedures were performed under direct supervision of experienced vascular surgeons.

A total of 47 limbs received RFA treatment of refluxing GSV in the current series. Concurrent phlebectomy

was performed in 22 (46.8%) limbs. Technical success rate was 97.9% (46/47). DUS examination in the follow-up period identified six limbs with grades 2 and 3 recanalization, reporting a 1-year cumulative occlusion rate of 87%. Recurrent varicose veins were observed in three limbs with a 93.5% cumulative rate of freedom from symptom recurrence.

The reported total occlusion rate using the first-generation RFA device ranged from 75 to 92%, with a partial occlusion rate of between 7 and 26% [13–15]. Previous studies demonstrated early occlusion rates of 99.6% using the ClosureFast device in 194 patients [16], 88.7% at 1 year [17], and 92.4% at 180 days [18]. Nicolini reported a total occlusion rate of 81% and varicose vein free rate of 90.1% at 1 year after RFA using the first-generation device in 330 limbs [19].

Of the ablated 47 veins in the current study, one limb failed the RFA procedure and was treated with surgical ligation of the SFJ and stripping of the GSV. Technical failure could be attributed to following a wrong technique or missing steps starting with detailed preoperative duplex vein mapping, ideal catheter positioning with optimal visualization, effective tumescence application around all vein segments, and inadequate limb position trying to empty the vein from blood.

In the current cohort, duplex follow-up demonstrated that recurrent varicose veins were noticed in relation to recanalization of incompetent vein segments with absence of neovascularization at the groin. Few studies described neovascularization as an important risk factor for symptom recurrence following high SFJ ligation and GSV stripping operations that may reach 45% at 2 years [20,21].

Our most frequent complication was paresthesia (10.6%), ecchymosis (6.4%), phlebitis (6.4%), and hyperpigmentation (2.1%). We have not observed any incidents of EHIT or pulmonary embolisms in our patients. Reported EHIT varies from 0 to 16% [22]. Its risk is higher in patients with documented thrombophilia, previous history of DVT, obesity, or old age [22,23]. The newer ClosureFast catheter (VNUS Medical Technologies) and early ambulation were linked to fewer adverse effects [24].

The current study patients demonstrated a significant clinical improvement after RFA as seen with healing of venous ulcers along with the improvement of VCSS and VDS score from  $4.03 \pm 1.88$  to  $1.08 \pm 0.85$ ,  $P$  value less than 0.0001, and from  $1.55 \pm 0.552$  to

$0.60 \pm 0.545$ ,  $P$  value less than 0.0001, respectively. Our results compare favorably with reported results in several studies [25–27].

Our study limitations could be the small sample size and the short follow-up period as we are reporting our initial experience. The retrospective design limited the availability of our retrieved data. We have not included analysis for pain assessment either intraprocedurally or postprocedurally, mean BMI, or for the proximity of the closure level to the SFJ, which is considered as an important factor for EHIT.

## Conclusion

RFA is a simple and safe procedure. The technique is effective with satisfactory technical success and closure rates leading to a significant symptomatic improvement. The procedure could be performed in centers with initial experience in endovenous thermal ablation, provided careful commitment to the procedure steps and the guiding supervision.

## Financial support and sponsorship

Nil.

## Conflicts of interest

There are no conflicts of interest.

## References

- Lattimer CR. CVD: a condition of underestimated severity. *Int Angiol* 2014; 33:222–228.
- O'Flynn N, Vaughan M, Kelley K. Diagnosis and management of varicose veins in the legs: NICE guideline. *Br J Gen Pract* 2014; 64:314–315.
- Gloviczki P, Comerota AJ, Dalsing MC, Eklof BG, Gillespie DL, Gloviczki ML, *et al.* The care of patients with varicose veins and associated chronic venous diseases: clinical practice guidelines of the Society for Vascular Surgery and the American Venous Forum. *J Vasc Surg* 2011; 53 (Suppl 2): S48.
- Wittens C, Davies AH, Bækgaard N, Broholm R, Cavezzi A, Chastanet S, *et al.* Editor's choice – management of chronic venous disease: clinical practice guidelines of the European Society for Vascular Surgery (ESVS). *Eur J Vasc Endovasc Surg* 2015; 49:678–737.
- Rasmussen LH, Lawaetz M, Bjoern L, Vennits B, Blemings A, Eklof B. Randomized clinical trial comparing endovenous laser ablation, radiofrequency ablation, foam sclerotherapy and surgical stripping for great saphenous varicose veins. *Br J Surg* 2011; 98:1079–1087.
- Whiteley MS, Shiangoli I, Dos Santos SJ, Dabbs EB, Fernandez-Hart TJ, Holdstock JM. Fifteen year results of radiofrequency ablation, using VNUS closure, for the abolition of truncal venous reflux in patients with varicose veins. *Eur J Vasc Endovasc Surg* 2017; 54:357–362.
- Helmy ElKaffas K, ElKashef O, ElBaz W. Great saphenous vein radiofrequency ablation versus standard stripping in the management of primary varicose veins – a randomized clinical trial. *Angiology* 2011; 62: 49–54.
- Subramonia S, Lees T. Randomized clinical trial of radiofrequency ablation or conventional high ligation and stripping for great saphenous varicose veins. *Br J Surg* 2010; 97:328–336.
- Woźniak W, Młosek RK, Ciostek P. Complications and failure of endovenous laser ablation and radiofrequency ablation procedures in patients with lower extremity varicose veins in a 5-year follow-up. *Vasc Endovascular Surg* 2016; 50:475–483.

- 10 Porter JM, Moneta GL. Reporting standards in venous disease: an update. International Consensus Committee on Chronic Venous Disease. *J Vasc Surg* 1995; 21:635–645.
- 11 Rutherford RB, Padberg FT, Comerota AJ, Kistner RL, Meissner MH, Moneta GL. Venous severity scoring: an adjunct to venous outcome assessment. *J Vasc Surg* 2000; 31:1307–1312.
- 12 Marsden G, Perry M, Kelley K, Davies AH, Guideline Development Group. Diagnosis and management of varicose veins in the legs: summary of NICE guidance. *BMJ* 2013; 347:f4279.
- 13 Merchant RF, DePalma RG, Kabnick LS. Endovascular obliteration of saphenous reflux: a multicenter study. *J Vasc Surg* 2002; 35:1190–1196.
- 14 Rautio T, Ohinmaa A, Perälä J, Ohtonen P, Heikkinen T, Wiik H, *et al.* Endovenous obliteration versus conventional stripping operation in the treatment of primary varicose veins: a randomized controlled trial with comparison of the costs. *J Vasc Surg* 2002; 35:958–965.
- 15 Pichot O, Kabnick LS, Creton D, Merchant RF, Schuller-Petroviae S, Chandler JG. Duplex ultrasound scan findings two years after great saphenous vein radiofrequency endovenous obliteration. *J Vasc Surg* 2004; 39:189–195.
- 16 Proebstle TM, Vago B, Alm J, Göckeritz O, Lebard C, Pichot O. Treatment of the incompetent great saphenous vein by endovenous radiofrequency powered segmental thermal ablation: first clinical experience. *J Vasc Surg* 2008; 47:151–156.
- 17 Boon R, Akkersdijk GJM, Nio D. Percutaneous treatment of varicose veins with bipolar radiofrequency ablation. *Eur J Radiol* 2010; 75:43–47.
- 18 Braithwaite B, Hnatek L, Zierau U, Camci M, Akkersdijk G, Nio D, *et al.* Radiofrequency-induced thermal therapy: results of a European multicentre study of resistive ablation of incompetent truncal varicose veins. *Phlebology* 2013; 28:38–46.
- 19 Nicolini P, Closure Group. Treatment of primary varicose veins by endovenous obliteration with the VNUS closure system: results of a prospective multicentre study. *Eur J Vasc Endovasc Surg* 2005; 29:433–439.
- 20 Jones L, Braithwaite BD, Selwyn D, Cooke S, Earnshaw JJ. Neovascularisation is the principal cause of varicose vein recurrence: results of a randomised trial of stripping the long saphenous vein. *Eur J Vasc Endovasc Surg* 1996; 12:442–445.
- 21 De Maeseener MG, Ongena KP, van den Brande F, van Schil PE, de Hert SG, Eyskens EJ. Duplex ultrasound assessment of neovascularization after saphenofemoral or sapheno-popliteal junction ligation. *Phleb J Venous Dis* 1997; 12:64–68.
- 22 Mozes G, Kalra M, Carmo M, Swenson L, Gloviczki P. Extension of saphenous thrombus into the femoral vein: a potential complication of new endovenous ablation techniques. *J Vasc Surg* 2005; 41:130–135.
- 23 Geerts WH, Bergqvist D, Pineo GF, Heit JA, Samama CM, Lassen MR, *et al.* Prevention of venous thromboembolism: American College of Chest Physicians Evidence-Based Clinical Practice Guidelines (8th edition). *Chest* 2008; 133 (Suppl 381):S453.
- 24 Van Rij AM, Chai J, Hill GB, Christie RA. Incidence of deep vein thrombosis after varicose vein surgery. *Br J Surg* 2004; 91:1582–1585.
- 25 Marston WA, Owens LV, Davies S, Mendes RR, Farber MA, Keagy BA. Endovenous saphenous ablation corrects the hemodynamic abnormality in patients with CEAP clinical class 3-6 CVI due to superficial reflux. *Vasc Endovascular Surg* 2006; 40:125–130.
- 26 Almeida JI, Kaufman J, Göckeritz O, Chopra P, Evans MT, Hoheim DF, *et al.* Radiofrequency endovenous ClosureFAST versus laser ablation for the treatment of great saphenous reflux: a multicenter, single-blinded, randomized study (RECOVERY study). *J Vasc Interv Radiol* 2009; 20:752–759.
- 27 Jin HY, Ohe HJ, Hwang JK, Kim SD, Kim JY, Park SC, *et al.* Radiofrequency ablation of varicose veins improves venous clinical severity score despite failure of complete closure of the saphenous vein after 1 year. *Asian J Surg* 2017; 40:48–54.