

Local tongue flap for posterolateral tongue defects after partial glossectomy: a prospective cohort study

Mahmoud G. Hagag, Mahmoud A. Shahin, Asem Fayed, Ahmed F. El-Kased

Department of General Surgery, Faculty of Medicine, Menoufia University, Shebeen El-Kom, Egypt

Correspondence to Mahmoud G. Hagag, MD, Department of General Surgery, Faculty of Medicine, Menoufia University Hospitals, Shebeen El-Kom, 32511, Egypt; Tel: 048 2222170, 01063040405; e-mail: mahhagag2002@yahoo.com

Received 13 February 2018

Accepted 12 March 2018

The Egyptian Journal of Surgery 2018, 37:344–348

Objectives

Tongue is a common site of squamous cell carcinoma of the oral cavity (OTSCC) with the subsequent high rate of local or regional recurrence owing to the complexity of its structure. In the present prospective study, we aimed to evaluate the novel local tongue flap technique for reconstruction of posterolateral tongue defects after partial glossectomy.

Patients and methods

The present study was approved by the Institutional Review Board of the Menoufia University Hospital. We conducted a prospective cohort study on 17 patients with OTSCC who underwent partial glossectomy. Local tongue flap was performed to reconstruct posterolateral tongue defects after partial glossectomy. Patients were followed for 2 months postoperatively.

Results

Most patients were male (70%), and the mean age of included patients was 57.47±9.53 years. Tumors were locally excised with mean safety margins of 1.06±0.48 cm and 64% of the patients with OTSCC underwent neck dissection. Postoperatively, 82.5% of the patients exhibited a good tongue healing result with adequate tongue function. Three (17.6) patients experienced tongue infection with partial dehiscence, which healed completely after 2 weeks with conservative treatment.

Conclusion

Local tongue flap is an effective technique for reconstruction of posterolateral tongue defects after partial glossectomy.

Keywords:

partial glossectomy, reconstruction, tongue flap, tongue healing

Egyptian J Surgery 37:344–348
© 2018 The Egyptian Journal of Surgery
1110-1121

Introduction

Squamous cell carcinoma of the oral cavity (OSCC) is one of the most commonly encountered malignancies of head and neck, and it accounts for more than 90% of all cases of head and neck cancers [1]. In addition, OSCC is the sixth most common cancer in the world and accounts for nearly 3% of all cancer cases, according to 2017 global cancer statistics [2]. Tongue is a common site of OSCC with the subsequent high rate of local or regional recurrence owing to the complexity of its structure [3]. Surgical removal of the affected side of the tongue, especially with T1 or early T2 carcinoma, remains the main line of management of oral tongue squamous cell carcinoma (OTSCC) [4]. However, reconstruction of the resulted tongue defects through the primary closure of the remaining tongue or skin grafting may result in distorted tongue, and such distortion may significantly lead to defective tongue ability to control food and liquid in the oral cavity, salivary pooling, and speech problems [5].

In the recent years, a novel technique for reconstruction of tongue defects through local

tongue flap has been proposed [6]. The local tongue flap procedure is based mainly on the rotation of the remaining tongue, which offers restoration of a full-bodied mobile tongue. Lam *et al.* [7] described a case with a 2-cm (T2N0M0) squamous cell carcinoma that involved the posterior right lateral border of the tongue, and the sliding anterior hemitongue flap resulted in a full-bodied tongue in the posterior oral cavity with excellent tongue mobility, speech ability, and swallowing.

In the present prospective study, we aimed to evaluate local tongue flap for reconstruction of posterolateral tongue defects after partial glossectomy.

This is an open access journal, and articles are distributed under the terms of the Creative Commons Attribution-NonCommercial-ShareAlike 4.0 License, which allows others to remix, tweak, and build upon the work non-commercially, as long as appropriate credit is given and the new creations are licensed under the identical terms.

Patients and methods

We followed the recommendations of the Strengthening the Reporting of Cohort Studies in Surgery during the preparation of the present prospective study [8].

Ethical approval

The study was conducted in accordance with the International Conference on Harmonization Good Clinical Practice guidelines, the Declaration of Helsinki, and applicable local regulatory requirements and laws. The study was approved by the Institutional Review Board of the Menoufia University Hospital.

Study design and setting

We conducted a prospective cohort study at General Surgery Department, Menoufia University Hospital from May 2013 to January 2016.

Patients

In the present study, we recruited 17 patients who presented with tongue ulcers and were diagnosed with T1 or T2 OTSCC involving the posterior part of the tongue after incisional biopsy. Metastatic workup was done using radiological methods, and neck nodes assessment was done using ultrasound and computed tomography scan. Patients with more advanced lesions (T3 or T4) and those with previous tongue excision procedures were excluded.

Local tongue flap technique

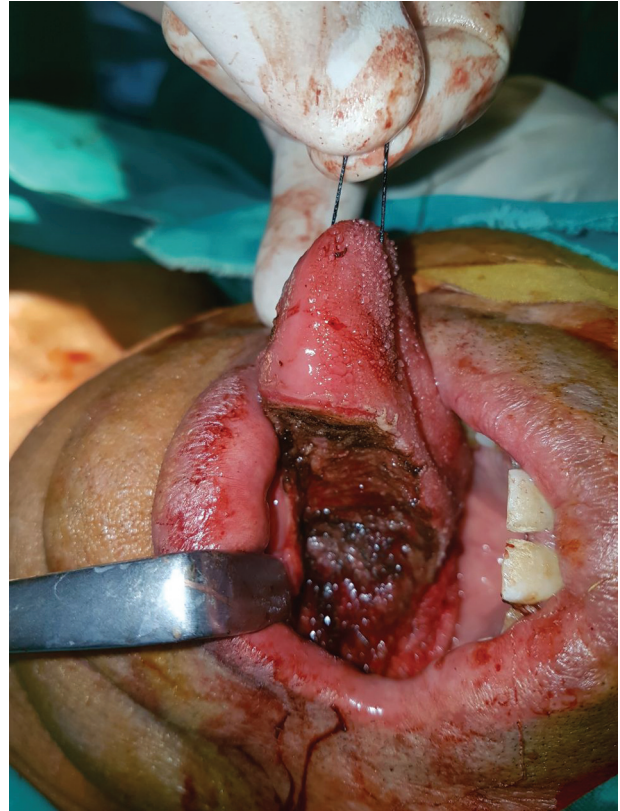
Initially, patients underwent partial hemiglossectomy with adequate margins (≥ 0.5 cm) of mucosa and soft tissue, and neck dissection – if indicated – (Figs. 1 and 2). The remaining usable tongue was divided down through the genioglossus muscle at the median fibrous septum, and the divided part was carried anteriorly (Fig. 3). A curvilinear incision was then extended to the contralateral anterior tongue and the remaining anterior half of the resected tongue was rotated along the curvilinear incision and moved posteriorly to be sutured to the remaining of the posterior part of the tongue. The affected side was sutured to the unaffected side by two layers.

- (1) Division of the remaining tongue along the median septum.
- (2) Preserving the anterior third of the tongue.
- (3) Rotation posteriorly along the curvilinear incision.
- (4) Suturing the flap.

Postoperative assessment

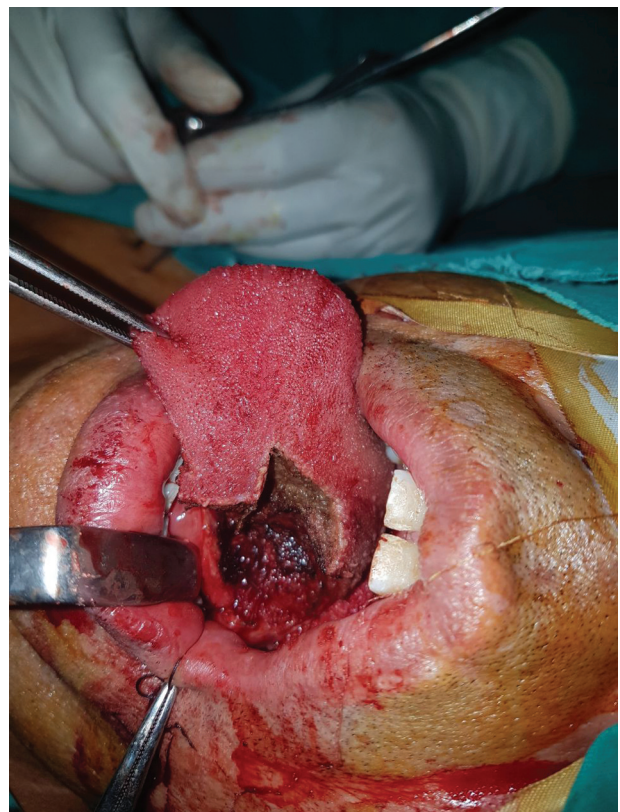
Patients were given fluid on the first day after the operation, followed by soft diet to the end of the first week. The regular feeding was then continued from the

Figure 1



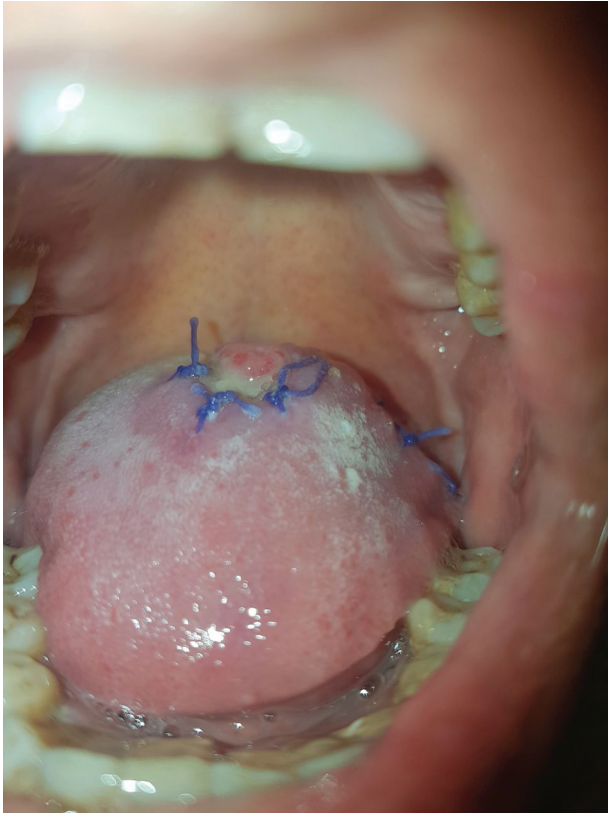
Shows the remaining tongue tissue.

Figure 2



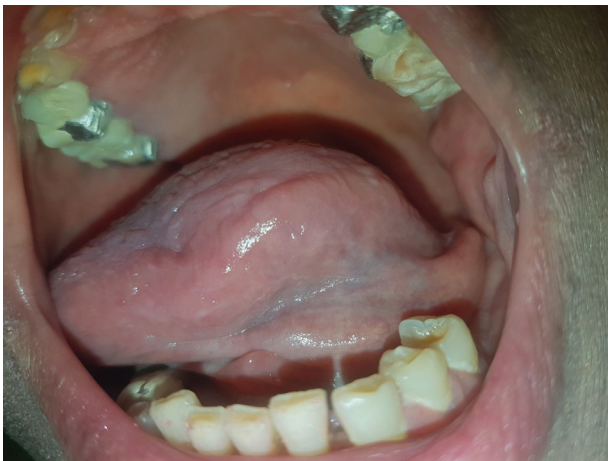Shows splitting of the tongue at lingual septum.

Figure 3



Postoperative after 2 weeks.

Figure 4



Postoperative after 6 months.

beginning of the week 2 (Fig. 4). The included patients were followed postoperatively and assessed for tongue healing and neck complications. The total duration of follow-up was 2 months (Fig. 5), and the patients were assessed at the week 1, week 2, 1 month, and 2 months postoperatively.

Statistical analysis

The statistical analysis was carried with statistical package for the social sciences software (SPSS, version

24; SPSS Inc., Chicago, Illinois, USA). Frequency tables with percentages were used for categorical variables, and descriptive statistics (mean and SD) were used for numerical variables.

Results

The mean age of included patients was 57.47 ± 9.53 years old, and the majority of them were male (70%). Approximately half of them were either smokers or diabetic, and six patients were both smokers and diabetic. The mean tumor size was 2.04 ± 0.85 cm. Tumors were locally excised with mean safety margins of 1.06 ± 0.48 cm. Overall, 64% of the patients with OTSCC underwent neck dissection, and the mean number of the positive lymph nodes was 3 ± 2.13 . Table 1 shows the characteristics of included patients.

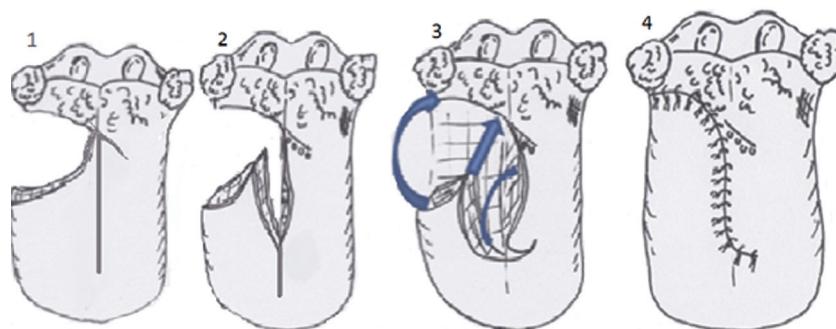
Postoperatively, 82.5% of the patients exhibited a good tongue healing with adequate tongue function. Three (17.6) patients experienced tongue infection with partial dehiscence, which healed completely after 2 weeks with conservative treatment. Regarding neck complications, 17.6% of the patients had infections and dehiscence, whereas only two patients had seromas (Table 2).

Discussion

Local tongue flap is a novel technique for the restoration of fully functioning tongue following partial hemiglossectomy. In the present prospective study, local tongue flap was an effective technique for reconstruction of posterior tongue defects after partial glossectomy of OTSCC. Most included patients (82.4%) exhibited a good tongue healing postoperatively, with a low rate of tongue infections which healed completely after conservative treatment.

The primary management of early OTSCC is based on partial glossectomy, with or without neck dissection. However, the subsequent tongue defects represent a reconstructive challenge that required special attention from the surgeon. Functional restoration is the main goal of reconstruction of tongue defects through providing both bulk and mobility [4]. Currently, the most commonly used surgical options for reconstruction of partial tongue defects are primary closure, skin grafting (either by full thickness or split thickness), pedicled flaps, and free flaps [9,10]. However, there is a growing body of evidence that shows a defect in the restoration of fully functioning tongue with those techniques. A previous systematic review by Lam and Samman [11] reported a significant decline in speech and swallowing function

Figure 5



Local anterior tongue flap technique.

Table 1 The characteristics of included participants

Variables	N=17
Age [mean (SD)] (years)	57.47 (9.53)
Male [n (%)]	12 (70.6)
History of diabetes mellitus [n (%)]	9 (52.9)
History of smoking [n (%)]	9 (52.9)
History of diabetes mellitus and smoking [n (%)]	6 (35.29)
Side affected [n (%)]	
Right	8 (47.1)
Left	9 (52.9)
Tumor size [mean (SD)] (cm)	2.04 (0.85)
Safety margins [mean (SD)] (cm)	1.06 (0.48)
Neck dissection [n (%)]	
Performed	11 (64.7)
Not performed	6 (35.3)
Lymph node number [mean (SD)]	13.18 (10.95)
Positive lymph node [mean (SD)]	3 (2.13)

Table 2 Postoperative results

Variables	Total=17
Tongue healing	
Good healing	14 (82.4)
Wound infection	3 (17.6)
Neck complications	
No	11 (64.7)
Infection and dehiscence	3 (17.6)
Seroma	2 (11.8)
Chyle	1 (5.9)

following free flap reconstruction limited to either the oral tongue or the base of tongue in early postoperative period; in addition, speech and swallowing outcomes were markedly declined following free flap reconstruction involving both oral and base of tongue.

To overcome the limitations of the commonly used surgical options, local tongue flap was proposed to restore a fully bodied mobile tongue. Lam *et al.* [7] reported excellent tongue mobility, speech ability, and swallowing following sliding anterior hemitongue flap. Moreover, another report showed that the sliding tongue

flap, following partial glossectomy of T1/T2 cancers in the anterior half of the tongue, resulted in natural bilateral symmetry of the tongue and good cosmetic appearance postoperatively [5]. The sliding posterior tongue flap of mid-tongue defect showed similar results, as well [12]. In the present prospective study, the local tongue flap was associated with high rate of good tongue healing and a limited number of wound infections.

Regarding postoperative complications, 17.6% of the patients in the present study had infections and dehiscence, whereas only two patients had seromas. This low rate of neck complications is similar to rates associated with other reconstruction techniques, Nueangkhota *et al.* [13] reported no incidence of wound dehiscence or infection following reconstruction of the tongue defect through nasolabial island flap in seven patients with small to moderate OTSCC.

Conclusion

Local tongue flap is an effective technique for reconstruction of posterolateral tongue defects after partial glossectomy. Local tongue flap is associated with high rate of good healing and low rate of complications. Further large-scale studies are still needed to establish the effectiveness of this technique.

Financial support and sponsorship

Nil.

Conflicts of interest

There are no conflicts of interest.

References

- Bagan JV, Scully C. Recent advances in oral oncology 2007: epidemiology, aetiopathogenesis, diagnosis and prognostication. *Oral Oncol* 2008; 44: 103–108.
- Siegel RL, Miller KD, Jemal A. Cancer statistics, 2017. *CA Cancer J Clin* 2017; 67:7–30.
- Rusthoven KE, Raben D, Song JI, Kane M, Altoos TA, Chen C. Survival and patterns of relapse in patients with oral tongue cancer. *J Oral Maxillofac Surg* 2010; 68:584–589.

- 4 Scully C, Bagan J. Oral squamous cell carcinoma overview. *Oral Oncol* 2009; 45:301–308.
- 5 Adachi M, Motohashi M, Muramatsu Y. Technique of sliding tongue flap after partial glossectomy. *Br J Oral Maxillofac Surg* 2015; 53:206–207.
- 6 Ceran C, Demirseren ME, Sarici M, Durgun M, Tekin F. Tongue flap as a reconstructive option in intraoral defects. *J Craniofac Surg* 2013; 24:972–974.
- 7 Lam DK, Cheng A, Berty KE, Schmidt BL. Sliding anterior hemitongue flap for posterior tongue defect reconstruction. *J Oral Maxillofac Surg* 2012; 70:2440–2444.
- 8 Agha RA, Borrelli MR, Vella-Baldacchino M, Thavayogan R, Orgill DP, Pagano D, *et al*. The STROCSS statement: strengthening the reporting of cohort studies in surgery. *Int J Surg* 2017; 46:198–202.
- 9 Archibald S, Gupta M, Thoma A. Oral tongue reconstruction. In: xxx. *Plast. Reconstr Surg*. Chichester, UK: John Wiley & Sons Ltd; 2015. pp. 318–329
- 10 Haughey BH. Tongue reconstruction: concepts and practice. *Laryngoscope* 1993; 103:1132–1141.
- 11 Lam L, Samman N. Speech and swallowing following tongue cancer surgery. and free flap reconstruction – a systematic review. *Oral Oncol* 2013; 49:507–524.
- 12 Chicarilli ZN. Sliding posterior tongue flap. *Plast Reconstr Surg* 1987; 79:697–700.
- 13 Nueangkhota P, Liang YJ, Zheng GS, Su YX, Yang WF, Liao GQ. Reconstruction of tongue defects with the contralateral nasolabial island flap. *J Oral Maxillofac Surg* 2016; 74:851–859.