

# Surgical management of gynecomastia: choice and outcome

Haytham M. Fayed<sup>a</sup>, Hassan M. Kholosy<sup>b</sup>

Departments of <sup>a</sup>Surgery, Faculty of Medicine,  
<sup>b</sup>Plastic Surgery, Alexandria University,  
Alexandria, Egypt

Correspondence to Haytham M. Fayed, MD,  
Assistant Professor of Surgical Oncology,  
Surgical Oncology Unit, Department of  
Surgery, Faculty of Medicine, Alexandria  
University, Alexandria, 21563, Egypt.  
Tel: +20 101 343 2368/+20 122 500 5995;  
e-mail: hayfay2005@gmail.com

**Received** 7 October 2017

**Accepted** 10 January 2018

**The Egyptian Journal of Surgery**

2018, 37:73–77

## Background

Gynecomastia is defined as a male breast benign condition that is characterized by enlargement of the breast owing to glandular tissue proliferation. The cause of gynecomastia includes an imbalance between estrogen and testosterone levels in male breast tissue. The primary mechanism is production of more estrogen, reduction of production of androgen, and increased peripheral conversion to estrogen from estrogen precursors.

## Patients and methods

A total of 35 male patients who presented with unilateral or bilateral gynecomastia (63 breasts) in the duration between June 2014 and June 2017 were assessed and surgically treated. All our patients were healthy except for one patient who had liver cirrhosis and two diabetic patients. Different surgical procedures were used to remove the excess skin and glandular tissue including lateral circumareolar incision, round block technique, reduction mammoplasty, liposuction, or combination of these procedures.

## Results

The commonest procedure used was round block technique. A total of four cases had complications in the form of hematoma in one case, seroma in one case, skin infection in one case, and skin necrosis in another case.

## Conclusion

Surgical correction of gynecomastia is the only hope for correction of gynecomastia in symptomatic patients.

## Keywords:

gynecomastia, male breast, mammoplasty, round block

Egyptian J Surgery 37:73–77

© 2018 The Egyptian Journal of Surgery

1110-1121

## Background

Gynecomastia is defined as a male breast benign condition that is characterized by enlargement of the breast owing to glandular tissue proliferation [1]. The cause of gynecomastia includes an imbalance between estrogen and testosterone in male breast tissue [2]. The primary mechanism is production of more estrogen, reduction of production of androgen, and increased peripheral conversion to estrogen from estrogen precursors [3]. Physiologic gynecomastia is the most common cause, which occurs mainly during the adolescent period. Overall, 85–90% of pubertal gynecomastia cases regress within 6 months to 2 years but some may persist till adulthood [4]. The condition may develop because of obesity, consumption of estrogens, anabolic steroids, or H2 blockers such as cimetidine [5]. Gynecomastia is characterized clinically by increase in the areolar diameter, breast swelling, deformation in the appearance of the male thorax, abnormal presence of an inframammary fold, skin ptosis with the nipple–areola complex sliding down to the height of the fold or even below it, and asymmetry [6]. Gynecomastia can be classified by different methods, but the most common is Simon's classification: grade 1, mild enlargement and no skin excess; grade 2a,

moderate enlargement and no skin excess; grade 2b, moderate enlargement with excess skin; and grade 3, marked enlargement with more skin increase and severe ptosis [7]. If a cause is identified, its treatment may result in regression of gynecomastia. If gynecomastia is progressive and does not respond to other treatments, surgical therapy is indicated. There are multiple surgical procedures, including removal of the excessive glandular tissue and skin by subcutaneous mastectomy, breast reduction, liposuction, round block suture, or a combination of these techniques [6,8].

The aim of the work was to assess the different surgical techniques to treat nonregressing cases of gynecomastia.

## Patients and methods

A total of 35 male patients who presented with unilateral or bilateral gynecomastia (63 breasts) in the duration between June 2014 and June 2017 were

This is an open access article distributed under the terms of the Creative Commons Attribution-NonCommercial-ShareAlike 3.0 License, which allows others to remix, tweak, and build upon the work noncommercially, as long as the author is credited and the new creations are licensed under the identical terms.

assessed and surgically treated. The study was approved by ethical committee of in Surgical department of Alexandria Faculty of Medicine. All our patients were healthy except for one patient who had liver cirrhosis and two diabetic patients.

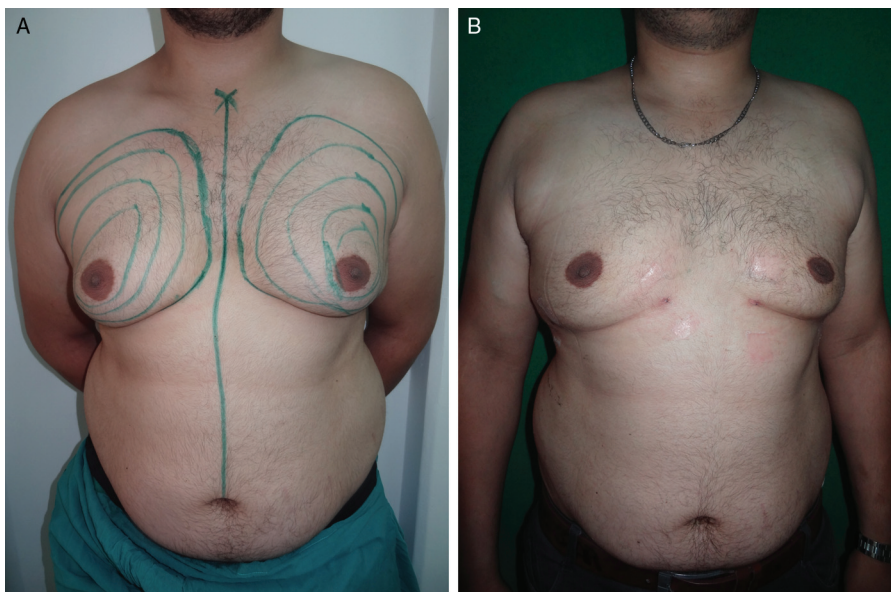
**Surgical procedures**

All patients were treated under general anesthesia. Concentric topography-type marks centered on the most prominent portion of the breast in the upright sitting position were made preoperatively. The inframammary fold, breast boundary, and planned incision sites were drawn on each breast. According to the grade of gynecomastia, a surgical procedure was done. For grade I, lateral circumareolar incision was done and the glandular disc was removed.

Round block technique (Fig. 1a-c) was the commonly used surgical procedure, and it involves de-epithelialization of the circumareolar skin according to the redundancy of skin followed by lateral incision between 6 and 12 o'clock position without reaching the midline. Dissection and excision of the glandular tissue was done through that incision with good hemostasis. Closure was done by approximation of the skin edges by absorbable suture material. We used to put suction drain after the procedure, which was removed on the third to sixth days according to the drained amount in 24 h.

Liposuction (Fig. 2a and b) was applied to cases where there was no increase in the glandular tissue but the fatty tissue.

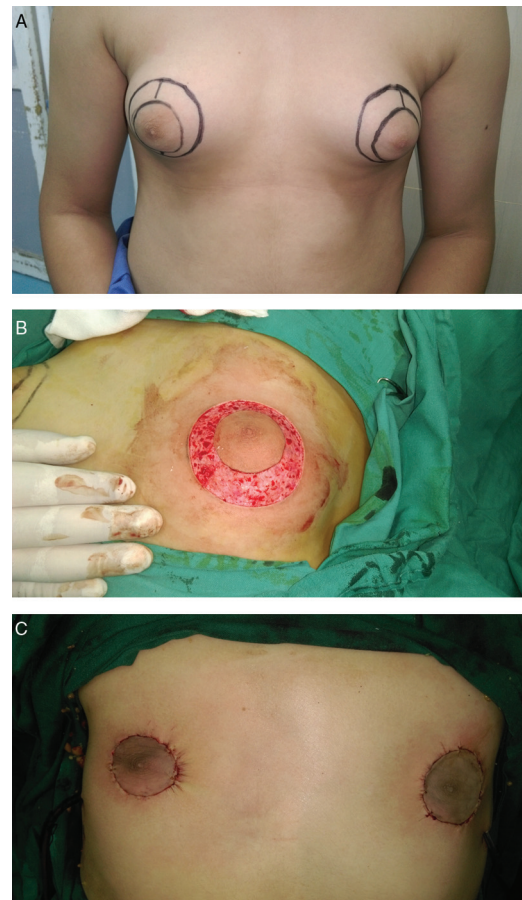
**Figure 2**



Liposuction for management of gynecomastia. A: Preoperative marking. B: Postoperative.

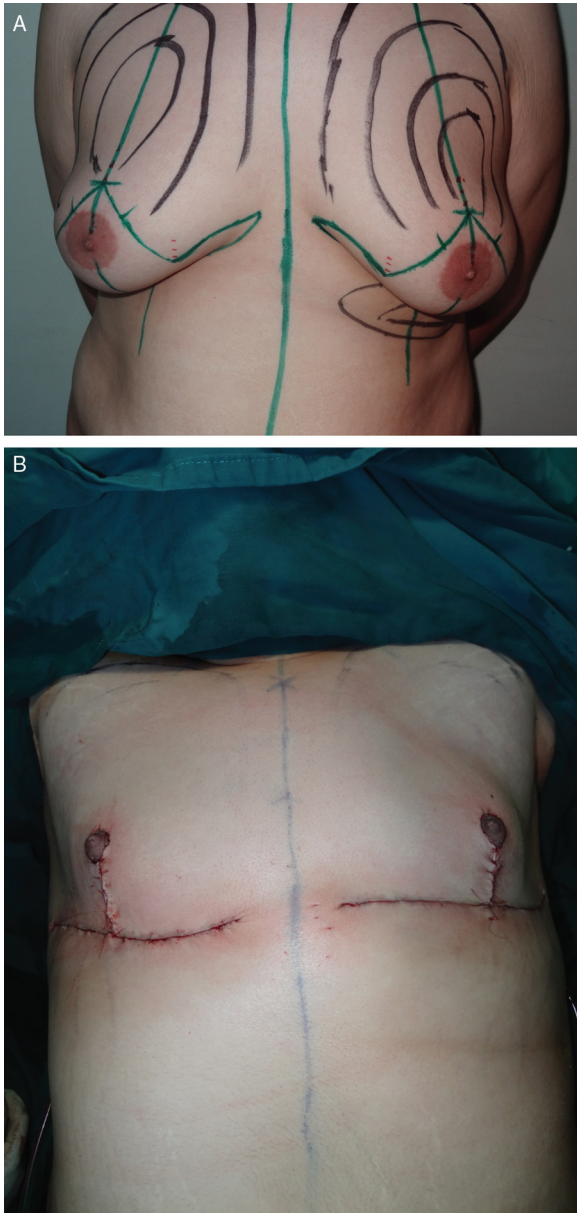
Superior pedicle reduction mammoplasty (Fig. 3a and b) was done to patients with grade III gynecomastia in whom the breast redundancy simulates the female breast.

**Figure 1**



Round block technique for management of gynecomastia. A: Preoperative marking. B: Intraoperative de-epithelialization of peri-areolar skin. C: Immediate postoperative.

Figure 3



Superior pedicle reduction mammoplasty for management of gynecomastia. A: Preoperative marking. B: Immediate postoperative.

Combination of two procedures as liposuction and round block techniques may be needed in some cases with redundant skin and increased fat and glandular tissues (Fig. 4a-c).

## Results

Most of our patients had bilateral gynecomastia (80%), most of them had grade II disease, and round block technique was the most commonly done surgical procedure (68.6%) (Table 1).

Postoperative complications were associated more with comorbid diseases. Complications were encountered in four cases in the form of

**Table 1** Distribution of the studied cases according to different parameters ( $n=35$ )

Age (years)	25.4±6.9
≤20	10 (28.6)
20–30	18 (51.4)
>30	7 (20.0)
Side	
Unilateral	7 (20.0)
Bilateral	28 (80.0)
Technique	
Lateral circumareolar	2 (5.7)
Liposuction	6 (17.1)
Round block	27 (77.1)
Liposuction and round block	3 (8.6)
Superior pedicle reduction mammoplasty	3 (8.6)
Comorbid disease	
No	32 (91.4)
HCV	1 (2.9)
DM	2 (5.7)
Complications	4 (11.4)
Pathology	
Primary	34 (97.1)
Secondary	1 (2.9)
Grades	
I	2 (5.7)
II	18 (51.4)
III	15 (42.9)

Qualitative data were described using number and percentage, whereas normally quantitative data were expressed in mean±SD. DM, diabetes mellitus; HCV, hepatitis C virus.

seroma in one patient who was diagnosed to have liver cirrhosis. Diabetes mellitus was associated with wound infection in one case and skin necrosis in another patient. Hematoma was encountered in one patient after liposuction (Table 2).

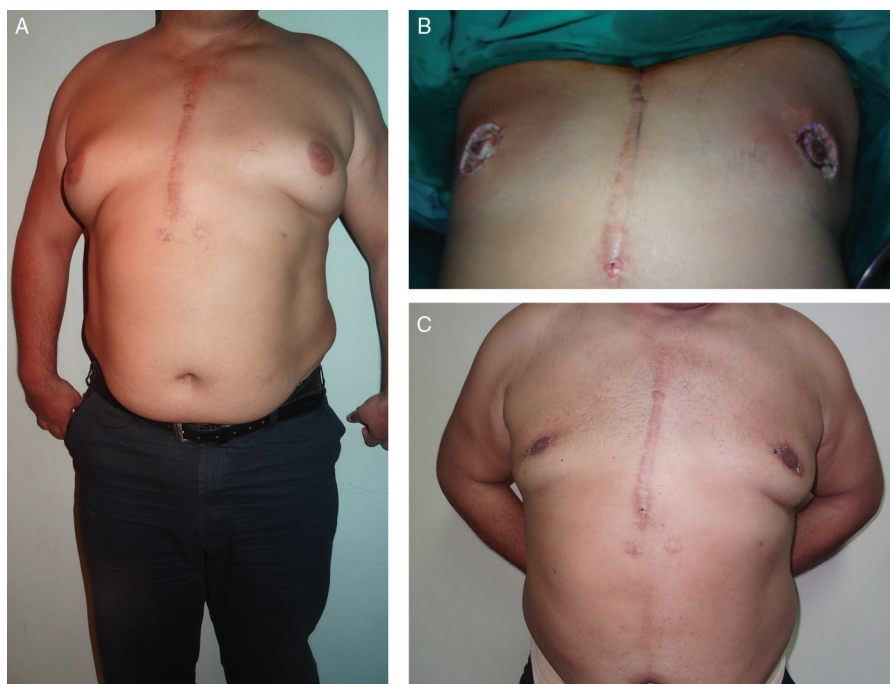## Discussion

Gynecomastia is a benign breast disease that may affect men of all ages. It is caused by different degrees of proliferation of the glandular tissue, which differs from pseudogynecomastia in which there is an increase in the fatty tissues in obese men [9]. Most cases are caused by hormonal imbalance between estrogen and androgen, and this may occur with increased estrogen action or decreased androgen action [10–12]. Medical treatment of gynecomastia is controversial, and actually there is no consensus about the proper drug and its duration [13,14]. We performed different techniques for surgical management of symptomatic patients. The choice of the surgical procedure depended on the presence of excess skin and abundant glandular tissue. In symptomatic grade I cases, we adopted to do lateral circumareolar incision to remove the small

**Table 2 Relation between complications and grade, technique, and comorbid disease**

	Total	Complications		P
		No (n=31)	Yes (n=4)	
<b>Grades</b>				
I	2(5.7)	2 (6.5)	0 (0)	1.000
II	18 (51.4)	16 (51.6)	2 (50)	
III	15 (42.9)	13 (41.9)	2 (50)	
<b>Technique</b>				
Lateral circumareolar	2 (5.7)	2 (6.5)	0 (0)	1.000
Liposuction	6 (17.1)	5 (16.1)	1 (25)	0.546
Round block	27 (77.1)	24 (77.4)	3 (75)	1.000
Liposuction and Round block	3 (8.6)	3 (9.7)	0 (0)	1.000
Superior pedicle reduction mammoplasty	3 (8.6)	3 (9.7)	0 (0)	1.000
<b>Comorbid disease</b>				
No	32 (91.4)	31 (100)	1 (25)	0.001*
HCV	1 (2.9)	0 (0)	1 (25)	
DM	2 (5.7)	0 (0)	2 (50)	

Qualitative data were described using number and percentage. DM, diabetes mellitus; HCV, hepatitis C virus. \* $P \leq 0.05$ , statistically significant.

**Figure 4**

Combination of liposuction and round block techniques for management of gynecomastia. A: Preoperative picture. B: Intraoperative after liposuction and de-epithelialization of the peri-areolar skin. C: One week after surgery.

retroareolar glandular disc with minimal scarring and good cosmetic appearance. Other surgical procedures were used with excess skin. Excess skin was either de-epithelialized in round block technique, which was the procedure of choice for grade II gynecomastia, or removed in mammoplasty technique for cases with severe ptosis simulating female breast. These procedures enabled us to remove the excess skin and excess glandular tissue with little complication rate, which was related to comorbid diseases such as diabetes mellitus and liver

cirrhosis. Liposuction alone was done in cases with excess fatty tissue.

### Conclusion

The gold standard for correction of gynecomastia is surgical excision of the glandular tissue and excess skin. Different surgical procedures are available, all aiming at subcutaneous mastectomy with removal of the excess skin. Lateral circumareolar incision is indicated for grade I gynecomastia in which there is no need to

remove excess skin. For grade II, round block technique is optimum with de-epithelialization of the excess skin. In grade III, combined techniques are required, or reduction mammoplasty is done in severe cases.

#### Financial support and sponsorship

Nil.

#### Conflicts of interest

There are no conflicts of interest.

---

#### References

- 1 Longheu A, Medas F, Corrias F, Farris S, Tatti A, Pisano G, *et al*. Surgical management of gynecomastia: experience of a general surgery center. *G Chir* 2016; 37:150–154.
- 2 Niewoehner CB, Nuttal FQ. Gynecomastia in a hospitalized male population. *Am J Med* 1984; 77:633–638.
- 3 Rochefort H, Garcia M. The estrogenic and antiestrogenic activities of androgens in female target tissues. *Pharmacol Ther* 1983; 23:193–216.
- 4 Treves N. Gynecomastia: the origins of mammary swelling in the male: an analysis of 406 patients with breast hypertrophy, 525 with testicular tumors, and 13 with adrenal neoplasms. *Cancer* 1958; 11:1083–1102.
- 5 Bembo SA, Carlson HE. Gynecomastia: its features, and when and how to treat it. *Cleve Clin J Med* 2004; 71:511–517.
- 6 Cordova A, Moschella F. Algorithm for clinical evaluation and surgical treatment of gynaecomastia. *J Plast Reconstr Aesthet Surg* 2008; 61:41–49.
- 7 Simon BE, Hoffman S, Kahn S. Classification and surgical correction of gynecomastia. *Plast Reconstr Surg* 1973; 51:48–52.
- 8 Handschin AE, Bietry D, Husler R, Banic A, Constantinescu M. Surgical management of gynecomastia – a 10-year analysis. *World J Surg* 2008; 32:38–44.
- 9 Lemaine V, Cayci C, Simmons PS, Petty P. Gynecomastia in adolescent males. *Semin Plast Surg.* 2013; 27:56–61.
- 10 Creighton WM, Custers M. Gynecomastia: is one cause enough? *Neth J Med* 2004; 62:257–259.
- 11 Mathur R, Braunstein GD. Gynecomastia: pathomechanisms and treatment strategies. *Horm Res* 1997; 48:95–102.
- 12 Narula HS, Carlson HE. Gynecomastia. *Endocrinol Metab Clin North Am.* 2007; 36:497–519.
- 13 Maidment SL. Question 2. Which medications effectively reduce pubertal gynaecomastia? *Arch Dis Child* 2010; 95:237–239.
- 14 Petty PM, Solomon M, Buchel EW, Tran NV. Gynecomastia: evolving paradigm of management and comparison of techniques. *Plast Reconstr Surg* 2010; 125:1301–1308.