

# Modified inferior-based oncoplastic technique for upper-inner-quadrant breast cancers

Tarek M. Rageh, Alaa A. Elsisy, Ahmed S. Elgammal

Department of General Surgery, Faculty of Medicine, Menoufia University, Menoufia, Egypt

Correspondence to Ahmed S. Elgammal, PhD, Department of General Surgery, Faculty of Medicine, Menoufia University, Menoufia, 32511, Egypt. Tel: +20 100 778 9255; e-mail: ahmedegyptsabry@yahoo.com

**Received:** 31 March 2021

**Revised:** 18 April 2021

**Accepted:** 27 April 2021

**Published:** 11 January 2022

**The Egyptian Journal of Surgery** 2021, 40:836–841

## Background

The use of oncoplastic surgery techniques in breast-conservation surgery (BCS) provides a wide range of procedural choices for achieving the best oncologic and cosmetic results. Breast surgeons face a challenge in conducting upper-inner-quadrant (UIQ) radical excision with an acceptable cosmetic result.

## Aim

The aim was to demonstrate a new technique for reconstructing UIQ excision defects with oncoplastic inferior-dependent dermoglandular reshaping to achieve a satisfactory cosmetic outcome when undergoing radical breast cancer excision.

## Patients and methods

A total of 46 patients with UIQ breast cancer were operated on between January 2016 and August 2020. The cosmetic result, postoperative complications, and resection margins were all evaluated.

## Results

The complication rate was 10.8% after 15 months of follow-up (range: 8–24) (marginal skin necrosis, seroma formation, and wound infection). In every case, the surgical margins of resection were negative. Overall satisfaction was rated excellent by 39 patients (84.7%), decent by five patients (10.8%), and average by two patients (4.3%).

## Conclusion

In terms of free surgical margins, resection speeds, and excellent cosmetic results, our methodology provides a good option for the reshaping that accompanies UIQ breast cancer.

## Keywords:

breast cancer, oncoplastic technique, upper inner quadrant

Egyptian J Surgery 40:836–841

© 2022 The Egyptian Journal of Surgery

1110-1121

## Introduction

Breast cancer is the most common type of malignancy and the main cause of cancer-related death among women worldwide [1,2]. According to the National Cancer Institute in Egypt, breast cancer is one of the commonest cancers in Egyptian women as it accounts for ~38.8% of total malignancies [3].

Despite the fact that many treatment options for this cancer have improved dramatically over the last 15 years, surgery remains the most popular treatment for early breast cancer [4]. For several years, various mastectomy procedures were thought to be the gold standard in the surgical treatment of breast cancer [5].

The first surgical revolution occurred in the 1970s with the publication of Fisher and Veronesi's breast-conserving surgery [6]. Breast surgery was later transformed, as plastic surgery was used to reshape the breast in a process known as oncoplastic breast surgery (OBS) [7]. These techniques are constantly being improved and updated as surgeons seek to introduce new techniques that yield better cosmetic

outcomes while preserving the technique's oncologic protection [8].

Oncoplastic surgery techniques are divided into three categories: level I, level II, and level III. When less than 20% of the breast volume is to be excised, a level I OBS is performed. When 20–50% of the breast volume is excised and tissue displacement is used to correct the defect, the procedure is called level II. Level III is used where more than half of the breast tissue is removed and replaced. The technique is performed to repair defect [9].

However, with the new range of OBS techniques, surgeons are up against two big roadblocks. The first is tumors in some parts of the breast, such as the upper-inner quadrant (UIQ), and the second is breast size,

This is an open access journal, and articles are distributed under the terms of the Creative Commons Attribution-NonCommercial-ShareAlike 4.0 License, which allows others to remix, tweak, and build upon the work non-commercially, as long as appropriate credit is given and the new creations are licensed under the identical terms.

with bigger breasts becoming more difficult to treat [10].

UIQ breast cancer is considered to be the most difficult breast cancer site to treat cosmetically. Grisotti and Calabrese coined the word 'no man's land' to describe this area. When the resection zone is far away from the nipple–areola complex (NAC), the problem would be compounded. This means that removing tumors near the sternoclavicular junction, where there is less breast tissue and the skin is relatively fixed, and where the surgeon cannot perform incisions esthetically, is one of the most complicated surgical procedures in breast-conserving surgery [11].

### Aim

The aim was to present a new reconstructive inferior-based oncoplastic dermoglandular flap reshaping technique for the UIQ breast cancer. Feasibility, operative time, complication, oncological results, and esthetic outcome were assessed.

### Patients and methods

This is a prospective study carried out from January 2016 to August 2020 on 46 patients diagnosed with breast cancer in UIQ admitted to the General Surgery Department at Menoufia University Hospital, Shibin AlKoom, Egypt.

#### Inclusion criteria

The following were the inclusion criteria:

- (1) Pathologically proven UIQ breast cancer.
- (2) Unifocal breast cancer.
- (3) T1 and early T2 breast cancer.
- (4) Patients candidate for breast-conserving surgery and oncoplastic reconstruction.

#### Exclusion criteria

The following were the exclusion criteria:

- (1) Recurrent breast cancer.
- (2) Past history of radiation therapy.
- (3) Multicentricity breast cancer.
- (4) Patients preferred modified radical mastectomy.

#### Informed consent process

An informed consent was obtained from all patients for the surgical procedure performed. All patients participating in the study received a detailed explanation of the purpose, methods, and value of the study. It was approved by the Hospital Ethical Committees, and the described work has been carried

out in accordance with the Code of Ethics of the World Medical Association.

### Technique

#### Patient marking and drawing

- (1) Marking was done while the patient was standing.
- (2) The skin-reduction approach was inverted T according to breast volume.
- (3) Nipple positioning was at 20–22 cm.
- (4) Nipple and areola are 10–11 cm from the midline.
- (5) Base of the inverted T of the flap is 8–10 cm wide.
- (6) Vertical limb of the inverted T is 6–8 cm (Fig. 1).

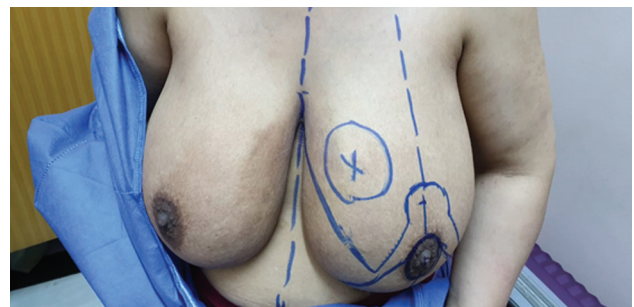
#### Skin incision and tissue preparation

After anesthesia and sterilization of the skin, the angle of marking was marked again by silk sutures. De-epithelialization of the inferior flap was done, which includes also the lower-inner quadrant, which was saved to be used to fill in the space of the excised tumor. Incision of the skin and subcutaneous tissue was done, followed by elevation of the flap from the underlying breast tissue with a thickness of 4–5 mm (Fig. 2).

#### Breast tissue resection

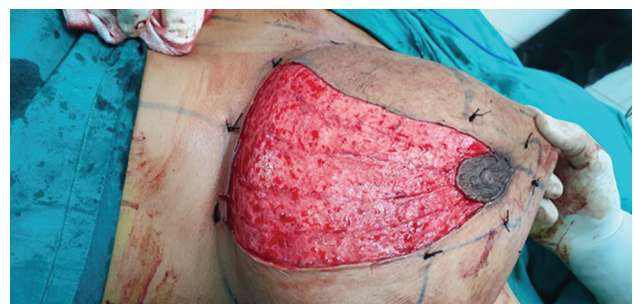An elliptical breast excision touching the pectoralis major muscle fascia is used to perform a

**Figure 1**



Patient marking and drawing.

**Figure 2**



Skin incision and tissue preparation.

quadrantectomy of the UIQ breast tissue. Stitches were used to mark the different faces of the specimen, and a frozen segment was taken to ensure the surgical margins were free and to determine how to proceed in the event of re-excision. Following the excision, the cavity would be clipped with surgical clips in the tumor bed. Resection of the lower-outer quadrant and breast tissue between the existing NAC and the expected site is completed (Fig. 3).

*Modified inferior-based dermal free glandular flap reconstruction*

The dermal free glandular flap was then rotated to replace the defect in the UIQ and sutured to the remaining superficial fascia of the UIQ with a 2/0 vicryl suture. The flap was then sutured to the lower portion of the remaining inner quadrant (Fig. 4). The NAC was rotated and positioned as expected; accurate hemostasis was maintained, and suction drains were fixed. Axillary lymph node dissection was done through separate incision. Contralateral immediate

breast reconstruction was performed in 36 patients (Fig. 5).

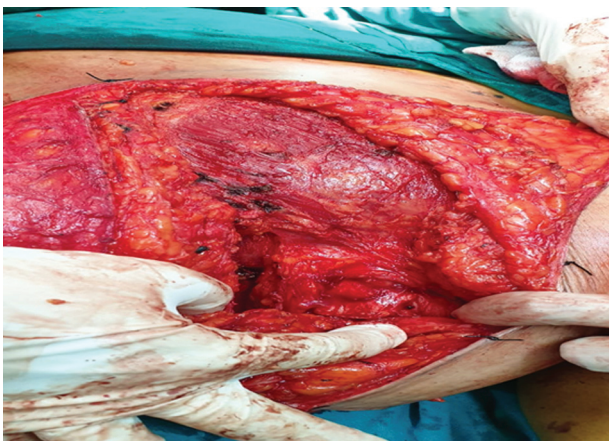In some cases, bilateral immediate reduction was done (Fig. 6).

Surgical outcome measures were as follows:

All patients were assessed for the following:

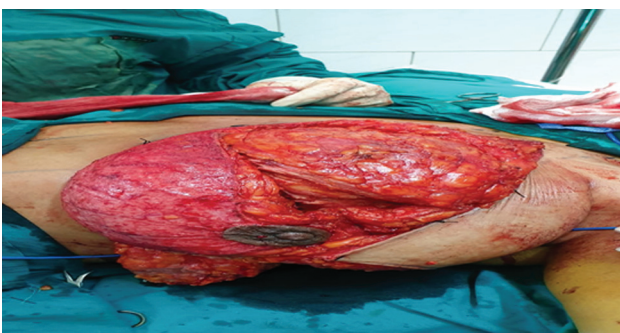
- (1) Operative time.
- (2) Resection margin assessment.
- (3) -Postoperative morbidity: wound dehiscence, hematoma, seroma, infection, and NAC necrosis (Fig. 7).
- (4) -Cosmetic outcome assessment: it included breast symmetry, NAC symmetry, scarring, and overall satisfaction. A four-point (Likert) score (Harvard Scale) was used to assess the cosmetic outcome as excellent, good, fair, or poor (Fig. 8).
- (5) Postoperative treatment: it included chemotherapy, radiotherapy, and hormonal treatment.

**Figure 3**



Breast tissue resection.

**Figure 4**

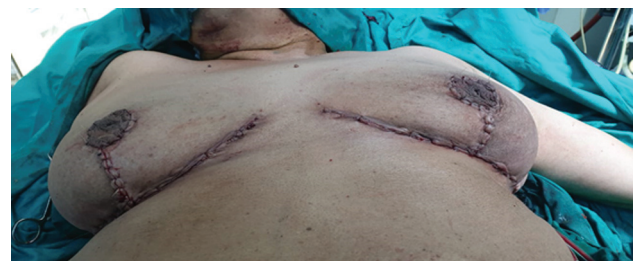

Modified inferior-based dermal free glandular flap reconstruction.

**Results**

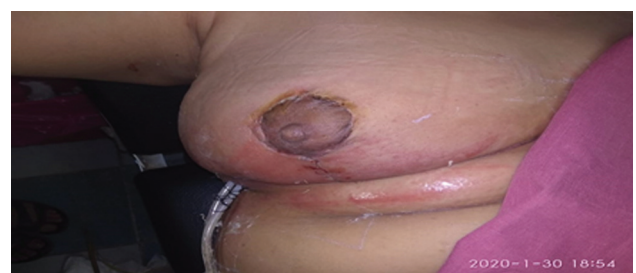A modified inferior-dependent dermal free glandular flap was used to treat 46 patients with breast cancer in the UIQ (Tables 1, 2). The median age of the patients was 47 years (range: 34–67), their BMI was

**Figure 5**



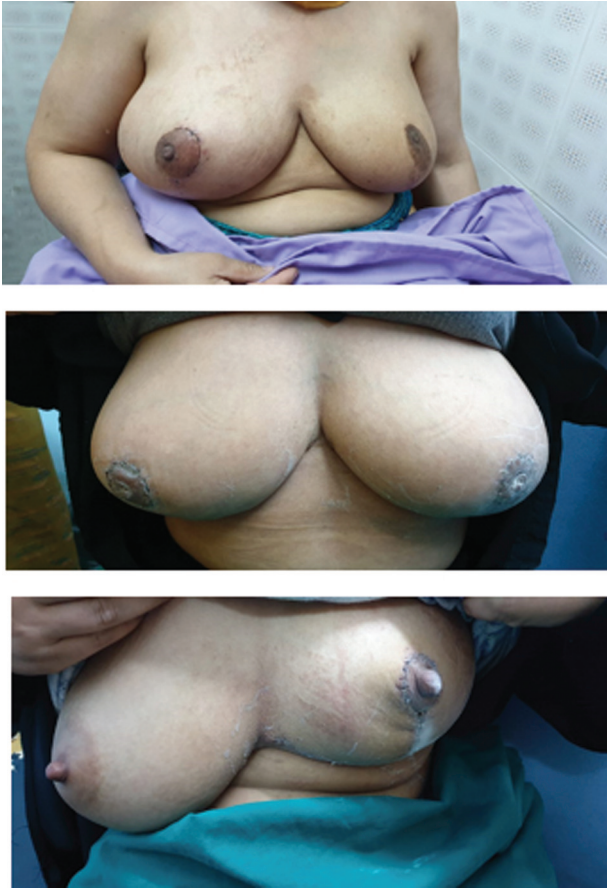Contralateral immediate breast reconstruction.

**Figure 6**



(a,b,c) Immediate contralateral breast reconstruction.

Figure 7



Postoperative complications.

29.7 kg/cm<sup>2</sup> (range: 22.4–33.1), and their tumor size was 1.3 cm (range: 0.9–2.8). Contralateral immediate breast reconstruction was performed in 36 patients (78.2%), and delayed contralateral breast reconstruction was performed in 10 patients (21.8%).

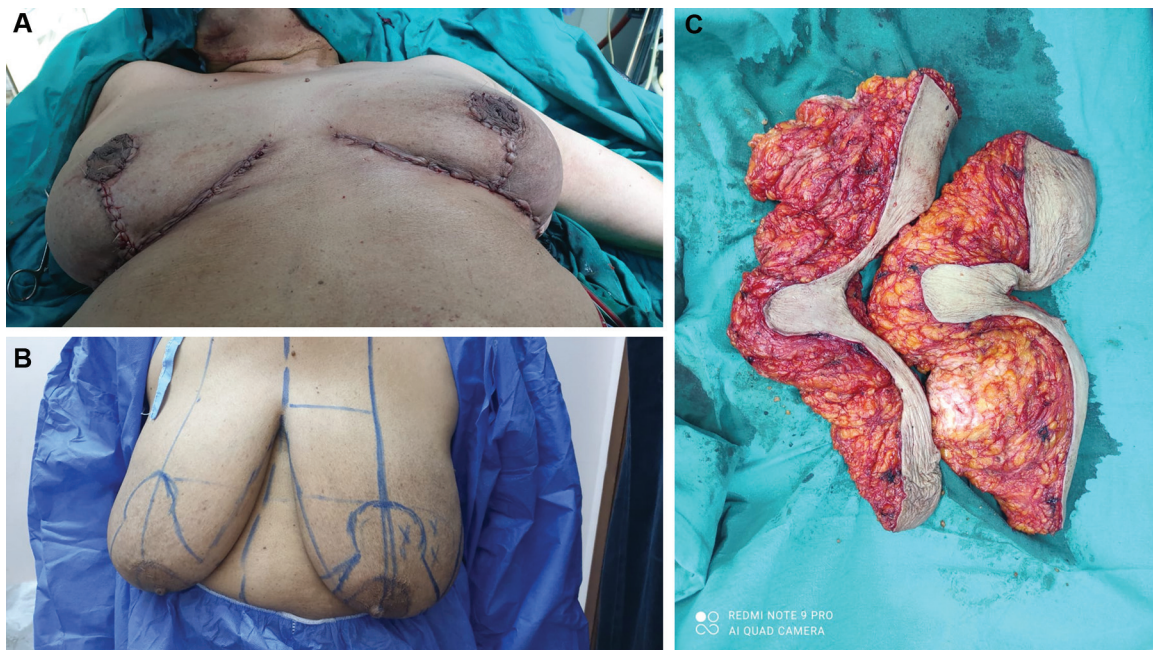
The average follow-up period was 15 months (range: 8–24 months). In every case, the surgical margins of resection were negative. Postoperative radiotherapy was provided to all of the patients in the study. A total of 36 patients (78.2%) received adjuvant chemotherapy, whereas three patients received neoadjuvant chemotherapy (6.5%). Moreover, 40 patients were given hormone therapy (86.9%).

Postoperative complications included margin skin necrosis (three patients; 6.5%), seroma formation (one patient; 2.1%), and skin infection in five patients (10.8 percent) (one patient; 2.1%). All complications were handled with caution. Patients were asked to rate the cosmetic result on a four-point scale. In 40 patients, overall satisfaction was rated as excellent (84.7%), good in five patients (10.8%), and fair in two patients (4.3%).

## Discussion

In relation to universal oncological rates, OBS decreases the number of mastectomies. In contrast

Figure 8



Postoperative cosmetic results.

**Table 1 Patients' characteristics and operative data**

Number of patients	46
Age (years)	47 (34–67)
BMI (kg/m <sup>2</sup> )	29.7 (22.4–33.1)
Tumor size (cm)	1.3 (0.9–2.8)
T staging	
PTis	3
pT1	36
pT2	7
Node staging	
pN0	10
pN1	35
pN2	1
Immediate contralateral breast reconstruction	36
Delayed contralateral breast reconstruction	10
Operative time (min)	100 (75–180)
Complications	
Margin skin necrosis	3
Seroma	1
Skin infection	1
Adjuvant therapy	
Neoadjuvant chemotherapy	3
Adjuvant chemotherapy	36
No chemotherapy	7
Radiotherapy	46
Hormonal	40

to other breast quadrants, the UIQ breast cancer prevalence is around 15.6%, and it is considered to be the most difficult breast cancer site to treat from a cosmetic perspective [12].

For each breast quadrant, a number of techniques have been tested. UIQ is the least desirable location for a tumor, particularly if it is located far from the breast's middle [13]. The surgical plan for resection of tumors in the UIQ of the breasts is more complicated owing to the importance of this field to women's esthetics. As a result, there is a critical need for innovative approaches that can overcome the drawbacks of existing techniques.

The methods used in oncoplastic surgery are not all the same. The degree of tumor resection and skin dissection varies depending on the type of oncoplastic operative procedure used, making comparisons difficult. A 20% early complication rate (2 months postoperative) has been identified in a systematic analysis of OBS [14,15]. We found only five cases (10.8%) of postoperative complications, which is less than the documented OBS worldwide results.

According to Fitoussi and colleagues, extensive undermining can cause seroma, fat necrosis, and

**Table 2 Esthetic result outcome**

	Excellent	Good	Fair	Poor
Breast symmetry	40	6	0	0
NAC symmetry	39	5	2	0
Scarring	32	10	3	1
Overall Satisfaction	39	5	2	0

NAC, nipple–areola complex.

hematoma, and the NAC transposition can cause partial or complete necrosis [16]. Just one case of postoperative seroma (2.1%), three cases of postoperative marginal skin necrosis (6.5%), and one case of infection have been recorded (2.1%). Because of the larger flap foundation, we did not have any wound dehiscence or NAC necrosis (8–10 cm).

Previous research has linked partial mastectomy with oncoplastic surgical techniques to a low rate of redo surgery for positive margins or a near margin with appropriate cosmetic outcomes [17,18]. Our results show no involved margins owing to two important factors: the tumor is first excised under bimanual palpation control, resulting in an open book for sufficient excision and a higher risk of achieving negative margins, and the other factor is the presence of a pathologist performing frozen sections for the resected specimens, directing the operating surgeons when obtaining involved margins allowing the same session intraoperative extended resections.

The so-called (Batwing) excision pattern is simple and reliable, but there is a scar in the upper half of the breast with no cosmetic outcome and equal patient satisfaction, according to Anderson and colleagues [19,20]. Cutress and colleagues identified a variation of the Wise pattern in which the UIQ and upper-outer quadrant of the breast are reduced, with the skin over the tumor resected and the same amount of skin moved from the inframammary fold to maintain the nipple to inframammary-fold distance [21]. Lee and colleagues presented the Fish-hook procedure, which helps the surgeon to prevent contralateral symmetrization while leaving a large visible scar and good cosmetic results for the patient [10].

Our proposed technique for UIQ tumors has a number of advantages. When the patient is seated, there is just one scar on the inferior side of the chest wall, which is not apparent. As a result, marks over the breast are avoided, and the cosmetic result is superior. Our technique represents excellent method for the challenging reshaping that follows upper-inner breast cancer with good cosmetic results.

The possibility of a delay in adjuvant treatment, such as radiotherapy or chemotherapy, owing to a longer wound healing period can be prevented with careful patient selection, which excludes diabetics and women with peripheral vascular disease from this surgical procedure.

Because of the possibility of volume modification as a result of contralateral breast symmetrization after radiotherapy, some writers recommend delaying it. Of fat necrosis and edema may derive from radiotherapy [22]. We conducted immediate contralateral breast reconstruction in 78.2% of our patients, and we found that doing contralateral symmetrization at the same time increases patient satisfaction.

We describe a simple oncoplastic technique that meets all of a woman's needs while retaining her breast shape. Because of the broad skin, there is no NAC mal-positioning or asymmetry with our modified inferior-dependent dermoglandular technique. Undermining that completely detaches the breast parenchyma from the overlying skin.

The surgery is performed according to level I oncoplastic guidelines. As seen in level 1 oncoplasty, broad biplanar mobilization, full thickness excision of the breast bearing the tumor with protection margins, defect closure by advancement of the local breast flap, and NAC mobilization are all important parts of this strategy.

## Conclusion

A modern method for treating UIQ breast cancer is the modified inferior-based oncoplastic technique. The method has many benefits, both oncological and esthetic. This method has many benefits, including the potential for patients to provide a single-stage procedure and reconstructive surgery that is cosmetically acceptable for women's needs.

## Recommendation

This procedure incorporates a new oncoplastic procedure known as the 'Modified inferior centered dermal free glandular flap.' This method appears to solve the majority of the issues listed before. It was used on patients with breast cancer who had tumors in the UIQ of the breast.

## Financial support and sponsorship

Nil.

## Conflicts of interest

There are no conflicts of interest.

## References

- Torre LA, Islami F, Siegel RL, Ward EM, Jemal A. Global cancer in women: burden and trends. *Cancer Epidemiol Biomarkers Prev* 2017; 26:444–457.
- Jazayeri SB, Saadat S, Ramezani R, Kaviani A. Incidence of primary breast cancer in Iran: ten-year national cancer registry data report. *Cancer Epidemiol* 2015; 39:519–527.
- Ibrahim AS, Khaled HM, Mikhail NN, Baraka H, Kamel H. Cancer incidence in Egypt: results of the national population-based cancer registry program. *J Cancer Epidemiol* 2014; 2014:437–971.
- Berry MG, Fitoussi AD, Curnier A, Couturaud B, Salmon RJ. Oncoplastic breast surgery: a review and systematic approach. *J Plast Reconstr Aesthet Surg* 2010; 63:1233–1243.
- Kaviani A, Sodagari N, Sheikhbahaei S, Eslami V, Hafezi-Nejad N, Safavi A, *et al.* From radical mastectomy to breast-conserving therapy and oncoplastic breast surgery: a narrative review comparing oncological result, cosmetic outcome, quality of life, and health economy. *Int Sch Res Notices* 2013; 2013:742462.
- Fisher B. The surgical dilemma in the primary therapy of invasive breast cancer: a critical appraisal. *Curr Probl Surg* 1970; 7:3–53.
- Kaviani A, Zand S, Ashraf-Ganjouei A, Younan R, Salmon RJ. A novel level I oncoplastic surgery technique for tumors located in UIQ of the breast far from the nipple: the 'cross' technique. *Plast Reconstr Surg Glob Open* 2019; 7:22–69.
- Honart JF, Reguesse AS, Struk S, Sarfati B, Rimareix F, Alkhashnam H, *et al.* Indications and controversies in partial mastectomy defect reconstruction. *Clin Plast Surg* 2018; 45:33–45.
- Munhoz AM, Montag E, Gemperli R. Oncoplastic breast surgery: indications, techniques and perspectives. *Gland Surg* 2013; 2:143–157.
- Clough KB, Kaufman GJ, Nos C, Buccimazza I, Sarfati IM. Improving breast Cancer surgery: a classification and quadrant per quadrant atlas for oncoplastic surgery. *Ann Surg Oncol* 2010; 17: 1375–1391.
- Grisotti A, Calabrese C. Conservation Treatment of Breast Cancer: Reconstructive Problems. *Surgery of the Breast: Principles and Art*. 2nd ed. Philadelphia, PA: Lippincott Williams & Wilkins; 2006. 147–178
- Rummel S, Huelman MT, Costantino N, Shriver C, Ellsworth R. Tumour location within the breast: does tumour site have prognostic ability? *Ecancermedalscience* 2015; 9:552.
- Lin J, Chen DR, Wang YF, Lai H. Oncoplastic surgery for upper/upper inner quadrant breast cancer. *PLoS One* 2016; 11:e0168434.
- Haloua MH, Krekel NM, Winters HA, Rietveld D, Meijer S, Bloemers F. A systematic review of oncoplastic breast-conserving surgery: current weaknesses and future prospects. *Ann Surg* 2013; 257:609e620.
- Fitoussi AD, Berry MG, Fama F, Curnier A, Couturaud B, Reyal F. Oncoplastic breast surgery for cancer: analysis of 540 consecutive cases. *Plast Reconstr Surg* 2010; 125:454–462.
- Moran MS, Schnitt SJ, Giuliano AE, Harris J, Khan S, Horton J. Society of Surgical Oncology and American Society for Radiation Oncology consensus guideline on margins for breast-conserving surgery with wholebreast irradiation in stages I and II invasive breast cancer. *J Clin Oncol* 2014; 32:1507–1515.
- Morrow M. Breast conservation and negative margins: how much is enough? *Breast* 2009; 18:84–86.
- Anderson B, Masetti R, Silverstein M. Oncoplastic approaches to partial mastectomy: an overview of volume displacement techniques. *Lancet Oncol* 2005; 6:145–157.
- Cutress RI, Simoes T, Gill J, Hurren JS. Modification of the Wise pattern breast reduction for oncological mammoplasty of upper outer and upper inner quadrant breast tumours: a technical note and case series. *J Plast Reconstr Aesthet Surg* 2013; 66:e31–e36.
- Lee S, Lee J, Jung Y, Bae Y. Oncoplastic surgery for inner quadrant breast cancer: fish-hook incision rotation flap. *ANZ J Surg* 2017; 87:E129–E133. doi:10.1111/ans.13336.
- Kronowitz SJ, Hunt KK, Kuerer HM, Strom EA, Buchholz TA, Ensor JE, *et al.* Practical guidelines for repair of partial mastectomy defects using the breast reduction technique in patients undergoing breast conservation therapy. *Plast Reconstr Surg* 2007; 120:1755.
- Fitoussi A, Berry MG, Couturaud B, Salmon RJ. *Oncoplastic and Reconstructive Surgery for Breast Cancer*. Berlin: The Institute Curie experience. Springer; 2009.