

Management of iatrogenic hepatic artery pseudoaneurysm

Ahmed Khalil, Fawzy S. Fawzy, Mohamed H. Zaid

Ain Shams University Hospitals, Faculty of Medicine, Ain Shams University, Cairo, Egypt

Correspondence to Ahmed Khalil, Medical Doctorate Degree; Ain Shams University Hospitals, Faculty of Medicine, Ain Shams University, Cairo, 11471, Egypt.
Tel: +20 109 771 7660; fax: 0020222742176; e-mail: abdelrazek79@hotmail.com

Received: 2 May 2021

Revised: 19 May 2021

Accepted: 30 May 2021

Published: 11 January 2022

The Egyptian Journal of Surgery 2021, 40:954–958

Background

Visceral aneurysms are rare, with a prevalence of ~1%. Hepatic artery aneurysms are the second most common type, accounting for ~20% of all visceral aneurysms. Pseudoaneurysm is a rare complication that can happen after any intervention. The treatment is through interventional radiology by either insertion of an arterial stent or coiling at the neck of the aneurysm versus surgical intervention.

Patients and methods

The authors analyzed the data of 12 cases in a retrospective pattern. All cases were referred to our Hepatopancreaticobiliary Unit in Ain Shams University Hospitals during the period between January 2017 and December 2020.

Results

The most common cause of hepatic artery pseudoaneurysm was following cholecystectomy. The time of presentation was ranging from 2 to 17 weeks from the intervention. The most common presentation was right hypochondrial pain in 100% of cases. The most common site of the aneurysm was main right hepatic, which constituted 41.7% of the cases. Interventional treatment was attempted in 11 cases (91.7% of the cases) through either coiling in four cases or arterial stenting in seven cases. Successful intervention occurred only in five cases (41.7% of the cases), and seven cases required surgical intervention.

Conclusion

Although it is a rare, pseudoaneurysm is a serious and challenging complication that requires multidisciplinary team management with cooperation between the interventional radiologist and the hepatopancreaticobiliary surgeon. Coiling or arterial stent insertion can solve the problem, but surgical treatment may be needed either after failure of interventional radiology treatment or in case of unstable patients who need urgent surgical treatment.

Keywords:

bile duct injury, hepatic artery pseudoaneurysm, iatrogenic pseudoaneurysm

Egyptian J Surgery 40:954–958
© 2022 The Egyptian Journal of Surgery
1110-1121

Introduction

Visceral aneurysms are rare, with a prevalence of ~1% [1].

Hepatic artery aneurysms are the second most common type, accounting for ~20% of all visceral aneurysms [2].

Pseudoaneurysm is a rare complication that can happen after any intervention like percutaneous cholangiography and stent insertion, laparoscopic or open cholecystectomy, biliary reconstruction, Whipple's procedure, or even liver transplant.

Laparoscopic cholecystectomy is one of the most commonly done general surgical procedures. The prevalence of bile duct injury (BDI) after laparoscopic cholecystectomy accounts for 0.2–0.6% and is still higher than open cholecystectomy, which accounts for 0.1%, and vascular injuries account for 25% of cases with BDI [3].

Vascular injury during cholecystectomy can be obvious during the procedure with evidence of bleeding, which may necessitate conversion to open for control or

inserting clips in a blind fashion which is considered a significant factor that causes BDI and vascular injury during laparoscopic cholecystectomy.

Arterial pseudoaneurysm can occur in any place according to the course of the hepatic artery and the site of the injury. It can happen in the right hepatic artery, cystic artery, main hepatic artery, or left hepatic artery.

The presentation of hepatic artery pseudoaneurysm can happen early within days after the procedure or months after and can be presented with a wide variety of presentations like right hypochondrial pain, melena, vomiting, hemorrhagic shock, or overt bleeding in the drains.

Management of hepatic artery pseudoaneurysm is very challenging, as it is a rare complication adding to the

This is an open access journal, and articles are distributed under the terms of the Creative Commons Attribution-NonCommercial-ShareAlike 4.0 License, which allows others to remix, tweak, and build upon the work non-commercially, as long as appropriate credit is given and the new creations are licensed under the identical terms.

complexity and severity of the cases with high incidence of morbidity and mortality. Treatment must be in a specialized hepatopancreaticobiliary (HPB) unit with a multidisciplinary team for decision making.

The treatment is either through interventional radiology (IR) by insertion of an arterial stent or coiling at the neck of the aneurysm versus surgical intervention.

Surgical intervention is a risky procedure with risk of adding more injury or massive bleeding.

Patients and methods

We analyzed the data of 12 cases in a retrospective pattern. This research was performed at the Department of General Surgery, Ain Shams University Hospitals. Ethical Committee approval and written, informed consent were obtained from all participants. All cases were referred to our HPB unit in Ain Shams University Hospitals during the period between January 2017 and December 2020.

Inclusion criteria

All cases of hepatic artery pseudoaneurysm that presented to our unit, except post-liver transplant cases, were included.

Exclusion criteria

Postliver transplant cases were excluded.

Surgical intervention

Surgical intervention for pseudoaneurysm is very challenging. Usually surgical intervention is done after failure of IR procedure. Surgical correction is usually done by right subcostal incision or a hockey stick incision. Attempt to do proximal control by exploring the hepatic artery proper proximal to the aneurysm then followed by dissection and excision of the aneurysm. Then, either ligation of the cystic artery stump is done in case if the aneurysm arising from the remnant of the cystic artery or reconstruction of the right hepatic artery through anastomosis of the distal end to the proximal end. Another way of reconstruction is done in case of severe affection of the main hepatic artery, where the reconstruction was done by dissection of the splenic artery and anastomosing it to the distal end of the main hepatic artery. Biliary system was managed either by primary closure in case of small defect or bilioenteric reconstruction.

Results

The age of our patients ranged from 19 to 67 years, with a mean age of 39.9 years. Most of our

patients were female [seven (58.3%) patients] (Table 1).

The most common cause was following cholecystectomy, either laparoscopic or open cholecystectomy (seven cases were laparoscopic, constituting 58.3%, and open cholecystectomy was only one case, constituting 8.3%). Other causes constituted the rest of the cases, such as following percutaneous transhepatic cholangiography, following Whipple surgery, and blunt liver trauma, as shown in Table 1 and Fig. 1.

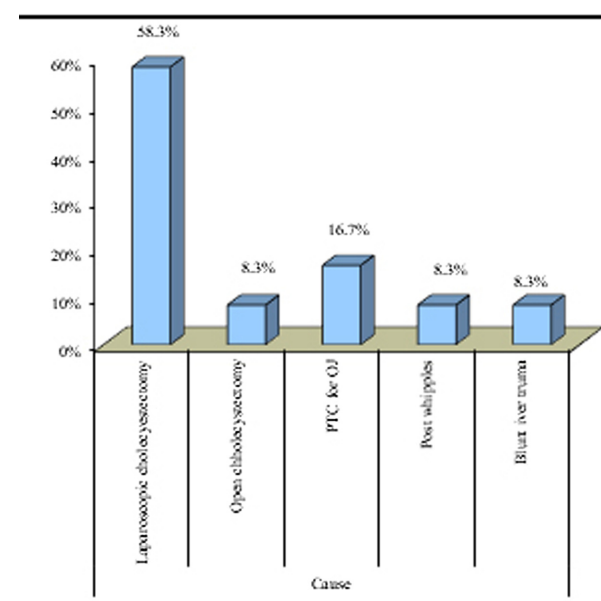
The time of presentation ranged from 2 to 17 weeks from the intervention, with median time of 3.5 weeks.

Table 1 Distribution and causes of pseudoaneurysm

N=12 [n (%)]	
Age	
Mean±SD	39.92±16.14
Range	19–67
Sex	
Female	7 (58.3)
Male	5 (41.7)
Cause	
Laparoscopic cholecystectomy	7 (58.3)
Open cholecystectomy	1 (8.3)
PTC for OJ	2 (16.7)
Following Whipple's surgery	1 (8.3)
Blunt liver trauma	1 (8.3)
Time from intervention (weeks)	
Median (IQR)	3.50 (2.5–9)
Range	2–17

IQR, interquartile range; PTC, percutaneous cholangiography.

Fig. 1



Procedures associated with pseudoaneurysm.

Acute cholecystitis was the most common original disease, which may be related to the difficulty of surgery during the acute attack.

Bleeding during surgery or during intervention was associated with eight cases (66.7%) of the whole cases, which can be an independent risk factor, and it indicates the difficulty of the procedure with high probability of complication.

The most common presentation was right hypochondrial pain and hypotension, which was present in all cases, requiring blood transfusion. Melena was present in nine cases (75% of cases). Six cases (50%) presented with vomiting. External bleeding in the drains was present in four cases (33.3% of the whole cases). Only three cases (25% of the cases) presented with obstructive jaundice, which required endoscopic retrograde cholangiopancreatography, which showed hemobilia and blood clots in the three bile cases (Table 2, Fig. 2).

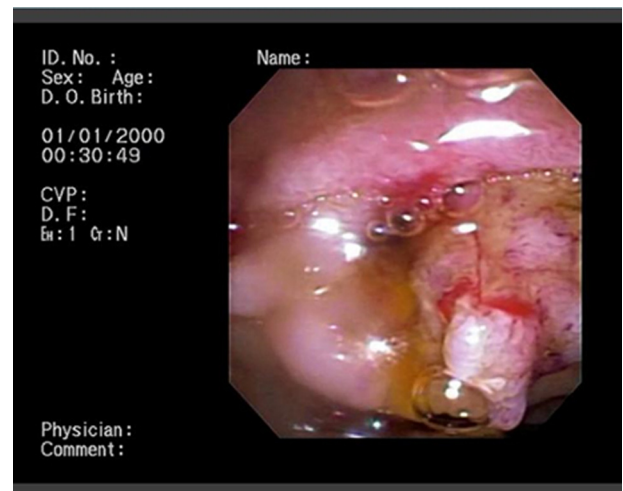
The most common site of the aneurysm was main right hepatic artery in five cases, which constituted 41.7% of the cases, followed by the right posterior hepatic artery in three cases (25% of the cases). Aneurysm arising from the cystic artery stump occurred in two cases (16.7% of the cases), and the main hepatic artery aneurysm had happened in two cases (16.7% of the cases) (Fig. 3).

Interventional treatment was attempted in 11 cases (91.7% of the cases) through either coiling in four cases

and arterial stenting in seven cases. Successful intervention occurred only in 5 cases (41.7% of the cases), and seven cases required surgical intervention.

Surgical treatment was tailored according to the radiological findings, intraoperative findings, and the hemodynamic stability of the patient. One case required right hepatectomy (14.3%). This case had multiple right lobe infarctions and abscesses after stent insertion. One case required surgical excision of the aneurysm and reconstruction of the main

Fig. 2

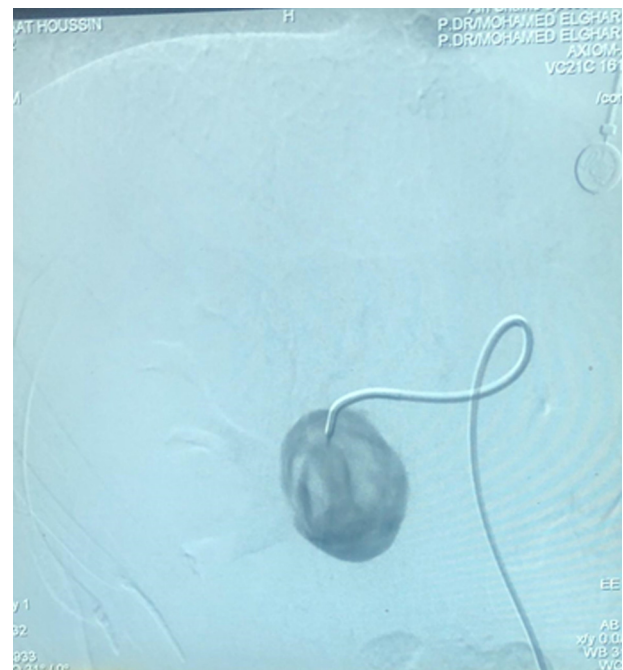


Hemobilia during endoscopic retrograde cholangiopancreatography.

Table 2 Presentations of hepatic artery pseudoaneurysm

	No. (%)
Right hypochondrial pain	
Yes	12 (100.0)
Melena	
No	3 (25.0)
Yes	9 (75.0)
Vomiting	
No	6 (50.0)
Yes	6 (50.0)
Obstructive jaundice	
No	9 (75.0)
Yes	3 (25.0)
External bleeding	
No	8 (66.7)
Yes	4 (33.3)
Hypotension	
No	0
Yes	12 (100.0)
Blood transfusion	
No	0
Yes	12 (100.0)

Fig. 3



Aneurysm arising from the cystic artery stump.

hepatic artery with a splenic artery graft. Two cases required just excision and ligation of the aneurysm base, which was at the stump of the cystic artery (28.6% of the cases) (Fig. 4).

Three cases had biliary fistula after excision of the aneurysm. Biliary reconstruction with Roux-en-Y hepaticojejunostomy was done in two cases. Only one case had a very small fistula with the common hepatic duct, which was closed primarily with three stitches of PDS 6/0 suture without stent (Fig. 5).

Mortality rate was 25% (three cases), and the causes of mortality were severe bleeding, disseminated intravascular coagulopathy (DIC), and liver abscess.

Discussion

Visceral aneurysms are a rare pathology, and hepatic artery aneurysms are the second common after splenic

artery aneurysms [4]. Hepatic arterial aneurysms can be either true or false aneurysms. False aneurysms, although rare, can result as a complication from any surgical or radiological intervention in the HPB system or intra-abdominal inflammatory process as pancreatitis [5]. When pseudoaneurysm happens, management is very challenging, with high rate of morbidity and mortality.

Bulut *et al.* [5] showed that iatrogenic injury is the most common cause of hepatic artery pseudoaneurysms, especially after laparoscopic cholecystectomy. In our study, iatrogenic injury was the main cause of the cases with postcholecystectomy pseudoaneurysms, constituting about 66.6% of the cases, but other iatrogenic causes were after percutaneous cholangiography and after Whipple's surgery. A review done by Pulitano and his colleagues showed that right hepatic arterial injury in association with BDI is seen in about 12–47%, which can be either ligation, transaction, or thrombosis [6].

In all these cases, the primary intervention was done either in our hospital and the patients were referred to our HPB unit or done outside the hospital and the patients were referred from other hospitals. Therefore, the incidence of this complication cannot be calculated, and also some pseudoaneurysms can pass asymptomatic as they may become thrombosed [5].

Sansonna *et al.* [7] reported a risk of pseudoaneurysm in laparoscopic cholecystectomy done for acute cholecystitis of 3 in 100 000 and during emergency cholecystectomy of 1 in 100 000, and the prevalence of pseudoaneurysms in the context of BDI is 2.6–4.5%.

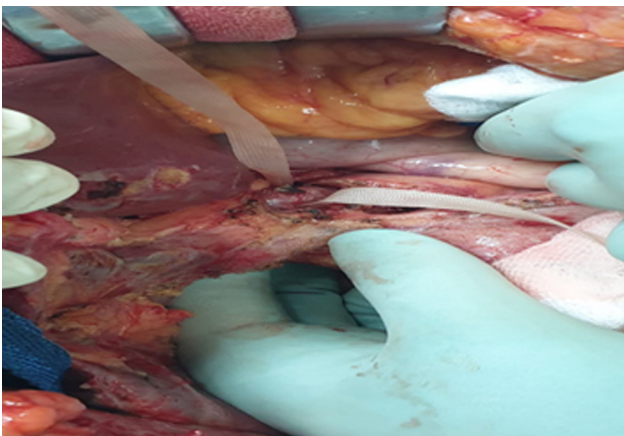
The time interval between the primary intervention and the presentation (the silent period) ranged between 2 and 17 weeks in our study.

Some literature studies reported the range was between 13 months and 5 years after cholecystectomy [5].

In our study, right hypochondrial pain was the main presenting complaints in almost all cases followed by melena, which was present in 75% of cases. This was close to what Bulunt *et al.* [5] reported, where upper gastrointestinal bleeding was present in about two-thirds of the cases.

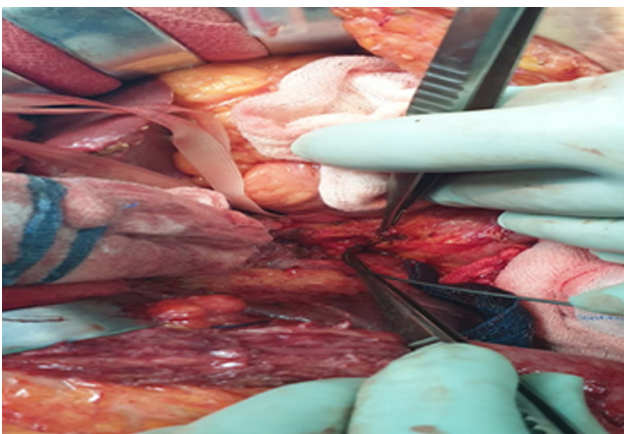
Upper gastrointestinal bleeding or hemobilia after laparoscopic cholecystectomy should be investigated. Duplex is a useful noninvasive tool but is operator

Fig. 4



Proximal control of the hepatic artery before attacking the aneurysm.

Fig. 5



Probing of the biliary fistula before reconstruction.

dependent, and the detection of the pseudoaneurysm is not always successful. Computed tomography angiography is our best way of investigation and very helpful in detecting the size and the origin of the pseudoaneurysm but needs a hemodynamically stable patient, so it is usually done after successful resuscitation.

In our study, the origin of the pseudoaneurysm as the right hepatic artery was seen in about 66% of the cases and from the cystic artery stump from 16.1% of the cases, which was similar to what Bulut *et al.* [5] reported, where the origin was from the right hepatic artery in two-thirds of the cases.

The first line of treatment was through IR either by coiling or stenting, as it is less invasive and does not need general anesthesia. IR treatment was attempted in 91.6% of cases. This treatment was successful only in 41.7% of the cases, and surgical intervention was needed in 58.3%. The success rate of interventional treatment in our study was much less than what Bulut *et al.* [5] reported. They reported that interventional treatment was successful in 81% of the cases. The aim of surgical intervention is to reconstruct the arterial anatomy to the same as much as possible of the liver parenchyma. In the cases where the origin was from the cystic duct stump, ligation of the stump was done.

More complex surgery was needed in cases where the aneurysm was in the main hepatic artery where reconstruction with the splenic artery was needed. If reconstruction is not possible, right hepatectomy may be needed to avoid the occurrence of liver infarction and abscess.

Mortality rate was 25% in our study, and the causes of death were DIC, liver abscess, and severe bleeding. This mortality rate was slightly higher than what Bulut *et al.* [5] reported, which was 17%. This difference can be owing to the higher number of cases with more experience in treatment.

Although a limited number of the cases were present in our study, which was owing to it being an uncommon complication and also the difficulty in detection, the management plan and the result were comparable to different literature studies.

Conclusion

Hepatic artery pseudoaneurysm is a rare but serious complication, which may occur after any intervention but mostly after laparoscopic cholecystectomy. Any patient who presents with unexplained abdominal pain or upper gastrointestinal bleeding after laparoscopic cholecystectomy should be fully investigated for the possibility of hepatic artery pseudoaneurysm. IR treatment can be successful and may avoid surgical treatment. Surgical treatment is challenging and should be done in a specialized unit and done by surgeons with vascular reconstruction experience. Avoidance of BDI and good knowledge of the arterial anatomical variation are the most important steps in prevention of such complications.

Financial support and sponsorship

Nil.

Conflicts of interest

There are no conflicts of interest.

References

- 1 Panayiotopoulos YP, Taylor PR, Assadourian R. Aneurysms of the visceral and renal arteries. *Ann R Coll Surg Engl* 1996; 78:412–419.
- 2 Abbas MA, Fowl RJ, Stone WM, Panneton JM, Oldenburg WA, Bower TC. Hepatic artery aneurysm: factors that predict complications. *J Vasc Surg* 2003; 38:41–45.
- 3 Strasberg SM, Helton WS. An analytical review of vascular injury in laparoscopic and open cholecystectomy. *HPB* 2010; 13:1–14.
- 4 Pasha SF, Glovizki P, Stanson AW, Kamath PS. Splenic artery aneurysms. *Mayo Clin Proc.* 2007; 82:472–479.
- 5 Bulut T, Yamaner S, Bugra D, Akyuz A, Acarli K, Poyani A. False aneurysm of the hepatic artery after laparoscopic cholecystectomy. *Acta Chir Belg* 2002; 102:59–463. DOI:0, 1080/00015458.2002.67952.
- 6 Pulitano C, Parks RW, Ireland H, Wigmore SJ, Garden OJ. Impact of concomitant arterial injury on the outcome of laparoscopic bile duct injury. *Am J Surg* 2011; 201:238–244.
- 7 Sansonna F, Boati S, Sguinzi R, Migliorisi C, Pugliese F, Pugliese R. Severe hemobilia from hepatic artery pseudoaneurysm. *Case Rep Gastrointest Med* 2011; 2011:925142.