

Single incision versus conventional four ports laparoscopic cholecystectomy: a Prospective comparative study

Rawda Seifeldin, Amir F. Abdelhamid, Osama H. Abd-Raboh, Mostafa M. Elsheikh, Maher Elgingehy

Department of General Surgery, Faculty of Medicine, Tanta University, Tanta, Egypt

Correspondence to Rawda Seifeldin, MSc, Department of General Surgery, Faculty of Medicine, Tanta University, Al Nady Street, Tanta Second, Alharbiyah, Tanta 27341, Egypt. Tel.: +201003141269; e-mail: rawda.ibrahim@med.tanta.edu.eg

Received: 24 January 2022

Accepted: 25 January 2022

Published: 10 October 2022

The Egyptian Journal of Surgery 2022, 41:437–448

Background

Laparoscopic cholecystectomy (LC) is now considered the gold standard for the treatment of symptomatic gallstone disease. Traditionally, it was performed with a four-port approach. Recently, attempts have been done to improve the established technique of LC aiming to minimize the invasiveness of this procedure by reducing the number and size of the surgical ports and instruments. Navarra and colleagues described the first single-incision laparoscopic surgery in 1997. It was performed using multiple ports through a single incision with the removal of the gallbladder through a single periumbilical skin incision.

Patients and methods

This prospective study was carried out on 40 patients with uncomplicated chronic calculous cholecystitis categorized into two equal groups. Group A patients underwent single-incision LC, whereas conventional LC was done in group B patients in the Gastrointestinal and Laparoscopic Surgery Unit, General Surgery Department, Tanta University Hospitals, during the study period (12 months, from November 2019 to November 2020 on 40 patients).

Results

There was no statistically significant difference between both groups regarding patient characteristics, and preoperative medical or surgical history. The operative time was significantly longer in group A patients with a mean 85.8 ± 25.3 min compared with group B in which the mean was 71 ± 2.6 min. The difference between both groups regarding postoperative pain, analgesia intake, and hospital stay was insignificant. Cosmetic satisfaction was significantly better in group A compared with group B.

Conclusion

Single-incision laparoscopic cholecystectomy is a safe, feasible but challenging procedure that needs experienced hands in handling the instruments in lack of triangulation.

Keywords:

chronic calculous cholecystitis, conventional laparoscopic cholecystectomy, gallstones, laparoscopic cholecystectomy, single-incision laparoscopic cholecystectomy, single incision

Egyptian J Surgery 2022, 41:437–448
© 2022 The Egyptian Journal of Surgery
1110-1121

Introduction

Conventional laparoscopic cholecystectomy (CLC) has become the gold standard for the treatment of benign gallbladder (GB) disease since it was first performed in 1985 [1].

Over the past few years, many surgeons have tried to improve the established technique of laparoscopic cholecystectomy (LC) assuming that it could be done through a single incision in the umbilicus without compromising the safety or benefit of the procedure [2,3].

The first single-incision laparoscopic cholecystectomy (SILC) was reported by Navarra *et al.* [4], suggesting that this new technique might be associated with not only less pain but also less hospital stay.

Eventually, SILC was reported to be a safe and feasible procedure with better cosmetic results and less postoperative pain by many comparative studies [1,5]. That is why it gained some acceptance internationally and currently accounts for 16% of LC performed in Japan [6].

In contrast, one of the main disadvantages of the single-incision approach is the loss of triangulation, which refers to the adequate distance between instruments to avoid conflicts and allowing adequate exposure of the operative field. Besides, loss of triangulation may

This is an open access journal, and articles are distributed under the terms of the Creative Commons Attribution-NonCommercial-ShareAlike 4.0 License, which allows others to remix, tweak, and build upon the work non-commercially, as long as appropriate credit is given and the new creations are licensed under the identical terms.

cause prolongation of operative time in case of lack of experience in this new technique [7,8].

Some studies have revealed similar complication rates in SILC compared with CLC. Others report higher rates of incisional hernia, wound infection, and intraoperative bile leakage. This is why there is a controversy about SILC, due to scanty information, short follow-up periods, and limited number of patients involved. Therefore, further studies are necessary to clearly identify the risks and benefits of SILC [9].

Aim

Our aim was to compare single incision with the conventional four-port LC with respect to operative time, postoperative pain, hospital stay, intraoperative and postoperative complications, and cosmetic satisfaction.

Patients and methods

This study is a prospective, randomized, controlled clinical trial that was carried out in the Gastrointestinal and Laparoscopic Surgery Unit, General Surgery Department, Tanta University Hospitals during the study period (12 months from November 2019 to November 2020 on 40 patients with uncomplicated chronic calculous cholecystitis). Written consents were obtained from all patients participated in this study after explaining the procedure and complications. Approval by the local ethical committee was obtained before starting this study. Patients were divided into two equal groups; A and B. Group A patients underwent SILC through a specialized port while group B patients underwent CLC. Allocation of patients to any group was randomized using the closed envelope method.

Inclusion criteria

- (1) Patients' age between 20 and 60 years.
- (2) BMI less than 35.
- (3) Patients with uncomplicated chronic calculous cholecystitis.

Exclusion criteria

- (1) Patients' age less than 20 years or more than 60 years.
- (2) BMI more than 35.
- (3) Complicated chronic calculous cholecystitis.
- (4) Acute cholecystitis.
- (5) Patients with major comorbidities as hepatic and cardiac ones.

Primary outcomes

Included patient cosmetic satisfaction about the scar(s).

Secondary outcomes

Included intraoperative, postoperative complications, conversion to CLC or open cholecystectomy, operative time, postoperative pain, and hospital stay.

Preoperative workup

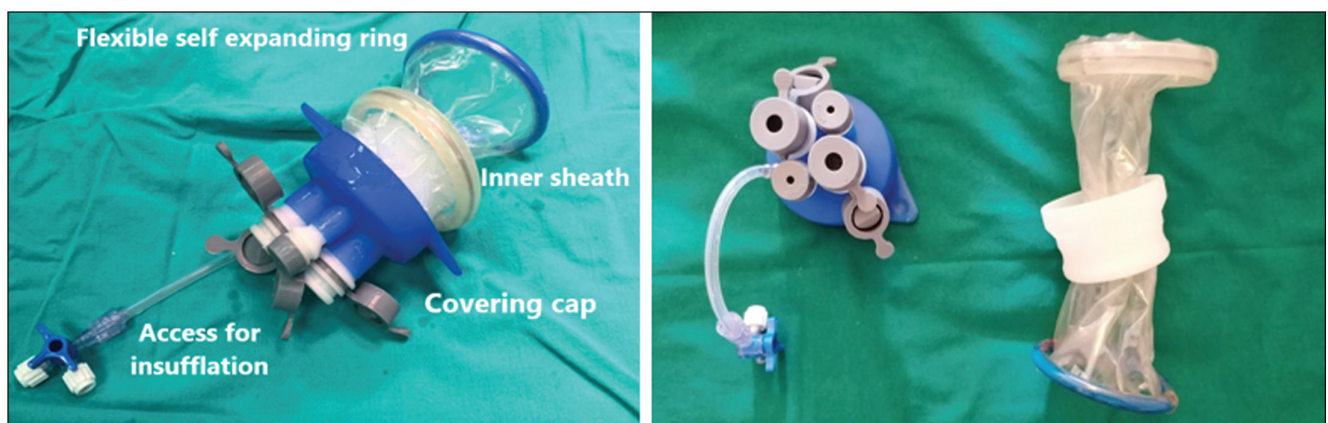
- (1) All patients were evaluated by thorough clinical examination and laboratory investigations as needed. Pelvi-abdominal ultrasound was done.

Operative techniques

Group A: single-incision laparoscopic cholecystectomy

- (1) We used an SILS multitrocar port (single-incision laparoscopic surgery), which is an FDA-approved access system.
- (2) It consists of an outer covering cap and an inner transparent sheath. The cap has two 5-mm ports and two 10-mm ports (reducible to 5 mm).

Figure 1

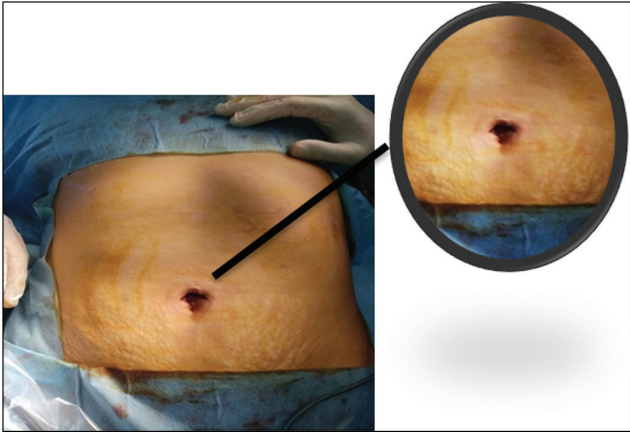


SILS multitrocar port. SILS, single-incision laparoscopic surgery.

The inner sheath has a plastic ring around and a flexible self-expanding ring, which allows the base of the port to remain inside the peritoneum (Fig. 1).

- (3) A 2–3 cm curvilinear supraumbilical incision was made; and the tissues were dissected to the fascia. A Kocher clamp was placed on the umbilical

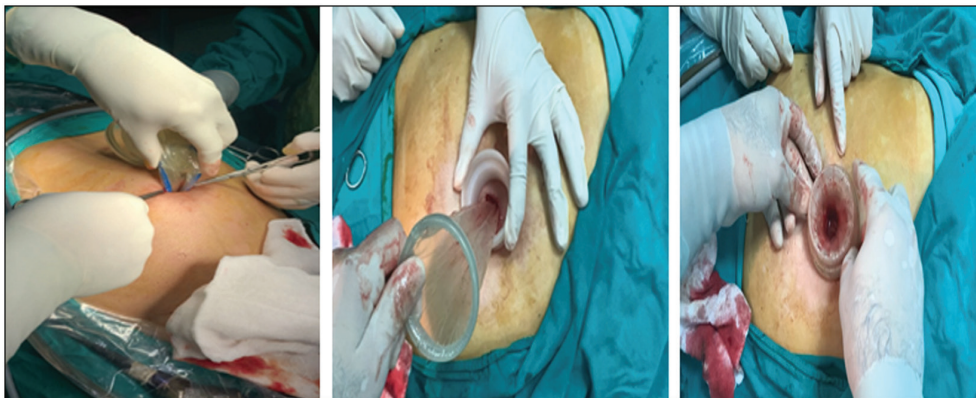
Figure 2



A 2–3 cm supraumbilical incision.

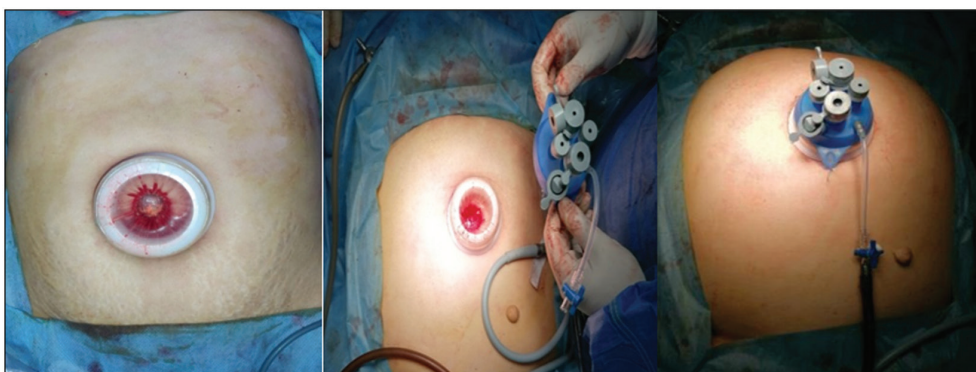
- raphe of the midline fascia and a 1.5-cm vertical fascial incision was made sharply (Fig. 2).
- (4) The internal flexible ring of the single port was folded to enter the abdominal cavity and the outer transparent sleeve was pulled up and rolled over to tighten the plastic ring against the inner abdominal fascia (Fig. 3).
- (5) The covering cap was put in place and two skin stitches were taken at 6 and 12 O'clock to hold it in place with the underlying skin (Fig. 4).
- (6) Pneumoperitoneum was achieved with a preset pressure of 12–14 mmHg and a 30° telescope was introduced.
- (7) The patients were placed in a reverse Trendelenburg position, with the right side elevated to keep the small bowel and colon away from the operative field (Fig. 5).
- (8) To retract the GB fundus, a 2–0 Prolene Suture on a straight needle was placed through the abdominal wall at the costal margin in the right upper quadrant, passed through the fundus of the GB, and brought back out of the abdominal wall near the entry site. Also, an endo-grasper was inserted through the 5 mm trocar within the

Figure 3



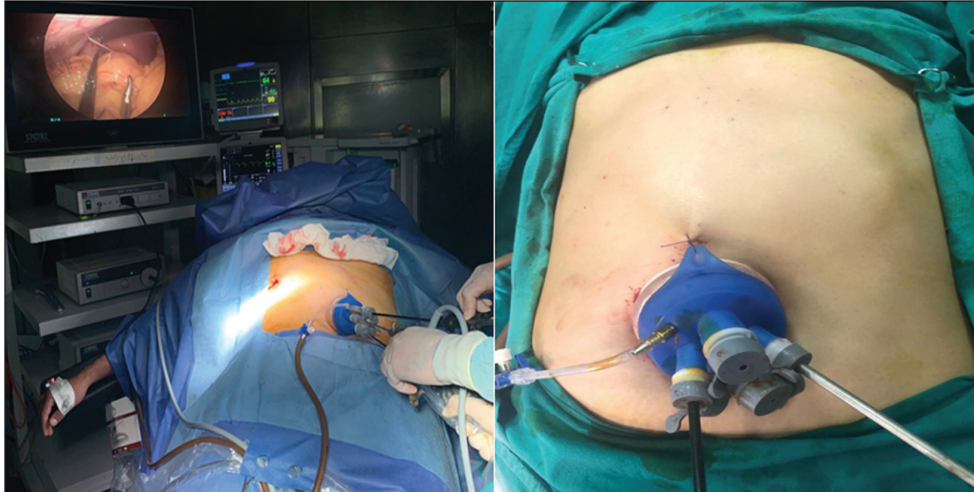
Placement of the SILS multitrocar port. SILS, single-incision laparoscopic surgery.

Figure 4



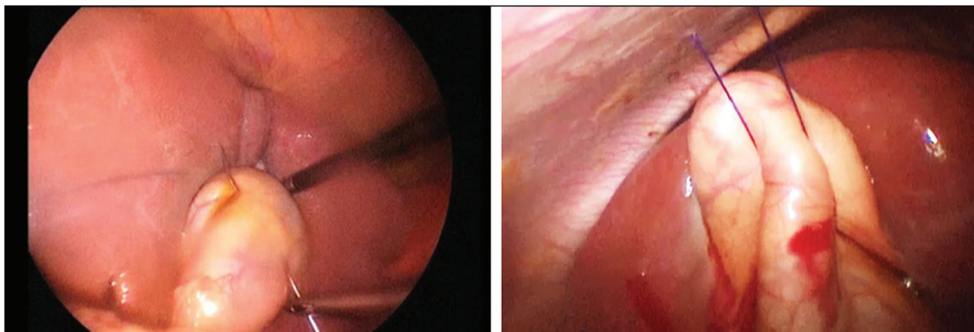
Placement of the covering cap.

Figure 5



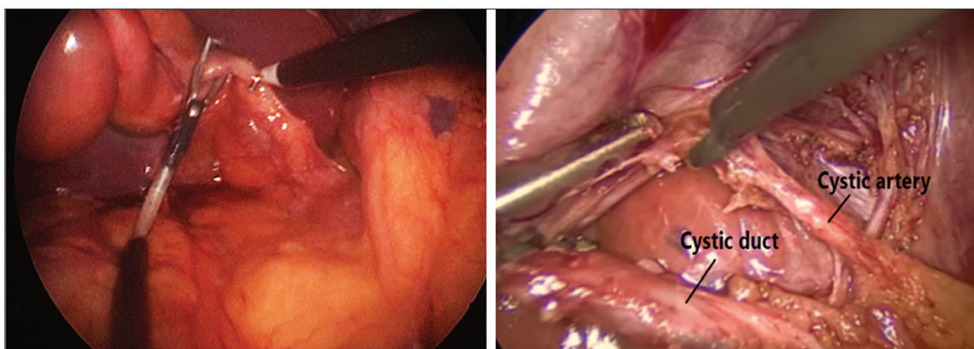
Patient lying in reverse Trendelenburg position.

Figure 6



Traction of the fundus by Prolene suture.

Figure 7



Dissection in the Calot triangle achieving the critical view of safety.

- single umbilical port to retract the fundus in some cases without the need for any sutures (Fig. 6).
- (9) The GB was laterally retracted by an endo-grasper, and a Maryland was alternatively used with the hook for dissection in the Calot triangle to identify the cystic artery and duct reaching the critical view of safety (Fig. 7).
 - (10) Curved and articulating instruments were used to allow adequate triangulation. Also, classic non-articulating straight instruments were used (Fig. 8).
 - (11) The cystic duct and artery were then clipped and transected (Fig. 9).
 - (12) The GB was dissected free from the liver bed using a hook monopolar cautery (Fig. 10).

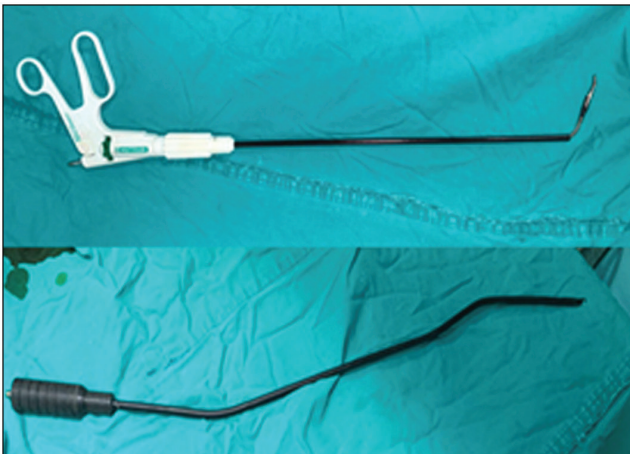
- (13) Once the GB was free, it remained attached to the abdominal wall by the Prolene suture; the suture was then removed from the GB and the specimen was extracted through the umbilical incision along with a single system (Fig. 11).
- (14) Fascia was closed by Prolene 0 sutures and the skin was closed by 4-0 Vicryl sutures (Fig. 12).

Group B: conventional laparoscopic cholecystectomy

- (1) The first 10 mm port was inserted just above the umbilicus after pneumoperitoneum was achieved using Veress needle with a preset pressure of 12–14 mmHg. A 30° telescope was inserted so that the rest of trocars was inserted under vision.
- (2) Another epigastric 10 mm port was introduced into the midline 2 cm below the xiphoid process just to the right of the falciform ligament.

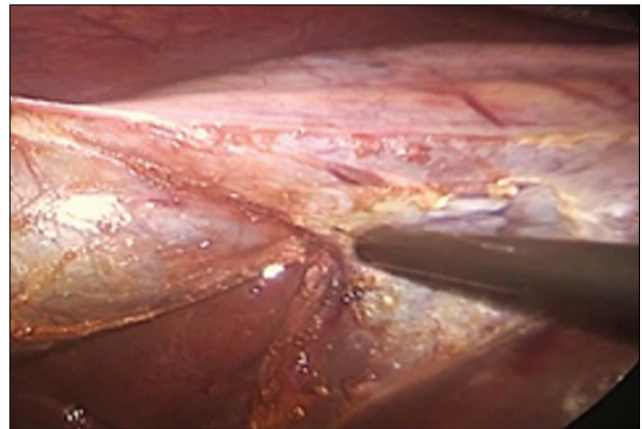
- (3) A 5 mm trocar was introduced into the right hypochondrium in the anterior axillary line 3 cm below the costal margin.
- (4) Another 5 mm trocar was inserted into the right midclavicular line around 2 cm from the costal margin.
- (5) The patients were placed in a reverse Trendelenburg position, the right side was elevated to allow falling of the small bowel and colon away from the operative field (Fig. 13).
- (6) Two graspers were inserted through the two lateral ports to retract the fundus and Hartmann pouch of the GB. This step helps straightening the cystic duct (i.e. retracts it at 90° from common bile duct (CBD) and helps protect the CBD from injury) (Fig. 14).
- (7) Dissection at the Calot triangle was carefully done to expose both the cystic duct and cystic artery aiming to reach the critical view of safety,

Figure 8



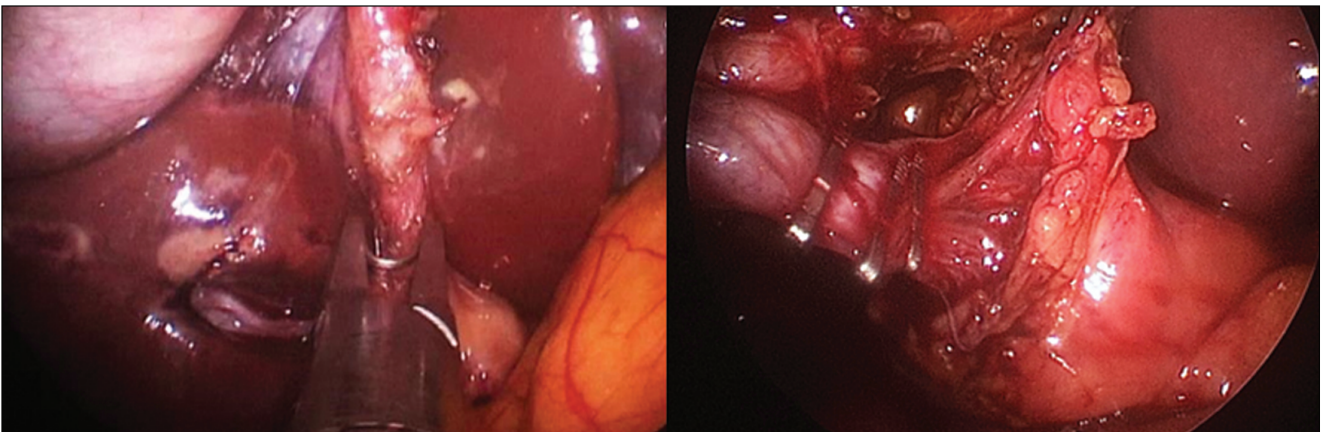
Curved and articulating laparoscopic instruments.

Figure 10



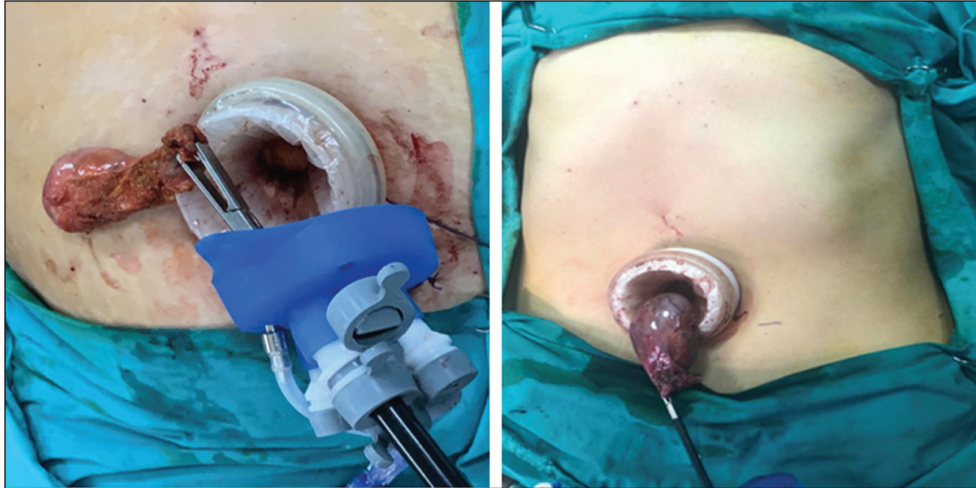
Dissection of the GB bed. GB, gallbladder.

Figure 9



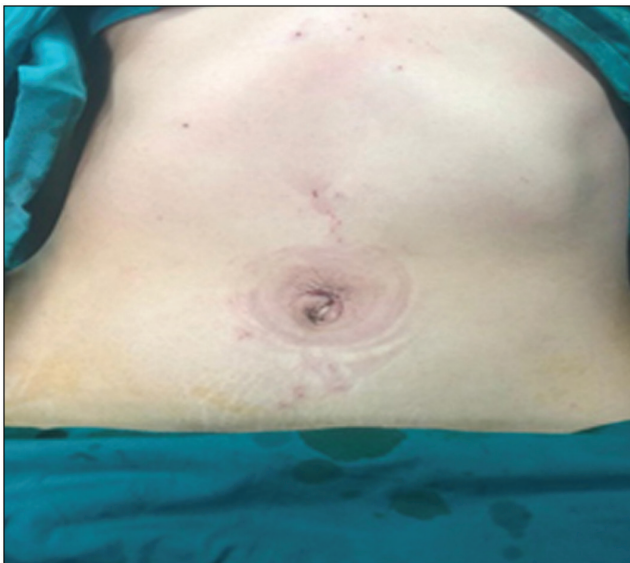
Clipping and transection of cystic duct and artery.

Figure 11



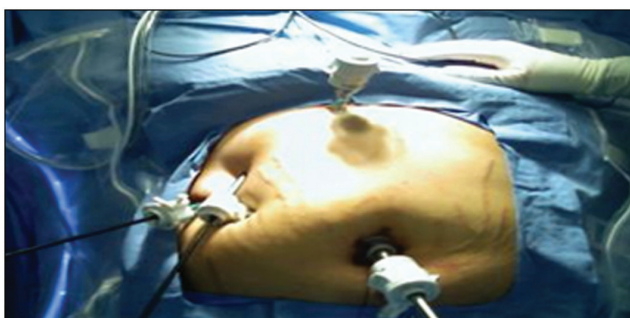Extraction of the gallbladder through the port.

Figure 12



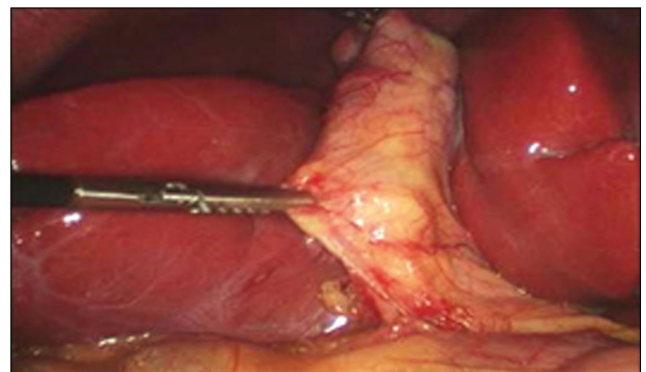
Wound was closed with Vicryl 4/0 by intradermal sutures.

Figure 13



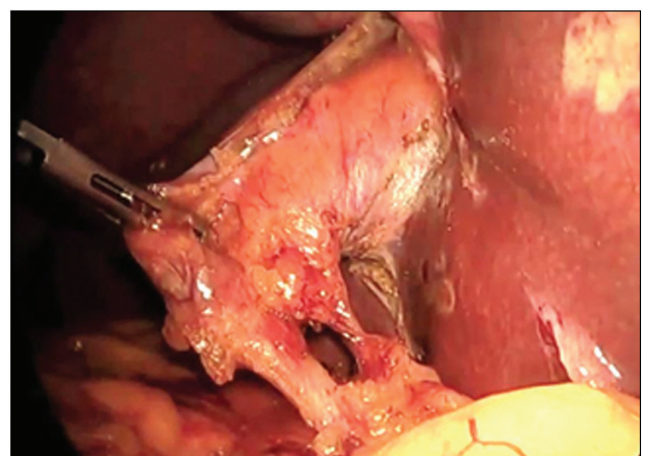
Positioning of the patient and trocar placement.

Figure 14



Retraction of the gallbladder.

Figure 15

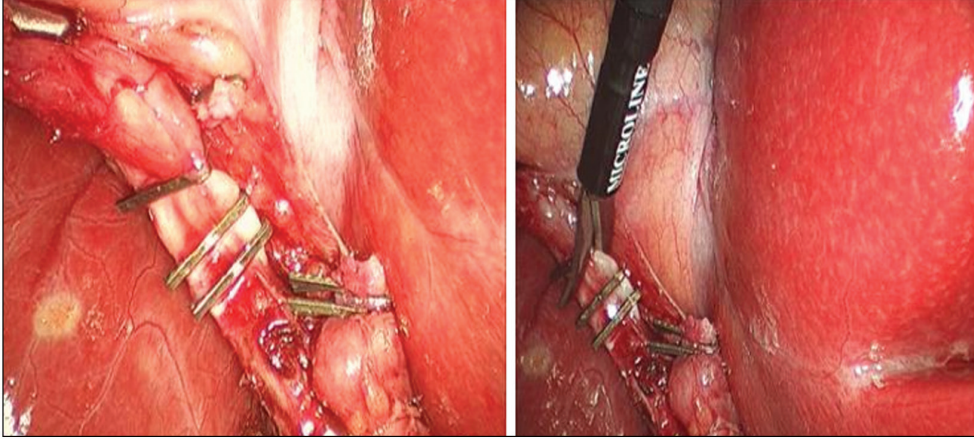


Achieving the critical view of safety.

which is obtained when the surgeon can see only two structures (the cystic duct and artery) (Fig. 15).

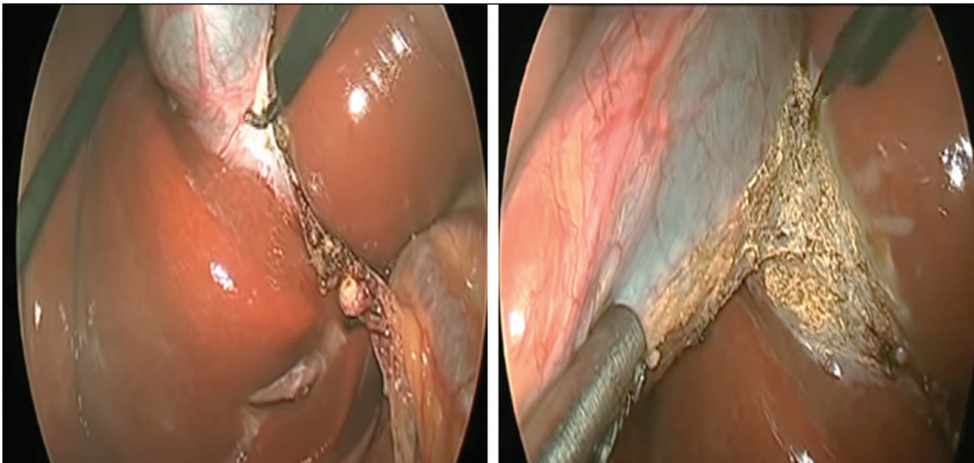
- (8) The cystic duct and artery were dissected, skeletonized, and transected after clipping (Fig. 16).
- (9) The infundibulum was retracted, and a hook was used to dissect the GB from its bed through the cystic plate (Fig. 17).

Figure 16



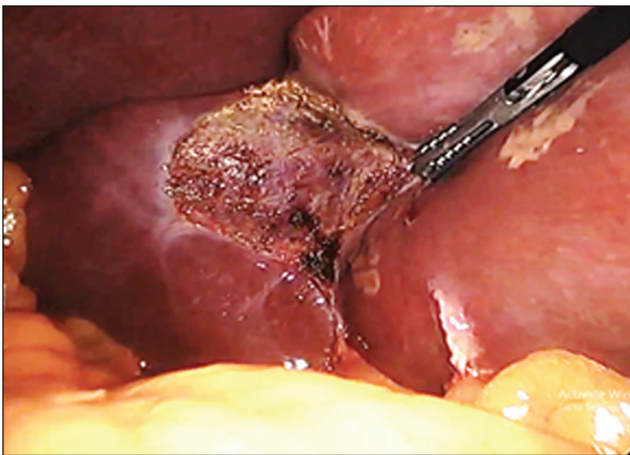
Clipping and transection of cystic duct and artery.

Figure 17



Dissection of the gallbladder from its bed.

Figure 18



GB fossa after separation of the specimen. GB, gallbladder.

(10) Before complete separation of the GB, a final inspection of the GB fossa and the clipped cystic artery and duct were done to control any bleeding points if present (Fig. 18).

- (11) The specimen was separated and removed through the epigastric port using claw forceps.
- (12) A drain was inserted through the lateral port at the anterior axillary line when needed (if there is gross intraperitoneal bile spillage or bleeding).
- (13) The two lateral ports were removed under vision and the skin was sutured by Prolene 3-0.
- (14) The epigastric wound was closed in two layers; subcutaneous sutured by Vicryl 2-0 and skin sutured by Prolene 3-0.
- (15) The supraumbilical wound was closed in three layers; the fascia was closed by Vicryl 0, subcutaneously and the skin as before.

Postoperative care and follow-up

- (1) The patient was extubated, transferred to the ward, and instructed to mobilize and resume oral fluid intake 6 h after complete recovery from general anesthesia.

- (2) On the operative and first postoperative days (PODs), postoperative abdominal and shoulder pains were assessed and recorded every 8h, starting after complete recovery from analgesic effect of anesthesia.
- (3) Severity of the pain was assessed using the numerical rating scale. Patients were asked to rate the pain from 0 to 10. Zero indicates no pain, while 10 represents the worst pain.
- (4) All patients received same analgesia according to the analgesic ladder starting with paracetamol, then paracetamol+NSAIDs.
- (5) Antibiotic was prescribed to all patients twice daily while hospitalized in the form of Amoxicillin clavulanic 1000 mg after a sensitivity test.
- (6) Patients were discharged once they tolerated full oral intake and no complications were detected. They were asked to come to the outpatient clinic on the seventh POD and then monthly for 6 months.
- (7) Follow-up of postoperative pain after discharge was done by a phone call with the patient once a day for 2 days and the pain score was recorded.
- (8) On the first visit to the outpatient clinic after 1 week, the patient was evaluated for any postoperative complications, stitches were removed after the wound was examined for signs of infection, seroma, and dehiscence.
- (9) Patient satisfaction about the scar was recorded after 1 week and 1 month later on a scale of 3° in the form of unsatisfied, satisfied, or very satisfied.
- (10) All patients underwent strict follow-up for incidence of incisional hernia by local examination of wound and ultrasound when suspected on monthly basis for 6 months.

Results

There was no statistically significant difference between both groups regarding age, sex, BMI, preoperative medical or surgical history.

The operative time was significantly longer in the SILC group as it ranged from 65 to 130 min with a mean 85.8 ± 25.3 (Table 1). The first five cases had a longer operative time with a mean 119 ± 16.7 min compared with the last five ones, which had a significantly shorter

time with a mean of 71 ± 2.6 min. In the CLC group, it was shorter as it ranged from 38 to 60 min with a mean of 45.05 ± 6.59 (Fig. 19).

Many intraoperative difficulties were encountered in both groups, in group A, two cases of fine adhesions, one case of coarse adhesion, and one case of thick-walled GB studded with stones. In group B, fine adhesions were found in three (15%) cases; coarse adhesions were encountered in two (10%) cases in group B, which were associated with difficult dissection of the Calot triangle. Large size GB with mucocele was found in one (5%) case among group B patients.

Intraoperative complications were bleeding occurred in five (12.5%) cases; three (15%) were in group A and two (10%) were in group B. Only one in group A was significant (about 200ml). GB perforation with bile spillage occurred in five (12.5%) cases, three (15%) in group A and two (10%) in group B and suction irrigation was done (Table 2). The difference between both groups regarding difficulties and intraoperative complications was insignificant ($P > 0.05$).

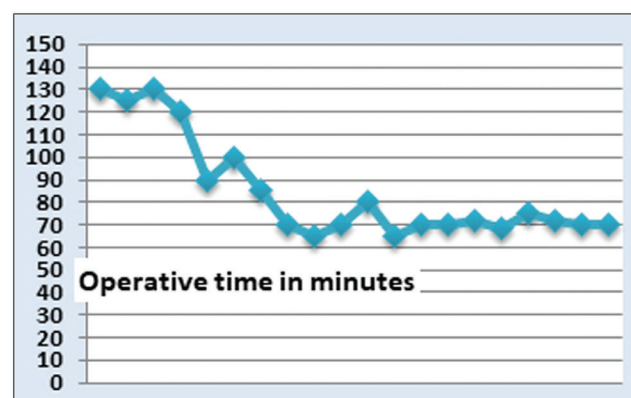
Two (10%) cases in group A were converted to CLC; one case was because of thick-walled GB studded with stones, which made dissection of the Calot very difficult and it was unsafe to proceed with SILC. The other one was due to significant bleeding from the cystic artery during dissection, which was managed after conversion by clipping of the bleeder after compression by a gauze and a drain was inserted. There was no conversion to open cholecystectomy in both groups.

Concerning postoperative pain, group A patients suffered less pain during all times of follow-up with a mean of 2.38 ± 0.4 than group B with a mean of 2.47 ± 0.47 (Table 3). The difference between both groups was found to be insignificant ($P > 0.05$).

Table 1 Operative time in both groups

	Group A (N=20)	Group B (N=20)	t	P
Operative time (min)				
Range	65–130	38–60	-7.454	<0.001
Mean±SD	85.8±25.3	45.05±6.59		

Figure 19



Change of operative time for group A over the study time.

Table 2 Intraoperative difficulties and complications in both groups

	Group A (N=20) [n (%)]	Group B (N=20) [n (%)]	χ^2	P
Intraoperative difficulties				
Fine adhesions	2 (10)	3 (15)	2.222	0.528
Coarse adhesions	1 (5)	2 (10)		
Mucocele	0	1 (5)		
GB studded with stones	1 (5)	0		
Intraoperative complications				
Bleeding	3 (15)	2 (10)	0.000	1
GB perforation	3 (15)	2 (10)		

GB, gallbladder.

Table 3 Postoperative pain score according to numerical rating scale in both groups

Mean of postoperative pain score (NRS 1–10)	Group A (N=20)	Group B (N=20)	t	P
Operative day				
1st 8 h	2.95±0.68	3.2±0.76	1.422	0.171
2nd 8 h	2.8±0.61	2.95±0.68	0.900	0.379
3rd 8 h	2.55±0.6	2.7±0.57	1.143	0.267
1st POD				
1st 8 h	2.45±0.51	2.55±0.6	0.698	0.494
2nd 8 h	2.35±0.58	2.35±0.67	0	1
3rd 8 h	2.3±0.57	2.3±0.57	0	1
1st day after discharge	2±0.64	1.95±0.6	-0.369	0.716
2nd day after discharge	1.75±0.47	1.8±0.5	0.698	0.494
Mean±SD of pain score of all follow-up times	2.38±0.4	2.47±0.47	0.652	0.518

NRS, numerical rating scale; POD, postoperative day.

Table 4 Analgesia intake and hospital stay in both groups

	Group A (N=20) [n (%)]	Group B (N=20) [n (%)]	t/ χ^2	P
Analgesia intake				
Paracetamol	18 (90)	16 (80)	0.0124	1
Paracetamol+NSAID	2 (10)	4 (20)		
Hospital stay (in days)				
Mean±SD	1.2±0.5	1.15±0.3	-0.3697	0.716

Paracetamol was effective in controlling early postoperative pain in 34 (85%) patients; 18 (90%) patients in group A and 16 (80%) in group B. Six (15%) patients [two (10%) patients in group A and four (20%) in group B] required addition of NSAID in the form of ketorolac injection twice a day with paracetamol to control postoperative pain (Table 4). The difference between both groups was statistically insignificant ($P>0.05$).

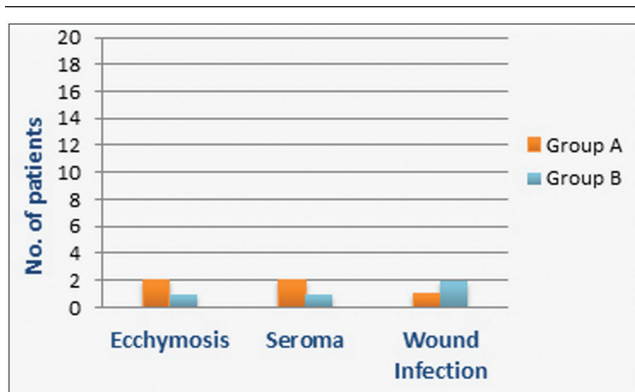
The mean of hospital stay was 1.2 ± 0.5 days in group A and it was 1.15 ± 0.3 days in group B (Table 4). The difference between both groups was statistically insignificant ($P>0.05$).

Regarding postoperative wound complications, ecchymosis was found in two (10%) patients in group A and one (5%) patient in group B while seroma occurred in two (10%) patients of group A and one (5%) patient in group B. Wound infection occurred in three (7.5%) patients; one (5%) in group A and

two (10%) in group B and they were managed by antibiotic and showed improvement within 1 week (Fig. 20). Incisional hernia did not occur in any patient of both groups during follow-up in the outpatient clinic up to 6 months postoperatively as examined clinically and excluded by ultrasound if needed. No major intraoperative or postoperative complications like biliary or major vascular injuries were recorded. The difference between both groups was statistically insignificant for all complications collectively ($P>0.05$).

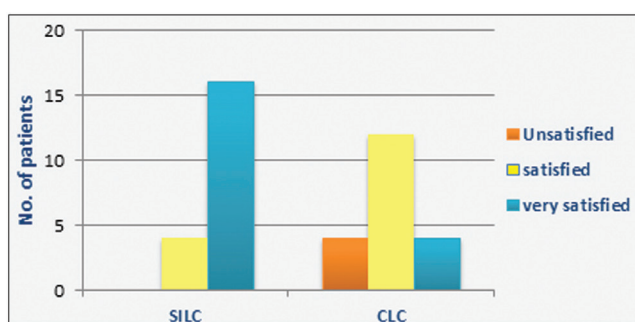
Regarding cosmetic satisfaction, 16 (80%) patients in group A reported that they were very satisfied and four (20%) patients were just satisfied, while in group B, four (20%) patients were very satisfied, 12 (60%) were satisfied, and four (20%) patients were unsatisfied (Fig. 21). The difference between both groups regarding cosmetic satisfaction was significantly higher among the SILC group patients compared with the CLC group patients ($P<0.001$) (Fig. 21).

Figure 20



Postoperative wound complications in both groups.

Figure 21



Cosmetic satisfaction in SILC and CLC groups. CLC, conventional laparoscopic cholecystectomy; SILC, single-incision laparoscopic cholecystectomy.

Discussion

Single-incision laparoscopic surgeries have emerged recently as a potential alternative to conventional laparoscopy with less invasiveness [10]. The rationale for the SILC includes many potential benefits such as minimizing morbidity related to unnecessary trocars through fewer traumas to the abdominal wall, fewer complications, higher patient comfort, less postoperative pain, and better cosmetic results because of a scarless procedure by working through a small unique incision [11,12,13]. However, SILC is a challenging technique due to inadequate triangulation of instruments, limited exposure, and visualization [14,15].

Today, CLC and SILC are the main approaches for LC. Randomized, controlled trials and meta-analyses have compared SILC with CLC, but results are still controversial [16,17].

The operative time was much longer in the SILC group with a range from 65 to 130 min and a mean of 85.8 ± 25.3 . This wide range with a high standard deviation is explained by lack of our experience with

this new technique, especially in handling the special port and roticulating instruments in the first cases in which the mean was 119 ± 16.7 in the first five cases. Eventually the operative time was significantly shorter in the last cases with rising learning curve and the mean was 71 ± 2.6 in the last five ones. In group B, it was shorter as it ranged from 38 to 60 min with a mean of 45.05 ± 6.59 , which agreed with the study by Hajong *et al.* [2] in which the mean operative time was longer in the SILC group (69 ± 4.00 vs. 38.53 ± 4.00 min), which was statistically significant ($P < 0.05$). This longer operative time may be referred to the use of limited instruments and difficult ergonomics associated with the single-port technique. Also, our results were consistent with all nine studies included in the meta-analysis by Evers *et al.* [14], which reported the operating time according to the calculated mean difference, in which there was a significant longer operating time in the SILC. We disagreed with the results of a study by Subirana *et al.* [18], which reported that the operative time was similar for SILC with a mean of 57.1 ± 20.67 min and CLC with a mean of 53.89 ± 28.05 min with no statistical differences.

Lee *et al.* [9] analyzed retrospectively the postoperative complications of SILC in 817 patients. There was intraoperative difficulty in the form of poor visualization of the Calot triangle in SILC that was noticed in 79 (9.7%) cases. So, they were converted to multiport laparoscopy. This is comparable to our results in which intraoperative difficulties were also present in the form of fine adhesions in two (10%) cases in group A; one of them was with duodenum and the other one was with the omentum, which was managed by adhesiolysis with combined sharp and blunt dissection. Conversion to CLC was done in two (10%) cases; one (5%) case showed coarse adhesions causing difficult dissection of the Calot and prolongation of the operative time with minor bleeding which is it was converted to CLC by introducing extra three ports. The other one (5%) showed a thick-walled GB studded with stones, which made it difficult to retract the GB by the stitch on the abdominal wall obscuring the field, which was complicated by significant bleeding from the cystic artery during dissection and it was unsafe to proceed with SILC and that why we converted it to CLC after introduction of a gauze for compression, and bleeding was then controlled by clipping of the bleeder after conversion followed by suction irrigation and a drain was inserted, which was removed on the second POD. In group B, fine adhesions were found in three (15%) cases. All of them were with the duodenum and sharp dissection with monopolar electrocautery was done for adhesiolysis with no complications. Coarse adhesions were present in two (10%) cases in group B, which were

associated with difficult dissection of the Calot triangle. Step-by-step combined sharp and blunt dissection of the Callot was attempted, and it was successful with safe clipping of cystic artery and duct after achieving critical view of safety (CVS) with no complications. A large-sized GB with mucocele was found in one (5%) case among group B patients making it difficult to handle; so, GB was emptied at first by percutaneous aspiration of its contents using a 20 Fr needle, then it was easy to handle GB and continue the procedure.

Conversion of SILC to CLC or introduction of additional ports was done in two (10%) cases in our study as discussed before, which is not different from other studies like Hajong *et al.* [2], Lee *et al.* [9], and Subirana *et al.* [18], which was 6.25, 9.7, and 8%, respectively.

According to Lee *et al.* [9], multiple intraoperative complications occurred like bile leak in 73 (8.9%) cases, bleeding in two (0.2%) cases, and CBD injury in two (0.2%) cases, which required open conversion for four (0.5%) cases. The overall incidence of postoperative complications was 38 (4.7%) patients. They classified complications to major and minor ones. Major complications occurred in eight (1.0%) cases including retained CBD stones in three (0.4%) cases, cystic duct leakage in two (0.2%) cases, and CBD injury in three (0.4%) cases. Minor complications were observed in 30 (3.67%) cases; 22 (2.7%) cases for wound infection (requiring antibiotics or not), six (0.7%) cases for port-site herniation, one (0.1%) case for pain, and one (0.1%) case for wound eversion.

Our results are different from Lee *et al.* [9] as no major intraoperative or postoperative complications like biliary or major vascular injuries that require reintervention or readmission were recorded. However, we agreed with them regarding the incidence of minor intraoperative complications despite lack of significant difference between SILC and CLC groups ($P>0.05$). Bleeding occurred in five (12.5%) cases; three (15%) were in group A and two (10%) were in group B, only one in group A was significant and managed after conversion to CLC as discussed before. The other four cases were of minor degree and it was successfully managed by gauze compression. GB perforation with bile spillage has occurred in five (12.5%) cases; three (15%) in group A and two (10%) in group B and suction irrigation was done.

Results of meta-analysis by Geng *et al.* [1] stated that pain scores in first 8 h postoperatively were significantly lower after SILC, while there were no significant differences in pain score at 12h and 24h. This is

relatively different from our results as there were no significant differences in postoperative pain between both groups at all times of follow-up ($P>0.05$).

Regarding hospital stay, our results showed that the difference between both groups was insignificant ($P=0.716$) with a mean of 1.2 ± 0.5 in the SILC group and 1.15 ± 0.3 in the CLC group, which matched findings of a study by Omar *et al.* [19] in which the mean was 1.3 ± 1.2 and 1.2 ± 0.9 in the SILC and the CLC group, respectively ($P=0.78$).

In our study, the difference between both groups regarding the incidence of postoperative wound complications was insignificant with an overall incidence of nine (22.5%) patients. This high percentage is due to the small sample size (40 patients only) with overlap and presence of more than one wound complication in a patient. Ecchymosis was found in two (10%) patients in group A and one (5%) patient in group B, while seroma occurred in two (10%) patients of group A and one (5%) patient in group B, which was aspirated ultrasound guided, then culture and sensitivity was done for aspirated fluid which was sterile. Wound infection occurred in three (7.5%) patients; one (5%) in group A and two (10%) in group B and they were managed conservatively and showed improvement within 1 week. This agreed with the results of meta-analysis by Arezzo *et al.* [20], which reported no significant difference between SILC and CLC groups, regarding the incidence of wound complications. During the 6 months period of follow-up, we have observed no incidence of incisional hernia in both groups. This may be attributed to the fact that we close the fascial layer in the umbilical port in both study groups with Prolene 0 sutures. However, this short time of follow-up may be underestimating the incidence of incisional hernia, which may occur years postoperatively. On the other hand, data from the meta-analysis by Lyu *et al.* [21] showed that SILC may be associated with higher incisional hernia rates compared with CLC as it was reported in 35 studies and occurred in 29 out of 2208 patients in the SILC group and in seven out of 2304 patients in the CLC group ($P=0.01$). Also, the systemic review by Haueterl *et al.* [22] showed that port-site hernia was reported in 10 trials including 927 patients (472 SILC, 455 CLC). The incidence of hernia was 19 (4.0%) of 472 in the SILC group compared with five (1.1%) of 455 in the CLC group. The mean follow-up ranged from 4 to 69 weeks.

Our results coincided with the literature concerning postoperative cosmetic satisfaction about the scar(s) assessed after 1 week and 1 month postoperatively,

which was better in favor to the SILC group ($P < 0.001$). Evers *et al.* [14] reported that cosmesis was significantly better in the SILC group at all time points. Also, Omar *et al.* [19] supported our findings as there was a significant difference in the aesthetic score between the two groups (7.9 ± 1.6 in SILC vs. 6.7 ± 1.4 in CLC; $P < 0.008$).

Conclusion

Our study revealed that SILC is a safe, feasible but challenging procedure that needs experienced hands in handling the instruments in lack of triangulation. SILC has shown better results than CLC regarding cosmesis but not in postoperative pain or recovery. Also, there were no significant differences between CLC and SILC regarding intraoperative and postoperative complications. The main drawbacks about SILC were higher cost and longer operative time, which was significantly improved with gaining more experience. So, we recommend SILC for selected patients by experienced surgeons although we cannot recommend it as a standard alternative for CLC based on our results. A large prospective double-blinded, randomized, controlled trial comparing SILC and CLC is needed to identify the best procedure.

Acknowledgements

All authors had equal role in the design, work, statistical analysis, and manuscript writing.

Financial support and sponsorship

Nil.

Conflicts of interest

There are no conflicts of interest.

References

- Geng L, Sun C, Bai J. Single incision versus conventional laparoscopic cholecystectomy outcomes: a meta-analysis of randomized controlled trials. *PLoS ONE* 2013; 8:e76530.
- Hajong R, Hajong D, Natung T, Anand M, Sharma G. A comparative study of single incision versus conventional four ports laparoscopic cholecystectomy. *J Clin Diagn Res* 2016; 10:06–09. doi: <https://doi.org/10.7860/JCDR/2016/19982.8601>
- He GL, Jiang ZS, Cheng Y, Lai Q, Zhou C, Liu H. Tripartite comparison of single-incision and conventional laparoscopy in cholecystectomy: a multicenter trial. *World J Gastrointest Endosc* 2015; 7:540–546.
- Navarra G, Pozza E, Occhionorelli S, Carcoforo P, Donini I. One wound laparoscopic cholecystectomy. *Br J Surg* 1997; 84:695.
- Joseph S, Moore BT, Sorensen GB, *et al.* Single-incision laparoscopic cholecystectomy: a comparison with the gold standard. *Surg Endosc* 2011; 25:3008–3015.
- Hirano Y, Watanabe T, Uchida T, Yoshida S, Tawaraya K, Kato H, Hosokawa O. Single-incision laparoscopic cholecystectomy: single institution experience and literature review. *World J Gastroenterol* 2010; 16:270–274. doi: 10.3748/wjg.v16.i2.270.
- Stavros AA, Salvador MC, George AA. Single-incision laparoscopic cholecystectomy with curved versus linear instruments assessed by systematic review and network meta-analysis of randomized trials. *Surg Endosc* 2015; 30:819–831.
- Chamberlain RS, Sakpal SV. A comprehensive review of single-incision laparoscopic surgery (SILS) and natural orifice transluminal endoscopic surgery (NOTES) techniques for cholecystectomy. *J Gastrointest Surg* 2009; 13:1733–1740.
- Lee Y, Roh Y, Kim M, Kim Y, Kim K, Kang S, Jang E. Analysis of post-operative complication in single-port laparoscopic cholecystectomy: A retrospective analysis in 817 cases from a surgeon. *J Min Access Surg* 2018; 14:311–315. doi: 10.4103/jmas.JMAS_168_17.
- Tsai AY, Selzer DJ. Single-port laparoscopic surgery. *Adv Surg* 2010; 44:1–27.
- Hoyuela C, Juvany M, Carvajal F. Single-incision laparoscopy versus standard laparoscopy for colorectal surgery: a systematic review and meta-analysis. *Am J Surg* 2017; 214:127–140.
- Marks JM, Phillips MS, Tacchino R, Roberts K, Onders R, DeNoto G, *et al.* Single-incision laparoscopic cholecystectomy is associated with improved cosmesis scoring at the cost of significantly higher hernia rates: 1-year results of a prospective randomized, multicenter, single-blinded trial of traditional multiport laparoscopic. *J Am Coll Surg* 2013; 216:1037–1047. doi: 10.1016/j.jamcollsurg.2013.02.024.
- Poon JTC, Cheung CW, Fan JKM, Lo OS, Law WL. Single-incision versus conventional laparoscopic colectomy for colonic neoplasm: a randomized, controlled trial. *Surg Endosc* 2012; 26:2729–2734. doi: 10.1007/s00464-012-2262-z.
- Evers L, Bouvy N, Branje D, Peeters A. Single-incision laparoscopic cholecystectomy versus conventional four-port laparoscopic cholecystectomy: a systematic review and meta-analysis. *Surg Endosc* 2017; 31:3437–3448.
- Pietrabissa A, Sbrana F, Morelli L, *et al.* Overcoming the challenges of single-incision cholecystectomy with robotic single-site technology. *Arch Surg* 2012; 147:709–714. doi:10.1001/archsurg.2012.508
- Romanelli JR, Roshek TB3rd, Lynn DC, Earle DB. Single-Port laparoscopic cholecystectomy: initial experience. *Surg Endosc* 2010; 24: 1374–1379. doi: 10.1007/s00464-009-0781-z. Epub 2009 Dec 29. PMID: 20039073
- Podolsky ER, Rottman SJ, Poblete H, King SA, Curcillo PG. Single port access (SPA) cholecystectomy: a completely transumbilical approach. *J Laparoendosc Adv Surg Tech A* 2009; 19:219–222. doi: 10.1089/lap.2008.0275. PMID: 19260790
- Subirana H, Rey FJ, Barri J, Robres J, Parra L, Martín M, *et al.* Single-incision versus four-port laparoscopic cholecystectomy in an ambulatory surgery setting: a prospective randomised double-blind controlled trial. *J Minim Access Surg* 2021; 17:311–317.
- Omar MA, Redwan AA, Mahmoud AG. Single-incision versus 3-port laparoscopic cholecystectomy in symptomatic gallstones: a prospective randomized study. *Surgery* 2017; 162:96–103.
- Arezzo A, Passera R, Forcignanò E, Rapetti L, Ciocchi R, Morino M, *et al.* Single-incision laparoscopic cholecystectomy is responsible for increased adverse events: results of a meta-analysis of randomized controlled trials. *Surg Endosc* 2018; 32:3739–3753.
- Lyu Y, Cheng Y, Wang B, Zhao S, Chen L. Single-incision versus conventional multiport laparoscopic cholecystectomy: a current meta-analysis of randomized controlled trials. *Surg Endosc* 2020; 34:4315–4329.
- Haueterl R, Schütz T, Raptis DA, Clavien PA, Zuber M. Meta-analysis of single-port versus conventional laparoscopic cholecystectomy comparing body image and cosmesis. *Br J Surg* 2017; 104:1141–1159.