

# Hollow viscus injuries after blunt abdominal trauma in children and adults in a comparative study

Mohammad A. Elian, Amr Abdel Hameed Elhiny, Asaad Abd El Rahman Abd El Aziz

Department of General Surgery, Faculty of Medicine, Minia University, Minia, Egypt

Correspondence to Amr A.H. Elhiny, MD, Department of General Surgery, Faculty of Medicine, Minia University, Minia 61741, Egypt  
Tel: +20 127 734 0340;  
e-mail: amr\_elhiny@yahoo.com

**Received:** 26 January 2022

**Revised:** 14 February 2022

**Accepted:** 01 March 2022

**Published:** 14 January 2023

**The Egyptian Journal of Surgery** 2023, 41:542–547

## Purpose

The study aimed to compare between children and adults in the cause, the pattern of injury, who is more liable for hollow viscus injuries, and clinical presentation of patients with blunt hollow viscus.

## Patients and methods

This prospective study was conducted from October 2020 to September 2021 at the Surgery Department in Minia University Hospital on patients of blunt abdominal trauma with hollow viscus injury.

## Results

In all, 53 patients had hollow viscus injuries. The most common site of injury is the jejunum as there were 30 (56.6%) patients had jejunal injuries isolated or associated with other injuries. Surgical management was conducted on all patients. The most common technique used in perforated cases was primary repair and this was performed in 35 (66%) patients with gastric perforation and small jejunal injuries, resection, and anastomoses in 13 (24.5%) patients with large jejunal perforation, and Hartmann's procedure in five (9.4%) patients with sigmoid and rectal injuries. The rate of complications was in 15 (28.30%) patients in the form of surgical site infection, wound dehiscence, anastomosis leakage, paralytic ileus, chest infection, and retraction of stoma. The mortality rate was 11.3% (six patients). It was detected that the most cause of death is septic shock with multiorgan failure.

## Conclusion

Patients with hollow viscus injury are often a cause of diagnostic uncertainty, due to potential missed injuries on initial imaging, delayed perforation due to ischemic injury, and presence of distracting injuries. The high incidence of hollow viscus injury in the younger age was due to road traffic accidents but the incidence of stomach injury was high in children due to cycle bar injury. Intestinal perforation was the most common site injury in blunt abdominal trauma. Early diagnosis and patient monitoring help early intervention and reduce the incidence of morbidity and mortality.

## Keywords:

adults, blunt trauma, children, hollow viscus

Egyptian J Surgery 2023, 41:542–547  
© 2023 The Egyptian Journal of Surgery  
1110-1121

## Introduction

Blunt abdominal trauma such as isolated trauma or following assaults, motor vehicle accidents, and falls commonly results in solid organ (liver, spleen, and kidney), hollow viscera injuries, and diaphragmatic, pancreatic, and retroperitoneal injuries [1]. Blunt hollow viscus injury occurs in less than 1% of total trauma admissions [2]. Hollow viscera injuries to the stomach, duodenum, jejunum, urinary bladder, colon, and the rectum are not common with an incidence that varies between 4 and 15% of blunt abdominal trauma [3].

Studies suggested that cases with isolated free fluid without solid organ injury in computed tomography (CT) after blunt abdominal trauma have high possibility of hollow viscus injuries [4,5]. The

combination of clinical, laboratory, and radiologic findings is the golden key to make early diagnosis of surgical hollow viscus injury in blunt abdominal trauma patients with isolated free fluid without solid organ injury [5].

Nonoperative management is more common with solid organ injuries after blunt abdominal trauma. Unlike hollow viscus injury as early surgical intervention is important late diagnosis increases the incidence of morbidity and mortality especially in children because of peritonitis and sepsis [2].

This is an open access journal, and articles are distributed under the terms of the Creative Commons Attribution-NonCommercial-ShareAlike 4.0 License, which allows others to remix, tweak, and build upon the work non-commercially, as long as appropriate credit is given and the new creations are licensed under the identical terms.

Patients with hollow viscus injury are often a cause of diagnostic uncertainty, due to potential missed injuries on initial imaging, delayed perforation due to ischemic injury, and presence of distracting injuries. High suspicion, serial examination, and repeat imaging are often employed to reduce the rate of septic complications and minimize the negative laparotomy rate [6].

Three time periods for intervention were identified. Immediate intervention was defined as laparotomy before cross-sectional imaging of the abdomen or the pelvis was obtained. Early intervention was defined as a laparotomy after cross-sectional imaging but before 12 h from the first admission to the emergency department. Delayed intervention was defined as laparotomy after 12 h from the first admission to the emergency department [6].

This study aimed to compare between children and adults in the cause, the pattern of injury, who is more liable for hollow viscus injuries, and clinical presentation of patients with blunt hollow viscus.

## Patients and methods

This prospective study was conducted at the Surgery Department in Minia University Hospital on patients of blunt abdominal trauma with hollow viscus injury from October 2020 to September 2021. Blunt abdominal trauma patients with proven hollow viscus injury diagnosed clinically/radiologically were included in this study. Patients with blunt abdominal trauma without hollow viscus injury and patients with penetrating abdominal trauma were excluded from this study. Informed consent was taken from all patients or their relatives. This study was conducted after obtaining the Institutional Ethics Committee's approval. Descriptive statistics were used to analyze the data collected in this observational study. Patients were analyzed for age, sex, cause of injury, presentation, site of injury, type of performed surgical intervention, complications, need for ventilator support, length of hospital stay, and incidence of mortality and morbidity. We classified our patients into two groups, child group under the age of 18 years and adult group from the age of 18 years.

## Results

Out of a total of 6973 trauma admissions, 493 blunt abdominal injuries were identified. Of these, hollow viscus injury was found only in 53 patients. During hospital stay, hollow viscus injury in blunt abdominal trauma was found to be with higher incidence in the

**Table 1** Distribution of patients according to the mechanism of injury

Etiology	Number of child (%)	Number of adult (%)
Road traffic accidents	3 (5.6)	22 (41.5)
Fall from height	9 (16.9)	6 (11.3)
Cycle bar injury	8 (15)	0
Animal injury	1 (1.8)	4 (7.5)

younger age group. Of the patients, 32 (60.3%) were in the age group of above 18 years, followed by child age under 18 years which were 21 (39.6%) patients. In this study, hollow viscus injury was found more commonly in males because of road traffic accidents that were found to be the most common cause of injury followed by fall from height. A total of 25 (47%) patients had sustained trauma due to roadside accidents, 15 (28.3%) patients due to fall from height, and the remaining patients had sustained blunt trauma from other causes such as animal injury and cycle bar injury (Table 1).

All patients underwent trauma survey in the form of plain radiographs of the chest and abdomen in erect position, FAST and laboratory evaluation. Ten (18.8%) patients with unstable hemodynamics, manifestation of peritonitis, and free collection on FAST were subjected for surgery without undergoing a CT scan. Also, 43 (81.1%) patients with stable hemodynamic status were taken up for surgery based on their clinical, laboratory data, pneumoperitoneum in radiograph, and abdominal contrast-enhanced CT finding to confirm the diagnosis.

In this study, 53 patients had hollow viscus injuries. The most common site of injury is the jejunum as there were 30 (56.6%) patients who had jejunal injuries isolated or associated with other injuries. Most of the children who had small intestinal perforation were less than 18 years which was due to fall from height but patients between the age of 20 and 35 years it was due to motor car or motor vehicle accident. Three (5.6%) patients had double pathology as double perforations in the jejunum or mesenteric tear causing ischemic injury in another part of the small intestine or colon. Four (7.5%) patients had associated solid organ injuries as splenic tear, mesenteric vessel injury, and perinephric hematoma. Seven patients in between the age of 5 and 12 years presented with perforated stomach, one of them have also injury in the transverse colon and three of them were associated with retroperitoneal hematoma. Five of the patients with perforated stomach were due to cycle bar injury but the other two patients were due to motor car accident. The less common injuries seen were sigmoid injuries in four patients after motor car

**Table 2 Distribution of site of injury**

Site of injury	Number of child (%)	Number of adult (%)
Jejunum	12 (22.6)	18 (33.9)
Ileum	2 (3.7)	8 (15)
Stomach	7 (13.2)	0
Sigmoid	0	4 (7.54)
Transverse colon	1 (1.8)	1 (1.8)
Rectum	0	1 (1.8)

**Table 3 Associated injuries**

Associated injuries	Number of children (%)	Number of adults (%)
Splenic injury	0	1 (1.8)
Liver injury	0	2 (3.7)
Vascular injury	1 (1.8)	0
Retroperitoneal hematoma	3 (5.6)	0
Perinephric hematoma	1 (1.8)	0

**Table 4 Surgical management**

Surgical management	Number of child (%)	Number of adult (%)
Primary repair	16 (30.1)	19 (35.8)
Resection anastomosis	5 (9.4)	8 (15)
Hartmann's procedure	0	5 (9.4)

accident, followed by rectal and colonic injuries after animal injury (Tables 2 and 3).

Regarding treatment, surgical management was conducted to all patients. The most common used technique was primary repair of the perforation, this was conducted in 35 (66%) patients with gastric perforation and small jejunal injuries, resection and anastomoses was done in 13 (24.5%) patients with large jejunal perforation more than 50% of circumference of bowel and with mesenteric tears associated with ischemic bowel, and Hartmann's procedure was done in five (9.4%) patients with sigmoid and rectal injuries (Table 4).

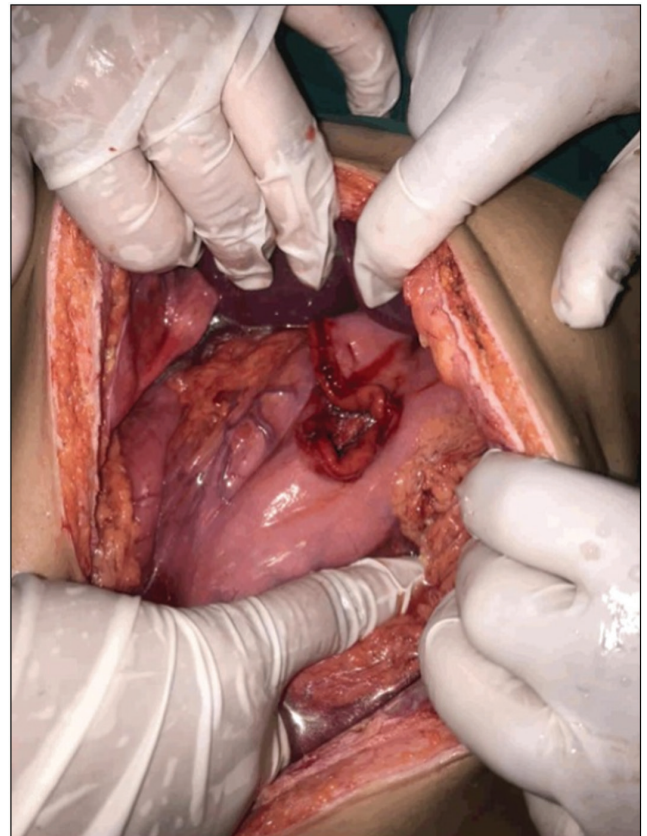
According to the time of presentation and intervention, 10 (18.8%) patients had immediate surgical intervention as they were hemodynamically unstable, two of them were adults and eight patients were in the child age. Forty (75.4%) patients had early surgical intervention after sure diagnosis of hollow viscus injury by abdominal CT and three (5.6%) patients had delayed intervention.

Inotropic support was required in 16 (30.1%) patients. Ventilator support was required in nine (16.9%) patients. Fresh blood and fresh frozen plasma was given to 90% of patients.

The rate of complications was 15 (28.30%) patients in the form of surgical site infection, wound dehiscence,

**Table 5 Postoperative complications**

Type of complication	Number of patients (%)
Paralytic ileus	5 (9.4)
Chest infection	4 (7.5)
Surgical site infection	4 (7.5)
Wound dehiscence	3 (5.6)
Anastomosis leakage	1 (1.8)
Retraction of stoma	1 (1.8)

**Figure 1**

Gastric perforation.

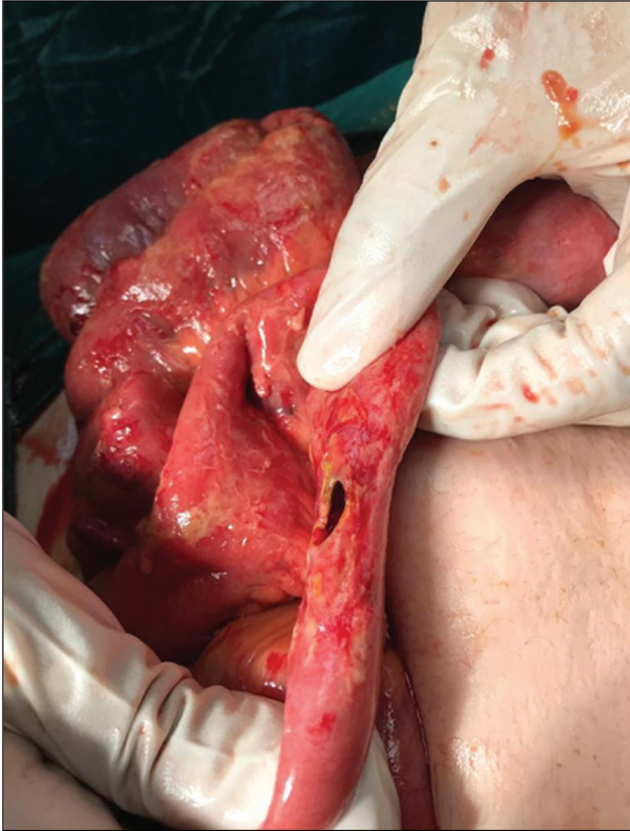
anastomosis leakage, paralytic ileus, chest infection, and retraction of stoma. Three patients had two types of complications as chest infection and wound dehiscence.

The mortality rate in the current study was 11.3% (six patients). It was found that the most common cause of death in this study was attributed to septic shock with multiorgan failure. Four were due to septic shock with multiorgan failure due to delayed surgical intervention. Two patients had associated head injuries with increasing risk of mortality (Table 5, Figs 1 and 2).

## Discussion

Hollow viscus injury can be caused by three patterns of injuries as direct injuries leading to perforation or ischemic perforation or as a result of mural injury [7].

Figure 2



Jejunal perforation.

According to the clinical manifestation of peritonism, patient's hemodynamics, radiological findings and laboratory findings, diagnosis of bowel injury was done. Patients with blunt trauma were diagnosed radiologically by radiograph of the chest, radiograph of the abdomen in erect position, ultrasound of the abdomen, and CT of the abdomen. Ultrasonography is considered an easily applied, nonexpensive and noninvasive investigation. Hollow viscus injury is suggested by the presence of free collection without solid organ injury. CT of the abdomen is almost the most sensitive and specific diagnostic method to document abdominal injury; however, 18% of patients with hollow viscus injuries were hemodynamically unstable to wait for CT abdomen and 75.4% of patients were with confirmed clinical diagnosis of pneumoperitoneum in radiograph of the abdomen, clinical signs of peritonism, and findings of CT abdomen [2].

A vascular injury leading to bowel ischemia or an enlarging mesenteric hematoma may take several hours to become clinically apparent, but a delay in diagnosis of even 5–8 h can significantly increase morbidity and mortality due to hemorrhage or peritonitis with resultant sepsis [8].

The most common cause of hollow viscus injury was road traffic accidents (41.5%). Compression and deceleration forces are responsible for hollow viscus injury and so road traffic accident is the most common cause of hollow viscus injury. Compression force increases the intraluminal pressure resulting in rupture but deceleration forces causing stretching and tearing of the mesentery [9]. Fall from height was the commonest cause in children (16.9%). This results are similar to other studies as fall from height was the commonest cause in children in the Chukwubuike [10] study, which may be due to increased violence between children or climbing trees to pluck fruits.

In this study, we managed 53 patients of blunt abdominal trauma with hollow viscus injury from October 2020 to September 2021. In all, 493 patients sustained blunt abdominal trauma and only 53 (10.75%) of these blunt abdominal trauma patients were diagnosed with hollow viscus injury. This incidence is similar to the incidence found in other studies as in the Wadhwa and colleagues study.

Patients' age varied from 5 to 55 years. The younger age group of 18–40 years was the highest incidence found among patients (52.8% of the total patients). This incidence was nearly similar to the incidence in the Wadhwa *et al.* [2] study but there was no difference between the various age groups in the Demetriades *et al.* [11] study. The children are more susceptible to solid organ injuries because of poor protection by the underdeveloped thoracic cage and the weakness of abdominal wall muscles [11].

Patients with hollow viscus injury are often a cause of diagnostic uncertainty, due to potential missed injuries on initial imaging, delayed perforation due to ischemic injury, and presence of distracting injuries.

There was no difference in clinical presentation between adults and children. Abdominal pain and tenderness were the most common symptom and sign in hollow viscus injury followed by vomiting, constipation, abdominal distension, and bruising on the abdominal wall.

Clinical state of shock was found in patients with delayed presentation. This was evidenced by tachycardia, hypotension, narrow pulse pressure, and signs of peritonitis, which was characterized by rebound tenderness, fever, guarding, and rigidity.

In our study, jejunum was the most common site to get injured, which was the same as reported by other

studies. The jejunum was the most common site of injury as in the Wadhwa *et al.* [2] study which as 24%. In our study, jejunal injury was more common in adults (33.9%) than children (22.6%). The jejunum is the most commonly injured segments of the bowel, with those portions that are anatomically fixed, as the jejunum near the ligament of Treitz, that is, close to fixed points. Large bowel injuries generally occur in penetrating trauma, whereas in blunt trauma, it is a less common finding. Ileal injury was also more common in adults (15%) than children (3.7%) unlike many studies as those of Chukwubuike [10]. In the current study, the incidence of small bowel injuries was found to be more higher and frequent than those in the large bowel. And it was coincident with other studies which reported that small bowel injures were more frequent than colonic injuries [8,12]. Sule *et al.* [12] also found colonic injuries to be less frequent than small bowel injury in their study. This is mainly due to its location and the lack of redundancy, which prevents the formation of closed loops.

Also, there were patients with gastric perforation mainly in the age of 8–12 years. According to the history of patients, gastric perforation almost follow blunt abdominal trauma with cycle bar. All patients had a history of eating before injury, which means that dilated stomach is more liable for perforation with abdominal trauma. In our study, all patients with gastric perforation was not associated with other organ injuries unlike other studies like those of Wadhwa *et al.* [2], which studied gastric perforation associated with splenic injury or pancreatic injury.

Classically, it was noticed that blunt abdominal trauma causing gastric perforations have been occurred by three mechanisms: external compression resulting in sudden and severe rise of intra-abdominal pressure. This mechanism applies in particular to a distended stomach with a consequent massive increase of intragastric pressure. This mechanism may explain the development of gastric perforation following the Heimlich maneuver. Dr Heimlich described this technique as placing the fist of the rescuer in between the costal margin and the umbilicus with the thumb in contact with the abdomen. This is repeated until dislodgment of the foreign body from the airway. Shearing forces among the adjacent structures were developed due to rapid deceleration causing hollow, solid, visceral organs, and vascular pedicles to tear, especially at relatively fixed points of attachment. Intra-abdominal contents are crushed between the anterior abdominal wall and the vertebral column or posterior thoracic cage. Gastric perforations develop in any location of the stomach. The most common

location for gastric perforation is the anterior wall [1,13].

As regards treatment, surgical intervention was conducted on all patients. The most commonly used intervention was primary repair of the perforation. However, in multiple proximal perforations or nonviable bowel, resection and anastomosis was performed, as found in some patients with mesenteric injuries. Hartmann's procedure was preferred for sigmoid colon injuries, and rectal injuries were repaired primarily with diversion. Hartmann's procedure was performed in four patients of sigmoid injury. Patients with rectal injury were repaired primarily with proximal diversion. These results were in agreement with Jha *et al.* [14] who performed simple closure of the perforation (66.5%), resection and anastomosis (11.0%), and stoma (22.5%).

The most common complication was paralytic ileus in five (9.4%) patients mainly in children; also, pneumonia is the most common complication with Harmston *et al.* [7] and surgical site infection with Chukwubuike [10]. Surgical site infection represented in 7.5% of patients. This could be due to contamination of the peritoneal cavity by bowel contents, which further led to surgical site sepsis. Surgical site infections were managed with aseptic dressings and intravenous antibiotics as per culture, and sensitivity tests were introduced to manage surgical site infection. One of the most fearful complications was wound dehiscence, which led to an increased hospital stay. In our study, three (5.6%) patients had wound dehiscence. Repeated daily dressings and secondary suturing were applied to close wound dehiscence.

The mortality rate was 11.3% (six patients). It was detected that the most cause of death is septic shock with multiorgan failure. This result was in line with Burch [15] who observed that mortality rates quoted from blunt intestinal trauma range from 10 to 30%. Reports have shown that mortality increases with the number of associated injuries [16].

---

## Conclusion

Patients with hollow viscus injury are often a cause of diagnostic uncertainty, due to potential missed injuries on initial imaging, delayed perforation due to ischemic injury, and presence of distracting injuries. High suspicion, serial examinations, and repeat imaging are often used to reduce the rate of septic complications and minimize negative laparotomy rate. There was high incidence of hollow viscus injury in the younger age due to road traffic accidents but the incidence of

stomach injury was high in children due to cycle bar injury. Intestinal perforation was the most common site injury in blunt abdominal trauma. Early diagnosis and patient monitoring help early intervention and reduce the incidence of morbidity and mortality.

#### Acknowledgements

The authors offer their sincere thanks to all people who participated in the study.

Author contributions: All authors contributed to the study conception and design. Material preparation and data collection were performed by Dr Asaad and Dr Mohammed. The analysis and first draft of the manuscript was written by Dr Amr and all authors commented on previous versions of the manuscript. All authors read and approved the final manuscript.

#### Financial support and sponsorship

Nil.

#### Conflicts of interest

There are no conflicts of interest.

#### References

- 1 Aboobakar MR, Singh JP, Maharaj K, Mewa Kinoo S, Singh B. Gastric perforation following blunt abdominal trauma. *Trauma Case Rep* 2017; 10:12–15.
- 2 Wadhwa M, Kumar R, Trehan M, Singla S, Sharma R, Ahmed A, Sharma R. Blunt abdominal trauma with hollow viscus and mesenteric injury: a prospective study of 50 cases. *Cureus* 2021; 13:2.
- 3 Isenhour JL, Marx J. Advances in abdominal trauma. *Emerg Med Clin North Am* 2007; 25:713–733.
- 4 Ng AK, Simons RK, Torreggiani WC, Ho SF, Kirkpatrick AW, Brown RG. Intra-abdominal free fluid without solid organ injury in blunt abdominal trauma: an indication for laparotomy. *J Trauma Acute Care Surg* 2002; 52:1134–1140.
- 5 Jung PY, Park EJ, Shim H, Jang JY, Bae KS, Kim S. Findings requiring immediate surgery in blunt abdominal trauma patients with isolated free fluid without solid organ injury on abdominal computed tomography: Retrospective laboratory, clinical and radiologic analysis. A case control study. *Int J Surg* 2020; 77: 146–153.
- 6 Kommunuri JS, Loto-Aso E, Harmston C. Incidence, outcomes and effect of delayed intervention in patients with hollow viscus injury due to major trauma in the Northern region of New Zealand. *ANZ J Surg* 2021; 91: 1148–1153.
- 7 Harmston C, Ward JBM, Patel A. Clinical outcomes and effect of delayed intervention in patients with hollow viscus injury due to blunt abdominal trauma: a systematic review. *Eur J Trauma Emerg Surg* 2018; 44:369–376.
- 8 Pham J, Kemp J, Pruitt J. Acute abdomen in adult trauma. *Sem Roentgenol.* 2020; 55:331–436.
- 9 Kulvatunyou N, Albrecht RM, Bender JS, Friese RS, Joseph B, Latifi R, *et al.* Seatbelt triad: severe abdominal wall disruption, hollow viscus injury, and major vascular injury. *Am Surg* 2011; 77:534–538.
- 10 Chukwubuike KE. Hollow viscus injury from blunt abdominal trauma in children: experience in a developing country. *Clin Res Clin Case Rep* 2021; 2:3.
- 11 Demetriades D, Murray J, Brown C, Velmahos G, Salim A, Alo K, Rhee P. High-level falls: type and severity of injuries and survival outcome according to age. *J Trauma Acute Care Surg* 2005; 58:342–345.
- 12 Sule AZ, Kidmas AT, Awani K, Uba F, Misauno M. Gastrointestinal perforation following blunt abdominal trauma. *East Afr Med J* 2007; 84:429–440.
- 13 Lee SL, *et al.* Complications as a result of the Heimlich maneuver. *J Trauma Acute Care Surg* 2009; 66:E34–E35.
- 14 Jha NK, Yadav SK, Sharma R, Sinha DK, Kumar S, Kerketta MD, *et al.* Characteristics of hollow viscus injury following blunt abdominal trauma; a single centre experience from eastern India. *Bull Emerg Trauma* 2014; 2:156–160.
- 15 Burch JM. Injury to the colon and rectum. In: Moore EE, Feliciano DV, Mattox KL, editors. *Trauma*. 5th ed. New York: McGraw Hill; 2004 pp. 763–782.
- 16 Watts DD, Fakhry SM, EAST Multi-Institutional Hollow Viscus Injury Research Group. Incidence of hollow viscus injury in blunt trauma: an analysis from 275,557 trauma admissions from the East multi-institutional trial. *J Trauma* 2003; 54:289–294.