

# Splenic vessel control during laparoscopic splenectomy, ligasure, endoclips, or endo-GIA stapler: a comparative study

Mohamed F. Amin, Mohamed I. Abdelhamid, Hazem Nour, Abdelwahab S. Almoregy

Department of General Surgery, Zagazig University, Zagazig, Egypt

Correspondence to Hazem Nour, MBBCH, MSC, MRCS, MD, Department of General Surgery, Zagazig University, Zagazig 44519, Egypt. Mob: +20552307830; e-mail: hzm\_nr@yahoo.com

**Received:** 18 September 2021

**Revised:** 27 September 2021

**Accepted:** 27 September 2021

**Published:** 10 October 2022

**The Egyptian Journal of Surgery** 2022, 41:60–64

## Background

Laparoscopic splenectomy became the gold standard operation for many splenic disorders, successful completion of the operation depends to a large extent on splenic size and control of bleeding, which mostly occurs due to capsular tears during dissection or mal control of the splenic vessels. Splenic vessels could be controlled by ligasure, endoclips, or endo-GIA staplers.

## Patients and methods

In all, 48 patients undergoing laparoscopic splenectomy were allocated into three groups according to the way we controlled the splenic vessels, each group had 16 patients. In group I, the ligasure was used for sealing splenic vessels; in group II endoclips were used for vessel control, and in group III endo-GIA stapler was used for control and transection of the splenic pedicle.

## Results

All cases were completed by a laparoscope except one patient in group II who was converted due to uncontrolled bleeding; blood loss and postoperative drainage were significantly higher in the second group. Ligasure use made dissection easy and safe. Ligasure and endo-GIA staplers helped in reducing the operative time.

## Conclusion

Ligasure and endo-GIA staplers are superior to endoclip application for the control of splenic vessels during laparoscopic splenectomy. Their combination helps in reducing the operative time.

## Keywords:

endoclips, endo-GIA stapler, laparoscopic splenectomy, ligasure

Egyptian J Surgery 2022, 41:60–64  
© 2022 The Egyptian Journal of Surgery  
1110-1121

## Introduction

Laparoscopic splenectomy was described for the first time in 1993 [1–3]. Since that time it became progressively favored. Now it is the standard procedure for splenectomy in pediatric patients, hematologic diseases, and selected trauma cases [4].

Nowadays laparoscopic splenectomy is a feasible and safe procedure, with less intraoperative blood loss, less postoperative pain, and shorter hospital stay [4,5]. Rate of conversion of laparoscopic splenectomy ranges between 2 and 10% [4,6]; the main causes of conversion are splenomegaly and intraoperative bleeding. In laparoscopic splenectomy, bleeding is mostly caused by capsular injury and hilar vessel injury during dissection [4,7,8]. Intraoperative bleeding could be less in many ways in hand-assisted laparoscopic splenectomy due to meticulous dissection at the vicinity of the tail of the pancreas, preoperative splenic artery embolization, use of endoclips, and energy-based hemostatic devices such as ligasure and ultrasonic shears [6,9,10].

Control of the splenic vessels at the hilum is the milestone in the completion of the procedure. This can be achieved by the use of endo-GIA staplers, endoclips, ligasure, or an ultrasonic shear device (harmonic scalpel) [11]. Endo-GIA staplers are better used with larger diameters of splenic vessels [7]. Ligasure uses an energy-based method that exerts a precise amount of pressure and bipolar energy to the tissues leading to sealing of vessels by changing the nature of the vessel wall [4,12]. The limitation of ligasure is that it can be used only if the diameter of vessels is more than 7 mm [4]. Endoclips and endo-GIA staplers can control vessels of more than 7 mm diameter but it needs good dissection of the splenic hilum, which carries the hazards of bleeding [7]. Harmonic scalpel is a very good device for tissue dissection, but its use is limited to vessels with a maximum diameter of 5 mm [13].

This is an open access journal, and articles are distributed under the terms of the Creative Commons Attribution-NonCommercial-ShareAlike 4.0 License, which allows others to remix, tweak, and build upon the work non-commercially, as long as appropriate credit is given and the new creations are licensed under the identical terms.

## Patients and methods

### Study design

This study is a comparative clinical trial carried out in the General Surgery Department, Zagazig University, Egypt, in the period between May 2017 and February 2020, on 48 patients undergoing laparoscopic splenectomy for different indications.

Randomization: patients were randomly allocated, using computer-generated cards, into three groups according to the way we controlled splenic vessels, each group had 16 patients. In group I splenic vessels were controlled using ligasure; in group II splenic vessels were controlled using laparoscopic endoclips; and in group III splenic vessels were controlled using endo-GIA staplers.

### Patient eligibility

Patients included in this study were those who are undergoing laparoscopic splenectomy for idiopathic thrombocytopenic purpura, thrombotic thrombocytopenic purpura, spherocytosis, thalassemia, splenic cysts, and splenic lymphoma.

Patients excluded were those with contraindications to laparoscopic surgery, patients with coagulopathy, patients with portal hypertension, and patients with a huge spleen.

All patients received a triple vaccine (pneumococcal, meningococcal, and *Haemophilus influenza*) 2 weeks before the surgery and the third-generation cephalosporin injection and fractionated heparin as prophylaxis against thrombotic complications of splenectomy on the induction of anesthesia.

The study was approved by the research ethics committee and the Institutional Research Board (IRB) of our university.

All study participants signed an informed written consent. The study has no external funding and we have no conflict of interest.

### Surgical technique

All the study patients were operated on by the same surgical team with the same approach and technique.

Patients were placed in the right lateral semi-decubitus position with the table tilted in a slight anti-Trendlenburg's position and flexed 30° to open the space between the left iliac crest and the left costal margin. Surgeon stands to the front of the patient,

main monitor and assistant behind the patient, and scrub nurse next to the surgeon.

Pneumoperitoneum was created using a Veress needle through the optic port; CO<sub>2</sub> pressure was maintained at 14 mmHg level.

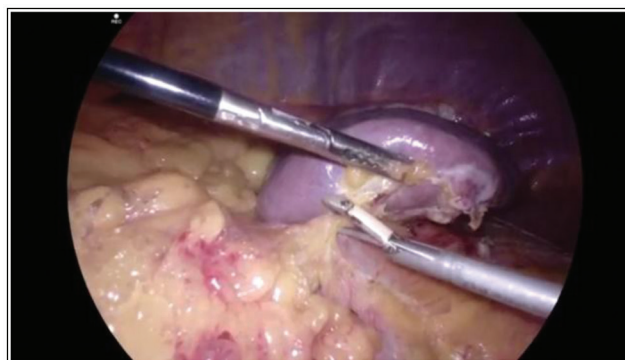The operation is done through four ports: the optic port (10 mm) is inserted in the left midclavicular line near the umbilical level (according to the size of the spleen). The other three ports make an arc facing the hilum of the spleen, a 5 mm port is inserted in the left midclavicular line or slightly to the right 5–7 cm above the umbilicus, a 10 mm or 12 mm port is inserted in the stapler group in the left anterior axillary line at or slightly below the level of the umbilicus, the last port (5 mm) is inserted in the left loin. The port in the left midclavicular line was used to free the adhesions around the splenic flexure, if present, to facilitate insertion of the left lumbar port.

We started dissection at the lower pole of the spleen to free the splenocolic and phrenico-colic ligaments and then the anterior leaflet of the splenico-pancreatic ligament; thereafter, the gastrosplenic ligament was released and the short gastric vessels were controlled using ligasure or endoclips if needed, now the splenic hilum is exposed and the vessels have to be controlled, this was achieved according to a preassigned method.

In the ligasure group, control of splenic vessels was performed with no dissection in the hilar area. A 10 mm ligasure was applied twice to the vessels, first proximally and then distally (close to the splenic hilum). Thereafter, the distal seal was transected (Fig. 1).

In the endoclip group, control of splenic vessels was achieved using hemlock clips after splenic hilar

Figure 1



Ligasure dissection.

dissection and dissection of the splenic artery and vein from the surroundings, especially the tail of the pancreas. This dissection was achieved by an ultrasonic shear device, ligasure, and sometimes bipolar diathermy (Fig. 2).

In the stapler group, control of splenic vessels was achieved using an endo-GIA stapler (45 mm Echelon Flex Stapler white cartridge), here we did not have to free the hilar vessels from the surroundings, as the stapler was applied to the splenic pedicle just next to the spleen not taking the tail of the pancreas within the bite, then the stapler was fired. In some cases one fire was sufficient but we needed two fires in some cases (Fig. 3).

At the end, the spleen was freed by releasing the remaining ligaments using the hook. Thereafter, the spleen was retrieved through a small Pfannenstiel incision.

Patient's basic data including demographic criteria, indication of splenectomy, size of the spleen, and the operative data including operative time, intraoperative blood loss, and rate of conversion together with the

postoperative complications and hospital stay time were all collected and analyzed using independent *t* test, analysis of variance (ANOVA), and Z test in SPSS program, version 23 (IBM Corp., Armonk, New York, USA).

## Results

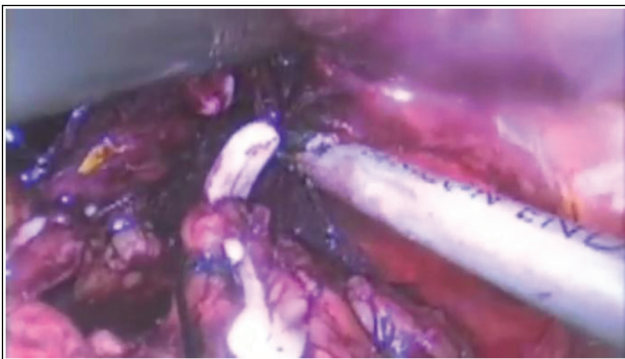
The mean age is  $30.5 \pm 14.5$  years in group I,  $31.1 \pm 14.6$  years in group II, and  $27.25 \pm 14.4$  years in group III; male represents 43.75% in group I, 25% in group II, and 50% in group III; BMI was  $25.9 \pm 3.3$  in group I,  $25.3 \pm 2.9$  in group II, and  $26.5 \pm 2.7$  in group III. The most common indication of splenectomy was idiopathic thrombocytopenic purpura, followed by splenic lymphoma, hereditary spherocytosis, thrombotic thrombocytopenic purpura, thalassemia, and splenic cyst. The span of the spleen as presented in Table 1 is nearly the same among all the study patients. Statistical analysis using one-way ANOVA test showed nonsignificant differences between the three groups regarding demographic criteria and splenic span. One-tailed Z test revealed the same results regarding the indication of splenectomy.

Among the 48 patients of the study only one patient of group II was converted to open surgery, the mean operative time was  $140.6 \pm 30.1$  min in group I,  $159.4 \pm 30.5$  min in group II, and  $142.9 \pm 27.2$  min in group III. Intraoperative blood loss (measured in the suction container at the end of the procedure) was  $166.6 \pm 87$  ml in group I,  $247.5 \pm 155.5$  ml in group II, and  $185.3 \pm 75.2$  ml in group III, only one case in group II complicated with intraoperative bleeding that entailed conversion. One-way ANOVA test showed nonsignificant difference regarding the operative time, but significant difference regarding intraoperative blood loss, there was no significant difference in terms of intraoperative complications and conversion rate.

The average hospital stay time (days) was  $2.9 \pm 0.66$  in group I,  $3.5 \pm 1.1$  in group II, and  $3.03 \pm 0.67$  in group III, with nonsignificant difference between groups. The amount of drainage was  $80.6 \pm 52.8$  ml in group I,  $191 \pm 134.8$  ml in group II, and  $93.1 \pm 54.9$  ml in group III. Statistical analysis showed a significant difference between the three groups.

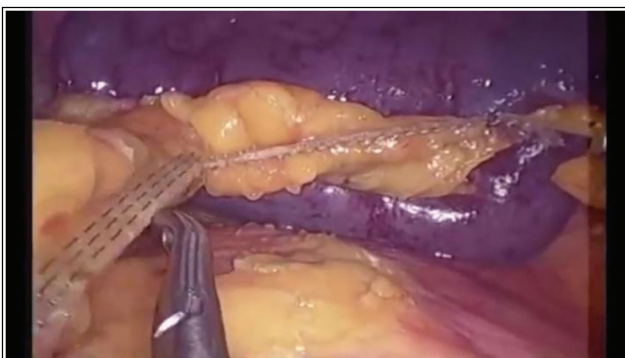Postoperative complication rate was higher in group II being two cases of postoperative fever, two cases ileus, and one case left hypochondrial collection resolved after ultrasound-guided aspiration. In group I, there was one case of fever and one case of ileus and in group III, there was one case of fever and calf deep venous thrombosis that was managed with fractionated

Figure 2



Endoclip applied to the vessels.

Figure 3



Pedicle stapled by three rows of staples.

**Table 1 Demographic criteria and indications of splenectomy.**

	Group I: ligasure	Group II: endoclip	Group III: endo-GIA	F	P
Age	30.5±14.5	31.1±14.6	27.25±14.4	0.33	0.72
Sex [n (%)]					
Male	7 (43.75)	4 (25)	8 (50)		
Female	9 (56.25)	12 (75)	8 (50)		
BMI	25.9±3.3	25.3±2.9	26.5±2.7	0.53	0.59
Splenic span	15.2±2.6	15±1.8	15.3±2.7	0.067	0.94
Indication [n (%)]					
ITP	8 (50)	6 (37.5)	7 (43.75)		
HSC	3 (18.75)	1 (6.25)	3 (18.75)		
Thalassemia	1 (6.25)	1 (6.25)	2 (12.5)		
Splenic cyst	–	2 (12.5)	1 (6.25)		
Lymphoma	2 (12.5)	2 (12.5)	3 (18.75)		
TTP	2 (12.5)	4 (25)	–		

HSC, hereditary spherocytosis; ITP, idiopathic thrombocytopenic purpura; TTP, thrombotic thrombocytopenic purpura.

**Table 2 Operative and postoperative data**

	Group I: ligasure	Group II: endoclip	Group III: endo-GIA	F	P
Operative time	140.6±30.1	159.4±30.5	142.9±27.2	1.96	0.15
Blood loss	166.6±87	247.5±155.5	185.3±75.2	3.69	0.032*
Conversion [n (%)]	0	1 (6.25)	0		
Intraoperative complication [n (%)]	0	Uncontrolled bleeding	0		
Hospital stay	2.9±0.66	3.5±1.1	3.03±0.67	2.3	0.11
Drainage	80.6±52.8	191±134.8	93.1±54.9	3.8	0.029*
Postoperative complications [n (%)]					
Ileus	1 (6.25)	2 (12.5)	0		
Fever	1 (6.25)	2 (12.5)	1 (6.25)		
Collection	0	1 (6.25)	0		
DVT	0	0	1 (6.25)		

DVT, deep venous thrombosis. \*Significant difference.

heparin and conservative measures. Operative and postoperative data are presented in Table 2.

## Discussion

The widespread use of laparoscopic surgery and the increased experience in laparoscopic splenectomy made it the standard treatment for many splenic diseases either benign, malignant, or selected trauma cases [14]. Huge splenomegaly and intraoperative bleeding are the main causes of laparoscopic splenectomy, bleeding comes either from injured splenic vessels or injured splenic capsule during the dissection of the hilum or the dissection of the spleen from the surroundings [15].

Many ways do exist for dissecting splenic ligaments, this includes monopolar or bipolar diathermy, the ultrasound shear devices (harmonic shears), and of course the ligasure. Each modality has its limitations, diathermy cannot control vessels larger than 2–3 mm diameter; ultrasound shears are excellent dissectors but cannot control vessels larger than 5 mm diameter; and ligasure can control only vessels not more than 7 mm in diameter [4]. For controlling the splenic vessels we can recruit ligasure devices as excellent coagulator

and cutting devices; we can use endoclips after skeletonization of the splenic vessels but this entails excessive dissection in the region of the hilum and tail of the pancreas or we can use endo-GIA staplers for control and dissection of the hilum with the vessels inside here not necessary to skeletonize the vessels [16].

In this study, we carried out laparoscopic splenectomy in 48 patients in three different groups, each one having 16 patients for comparing the way in which we are controlling the splenic vessels either ligasure, endoclips, or endo-GIA stapler. The results of the study show nonsignificant differences between the three groups regarding the demographic criteria and indications of splenectomy.

Laparoscopic splenectomy was successful in all patients of groups I and III; one (6.25%) case of group II converted to open surgery due to uncontrolled bleeding from the severed splenic vein.

In group II, meticulous wide dissection of the splenic vessels is mostly required for endoclip applications putting the vessels at a great risk of injury; this was not much required in groups I and III. The rate of conversion

in the study of Romano *et al.* [16] was 7% and in Misawa *et al.* [11] was 3.3%. The low conversion rate may be due to the experience of the working team, simplicity of the cases, and the small or average size of the spleen.

As reported in different studies [4,11], ligasure is very safe in dissecting the splenic hilum and controlling the splenic vessels with less intraoperative blood loss, less need for transfusion, and shorter hospital stay in comparison to the use of endoclips. This was confirmed in our study as we obtained a significant difference between the endoclip group and the other two groups.

The use of endo-GIA stapler helps shortening the operative time especially if combined with harmonic dissectors or ligasure as the hilum control, and dissection was made safe and easy.

A higher incidence of intraoperative bleeding influences the incidence of intraperitoneal collection that in turn may increase hospital admission time. Postoperative complication rate is slightly higher in group II, but this difference is not significant.

Some studies have reported higher thromboembolic manifestations as the Tran *et al.* [17] study. Xu *et al.* [18] reported a rate of 22% portal vein thrombosis and Xu *et al.* reported 7% portal vein thrombosis. The routine use of prophylactic anticoagulants was of great benefit in decreasing postsplenectomy thromboembolic complications.

## Conclusion

Ligasure and endo-GIA staplers are superior to endoclip application for the control of splenic vessels during laparoscopic splenectomy. Their combination helps reducing the operative time.

## Financial support and sponsorship

Nil.

## Conflicts of interest

No conflict of interest, nothing to declare.

## References

- Silvaroli S, Montalembert MD, Sauvat F, Brousse V, Sarnacki S, Irtan S. Laparoscopic splenectomy in children: a modified technique with joint sealing of segmental splenic arteries and veins favorably compared with the classic technique. *Eur J Pediatr Surg* 2017; 27:91–95.
- Minkes RK, Lagzdins M, Langer JC. Laparoscopic versus open splenectomy in children. *J Pediatr Surg* 2000; 35:699–701.
- Reddy VS, Phan HH, O'Neill JA, Neblett WW, Pietsch JB, Morgan WM, *et al.* Laparoscopic versus open splenectomy in the pediatric population: a contemporary single-center experience. *Am Surg* 2001; 67:859–863. discussion 863–864.
- Shabadong H, Maddah G, Tavassoli A, Jangjoo A, Alvandipour M, Abdollahi A. Laparoscopic splenectomy: ligasure or clip ligation? *Surg Laparosc Endosc Percutan Tech* 2012; 22:136–138.
- Pattenden CJ, Mann CD, Metcalfe MS, Dyer M, Lloyd DM. Laparoscopic splenectomy: a personal series of 140 consecutive cases. *Ann R Coll Surg Engl* 2010; 92:398–402.
- Lee WF, Wu SC, Yong CC, Chen C, Wang C, *et al.* Hand-assisted laparoscopic splenectomy—preliminary experience in Southern Taiwan. *Chang Gung Med J* 2010; 33:67–72.
- Romano F, Caprotti R, Franciosi C, Fina SD, Colombo G, Uggeri F, *et al.* Laparoscopic splenectomy using ligasure. Preliminary experience. *Surg Endosc* 2002; 16:1608–1611.
- Gelmini R, Romano F, Quaranta N, Caprotti R, Tazzioli G, Colombo G, *et al.* Sutureless and stapleless laparoscopic splenectomy using radiofrequency: ligasure device. *Surg Endosc* 2006; 20:991–994.
- Wang GY, Liu YH, Lü GY, Liu K, Zhang W, Li N, Tan YQ. [The value of spleen subpedicle two steps severance with ligasure in laparoscopic splenectomy]. *Zhonghua Wai Ke Za Zhi* 2008; 46:1457–1459. Chinese.
- Canda AE, Ozsoy Y, Yuksel S. Laparoscopic splenectomy using ligasure in benign hematologic diseases. *Surg Laparosc Endosc Percutan Tech* 2009; 19:69–71.
- Misawa T, Yoshida K, Iida T, Sakamoto T, Gocho T, Hirohara S, *et al.* Minimizing intraoperative bleeding using a vessel-sealing system and splenic hilum hanging maneuver in laparoscopic splenectomy. *J Hepatobiliary Pancreat Surg* 2009; 16:786–791.
- Evangelos P, George B, Theodore L, Anastasios M. Laparoscopic splenectomy: current concepts. *World J Gastrointest Endosc* 2017; 9:428–437.
- Fujioka S, Yoshida K, Okamoto T, Yanaga K. Stapleless laparoscopic splenectomy using harmonic scalpel by 2-step sealing. *Int Surg* 2013; 98:385–387.
- Barbaros U, Dincag A, Deveci U, Akyuz M, Tükenmez M, Erbil Y. Use of electrothermal vessel sealing with ligasure device during laparoscopic splenectomy. *Acta Chir Belg* 2007; 107:162–165.
- Romano F, Caprotti R, Franciosi C, *et al.* The use of ligasure during pediatric laparoscopic splenectomy: a preliminary report. *Pediatr Surg Int* 2003; 19:721–724.
- Romano F, Gelmini R, Caprotti R, *et al.* Laparoscopic splenectomy: ligasure versus endo GIA: a comparative study. *J Laparoendosc Adv Surg Tech A* 2007; 17:763–767.
- Tran T, Demyttenaere SV, Polyhronopoulos Séguin C, Artho GP, Kaneva P, Fried GM, Feldman LS. Recommended timing for surveillance ultrasonography to diagnose portal splenic vein thrombosis after laparoscopic splenectomy. *Surg Endosc* 2010; 24:1670–1678.
- Xu M, Xue W, Ma Z, Bai J, Wu S. Resveratrol reduces the incidence of portal vein system thrombosis after splenectomy in a rat fibrosis model. *Oxid Med Cell Longev* 2016; 2016.