

Surgical and functional outcome of laparoscopic TAPP repair of bilateral inguinal hernia using a single large mesh

Mohamed I. Abuelnasr, Sherif M. Elkaffas, Hussein Elgohary, Hazem E. Ali

Department of General Surgery, Faculty of Medicine, Benha University, Benha, Egypt

Correspondence to Mohamed I. Abuelnasr, MBBCh, MSc, MD, PhD, Department of General Surgery, Faculty of Medicine, Benha University, Benha, 13518, Egypt. Tel: +01151788175; e-mail: drabuelnasr@gmail.com

Received: 21 May 2022

Revised: 07 July 2022

Accepted: 02 August 2022

Published: 05 April 2023

The Egyptian Journal of Surgery 2023, 41:947–953

Aim

The aim was to examine laparoscopic transabdominal preperitoneal patch repair (TAPP) repair of bilateral inguinal hernia using one big mesh instead of using one mesh for each side as usual.

Patients and methods

A prospective cohort trial was carried out on 40 patients with bilateral inguinal hernia. Laparoscopic TAPP repair using a single large mesh with fixation, and the preoperative and postoperative (PO) course of each patient was followed up for 24 months.

Results

Operative time ranged from 70 to 110 min. Blood loss in the operation ranged from 10 to 50 ml, with a mean value of 21.79 ± 8.23 ml. Bleeding occurred in two patients (5%) with hospital stay ranged from 1 to 3 days. Regarding PO complications, port infection occurred in one (2.5%) patients, hematoma occurred in only one (2.5%) patient, orchitis occurred in three (7.5%) patients, and groin pain occurred in three (7.5%) patients. None of the patients had recurrence, and the time to return of normal activities ranged from 4 to 9 days.

Conclusion

The use of a single large mesh during laparoscopic TAPP repair for bilateral inguinal hernias is a method that is possible, safe, and cost-effective with low rates of PO morbidities with a low recurrence rate.

Keywords:

bilateral inguinal hernia, laparoscopic transabdominal preperitoneal patch repair, single large mesh

Egyptian J Surgery 2023, 41:947–953
© 2023 The Egyptian Journal of Surgery
1110-1121

Introduction

Inguinal hernia repair is one of the most frequent surgical procedures; more than 700 000 inguinal hernias are repaired annually in the USA [1]. Overall, 20–30% of patients with inguinal hernia present with bilateral hernias at diagnosis [2].

Nowadays, laparoscopy has become the most preferred approach for hernia repair [3]. The recent HerniaSurge Group international guidelines for inguinal hernia management stated that the laparoscopic approach is the gold standard treatment for bilateral inguinal hernias [4].

A reduction in postoperative (PO) pain, a quicker recovery period, and a shorter amount of time spent in the hospital are some of the many advantages that are associated with laparoscopic repair. There are many more advantages as well [5]. On the contrary, laparoscopic repair has been slow to gain approval in the medical community. It is possible that this is owing to issues with surgical technique and a steep learning curve, which need to be addressed.

Following a laparoscopic transabdominal preperitoneal patch repair, several studies have found instances of mesh migration [6,7]. We decided the use of a single large mesh with fixation in bilateral inguinal hernia to reduce the incidence of mesh migration and recurrence rate.

Evaluation of simultaneous laparoscopic transabdominal preperitoneal patch repair (TAPP) of bilateral inguinal hernias using a single big mesh for both sides was the major objective of the current investigation.

Patients and methods

The current prospective clinical cohort study was conducted at surgery department, Benha University Hospital, after obtaining approval from the local ethical

This is an open access journal, and articles are distributed under the terms of the Creative Commons Attribution-NonCommercial-ShareAlike 4.0 License, which allows others to remix, tweak, and build upon the work non-commercially, as long as appropriate credit is given and the new creations are licensed under the identical terms.

committee and after fully informed written consent was signed by the patients. The study was performed from March 2017 till January 2021, including the follow-up period.

Participants in this prospective trial had to have bilateral inguinal hernia and be between the ages of 21 and 65 years to be considered for enrollment. This research includes instances that occurred more than once.

Those who were high risk for General Anesthesia (GA) or had significant scrotal hernias, as well as patients whose BMI was more than 35 kg/m², were excluded from the research.

Methods

Preoperative assessment

A thorough history was gathered to establish the presence or absence of diseases that are known to cause elevations in intra-abdominal pressure, such as persistent coughing, persistent constipation, or trouble peeing. To arrive at an accurate assessment of the difficulties of the operation, the history of prior procedures and the PO diagnoses of patients who have had recurrent hernias was gathered.

It is recommended that regular ultrasonography be conducted to rule out cryptorchidism, spermatic cord hydrocele, and malignancies. Routine preoperative laboratory investigation was done.

Surgical technique

Patients received general anesthesia before being positioned in the supine position with a Trendelenburg tilt of 10° and both arms in the adduction position by their sides. The surgeon is positioned on the opposite side of hernia he/she decides to begin with, the assistant is positioned diagonally across from the surgeon, and the monitor is positioned at the foot of the operating table.

After urinary catheterization, pneumoperitoneum was created using a Veress needle through umbilical stab incision. Then, a 10-mm visiport trocar (camera port) was inserted through the supraumbilical incision and a 30° telescope was inserted through this port. Then, two 5-mm trocars were inserted on both sides of optical trocar in the midclavicular line at the level of umbilicus.

Laparoscopic exploration was done to identify any abdominal masses, anatomical landmarks (median umbilical fold, medial umbilical folds, and spermatic cord structures), the site and type of hernia, triangle of pain, and triangle of doom to avoid them during mesh fixation.

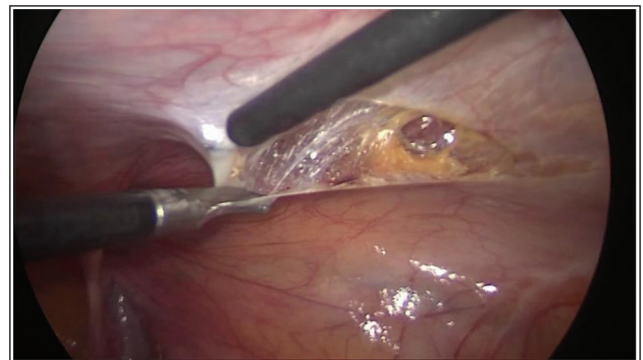
We started the preperitoneal dissection by making two separate incisions on both sides of the peritoneum using the hook and the diathermy (Fig. 1) beginning three to 4cm above any potential defects from the anterior superior iliac spine until the medial umbilical ligament on the same side, and identifying the inferior epigastric vessels (Fig. 2).

We begin with medial dissection to the sac by mixed sharp and blunt dissection till exposure of Cooper's ligament and the pubis (Fig. 2). Then, we started lateral dissection by creation of a preperitoneal pocket lateral to the sac.

Then, dissection of the hernia sac was done with identification of spermatic vessels and vas deference in males and round ligament in females with complete partialization of cord (Figs 3 and 4).

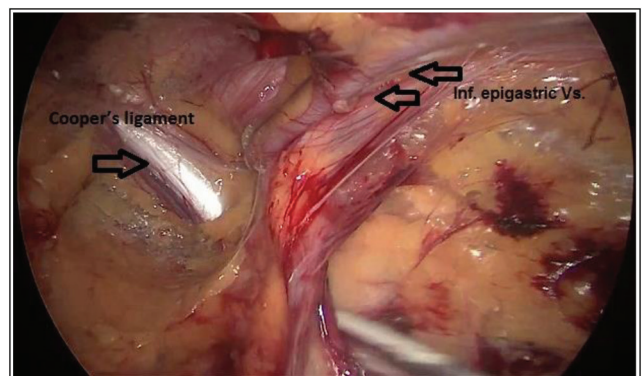
Then, the space of Bogros was opened anterior to the bladder by extended medial dissection on both sides and the two planes were joined together to create one complete preperitoneal space (Fig. 5).

Figure 1



Opening the peritoneum.

Figure 2



Exposure of Cooper's ligament with identification of inferior epigastric vessels.

A large 30 × 12 cm polypropylene mesh was designed to be butterfly in shape. Each wing measured 12 × 13 cm and the bridge was about 4 × 6 cm. The mesh is rolled in and introduced through a 10-mm port to one space and pulled from the opposite side to cover the dissected space, wing for each side and bridge of mesh being at the space of Bogros.

Then, fixation of the mesh was done using a stapler. We begin by median fixation of bridge to Cooper's

ligaments on both sides and then lateral fixation of each wing. Then, closure of the peritoneum was done using the stapler (Figs 6 and 7).

PO care

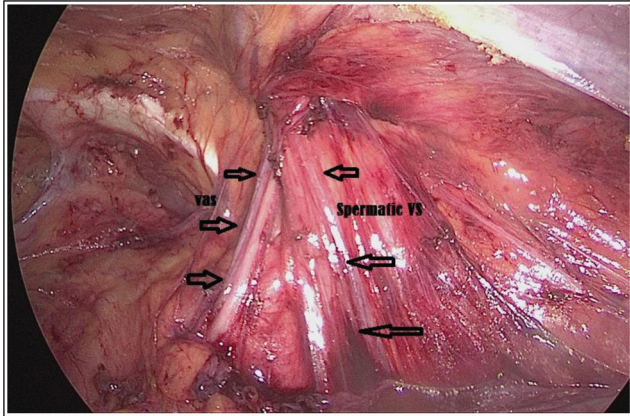
Patients were allowed to go home between 24 and 48 h after being admitted, and they were followed up after 1 week, 1 month, 6 months, and so on, all the way up to 24 months. At each PO checkup, indications and symptoms of PO problems were scrutinized and noted down.

Study outcome

Surgical outcome

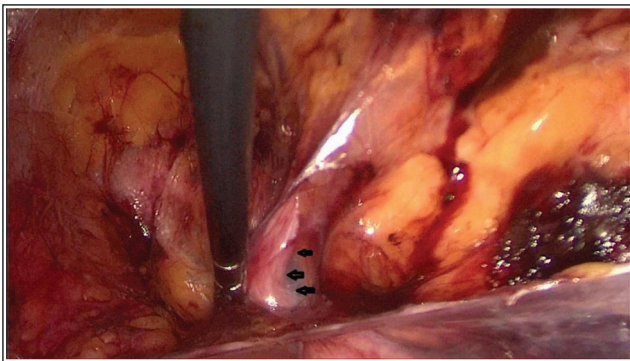
- (1) Intraoperative (IO) collected data included operative time, IO blood loss, and frequency of IO complications
- (2) PO data included PO hospital stay, the frequency of PO complication, and pain score.
- (3) PO follow-up extending for 24 months for the frequency of recurrence.

Figure 3



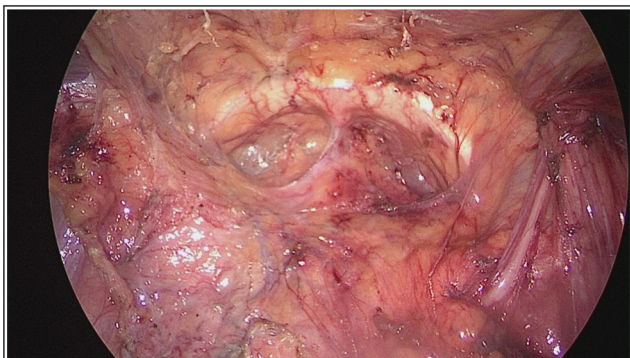
Identification of spermatic vessels and vas deference.

Figure 4



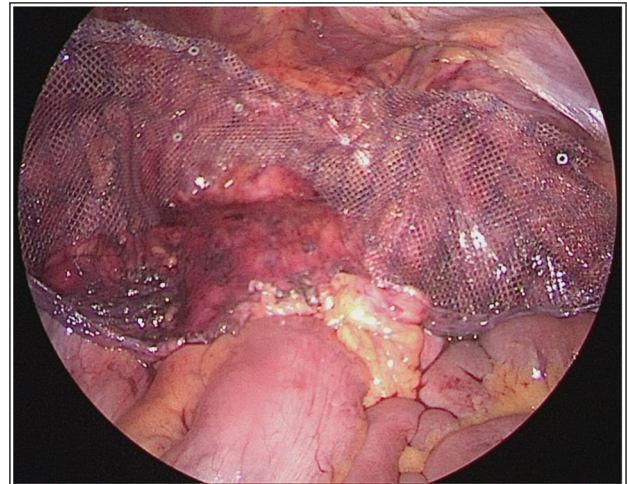
Identification of round ligament in females.

Figure 5



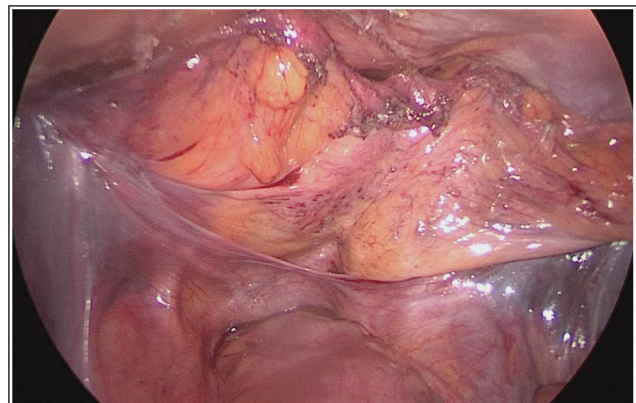
Opening space of Bogros.

Figure 6



Fixation of the mesh.

Figure 7



Closure of the peritoneum.

Functional outcome

- (1) Evaluation of the effect of this type of repair on the improvement of the quality of life was done by comparing the preoperative results of the two main components of the Short Form (36) Health Survey (SF-36) (physical component summary and mental component summary) [8] with the PO results at 3 and 6 months PO.
- (2) Return of normal activity of the patients was assessed.

Statistical methods

Once data were collected, a code sheet was developed. Organization, tabulation, presentation, and analysis of data were performed using SPSS (Statistical Package for the Social Sciences) V26 of (IBM, Armonk, NY, USA). The data were presented as numbers and percentages for the qualitative data and mean, SD, and ranges for the quantitative data with parametric distribution. SF-36 score was compared preoperatively and PO using repeated measures analysis of variance.

Results

Baseline characteristics of the study participants

The study included 40 patients with bilateral inguinal hernia. The age of the study participants ranged from 18 to 65 years, with a mean value of 38.05 ± 11.36 years, and BMI ranged from 20 to 35 kg/m^2 , with a mean value of $27.17 \pm 4.03 \text{ kg/m}^2$.

Regarding the sex of the study participants, 31 (77.5%) patients were males and nine (22.5%) patients were females. Regarding the type, 20 (50%) patients were direct, 10 (25%) patients were indirect, and 10 (25%) patients were mixed (Table 1).

Table 1 Baseline characteristics of the study participants

	Study participants (n=40)
Age (years)	
Mean±SD	38.05 ± 11.36
Range	18–65
Sex [n (%)]	
Male	31 (77.5)
Female	9 (22.5)
BMI (kg/m ²)	
Mean±SD	27.17 ± 4.03
Range	20–35
Type [n (%)]	
Direct	20 (50)
Indirect	10 (25)
Mixed	10 (25)

Regarding the comorbidities in the study participants, nine (35%) patients had comorbidities in the form of benign prostate hyperplasia in six patients (15%), chronic obstructive pulmonary disease in four patients (10%), cardiovascular disease in three patients (7.5%), diabetes mellitus in two patients (5%), and hepatic disease in one patients (2.5%). Previous repair was unilateral in seven (17.5%) patients and bilateral in two (5%) patients. A total of 31 (77.5%) patients did not have previous repair (Table 2).

Operative, IO, and PO data

All patients passed smooth with uneventful operative and immediate PO course. Regarding operative data, American Society of Anesthesiologists score was 1 in 22 (55%) patients, 2 in 11 (27.5%) patients, and three in seven (17.5%) patients. Operative time ranged from 70 to 110 min, with a mean value of 88.5 ± 8.56 min. Blood loss in the operation ranged from 10 to 50 ml with a mean value of 21.79 ± 8.23 ml except for a one case, which had blood loss of 150 ml. None of the cases were converted to open (Table 3).

Table 2 Comorbidities and previous repair in the study participants

	Study participants (n=40) [n (%)]
Comorbidities	
No	26 (65)
BPH	6 (15)
DM	4 (10)
CVD	3 (7.5)
COPD	2 (5)
Hepatic	1 (2.5)
Previous repair	
No	31 (77.5)
Unilateral	7 (17.5)
Bilateral	2 (5)

BPH, benign prostate hyperplasia; COPD, chronic obstructive pulmonary disease; CVD, cardiovascular disease; DM, diabetes mellitus.

Table 3 Operative data in the study participants

	Study participants (n=40) [n (%)]
ASA score	
1	22 (55)
2	11 (27.5)
3	7 (17.5)
Operative time (min)	
Mean±SD	88.5 ± 8.56
Range	70–110
Blood loss (ml)	
Mean±SD	21.79 ± 8.23
Range	10–50
Conversion to open	
Yes	0
No	40 (100)

ASA, American Society of Anesthesiologists.

Regarding IO complications, bleeding and bladder injury only occurred in two (5%) patients and one (2.5%) patient, respectively (Table 4).

Regarding PO data, PO pain score ranged from two to six with a mean value of 3.45 ± 1.23 , and hospital stay ranged from 1 to 3 days, with a mean value of 1.2 ± 0.46 (Table 5).

Regarding PO complications, port infection occurred one (2.5%) patient, hematoma occurred in only one (2.5%) patient, orchitis occurred in three (7.5%) patients, groin pain occurred in three (7.5%) patients, and none of the patients had recurrence (Table 6).

Table 4 Intraoperative complications in the study participants

	Study participants (n=40) [n (%)]
Bleeding	
Yes	2 (5)
No	38 (95)
Intestinal injury	
Yes	0
No	40 (100)
Bladder injury	
Yes	1 (2.5)
No	39 (97.5)

Table 5 Postoperative pain score, hospital stay, and return to normal activities in the study participants

	Study participants (n=40)
Postoperative pain score	
Mean±SD	3.45 ± 1.23
Range	2–6
Hospital stays (days)	
Mean±SD	1.2 ± 0.46
Range	1–3
Time to return to normal activities (days)	
Mean±SD	5.5 ± 1.41
Range	4–9

Table 6 Postoperative complications in the study participants

	Study participants (n=40) [n (%)]
Port infection	
Yes	1 (2.5)
No	39 (97.5)
Hematoma	
Yes	1 (2.5)
No	39 (97.5)
Orchitis	
Yes	3 (7.5)
No	37 (92.5)
Recurrence	
Yes	0
No	40 (100)
Groin pain	
Yes	3 (7.5)
No	37 (92.5)

Return of normal activities

Regarding the time to return of normal activities, it ranged from 4 to 9 days with a mean value of 5.5 ± 1.41 days.

Quality of life by short form (36) health survey (SF-36)

Regarding the physical and mental components in the summary of SF-36 score in the study participants, it was significantly higher 6 months PO than 3 months PO and preoperatively, and it was significantly higher 3 months PO than preoperatively ($P < 0.001$) (Table 7, Fig. 8).

Discussion

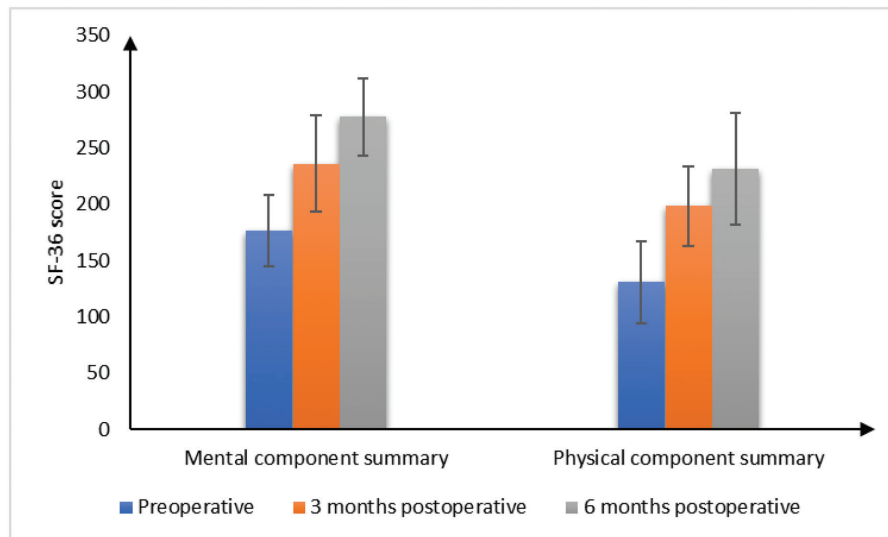
Bilateral inguinal hernias have been the topic of much debate throughout the years. Because simultaneous repairs have been related to an increased risk of recurrence and complications, phased operations were originally advocated. This advice is still relevant today [9]. For bilateral inguinal hernias, Stoppa, an open preperitoneal technique, has been described as having outstanding results. This technique is completed using a large mesh [10]. Several advantages of laparoscopic TAPP repair for bilateral inguinal hernias include reduced pain after surgery, mesh placement in the

Table 7 SF-SF36 score preoperative, 3 months, and 6 months postoperative in the study participants

	Study participants (n=40)	P value
Mental component summary		
Preoperative		
Mean±SD	176.26 ± 3182	$P < 0.001$ $P_1 < 0.001$
Range	104–262.5	$P_2 < 0.001$
Range	104–262.5	$P_3 < 0.001$
3 months postoperatively		
Mean±SD	235.93 ± 42.61	
Range	152–320	
6 months postoperatively		
Mean±SD	277.51 ± 34.42	
Range	205–330	
Physical component summary		
Preoperative		
Mean±SD	130.78 ± 36.6	$P < 0.001$ $P_1 < 0.001$
Range	75–195	$P_2 < 0.001$
Range	75–195	$P_3 = 0.003$
3 months postoperatively		
Mean±SD	198.46 ± 35.54	
Range	135–265	
6 months postoperatively		
Mean±SD	231.36 ± 49.54	
Range	150–330	

Repeated measure analysis of variance test was used. P_1 , significance between preoperative and 3-month postoperative values; P_2 , significance between preoperative and 6-month postoperative values; P_3 , significance between 3- and 6-month postoperative values; SF-36, Short Form (36) Health Survey.

Figure 8



Short Form (36) Health Survey score preoperative, 3 months, and 6 months postoperative in the study participants.

preperitoneal space where the hernia is produced, bilateral repair through a single access, and the avoidance of many disadvantages associated with sequential repair, such as the need to administer anesthesia twice, doubling the risk of general complications, and having a doubled restriction on activity [2,11,12].

Many studies reported mesh migration after laparoscopic transabdominal preperitoneal patch repair [6,7], so we decide to use a single large mesh with fixation in bilateral inguinal hernia to reduce the incidence of mesh migration and recurrence rate.

In the present study, the use of a large mesh gives protection against the development of not only both direct and indirect inguinal hernias but also femoral and obturator hernias. Moreover, the position of the mesh in the preperitoneal space behind the full thickness of the anterior abdominal wall gives great support against any high intra-abdominal pressure conditions as in patients with benign prostatic hyperplasia and chronic obstructive pulmonary disease. Moreover, mesh fixation to Cooper's ligaments on both sides and then lateral fixation of each wing prevents sliding of the sac again in front of the mesh, so it is considered a form of reconstruction of the lower anterior abdominal wall in this vulnerable group of patients.

In a study comparing the transinguinal preperitoneal approach with Lichtenstein hernioplasty, Ray *et al.* [13] reported that the Lichtenstein group had increased incidence of the wound and scrotal collection in the immediate PO period, as well as wound induration and chronic pain in the long-term follow-up.

In the current research, the mean operation time for bilateral hernia repair with a single big mesh was

88.5 ± 8.56 min in this research. For seven (17.5%) patients, the prior surgery was unilateral, whereas for two (5%), the prior repair was bilateral. Compared with bilateral nonrecurrent hernias, bilateral recurrent hernias seem to be a more complicated problem, as shown by the longer operating duration. The mean operating time was 73.99 min in a study by Jacob *et al.* [14] on bilateral laparoscopic hernia repair (TAPP) using two different meshes, and the operational time was quite close to that of the previous study. There is some discrepancy between the stated operating time of 53.9 (35–167) min stated by Bochkarev *et al.* [15] and the time required in our study.

The length of time spent in the hospital after inguinal hernia repair using transabdominal peritoneal repair was 38.7 h in the research done by Salma *et al.* [16], whereas the mean length of time spent in the hospital following the current study was 1.2 days and 0.46 h. A research that was conducted by Zdravko *et al.* [17] found that the average length of hospital stay for the closure of bilateral hernias using two meshes was 2 days.

The TAPP technique carries with it the possibility of causing harm to the viscera and the blood vessels; nevertheless, in our research, bleeding occurred in just two patients (5%), and only one patient had bladder injury (2.5%).

During the procedure in which the peritoneal flap was bonded to the abdominal wall using tackers' firings, the inferior epigastric vessels were injured causing bleeding to occur and the bleeding was controlled using bipolar diathermy. It is possible that bleeding from an injury to the inferior epigastric arteries led to the development of an anterior abdominal wall hematoma in one patient, which was handled with conservative therapy

consisting of antibiotics and anti-inflammatory medicines. The danger of injuring the abdomen wall's arteries and nerves should persuade surgeons to use sutures instead of tackers to close the peritoneal flab, despite the fact that this approach takes a long time. Sajid and colleagues did a research comparing the usage of tackers and fibrin glue for mesh fixing. Fibrin glue was proposed by the researchers as a way to keep the mesh in place and closure the peritoneum, which reduced persistent discomfort and bleeding. Moreover, tackers were used in the experiment [18].

The presence of hematuria and air in the urine catheter bag during surgery revealed that one patient had iatrogenic bladder injury during medial dissection. It was decided to take intracorporeal sutures to approximate bladder walls and keep the urinary catheter for 5 days following surgery.

During the course of this research, orchitis manifested itself in three patients, which accounts for 7.5% of the whole sample. These patients had large inguinoscrotal hernias, which leads us to believe that dissection techniques were most likely to blame. Antibiotic treatment, anti-inflammatory medication, and scrotal support were all effective in curing orchitis in these individuals within three to four weeks.

During the duration of follow-up, there were no instances of recurrence found. It is possible that this is because of the use of a big mesh that covers the inguinal area on both sides, as well as the fact that the mesh was fixed to decrease the risk of mesh movement. According to the findings of a research project carried out by Leibl and colleagues, in which the reason for recurrence following unilateral transperitoneal hernia repair was investigated, the primary reason for recurrence was the use of a mesh that was too small (13 × 8 cm mesh) in 47.4% of the cases. Moreover, it was observed that the major cause of recurrence was a mesh migration (38.9%); however, the incidence of re-recurrence was 0% following a median follow-up of 26 months after the shift to a 15 × 10-cm implant [19]. This supports our hypothesis that a single, big mesh measuring 15 by 30 cm, secured in place, is the best way to prevent recurrence and migration of the mesh.

This research is the first and one of its kind to be conducted in both our hospital and the surrounding area. It focuses on the laparoscopic repair of bilateral inguinal hernias using a single large size mesh. One of the drawbacks of our research is that there were only a very limited number of cases to begin with. This surgical laparoscopic technique improved the patients' expectation of improved well-being, making it feasible

and more acceptable for our patients and other patients who wanted a good solution for their conditions and improvement of their status of life, with no added major comorbidities.

Financial support and sponsorship

Nil.

Conflicts of interest

There are no conflicts of interest.

References

- Perez AJ, Strasse PD, Sadava EE, *et al.* Nationwide analysis of inpatient laparoscopic versus open inguinal hernia repair. *J Laparoendosc Adv Tech A* 2020; 30:292–298.
- Griffin KJ, Harris S, Tang TY, *et al.* Incidence of contralateral occult inguinal hernia found at the time of laparoscopic trans-abdominal pre-peritoneal (TAPP) repair. *Hernia* 2010; 14:345–349.
- Bittner R, Montgomery MA, Arregui E, Bansal V, Bingener J, Bisgaard T, *et al.* Update guidelines on laparoscopic (TAPP) and endoscopic (TEP) treatment of inguinal hernia (International Endohernia Society). *Surg Endosc* 2015; 29:289–321
- The HerniaSurge Group, International guidelines for groin hernia management. *Hernia* 2018; 22:1–165
- Gould J. Laparoscopic versus open inguinal hernia repair. *Surg Clin North Am* 2008; 88:1073–1081
- Agrawal A, Avill R. Mesh migration following repair of inguinal hernia: a case report and review of literature. *Hernia* 2006; 10:79–82.
- Liu S, Zhou XX, Li L, Yu MS, Zhang H, Zhong WX, Ji F. Mesh migration into the sigmoid colon after inguinal hernia repair presenting as a colonic polyp: a case report and review of literature. *World J Clin Cases* 2018; 6:564.
- Patel AA, Donegan D, Albert T. The 36-item short form. *J Am Acad Orthop Surg* 2007; 15:126–134.
- Torraiba-Martinez JA, Moreno-Egea A, Liron-Ruiz R, Alarte- Garvi JM, Morales-Cuenca G, Miguel-Perello J, *et al.* Bilateral inguinal hernia: open surgery versus extraperitoneal laparoscopic repair. *Cir Esp* 2003; 73:282–287.
- Fernandez-Lobato R, Tartas Ruiz A, Jimenez-Miramón FJ, Marin- Lucas FJ, Ruiz de Adana-Belbel JC, Limones-Esteban M. Stoppa procedure in bilateral inguinal hernia. *Hernia* 2006; 10:179–183.
- Kalpesh HP, Jayesh BGL, Bhumika JP. Managing bilateral inguinal hernia laparoscopically is it gold standard?. *Int Surg J* 2017; 4:296–299.
- Wauschkunn CA, Schwarz J, Boekeler U, Bittner R. Laparoscopic inguinal hernia repair: gold standard in bilateral hernia repair? Results of more than 2800 patients in comparison to literature. *Surg Endosc* 2010; 24:3026–3030.
- Ray R, Kar M, Mukhopadhyay M. Transinguinal preperitoneal technique of inguinal hernioplasty-a better alternative to Lichtenstein procedure. *J Clin Diagn Res* 2014; 8:NC01.
- Jacob DA, Hackl JA, Bittner R, *et al.* Perioperative outcome of unilateral versus bilateral inguinal hernia repairs in TAPP technique: analysis of 15,176 cases from the Herniated Registry. *Surg Endosc* 2015; 29:3733–3740.
- Bochkarev V, Ringley C, Vitamvas M, Oleynikov D. Bilateral laparoscopic inguinal hernia repair in patients with occult contralateral inguinal defects. *Surg Endosc* 2007; 21:734–736.
- Salma U, Ahmed I, Ishtiaq S. A comparison of post operative pain and hospital stay between Lichtenstein's repair and Laparoscopic Transabdominal Preperitoneal (TAPP) repair of inguinal hernia: a randomized controlled trial. *Pak J Med Sci* 2015; 31:1062.
- Zdravko P, Mislav R, Zenon P, *et al.* Laparoscopic transabdominal preperitoneal approach for inguinal hernia repair: a fiveyear experience at a single center. *Surg Today* 2011; 41:216–221.
- Sajid MS, Ladwa N, Kalra L, McFall M, Baig MK, Sains P. A meta-analysis examining the use of tacker mesh fixation versus glue mesh fixation in laparoscopic inguinal hernia repair. *Am J Surg* 2013; 206:103–111.
- Leibl BJ, Schmedt CG, Kraft K, Ulrich M, Bittner R. Recurrence after endoscopic transperitoneal hernia repair (TAPP): causes, reparative techniques, and results of the reoperation. *J Am Coll Surg* 2000; 190:651–655.