

One stage repair of giant inguinal herniae: a feasible option

Abdus-Samiu A. Musa-Olomu^a, Titilayo M. Musa^b, Nurudeen A. Adeleke^c,
Nurudeen T. Abdulraheem^d, Abdulwahab A. Ajape^e

^aDepartment of Surgery, University of Ilorin Teaching Hospital, ^bDepartment of Educational Foundation and Counselling, Olabisi Onabanjo University, Ago-Iwoye, ^cNeurosurgeon, Department of Surgery, University of Ilorin Teaching Hospital, ^dPaediatric Surgeon, Department of Surgery, University of Ilorin Teaching Hospital, ^eDivision of Urology, Department of Surgery, University of Ilorin Teaching Hospital, Ilorin, Nigeria

Correspondence to Abdus-Samiu A. Musa-Olomu, MBBS, FWACS, FICS, MSc., PhD, Consultant Surgeon, Department of Surgery, University of Ilorin Teaching Hospital, PMB 1459, Federal Medical Centre, Olabisi Onabanjo Way, Idi-Aba, Abeokuta, Ogun state, Ilorin, Nigeria. Tel: +234-803-0608-704, +234-802-3250-865; e-mail: alwajud1423@gmail.com

Received: 1 July 2023

Revised: 20 July 2023

Accepted: 1 August 2023

Published: 6 October 2023

The Egyptian Journal of Surgery 2023, 42:697–704

Background

Surgical repair of giant inguino-scrotal hernia (GIH), based mainly on anatomical considerations and minimal organ resection; without the use of mesh or pneumo-peritoneum.

Patients/method

Over a 15-year period (2005-2019), all patients managed for GIH were reviewed. They had an elevation of the scrotum, and foot of the bed, to allow for the reducible part of the hernia to gradually return and expand the abdominal cavity. Volume estimations of the hernias were done applying Archimedes' principle followed by a 5-day bowel preparations. Abdomino-inguinal/Inguinal incisions (depending on the size), were made to repair the hernias taking advantage of the special anatomical make-up of the abdominal cavity.

Results

A total of 20 male patients with GIH were treated; 13 were on the right while seven were left-sided. All the GIHs were repaired successfully without any serious morbidity; one patient had a scrotal hematoma that was managed conservatively and another developed a ventral hernia (5 cm long), which was repaired at a later day. An average of 6 months follow-up revealed no recurrence or any other complications.

Conclusion

Surgical techniques in the repair of GIH are many and varied but its rarity has made the adoption of any specific technique(s) impossible. A fairly large series like ours over many years might be a fruitful attempt at solving this problem.

Keywords:

hernia, Inguino-scrotal hernia, inguinal hernia, stage repair

Egyptian J Surgery 42:697–704

© 2023 The Egyptian Journal of Surgery

1110-1121

Introduction

Giant Inguinal Hernia (GIH) is defined as a sac with a capacity greater than 2000 mls or the size of the patient's head or any hernia that extends beyond the mid thigh when the patient is standing [1,2]. GIH is very rare nowadays in medical practice, especially in the developed world where the prevalence has been reported to be very low; the few cases encountered were said to be associated with mental neglect for many years [3]. However, GIH is still relatively more prevalent in the developing world where more cases are reported [4,5]. The reasons advanced for the ones seen in developing and low-resource settings include, ignorance on the part of the patient, lack of trust in the health care system, and poverty [5–7].

The loss of domain of the abdominal space has been used to explain the possible occurrence of abdominal compartmental syndrome following the reintegration of the hernia into the abdominal cavity [3,8]. Some specific problems that have been associated with the management of this giant inguinal hernia include loss

of domain of the abdominal space (with its possible attendant complications when the hernia content is returned), high risk for recurrence, residual scrotal skin and hematoma [6] and lack of resource, such as facilities for pneumo-peritoneum, minimal access surgery and availability of mesh for repairs as found in low-income settings [5].

Several techniques, which involve serial pneumo-peritoneum, debulking of abdominal contents, abdominal relaxing incisions, and use of mesh among others, have been described to address many of the identified peculiarities of this entity [9–12]. Many reports have equally demonstrated the feasibility of management of GIH in a single-stage, without the need for pneumo-peritoneum, mesh repair, and minimal or no organ resection [3,13,14].

This is an open access journal, and articles are distributed under the terms of the Creative Commons Attribution-NonCommercial-ShareAlike 4.0 License, which allows others to remix, tweak, and build upon the work non-commercially, as long as appropriate credit is given and the new creations are licensed under the identical terms.

We herein report our experience with the management of GIH, based on a perceived better understanding of the anatomy and physiology of the abdominal cavity and the abdominal muscle wall, in a single-stage procedure without the use of pneumo-peritoneum or mesh repair and with minimal organ resection.


Patients and method

Institutional Ethical Review clearance was obtained for the study. The study was a descriptive retrospective review of prospectively collected data.

All patients that reported GIH from 2005-2019 were recruited for the study. The exclusion criteria include patients with concurrent chronic obstructive airway disease, pulmonary tuberculosis, obstructive uropathy or intraabdominal tumor and hernia volume of more than 4000 ml. In addition, patients with intercurrent medical illnesses, hypertension, or diabetes mellitus were excluded.

The volume of the hernia was determined in the clinic by the water displacement method (Musa-Olomu water displacement can) based on Archimedes principle (Fig. 1). This gives the estimated volume of the GIH. All included patients had chest radiography, Electrocardiography, and respiratory function test (spirometry) in addition to the basic hematological, biochemical, and microbiological evaluation from the surgical out-patient unit before admission.

Figure 1



Measuring the volume of the inguinal hernia using Achimede's Principle (Musa-Olomu water-can device).

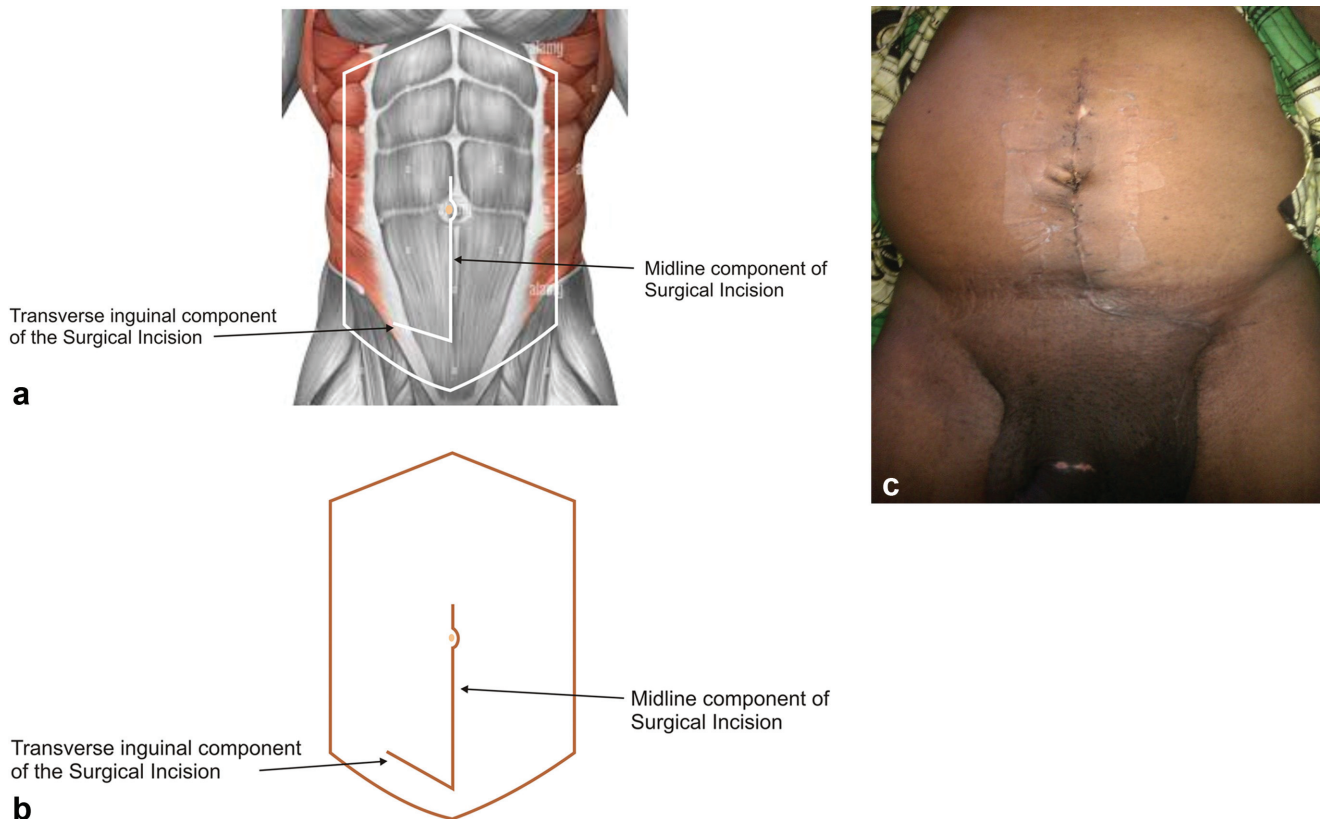
All the patients were admitted and allowed to acclimatize for 2 weeks, within which clinical and psychological counseling was done, the foot end of the bed was elevated for increasing times throughout this period. The aim was to allow the reducible part of the hernia contents to get back into the peritoneum to cause a gradual increase in the abdominal cavity. This, in addition, will encourage the diaphragm to act against the stress of abdominal contents and gravity as well as promote venous return from the legs. This procedure lasted some 2 to 4 weeks depending on the volume of GIH.

About 5 days before the operation, the patients were commenced on a low-residue diet (tea, pap), daily water and soap enema, and high rectal washout on the morning of surgery, this was aimed at reducing the bulk content of the bowel. Another counseling session was held with the patients to further discuss the procedure and the expectations; informed consent was also obtained. At least two pints of compatible blood were made available for the procedure.

Surgical technique

The operation was carried out under General Anesthesia (GA) with an endotracheal tube (ETT) *in-situ* and the patient placed in Trendelenburg position to allow for the reduction of the free part of the hernia sac content into the abdominal cavity and to enable the bladder to be visualized to avoid iatrogenic injury. Size 16FR Foley urethral catheter was routinely passed into the urinary bladder for all patients; intraabdominal access was gained through a midline incision from just above the umbilicus and carried down to the supra-pubic region and joined to the inguinal incision for standard inguinal herniorrhaphy (Fig. 2a-c); this was to afford a good exposure to both abdominal cavity, the hernia sac and its contents and to allow easy reduction of the herniae and close-up without tension. The scrotal skins were very thick due to the chronicity of the hernias but the incisions were deepened and dissections continued until the herniae sacs were identified in the case of indirect ones. The sacs were dissected until the extra-peritoneal fats were seen or the internal ring reached in all cases. Subsequently, the sacs were opened and the reducible parts were first returned into the abdominal cavity and the rest after separating the adhesions between the bowel loops as well as between the loops, the omentum, and the sac. The sac was then carefully resected and the remnants were closed by continuous suturing using vicryl 0 or 1. There was little or no problem with the sliding hernias as these were easily reduced after adhesiolysis. The omenta

Figure 2



(a) Schematic representation of the incision employed, interposed on the anterior abdominal wall image. (b) Schematic description of the incision during surgery. (c) Showing the scar of the incision in one of the patients.

were found squeezed together in some of the cases and considered worthless and were thus resected. There was no need for orchidectomy in any of our patients. The over-stretched internal ring was reconstructed. The posterior wall repair was done using tension-free nylon darning between the conjoint tendon and the inguinal ligament in two layers using nylon 1.

Result

A total of twenty male patients were seen over the study period. The mean (\pm SD) age was 62.90 (\pm 5.63) years [range from 54-70 years] and the majority of them were farmers (Table 1). All of the patients had unilateral giant inguino-scrotal hernia reaching the level of the midthigh or the knees or some 5 cm below it, it was commoner on the right side and with a preponderance of indirect hernia. The mean estimated volume of the hernia was 3039.75 (\pm 319.90) ml (Table 2).

All the patients presented with the consistent triad of massive groin swelling, dragging sensation by the swelling, and interference with normal daily activities, including coitus (Table 3 and Fig. 3a & b). They all presented late because of varying reasons

spanning from fear of surgery to financial constraints (Fig. 4). None of the patients had features suggestive of chronic respiratory diseases, those with premonitory condition and/or obstructive uropathy were excluded.

The repair was undertaken under GA + ETT in all the patients. The contents of the hernia sac was combination of various parts of the abdominal organs in all the patients, however, the combination of the loops of small bowel (ileum), transverse colon and part of the omentum was found in one-half of the patients (Fig. 5). There was no untoward event reported peri-operatively, none of the patients shows any feature suggestive of the abdominal compartmental syndrome. One patient each developed a scrotal hematoma and ventral hernia that were managed conservatively and by herniorrhaphy, respectively.

Discussion

Several researchers have reported the suggestion that inguinal hernia might have attained the status of public health problem in the developing countries of the world Akpo, Lebeau and colleagues, Kombo and Allison [6,7,13]. To qualify to be termed 'Giant Inguinal

Table 1 Demographic variable among patients with Giant Inguinal Hernia

Age of Patients (years)	Frequency	Percent (%)	Mean (\pm SD) [years]
< 50	0	0	
50 –59	5	25	
60-69	12	60	62.90 (\pm 5.63)
\geq 70	3	15	
Total	20	100	
Sex of Patients			
Male	20	100	
Female	0	0	
Total	20		
Occupation of Patient			
Farmers	15	75	
Civil servants	2	10	
Businessman	3	14	
Total	20		

Table 2 Shows the type of Hernia, the side affected, and the estimated hernia volume

Type of Hernia	Frequency	Percentage (%)	Mean (\pm SD)
Indirect	16	80	
Sliding	4	20	
Total	20	100	
Side Affected			
Left	7	35	
Right	13	65	
Total	20	100	
Estimated Hernia Volume (ml)			
< 2000	0	0	3039.75 (\pm 319.90)
2001–3000	9	45	
3001–4000	11	55	
> 4000	0	0	
Total	20	100	

Table 3 Shows the presenting features of patients with giant inguinal hernia (GIH)

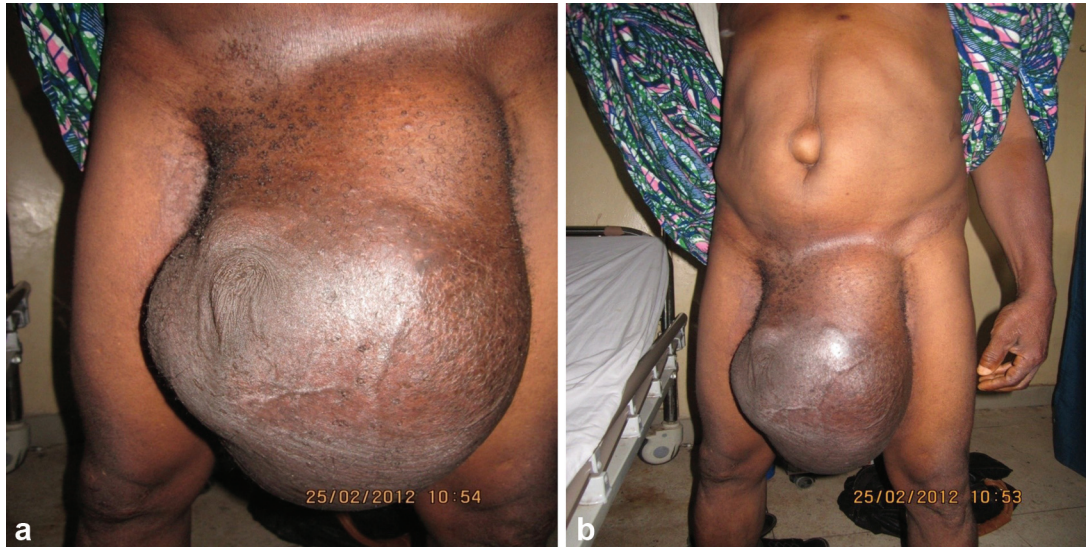Presenting features	Frequency	Percentage (%)
Groin swelling	20	100
Dragging sensation	20	100
Interference with normal activity	20	100
Impaired mobility	14	70
Coital problem	16	80
Vanishing penis	16	80
Dermatitis	6	30
Recurrent bowel obstructive symptoms	5	25

Hernia' it must extend beyond the midpoint of the inner thigh in the standing position. Sading and colleagues, Ertem and colleagues [1,2]. The frequency of encountering GIH and its management have been reported to vary especially among the developed nations and resource limited developing nations of the world.

In this study, all the patients were male with mean (\pm SD) age of 62.90 (\pm 5.63) years [range from 54–70years]; this was in keeping with reports from other parts of the world however, Lebeau and colleagues [7] reported a much lower mean age and in as low as 15-year-old patient. As expected, the majority of our patients were farmers and rural dwellers and they presented late due to reasons which vary from fear of surgery, financial constraints and others which were similar to reports from other resource-limited settings like ours (Table 1 and Fig. 4) Groen and colleagues, Lebeau and colleagues [5,7].

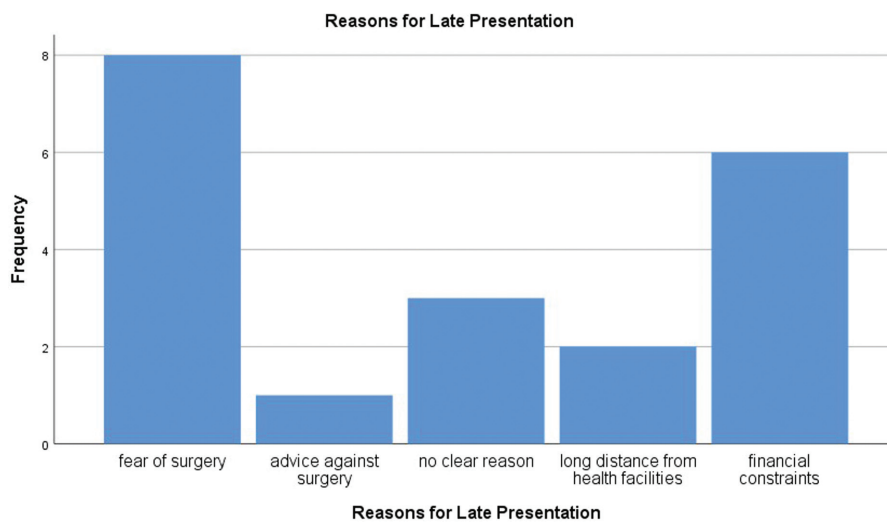
The triad of groin swelling, dragging sensations while walking, and interference with normal activities (including sexual intercourse) was the sine-qua-non in all our patients; although, other features of the presentation included vanishing penis syndrome and recurrent bowel obstructive symptoms (Table 3). This finding was not particularly different from previous reports by Sading and colleagues, Mabula and

Figure 3



(a) Shows the extent of the hernia with invagination of the penis (vanished penis). (b) Showing the contracted anterior abdominal wall muscle and the hernia extent.

Figure 4

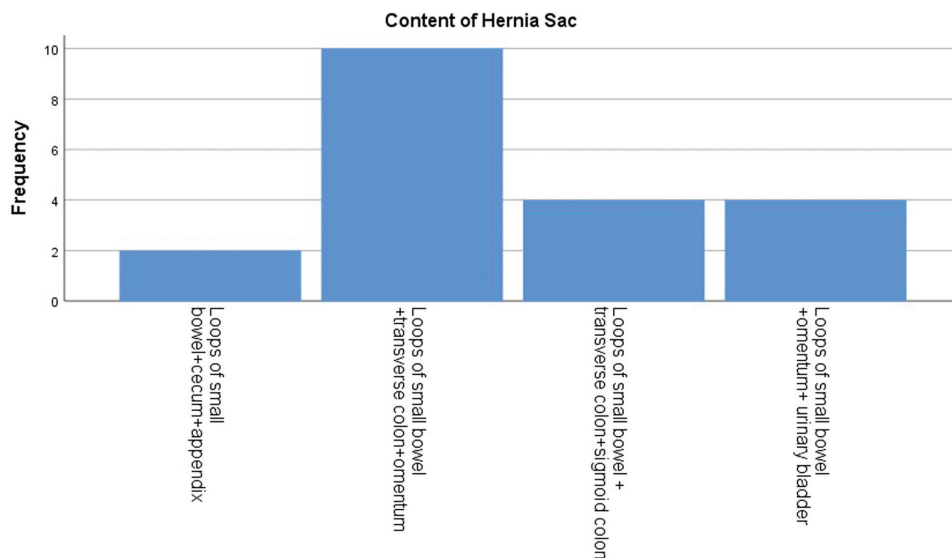


Shows the distribution of reasons given for the late presentation.

colleagues [1–14]. In this report, the indirect hernia was the most encountered, and the right side is more frequently involved. The estimated volume of the hernia was greater than 3000 ml in 55% of the patients and less than 3000 ml in 45% of them. It is noteworthy that none of the patients had hernia volume of less than 2000 ml, thus subjective clinical assessment of GIH seems to correlate well with objective quantification in the definition of GIH as those with hernia volume of more than 2000 ml (Table 2) Ertem and colleagues, Groen and colleagues [2,5]. It is often more convenient and

safer for the repair of GIH to be undertaken under GA +ETT, as it was done in all our patients; Groen and colleagues [5] attempted a third stage repair under spinal anesthesia but had to convert to GA+ETT. The common contents of the hernia sac at operation, in this report, was the combinations of bowel loop of ileum, transverse colon, and omentum; in one-half of the patients (Fig. 5). The omentum was often found squeezed together in some of the cases; they were assessed to be worthless and were resected. This partial omentectomy, which was done in some of the patients, was not necessarily aimed at debulking the

Figure 5



Depicts the distribution of the content of the hernia sac at operation.

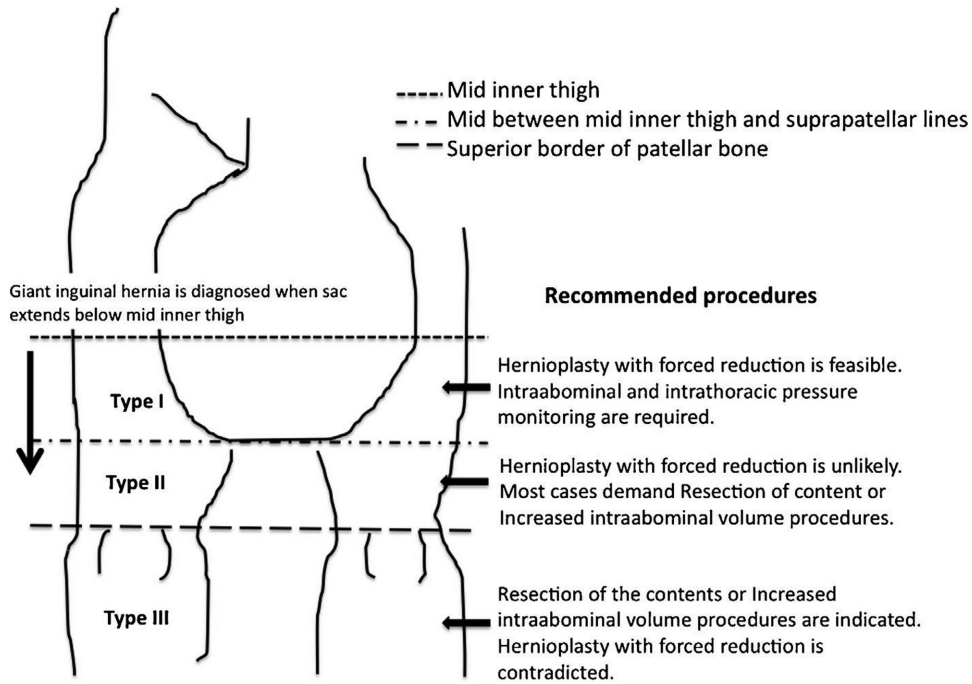
abdominal content but rather to remove the worthless structure. However, the other contents of the sac were returned completely into the abdominal cavity without any feature suggesting intraabdominal compartmental syndrome or other untoward events.

In patients with, GIH the abdominal viscera have lost the domicile of the abdominal cavity because of the long time they had stayed outside the cavity, and the cavity had adapted to be 'empty' Lebeau and colleagues, Koontez [7,15]. It was proposed, and clinically proven in many instances, that sudden return of these herniated viscera may lead to a sudden increase of intraabdominal and intrathoracic pressures with severe consequences of intraabdominal compartmental syndrome which have been well characterized and documented Basukala and colleagues, Papavramidis and colleagues [8,16]. Various techniques had been described, and steps taken, to prevent or mitigate the occurrence of this possible catastrophic event due to loss of intraabdominal domain. These options fall under two main categories, either de-bulking of abdominal contents or enlarging of the abdominal cavity. The de-bulking of abdominal contents often involves extensive resection of the bowel (both small and large bowels), omentectomy, and splenectomy; these procedures are not without significant morbidity, and occasional fatality, for the patients Trakarnsagna and colleagues [12]. The calculated risks may sometimes outweigh the benefit, thus the need to err on the side of caution. Enlargement of the abdominal cavity can be done by progressive pneumo-peritoneum, phrenectomy

(creating a ventral hernia and using mesh), or by component separation technique Karthikeyan and colleagues [4]. Several musculocutaneous and scrotal skin flaps have also been incorporated to increase the abdominal cavity volume Karthikeyan and colleagues [4]. Apart from the fact that many of these procedures are technically complex, some of them are not effective. The pneumo-peritoneum has been documented to transmit the pressure onto the scrotal sac and end-up at increasing the size of the hernia against the abdominal cavity that it was intended to do Staubitz and colleagues [3]. More so, the availability of these facilities and technical know-how of these complex procedures are limited in developing nations.

Many contemporary reports have proven that a lot of the procedures described above may not be a prerequisite for a successful repair of GIH without risking the occurrence of the dreaded abdominal compartment syndrome Groen and colleagues, Basukala and colleagues, Kombo and Allison, Mabula and Chalya [5-8,13,14]. It was from this premise that a form of classification of GIH and their recommended management protocol was proposed (Fig. 6) Trakarnsagna and colleagues [12]. In Type I GIH hernioplasty with forced reduction of sac content was deemed to be feasible but monitoring of both the intraabdominal and intrathoracic pressure is mandatory; in Type II GIH hernioplasty with forced reduction is believed to be unlikely to be successful, thus resection of the content or procedures to increase intraabdominal volume are required. In Type III GIH hernioplasty with forced reduction is contraindicated

Figure 6

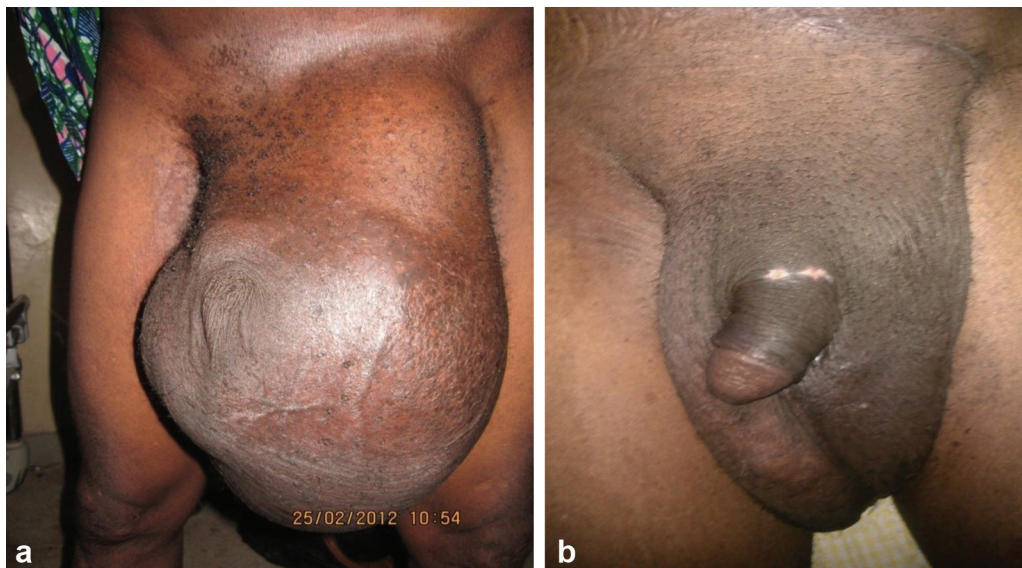

New classification of giant inguinal hernia and recommended procedure. (Adapted from Ref [12]).

Trakarnsagna and colleagues [12]. From our study, and experiences over the years, we concluded that in highly selected patients, with estimated hernia volume of about 4000 ml or less, a single-stage repair of GIH without the need for preoperative pneumoperitoneum, mesh or component separation repair, or deliberate organ resection was feasible with good physiological and acceptable cosmetic outcome (Fig. 7a & b). We believed that the loss of domicile of the

contents of the abdominal cavity do not, in many scenarios, lead to significant contracture of the abdominal spaces. There exist connective tissue in the abdominal cavity that divides the cavity into different anatomical spaces filled by fatty or loose areolar tissues which are generally avascular; these spaces have a role in the functioning of urinary, reproductive, and gastro-intestinal systems Sugarbaker [17] and may be available as 'special

Figure 7



(a) Depicts the photograph of one of the patients before and a few weeks after surgery. (b) Showing the shrunken left scrotum weeks after the surgery.

anatomical spaces' to admit the hernia contents at repair of GIH.

The reducible portion of hernia returns into the abdominal cavity when the patient sleeps and continues to make both the abdominal wall muscles and the diaphragm active. We equally believed that our protocol of elevating the foot of the bed, to allow for expansion of the abdominal cavity, over a period of two weeks prior to repair further contribute to the outcome observed. We considered and took the advantage of the reducible part of the hernia and utilized it to expand the abdominal cavity by elevation of the foot of the bed.

Conclusion

Giant Inguino-scrotal Hernia is still infrequently encountered in surgical practice in the developing world where the modern technological supports are not readily available; single-stage repair, without the need for pre-operation pneumo-peritoneum, complex abdominal wall component separation techniques or major organ debulking surgeries, is feasible in well selected patients. Adherence to basic surgical principle and attention to details should be the guiding principle for good surgical outcome. Few days of bowel preparation in addition to daily water and soap enema, in order to reduce intestinal contents and facilitate easy reduction, might have positively affected our outcome.

Acknowledgements

We acknowledged the assistance of Mr. Oluwaseun OLOWOYO for secretariat work.

Presentation: Part of this paper was presented at the 43rd Annual Conference of the West African College of Surgeons in 2013.

Source of Support: nil

Financial support and sponsorship

Nil.

Conflicts of interest

There are no conflicts of interest.

References

- Saiding Q, Chen Y, Wang J, Pereira CL, Sarmiento B, Cui W, *et al.* Abdominal wall hernia repair: from prosthetic meshes to smart materials. *Mater Today Bio* 2023; 21:10069.
- Ertem M, Gok H, Ozben V, Hatipoglu E, Yildiz E. Can volumetric measurement be used in the selection of treatment for inguinoscrotal hernias?. *Turk J Surg* 2018; 34:13–16.
- Staubitz JI, Gassmann P, Kauff DW, Lang H. Surgical treatment strategies for giant inguinoscrotal hernia – a case report with review of the literature. *BMC Surg* 2017; 17:135.
- Karthikeyan VS, Sistla SC, Ram D, Ali SM, Rajkumar N. Giant Inguinoscrotal Hernia – Report of a rare case with literature review. *Int Surg* 2014; 99:560–564.
- Groen RS, Sesay S, Kushner AL, Dumbuya S. Three-stage repair of a giant inguinal hernia in Sierra Leone: A Management technique for low-resource settings. *JSCR* 2011; 12:8.
- Akpo EE. Bilateral giant inguinoscrotal hernia: psychosocial issues and a new classification. *Afr Health Sci* 2013; 13:166–170.
- Lebeau R, Anzoua KI, Traore M, BI Kalou IL, N'Dri AB, Kakou AG, *et al.* Management of giant inguinoscrotal hernia in resource limiting setting. *J Gastrointest Dig Syst* 2016; 6:1.
- Basukala S, Rijal S, Pathak BD, Gupta RK, Thapa N, Mishra R. Bilateral giant inguinoscrotal hernia: A case report. *Int J Surg Case Rep* 2021; 88:106467.
- Valliattu AJ, Kingsnorth AN. Single-stage repair of a giant inguinoscrotal hernias using the abdominal wall component separation technique. *Hernia* 2008; 12:329–330.
- Kovachev LS, Paul AP, Chowdhary P, Choudhary P, Filipov ET. Regarding extremely large inguinal hernias with a contribution of two cases. *Hernia* 2010; 14:193–197.
- Patsa A, Tsiaousis P, Papaziogas B, Koutelidakis I, Goula C, Atmatzidis K. Repair of a giant inguinoscrotal hernia. *Hernia* 2010; 14:305–307.
- Trakarnsagna A, Chinswangwatanakul V, Methasate A, Swangsri J, Phalanusitthepha C, Parakonthon T, *et al.* Giant inguinal hernia. Report of a case and reviews of surgical techniques. *Int J Surg Case Rep* 2014; 5:868–872.
- Kombo BB, Allison AB. Giant inguino-scrotal hernias seen at the University of Port Harcourt Teaching Hospital. *Niger J Med* 2013; 22:317–318.
- Mabula JB, Chalya PL. Surgical management of inguinal hernias at Bugando Medical Centre in Northwestern Tanzania: our experience in a resource-limited setting. *BMC Res Notes* 2012; 5:585.
- Koontz AR. Hernias that have forfeited the right of domicile: use of pneumoperitoneum as an aid in their operative cure. *South Med J* 1958; 51:165–168.
- Papavramidis TS, Marinis AD, Pliakos I, Kesisoglou I, Papavramidou N. Abdominal compartment syndrome-Intra-abdominal hypertension: Defining, diagnosing, and managing. *J Emerg Trauma Shock* 2011; 4:279–291.
- Sugarbaker PH. Peritoneum and Peritoneal Cavity. Section 8; Chapter 63 Stringer MD, Smith AL, Wein AJ (Sectional Eds). In: Standring S, (Ed). *Gray's Anatomy: The Anatomical Basis of Clinical Practice*. 41st Edition. Edinburgh: Elsevier 2016. 1098–1110