

Bipolar electrosurgery versus thermocautery in circumcision with safe anesthetic techniques

Mohamed M. Abdalgaleil^a, Ahmed M. Shaat^b

Departments of ^aGeneral Surgery, ^bAnesthesia and Intensive Care, General Organization for Teaching Hospitals and Institutes, Damanhour Teaching Hospital, El-Beheira Governorate, Egypt

Correspondence to Mohamed M. Abdalgaleil, MD, Kafr Eldawar, El-Beheira Governorate 22625, Egypt. Tel: +20 106 398 8262; fax: +20 452 240 022; e-mail: mkameha0@gmail.com

Received: 10 January 2023

Revised: 30 January 2023

Accepted: 10 February 2023

Published: 9 June 2023

The Egyptian Journal of Surgery 2023, 42:81–87

Background

Circumcision is one of the most common surgical procedures. Several techniques and devices have been used for circumcision, of them, bipolar electrosurgery and thermocautery devices are widely used.

Objective

To compare the safety and efficacy of bipolar electrosurgery versus thermocautery in the circumcision of infants under combined general and local anesthesia.

Patients and methods

This was a prospective randomized study comparing two techniques of male circumcision, carried out on 120 infants enrolled for circumcision at Damanhour Teaching Hospital, El-Beheira, Egypt, between September 2022 and January 2023. Infants were randomly allocated into two equal groups assigned to circumcision. All infants were circumcised by bone-cutting forceps, whereas in group A, cutting the foreskin with a scalpel and achievement of hemostasis with bipolar electrosurgery, and in group B, cutting the foreskin and achievement of hemostasis using thermocautery.

Results

There were no statistically significant differences between both groups as regards demographic data, time to emerge from anesthesia, and intraoperative complications. The operative and anesthesia duration were significantly prolonged in group A than in group B. Penile edema, postoperative pain, and analgesic consumption were significantly lower in group A than in group B. Four-week follow-up demonstrated no statistically significant differences between both groups.

Conclusion

Bipolar electrosurgery significantly decreases penile edema, postoperative pain, and analgesic consumption, but with an increase in operative and anesthesia duration. The use of thermocautery is a fast and safe method for circumcision but with significant penile edema, postoperative pain, and analgesic consumption.

Keywords:

bipolar electrosurgery, circumcision, penile block, thermocautery

Egyptian J Surgery 42:81–87

© 2023 The Egyptian Journal of Surgery

1110-1121

Introduction

Circumcision is the most commonly performed surgical procedure in the pediatric age group worldwide and is considered one of the oldest operations done [1]. Circumcision is performed in the majority of cases because of religious, ethnic, and cultural causes, with a minority for medical indications [2]. It should be performed properly with safe surgical techniques, with the least possibility of complications [3]. Many different techniques are used for circumcision in neonates and infants, including bone-cutting forceps, the Gomco clamp, the Mogen clamp, the Plastibell device, and the dissection technique [4,5]. Although it is not well studied in recent literature, using bone-cutting forceps is still one of the most commonly used techniques in circumcision in Egypt, and using bipolar electrosurgery or thermocautery for the achievement of hemostasis is preferred by many surgeons to minimize the risk of bleeding. Penile blocks are

commonly used in pediatric patients as an adjunct to general anesthesia for procedures on the penis such as circumcision, as it provides anesthesia to the distal 2/3 of the penis only, without sensory or motor block to the lower extremities [6]. The aim of this study was to compare the safety and efficacy of bipolar electrosurgery versus thermocautery in the circumcision of infants under combined general and local anesthesia.

Patients and methods

After obtaining approval from the local ethics committee, written consent was obtained from each

This is an open access journal, and articles are distributed under the terms of the Creative Commons Attribution-NonCommercial-ShareAlike 4.0 License, which allows others to remix, tweak, and build upon the work non-commercially, as long as appropriate credit is given and the new creations are licensed under the identical terms.

parent to participate in the study. This was a prospective randomized study comparing two techniques of male circumcision, carried out on 120 infants who were candidates for elective circumcision under combined general and local anesthesia at Damanhour Teaching Hospital, El-Beheira, Egypt, between September 2022 and January 2023. The trial was registered on ClinicalTrials.gov (NCT05590052). Inclusion criteria were age from 1 to 12 months and infants with normal preoperative laboratory investigations. Exclusion criteria included infants with congenital malformations, especially hypospadias and epispadias, congenital inguinal hernia, and undescended testis, infants with acute penile infection or excess suprapubic fat, infants with cardiovascular, neurological, respiratory, liver, renal, endocrine, blood, or immune diseases, and allergy to any drug used in this study. Infants were randomly allocated into two equal groups (60 infants each) and circumcised by bone-cutting forceps with cutting foreskin using a scalpel and achievement of hemostasis using bipolar electrosurgery in group A, while cutting foreskin and achievement of hemostasis using thermocautery in group B. All infants in the study were subjected to clinical assessment in the form of history, clinical examination, and laboratory investigations in the form of complete blood picture and coagulation profile (prothrombin time/activity, international normalized ratio, and activated partial thromboplastin time). Infants were fasting for 4 h for breast milk, 6 h for formula milk, and solid meal, and 2 h for clear fluid before the operation. All operations were done by the same surgeon with more than 10 years of experience in surgery. On arrival at the operating room, monitoring using an ECG and pulse oximetry was applied.

General anesthesia was induced using sevoflurane 7% in 100% O₂, through a facemask, until loss of eyelash reflex and a peripheral intravenous cannula was secured. Anesthesia was maintained with sevoflurane 3% in 100% O₂ with spontaneous ventilation till the end of surgery. The sevoflurane concentration was increased by 1% when movement occurred. Local anesthesia with a dorsal penile nerve block was given 10 min before the procedure.

Dorsal penile nerve block technique

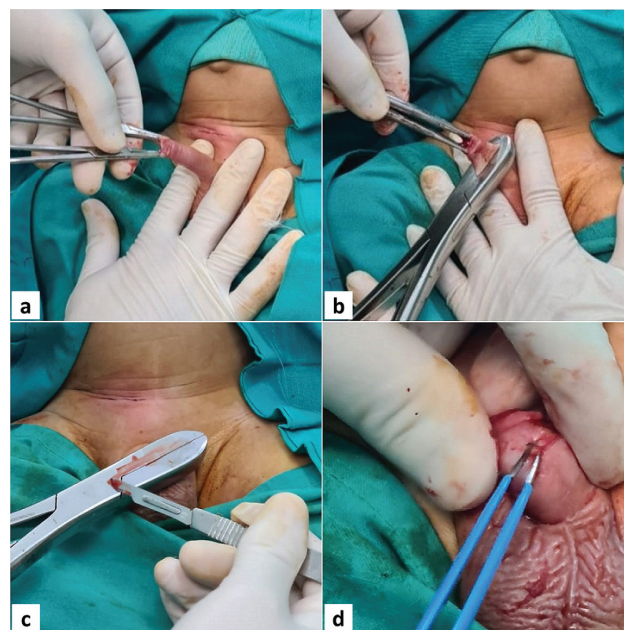
Under aseptic precautions, the penis was pulled downward to put the Scarpa's fascia under tension, and a 25-G needle was inserted on one side of the suspensory ligament and advanced until it touches the symphysis pubis. The needle was then withdrawn slightly and redirected to pass below the pubic

symphysis pubis, slightly laterally to enter the appropriate space deep to the Scarpa's fascia with a distinct 'pop,' the syringe was aspirated to ensure there is no flashback indicating the needle tip lies in an artery/vein, and the local anesthetic (bupivacaine hydrochloride 0.25%, 0.5 ml/kg, not exceeding a dose of 2 mg/kg) (Bupivacaine HCl 0.5%, 20-ml vial, 5 mg/ml; DBK Pharma, Obour City, Qalyubia, Egypt) was infiltrated. The procedure was repeated for the contralateral side. Due to the innervation of the frenulum of the penis, an additional 1 ml of local anesthetic was infiltrated at the base of the ventral penis.

Circumcision technique

The surgical area was cleaned with a povidone-iodine solution and covered with a sterile drape. The foreskin was retracted away from the glans with the cleaning of any smegma. For marking skin anteriorly and posteriorly at the coronal sulcus level, pressure was applied from the penile base to the pubic bone and the length of the foreskin to be cut was determined. The foreskin was lifted with clamps at the 6 and 12 O'clock positions and squeezed to the level of the skin mark with the lower edge of the bone-cutting forceps used for circumcision on the skin mark at an angle of ~15–20° with the ventral side up (Fig. 1a, b). In group A, a scalpel was used for cutting excess foreskin with the achievement of hemostasis using bipolar

Figure 1



(a) The foreskin was lifted with clamps at the 6 and 12 O'clock positions. (b) Bone-cutting forceps was applied at an angle of 15–20°. (c) A scalpel was used for cutting excess foreskin. (d) Hemostasis with bipolar electrosurgery.

electrosurgery (Fig. 1c, d), whereas in group B, thermocautery was used for cutting excess foreskin and hemostasis (Fig. 2a–c). No skin approximation to the mucosa by suturing was done in either group. At the end of the surgery, the inhalational anesthetic vaporizer was turned off and the infant was transferred to the postanesthesia care unit. Postoperative analgesia in the form of paracetamol 15 mg/kg oral drops (Cetal oral drops, 15-ml bottle, 100 mg/ml, EIPICO, 10th of Ramadan city, El-Sharqia, Egypt) was prescribed on demand if the infant is continuously crying and refusing feeds. The parents applied topical gentamicin sulfate cream three times daily for the first 3 days after the procedure. Follow-up visits in the outpatient clinic were planned at 1 and 4 weeks postoperatively.

Measurements

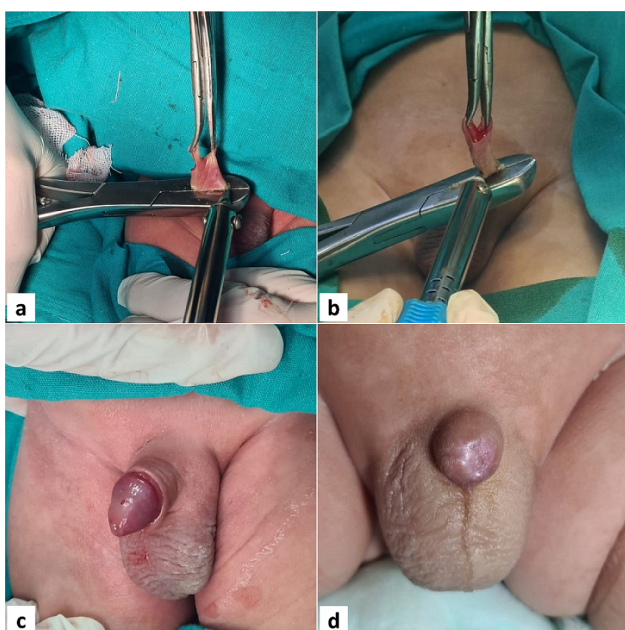
Demographic data, age (months), and weight (kg) were collected. Duration of anesthesia (min) (the time from induction of anesthesia till stoppage of anesthesia) and duration of surgery (min) (the time from holding the penis till the dressing of the penis) were recorded. Time to emerge from anesthesia (min) (the time from stopping the use of anesthetics till the appearance of at least two signs of crying or attempting to cry, vigorous limb movements, gagging on suction, eye-opening, and looking around) was recorded. The incidence of any intraoperative complications was recorded as bleeding or glans injury. The incidence of any postoperative complications (during 4 weeks postoperative) was recorded as bleeding requiring

surgical intervention, penile edema, wound infection, meatal stenosis, or trapped penis, secondary to phimosis as a result of circumcision. For postoperative analgesic doses (primary outcome measure), parents were told to record how many times they gave analgesic (paracetamol) each day for the first 3 days separately, and then if there was still a need for analgesia after these 3 days until the first postoperative clinic visit after 1 week. The primary endpoint was 4 weeks postoperative. The primary outcome variable of this study was the number of doses of postoperative analgesic (paracetamol).

Sample-size calculation and randomization

After reviewing the literature [7], we found that by using a two-tailed independent *t* test to detect a difference of 1 in the mean number of postoperative paracetamol doses (primary outcome variable) between groups with a SD of 1.4, a significance level of 5%, a power of 95%, and an effect size of 0.7, at least 52 infants were required per group, therefore, we included 60 infants in each group to compensate for potential dropouts and protocol violations. The sample size was calculated using the G*Power program, version 3.1.9.7, 2020, Institute für Experimentelle Psychologie, Heinrich-Heine-Universität, Düsseldorf, Germany. Randomization was performed by the online application (<https://www.randomizer.org/>), which randomly assigns infants into two equal groups (60 each) and concealed using sealed, opaque envelopes that were randomly selected by each parent and contained a group number in which the infant was to be enrolled.

Figure 2



(a, b) Cutting excess foreskin and hemostasis using thermocautery. (c) Penis after circumcision. (d) A case of a trapped penis.

Statistical analysis

Charts were drawn using Microsoft Excel 2019 MSO, 64-bit, Redmond, Washington, USA. Data were statistically analyzed using the Statistical Package for the Social Science Program (IBM SPSS Statistics for Windows 2020, Version 27.0. 64-bit; IBM Corp., Armonk, New York, USA). Data were tested with Student's *t* test for comparison between continuous variables and were expressed as mean±SD and Pearson's χ^2 test, for comparison between dichotomous or nominal variables, and expressed as the number of patients (percentage). A *P* value less than 0.05 was considered statistically significant, and less than 0.001 was considered statistically highly significant.

Results

One hundred forty-eight infants who were candidates for circumcision were assessed for enrollment; 28

infants were excluded and 120 infants were eligible for randomization. All 120 infants randomized completed the study and were included in the analysis (Fig. 3). There were no statistically significant differences between both studied groups as regards age, weight, and time to emerge from anesthesia. The duration of surgery and consequently the duration of anesthesia were longer in group A (11.53±1.732 and 27.03 ±1.813 min) than in group B (5.67±1.084 and 21.13 ±1.142 min) with a highly statistically significant difference between both groups ($P<0.001$) (Table 1). There were no intraoperative complications as regards significant bleeding or glans injury in either group. There were three infants who experienced early postoperative bleeding on the first postoperative day, two (3.3%) in group A and one (1.7%) in group B, managed by hemostatic sutures with no statistically significant difference between both groups. After 1 week (first follow-up visit), 16 infants had developed penile edema, four (6.7%) in group A, and 12 (20%) in group B, managed with

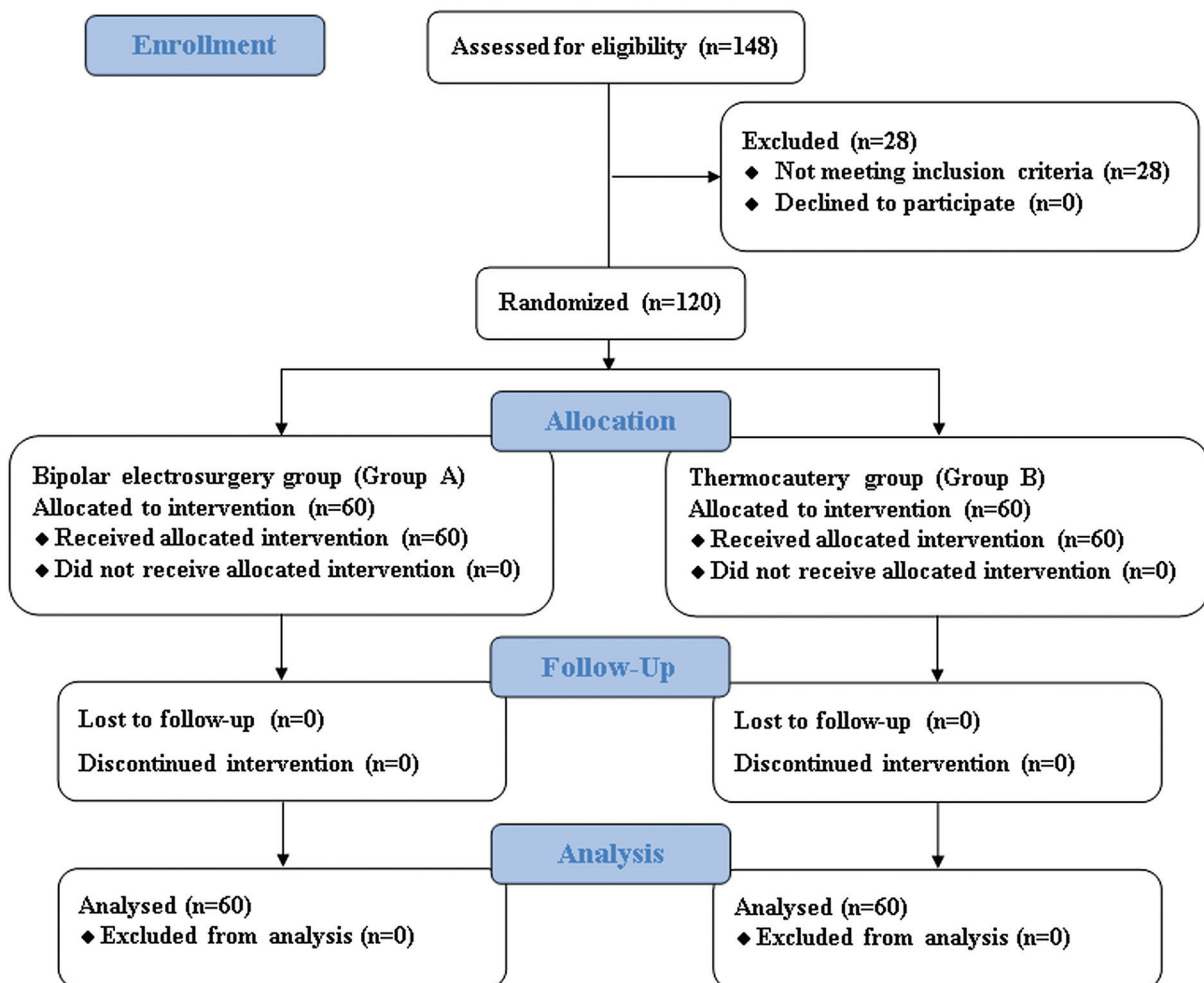
medical treatment, and resolved in 5–8 days, with a statistically significant difference between both groups ($P=0.032$). As regards wound infection, there were two (3.3%) infants in group A and three (5%) in group B managed with medical treatment with no statistically significant difference between both groups. After 4

Table 1 Demographic data, duration of surgery, duration of anesthesia, and time to emerge from anesthesia of the two studied groups

Variables	Group A (N=60) (mean±SD)	Group B (N=60) (mean±SD)	t test	P
Age (months)	4.68±2.837	4.38±3.026	0.560	0.576
Weight (g)	6820.55 ±1522.798	6678.33 ±1488.140	0.609	0.544
Duration of surgery (min)	11.53 ±1.732	5.67±1.084	22.243	<0.001*
Duration of anesthesia (min)	27.03 ±1.813	21.13 ±1.142	21.329	<0.001*
Time to emerge from anesthesia (min)	4.58±0.829	4.28±1.059	1.727	0.087

*Highly significant.

Figure 3



CONSORT flow diagram.

weeks (second follow-up visit), there were two cases of meatal stenosis one in each group and managed by meatal dilatation on two sessions 1 week apart, and one case of a trapped penis in group B (Fig. 2d), managed by surgical repair with no statistically significant difference between both groups (Table 2). Postoperative pain and analgesic consumption in the first three postoperative days were significantly higher in group B than in group A (Table 3).

Discussion

Circumcision is one of the most frequently and oldest-performed surgeries in human medical history [1]. The most common indications for it are religious and traditional reasons, but sometimes for medical problems. In Egypt, parents preferred their infants to be circumcised in the first year of age. The reported prevalence of circumcision in Egypt is

94.7% and the worldwide prevalence of circumcision is 38% in a total of 237 countries [8]. Due to this high prevalence, continuous investigation and search for a fast and safe reliable method that does not have serious complications have no end, especially if we know that most cases are performed under local anesthesia [9]. The most serious complication of circumcision is bleeding, mainly in the early postoperative period, which may have serious morbidity and mortality if not urgently and properly managed because of the small blood volume of the infants [10]. Previously, the most commonly used method for achieving hemostasis is suture ligation and suturing as it is available and needs no equipment, but it takes more time with less cosmesis [9]. Since the introduction of electrosurgery and thermocautery devices in achieving hemostasis in circumcision, continuous investigations on their safety are not ended. These devices achieve less bleeding and allow the operation to be very short. The mechanisms of action of electrosurgery and thermocautery devices are completely different, and to predict their possible complications, we should understand their mechanism of action [11]. Electrosurgery uses a high-frequency electrical current to coagulate, cut, or desiccate tissue. Bipolar electrosurgery uses lower voltages, so less energy is required [12]. With bipolar electrosurgery, the risk of patient burns is significantly reduced as the current passes only through the tissue between the two electrodes of the instrument. When bipolar forceps is applied directly to a bleeding vessel, the energy from the electrosurgery device travels several millimeters along the vessel, causing a short circuit with

Table 2 Intraoperative and postoperative complications of the two studied groups

Variables	Group A (N=60) [n (%)]	Group B (N=60) [n (%)]	χ^2 test	P
Intraoperative bleeding	0	0	0.0	1.000
Glans injury	0	0	0.0	1.000
Postoperative bleeding	2 (3.3)	1 (1.7)	0.342	0.559
Penile edema	4 (6.7)	12 (20)	4.615	0.032*
Wound infection	2 (3.3)	3 (5)	0.209	0.648
Meatal stenosis	1 (1.7)	1 (1.7)	0.0	1.000
Trapped penis	0	1 (1.7)	1.008	0.315

*Significant.

Table 3 Paracetamol doses in the first three postoperative days of the two studied groups

Variables	Group A (N=60) [n (%)]	Group B (N=60) [n (%)]	χ^2 test	P
1st postoperative day				
Nil	0	0	0.0	1.000
1 dose	46 (76.7)	34 (56.7)	5.400	0.020*
2 doses	14 (23.3)	26 (43.3)	5.400	0.020*
3 doses	0	0	0.0	1.000
Total (0/1/2/3)	0/46/14/0	0/34/26/0	5.400	0.020*
2nd postoperative day				
Nil	10 (16.7)	3 (5)	4.227	0.040*
1 dose	31 (51.7)	19 (31.7)	4.937	0.026*
2 doses	16 (26.7)	27 (45)	4.385	0.036*
3 doses	3 (5)	11 (18.3)	5.175	0.023*
Total (0/1/2/3)	10/31/16/3	3/19/27/11	14.035	0.003*
3rd postoperative day				
Nil	35 (58.3)	18 (30)	9.766	0.002*
1 dose	23 (38.3)	34 (56.7)	4.043	0.044*
2 doses	2 (3.3)	8 (13.3)	3.927	0.048*
3 doses	0	0	0.0	1.000
Total (0/1/2/3)	35/23/2/0	18/34/8/0	11.176	0.004*

*Significant.

short bursts of energy, with only a minimum power setting needed to prevent delayed bleeding. All these data declare that the bipolar type of electrosurgery method is safe for hemostasis and bleeding control in circumcision [12]. The thermocautery device does not transmit electrical energy to the tissue but transmits heat and causes cauterization. When it is used to cut the foreskin, it does not cut continuously like a scalpel. Therefore, its blade should be rotated to the right and left during cutting tissues. If the blade is insufficiently heated, it may increase the incidence of scarring and damage to tissues that can impair wound healing [13]. If tissue damage and intense scar tissue developed along the cutting line, pathological phimosis develops, and the penis is trapped inside, but it is common in cases of a buried penis, especially in cases with excess suprapubic fat [11]. Previous studies showed that only limited tissue damage develops from the use of thermocautery in circumcision and does not lead to significant scarring, as a result of these studies, it is established that thermocautery can be used safely [2,11,13]. Karaman *et al.* [11] reported that the use of thermocautery has no significant scar tissue in the biopsy examinations of circumcisions performed with no negative effect on vascular or neural structures. As regards the duration of surgery, the thermocautery method was associated with significantly less operative time than the bipolar one, as there was a long time spent in the achievement of hemostasis with the bipolar electrosurgery method. In a previous study performed on 121 neonates, the mean operative time was 6 min when thermocautery was used [14] and this indicates less time needed for the procedure as a whole. This goes hand-in-hand with what was found in the literature [15,16]. Saracoglu *et al.* [10] reported that circumcisions done with the thermocautery method led to less bleeding, with less operative time, when compared with the other methods. Excessive postoperative bleeding in reported cases ranges from 0.1 to 35%, however, blood transfusion was rarely indicated [17]. Tuncer and Erten [18] reported that short-term and long-term complications observed in 1011 cases using the thermocautery method were 21 (2%) cases, of these, 11 (1.08%) had postoperative bleeding, two (0.19%) had surgical site infection, six (0.19%) had trapped penises, one had meatitis (0.01%), and one had a scrotal injury (0.01%). The most frequent complication we observed in our study related to electrosurgery and thermocautery techniques was penile edema. In a study by Méndez-Gallart *et al.* [19], postoperative edema was seen more commonly in the bipolar scissor group than the conventional circumcision group. They explain the reason for edema by excessive thermal damage to the

foreskin during bipolar cutting. In the present study, edema was present in 7.3% of cases of the electrosurgery method that is very small when compared with the thermocautery method that was 21.8%, using local anesthesia may be another factor of edema. Ngcobo *et al.* [20] reported that 30% of patients had penile edema on the second day after surgery, which was a slightly higher rate than in our study; however, the surgical procedure was not made clear. Edema continued for 3–5 days after the surgery and resolved spontaneously in most cases without any medical treatment. A study by Cakiroglu *et al.* [21] reported that glans injury, surgical site infection, meatal stenosis, and trapped penis were rarely observed. The most serious complication was a trapped penis, which occurred in 25 (0.078%) patients. Meatal stenosis developed in six (0.018%) cases, wound infection occurred in only 10 (0.03%) cases, through the formation of an aseptic environment, and penile adhesion was seen in 35 (0.1%) cases. In the present study, we did not observe cases of glans injury, as regards postoperative bleeding, wound infection, meatal stenosis, and trapped penis, there was no statistically significant difference between the two techniques. The case of a trapped penis that occurred in the thermocautery group was repaired 1 month after the first intervention. Our results showed that postoperative pain reflected by the required number of analgesic doses in the first three postoperative days was significantly higher in the thermocautery group than in the bipolar electrosurgery group.

Conclusion

Bipolar electrosurgery significantly decreases penile edema, postoperative pain, and analgesic consumption, but with prolonged operative and anesthesia duration, while the use of thermocautery is a fast and safe method for circumcision but with increased incidence of penile edema, postoperative pain, and consequently analgesic consumption.

Financial support and sponsorship

Nil.

Conflicts of interest

There are no conflicts of interest.

References

- Dunsmuir WD, Gordon EM. The history of circumcision. *Br J Urol* 1999; 83:1–12.
- Tuncer AA, Bozkurt MF, Bayraktaroglu A, Koca HB, Dogan I, Cetinkursun S, *et al.* Examination of histopathological changes of scalpel, monopolar, bipolar, and thermocautery applications in rat experimental circumcision model. *Am J Transl Res* 2017; 9:2306–2313.

- 3 Fraser ID, Tjoe J. Circumcision using bipolar diathermy scissors: a simple, safe and acceptable new technique. *Ann R Coll Surg Engl* 2000; 82:190–191.
- 4 Banieghbal B. Optimal time for neonatal circumcision: an observation-based study. *J Pediatr Urol* 2009; 5:359–362.
- 5 Tucker SC, Cerqueiro J, Sterne GD, Bracka A. Circumcision: a refined technique and 5 year review. *Ann R Coll Surg Engl* 2001; 83:121–125.
- 6 Ashrey EM, Bosat BE. Single-injection penile block versus caudal block in penile pediatric surgery. *Ain-Shams J Anesthesiol* 2014; 7:428–433.
- 7 El-Asmar KM, Abdel-Kader HM, El-Shafei EA, Ashraf A. Comparison between the bone cutter with thermal cautery, Gomco, and Plastibell for circumcision in neonates and infants: a prospective randomized trial. *Egypt J Surg* 2017; 36:27–32.
- 8 Morris BJ, Wamai RG, Henebeng EB, Tobian AA, Klausner JD, Banerjee J, *et al.* Estimation of country-specific and global prevalence of male circumcision. *Popul Health Metr* 2016; 14:1–13.
- 9 Akyüz O, Tatar Z. Is it safe to use a thermocautery device for circumcision? Examination of the histopathological changes emerging after thermocautery assisted circumcisions. *Andrologia* 2021; 53:e13968.
- 10 Saracoglu M, Ozturk H, Zengin T, Kerman HS. Comparison of thermal cautery-assisted circumcision with the conventional technique. *Human Androl* 2014; 4:34–37.
- 11 Karaman MI, Zulfikar B, Caskurlu T, Ergenekon E. Circumcision in hemophilia: a cost-effective method using a novel device. *J Pediatr Surg* 2004; 39:1562–1564.
- 12 Shinmura K, Ikematsu H, Kojima M, Nakamura H, Osera S, Yoda Y, *et al.* Safety of endoscopic procedures with monopolar versus bipolar instruments in an ex vivo porcine model. *BMC Gastroenterol* 2020; 20:1–6.
- 13 Akyüz O, Bodakçı M, Tefekli A. Thermal cautery-assisted circumcision and principles of its use to decrease complication rates. *J Pediatr Urol* 2019; 15:186.e1–186.e8.
- 14 Kamil M, Al badri J. Bone cutter circumcision in neonates. *Al-Kindy Col Med J* 2012; 8:119–121.
- 15 Gologram M, Margolin R, Lomiguen CM. Need for increased awareness of international male circumcision variations and associated complications: a contemporary review. *Cureus* 2022; 14:e24507.
- 16 Muhammad MY, Agbo CA. A systematic review of urethral complications following male circumcision: the importance of provider training. *Niger J Med* 2022; 31:125–132.
- 17 Abdulwahab-Ahmed A, Mungadi IA. Techniques of male circumcision. *J Surg Tech Case Rep* 2013; 5:1–7.
- 18 Tuncer AA, Erten EEA. Examination of short and long term complications of thermocautery, plastic clamping, and surgical circumcision techniques. *Pak J Med Sci* 2017; 33:1418–1423.
- 19 Méndez-Gallart R, Estévez E, Bautista A, Rodríguez P, Taboada P, Armas AL, *et al.* Bipolar scissors circumcision is a safe, fast, and bloodless procedure in children. *J Pediatr Surg* 2009; 44:2048–2053.
- 20 Ngcobo S, Wolvaardt JE, Bac M, Webb E. The quality of voluntary medical male circumcision done by mid-level workers in Tshwane District, South Africa: a retrospective analysis. *PLoS ONE* 2018; 13:e0190795.
- 21 Cakiroglu B, Gozukucuk A, Arda E, Tas T. Reliability of thermocautery-assisted circumcision: retrospective analysis of circumcision performed voluntarily in countries of low socioeconomic status. *Ther Adv Urol* 2019; 11:1–6.