



## Chlorella vulgaris Effectively Attenuates Acetic acid-induced Colitis in Rats by Inhibiting NF- $\kappa$ B, and Caspase-3, While Activating IL-10 Expression

Hadeer Aboumosalem<sup>1</sup>, Abd-Allah A. Mokhbatly<sup>1</sup>, Wael M. Goda<sup>2</sup>, Emad W. Ghazy<sup>1</sup>, Mohamed F. Abou ELazab<sup>1</sup>, Alaa Abdelatty<sup>3</sup>, Zizy I. Elbially<sup>4\*</sup> and Doaa H. Assar<sup>1\*</sup>

<sup>1</sup>Clinical Pathology Department, Faculty of Veterinary Medicine, Kafrelsheikh University, Kafrelsheikh 33516, Egypt.

<sup>2</sup> Faculty of Veterinary Medicine, Department of Clinical Pathology, Damanhour University, Egypt.

<sup>3</sup>Pathology Department, Faculty of Veterinary Medicine, Kafrelsheikh University, Kafrelsheikh 33516, Egypt.

<sup>4</sup>Fish processing and Biotechnology Department, Faculty of Aquatic and Fisheries Sciences, Kafrelsheikh University, Kafrelsheikh 33516, Egypt.

### Abstract

ULCERATIVE COLITIS (UC) is a chronic health condition characterised by inflammation and ulcer formation in the colon and rectum. Although *Chlorella vulgaris* (C.V) possesses anti-inflammatory properties and additional therapeutic advantages, its efficacy in managing colitis has not been researched. Our research aims to examine the anti-colitis properties of *Chlorella vulgaris* using a colitis model in rats induced by acetic acid. Sixty male Wistar rats (150-170 g) were randomly distributed into six groups, including control group, acetic acid (received 2 ml per animal of 4% acetic acid transrectal single dose on the 15th day by (pediatric plastic catheter), sulfasalazine (100mg/kg b.w), *Chlorella vulgaris* only (300 mg/kg b.w), *Chlorella vulgaris* (300 mg/kg b.w) with acetic acid, and *Chlorella vulgaris* at (300 mg/kg b.w) along with sulfasalazine (100 mg/kg b.w orally). Animals with induced colitis were sacrificed on the 7th day after induction, and whole blood was obtained for haematological analysis. Colons were removed for assessment of macroscopic and histological changes and for immunohistochemical and molecular analyses. *Chlorella vulgaris* treatment protects the colonic mucosa from inflammatory cell infiltration and destruction, profound erosive lesions, necrosis oedema, and loss of epithelial integrity. Moreover, administration of *Chlorella vulgaris* was associated with improved haematological parameters, macroscopic features, Malondialdehyde (MDA) and nitric oxide (NO) levels were lowered, whereas antioxidant/oxidant equilibrium was restored, as seen by increased catalase activity and decreased glutathione levels, inhibited inflammation by reducing NF- $\kappa$ B and apoptotic marker caspase-3 in colonic tissue, thus preventing apoptosis. In conclusion, *Chlorella vulgaris* effectively improves AA-induced UC in rats by reducing inflammation, apoptosis, and oxidative stress in colon tissue. Therefore, *Chlorella vulgaris* could be a suitable choice for UC therapy.

**Keywords:** Colitis; *chlorella vulgaris*; acetic acid; sulfasalazine; antioxidant, Gene expression, Rats.

### Introduction

Inflammatory bowel disease (IBD) is a chronic state of inflammation and immunological activation of the gastrointestinal tract. The two major phenotypes of inflammatory bowel disease are Crohn's disease, which can target any part of the gastrointestinal tract

from the mouth to the anus, and ulcerative colitis, which impacts the mucosa of the colon and rectum [1]. The prevalence of colitis is increasing in developing nations, including Egypt [2]. Although the particular genesis of IBD remains unknown, environmental variables, infectious agents, immunological and psychological elements, and

\*Corresponding authors: Zizy I. Elbially, E-mail.: zeze\_elsayed@fsh.kfs.edu.eg, Tel.: 01004060315

(Received 12/05/2024, accepted 04/07/2024)

DOI: 10.21608/EJVS.2024.289158.2084

©National Information and Documentation Center (NIDOC)

genetic predisposition may all play a role in the development of the condition [3;4]. Several investigations have shown that the gastrointestinal tract is a significant producer of reactive oxygen species (ROS). Bacteria, dietary components, and immune cell interactions account for most ROS production [5]. Acute acid-induced colitis is a widely used experimental model for ulcerative colitis because of its similarity to the actual clinical symptoms of UC, as well as its simplicity and consistency. Acetic acid can breach the epithelial barrier, disrupting the equilibrium between luminal antigens and intestinal immunity, which is the main trigger for colitis. In addition, increasing ROS in IBD reduces the total antioxidant capacity (TAC) of intestinal cells, resulting in a loss in the entire antioxidant system of intestinal cells, which includes both enzymatic and non-enzymatic antioxidants [6]. Recently, the main treatments for IBD include corticosteroids, sulfasalazine (aminosalicylates), immunosuppressive medications, and biological therapy [7]. However, these therapy choices have bounded positive benefits and are accompanied by negative side effects [8]. Recent research revealed that the administration of antioxidants with anti-inflammatory properties is useful for treating ulcerative colitis. Inhibition of inflammatory mediators is a useful treatment for both acute and chronic inflammatory disorders. Natural anti-inflammatory medicines with minimal side effects may be produced for long-term use. Microalgae are a natural source of bioactive chemicals and have been widely recognised to have anti-inflammatory properties [9; 10]

*Chlorella vulgaris* (CV) is a green microalga grown with high productivity that can be utilised as a functional food or nutritional supplement for both humans and animals to improve their health [11]. *Chlorella vulgaris*, a very nutritious unicellular freshwater microalga declared safe by the Food and Drug Administration, is an important natural dietary supplement for both humans and various animal species [12]. *Chlorella vulgaris* has various essential components, including the S-nucleotide adenosyl peptide complex, carotenoids, polysaccharides, polyphenols, minerals, and vitamins [13]. *Chlorella vulgaris* has been shown to reduce organ toxicities caused by chemotherapeutic medicines such as paracetamol in rats, in addition to improving stress-altered growth [14]; in the same context, *Spirulina platensis* counteracts the effect of diclofenac sodium in broilers [15], also for cutaneous wound healing capacity in a rat model [16]. In animal and human studies, chlorella species demonstrate antibacterial, anti-inflammatory, analgesic, immune-modulatory, and analgesic properties, as well as anticancer effects with antioxidative, antihypertensive, hypolipidemic, and hypoglycaemic effects [17; 18].

Current research aims to examine the anti-oxidative, anti-inflammatory, and antiapoptotic capacities of *Chlorella vulgaris* by estimating DAI, macroscopic damage, body weight, colon length, colon weight, leukogram, oxidative stress, histopathology, immune-histochemical analysis of the colon, and molecular gene expression in acetic acid-induced colitis to determine a potential role in the management of colitis.

## **Material and Methods**

### *Chemicals and assay kits*

**Glacial Acetic Acid (AA)** was obtained from Piochem for laboratory Chemicals Company (Cairo, Egypt) [19]. It was used for the induction of ulcerative colitis (4% acetic acid by adding distilled water).

**SALAZO-SULPH PYRINE** (Sulphasalazine tablet): supplied by USP KAHIRA Pharma, CAIRO, Egypt. Each enteric coated tablet contains 500 mg sulphasalazine, dissolved in 0.9% normal saline. Therapeutic indications: for the treatment of ulcerative colitis.

Dosage: 100 mg/kg diluted with normal saline 0.9% [20].

**Diethyl aether:** It was obtained from (Spinreact); it was used to Anaesthetize rats [21].

**Catalase (CAT), Malondialdehyde (MDA), reduced Glutathione (GSH), and nitric oxide (NO)** were purchased from BIO-DIAGNOSTIC.

**EDTA was obtained from Salix.**

### *Algae Material*

*Chlorella vulgaris* was purchased from EL- Dokki animal Research Institute. The green microalga *Chlorella vulgaris* was cultivated in a closed photobioreactor [22] and spray-dried after harvesting and centrifugation. Chemical analyses of the algae were performed at the Institute for Cereal Proceeding. The obtained *Chlorella vulgaris* powder was mixed with normal saline and taken orally using an orogastric tube.

Dosage: 300 mg/kg [23]

### *Animals and feed management*

This study was conducted in the Department of Clinical Pathology, Faculty of Veterinary medicine, KFS University, Egypt. Sixty male albino rats weighing between 150 and 170 g each were utilised. Rats were purchased from the Tanta Centre's Animal House Colony and acclimatized for two weeks at room temperature ( $23 \pm 1^\circ\text{C}$ ). Animals were kept in a comfortable habitat with a 12/12 h light-dark cycle and keeping relative humidity around  $55 \pm 1\%$ . The animals were placed in plastic cages. They have

drinking water ad libitum and a typical laboratory diet.

#### *Ethical approval*

Following the normal operating procedures approved by the Institutional Animal Care and Animal Ethics Committee (IAACUC-KSU), Faculty Veterinary Medicine, Kafrelsheikh University, Egypt.

#### *Experimental design scheme*

For the purposes of this experiment, 60 male Wistar rats were assigned randomly to six (6) groups (10 rats in each), with a 21-day experiment period, as shown in figure 1.

The 1st group, (C–ve): Rats were kept as controls and were only administered normal saline continuously for the whole period of the experiment (21 day) through an orogastric tube. Intrarectal instillation of 2ml of normal saline were administered at the 15<sup>th</sup> day of the experiment.

The second group, (C+ve): (Acetic Acid group) (AA); the rats were administered orally with normal saline throughout the trial. 2ml of acetic acid (4%) was administered intrarectally on the 15th day of the experiment as a positive control (ulcerated, untreated). The third group (sulfasalazine, therapeutic group): The rats were treated orally with normal saline for two successive weeks followed by intrarectal administration of 2ml of acetic acid (4%) on the 15th day of the experiment with treatment for one week by sulfasalazine orally (100mg/kg b.w orally).

The fourth group: without colitis induction. Rats were orally administered *Chlorella vulgaris* (300 mg/kg b.w) orally on the first day of the experiment continuously for the whole period of the experiment (21 day).

The 5th group: Rats were orally administered *Chlorella vulgaris* only (300 mg/kg b.w orally at the first day of the experiment) continuously for the whole period of the experiment (21 day) before and after intrarectal administration of 2ml of acetic acid (4%), which had been administered on the 15th day of the experiment.

The 6th group: Rats were orally co-administered *Chlorella vulgaris* (300 mg/kg b.w orally at the first day of the experiment) continuously for 21 days throughout the entire period of the experiment before and after intrarectal administration of 2ml of 44% acetic acid on the 15th day of the experiment with treatment by sulfasalazine at a dose of 100 mg/kg b.w orally for 1 week after colitis induction.

Animals in each group were monitored on a daily basis for clinical symptoms, mortality rates, body weights, and food and water intakes. The rats were

sacrificed on the seventh day after colitis induction; they were killed under diethyl aether anaesthesia.

Induction of colitis: To induce colitis, animals were fasted for 24 h prior to the experiment, although they were permitted to drink water. Under light anaesthesia, 2 mL of 4% acetic acid was administered rectally using a flexible plastic catheter that was 8 cm long.

To avoid leakage of acetic acid, the animals were maintained in the Trendelenburg position for 1 min. Animals in groups one and four underwent the same procedure using normal saline instead of acetic acid solution.

Two hours following the acid administration, treatment commenced with oral administration of *chlorella vulgaris* (300mg/kg), sulfasalazine (100 mg/kg), or its combination for seven consecutive days; animals were sacrificed on the seventh day. Subsequently, the abdomen was surgically opened; the colon was excised, opened lengthwise, and cleansed with normal saline.

Assessment of disease activity index (DAI): Following He et al. [24], clinical indications of colitis were assessed by the disease activity index with three significant symptoms, including stool consistency, presence of rectal haemorrhage and decrease in body weight. The disease activity index (DAI) for all groups was monitored daily following the induction of colitis (Table 1).

DAI = diarrhoea score + rectal bleeding score + body weight loss score/3

#### *Evaluation of colitis severity by scoring macroscopic damage*

Table(2), the colon was macroscopically inspected for clear injuries, including shortening, thickening, hyperaemia, adhesion, necrosis, or other significant morphological changes immediately following death. The abdomen was dissected through a midline incision, and the colons were extirpated and then rinsed with normal cold saline to remove the faeces, and its wet weight after separation of the colon from the adipose tissue and the remaining intestine was weighed using a sensitive balance scale. The excised part of the colon was also measured with the aid of a metre ruler. The weight to length ratio of the colon (g/cm) was calculated [25]. The colon macroscopic damage (CMD) was estimated according to this formula;

CMD =Weight of the colon (g) / Length of the colon (cm)

#### *Blood and colon sampling*

On day 21 of the trial, blood samples were collected through retro-orbital puncture of the medial

canthus of the eyes in anticoagulant tubes under moderate ether anaesthesia by using of clean capillary tubes. The collected blood was analysed for the estimation of the total leukocytic count; total white blood cells (WBC). Subsequently, rats were sacrificed, and the rat abdomen was opened immediately through a midline incision. The colon was removed, flushed gently with ice-cold saline to remove luminal contents with normal saline, cleaned, and dried. Colons were positioned on non-absorbent surfaces, and their weight-to-length ratios were assessed blindly.

The colon was divided into three parts: The first part was dipped in liquid nitrogen and stored at 80°C for molecular analysis. The second part was homogenised in buffered saline solution (10% w/v), and colon homogenates were stored at 80°C for analysis of oxidative and antioxidant parameters. The final portion was placed in 10% fresh formalin solution for histological and immune histochemistry measurements. All samples were collected within 15 min after sacrifice.

#### *Haematological examination*

Blood samples were collected in sterile vacutainer tubes with EDTA to serve as an anticoagulant. for measuring white blood cells (WBCs) using a Rayto RT.7600 Auto Haematology Analyser [26;27].

#### *Estimation of lipoperoxidation and antioxidant markers*

Lipid peroxidation was estimated by colorimetric analysis of malondialdehyde, the main product of lipid peroxidation. MDA was evaluated in tissues homogenate using thiobarbituric acid-reactive substance reaction according to [28], nitric oxide (NO) activity activities with [29]. To estimate oxidative stress activity. A spectrophotometric method for the determination of catalase activity in tissues homogenate was used by [30], and the concentration of GSH in the homogenate was measured spectrophotometrically for analyses of antioxidant status using the method described by [31].

#### *Histopathological analysis*

First, colon samples were fixed in a solution of 10% neutral buffered formalin with a pH of 7.4. Subsequently, the samples underwent a series of processes, including alcohol dehydration, xylene clearing, and subsequent paraffin embedding. Tissue sections were prepared using a microtome, and these sections were utilised to prepare slides for light microscopy analysis. Histopathological assessment involved scoring observed findings on a four-point scale, considering factors such as mucosal necrosis, ulceration, submucosal oedema, haemorrhage, and inflammation. The scoring was conducted across eight high-power fields (HPFs) following a detailed method outlined elsewhere [32].

*Egypt. J. Vet. Sci.*

#### *Immunohistochemistry analysis*

Immunohistochemical staining was performed using paraffin sections fixed onto specially coated glass slides. These sections went through a series of steps, including xylene clearing, rehydration, and antigen retrieval using an EDTA solution at pH 8. The slides were treated with 0.3% hydrogen peroxide (H<sub>2</sub>O<sub>2</sub>) to minimize nonspecific staining and subsequently blocked with a solution containing 5% bovine serum albumin in Tris-buffered saline (TBS) for 2 h. The slides were then prepared and stained with an anti-caspase-3 antibody (Thermo Fisher Scientific, Waltham, MA, USA).

After staining, the slides underwent multiple PBS washes and were then treated with a secondary antibody (EnVision + System HRP; Dako, Santa Clara, CA, USA) for 30 minutes at room temperature. This was followed by additional washing steps and a 2-min incubation with diaminobenzidine (DAB; Dako, Santa Clara, CA, USA). Finally, the slides were counterstained with Mayer's haematoxylin stain and covered with glass cover slides.

Scanned immunohistochemistry (IHC) images (five sections per group) were analyzed using ImageJ software (NIH/Bethesda, Maryland). This analysis involved quantifying the percentage of the area of caspase-3-positive regions (stained dark brown) compared with non-stained regions. This was achieved through the application of thresholding techniques, enabling the determination of the mean percentage of caspase-3-positive stained areas, which are indicative of apoptosis and necrosis [33].

#### *Quantitative analysis of the RNA expression of IL10 and NF- $\kappa$ B by qRT-PCR*

Rat specific primers full sequence for  $\beta$ -actin, NF- $\kappa$ B and IL10 genes are presented in Table.3 [34-36]. Colon Tissue RNA was extracted using TRIzol Reagent (iNtRON Biotechnology, Inc). Complementary DNA (cDNA) was then synthesised using cDNA synthesis kits (INTRON) following the manufacturer's instructions. SYBR green (RT-PCR) was performed using BIoRad IQ2 (japan). The mRNA expression levels of all samples were normalised against  $\beta$ -actin reference gene. Melting curve analysis was performed to confirm the identity and specificity of the PCR products. CT values were analysed using the Stratagene MX3005P software. Estimation of RNA expression variation in different samples. The CT value of each sample was normalised against that of the control group using the " $\Delta\Delta$ Ct" analysis method.

#### *Statistical analysis*

All results are expressed as mean  $\pm$  SEM. One-way analysis of variance (ANOVA) was used for data analysis followed by Tukey's-compare for all pairs of columns. Statistically significant differences were

considered at P value <0.05. All statistical analysis was performed using Graph Pad Prism 8.0 [37].

## Results

### *Mortality rate*

Table.4 and Figure.2A depict the Mortality rate of the control and different treated groups. The control rats in the chlorella vulgaris (300mg/kg)-treated group without colitis induction did not show any abnormal clinical signs or mortality during the entire experimental period. The positive control group exhibited a marked increase in mortality rate (4/10) (40%). Furthermore, the sulfasalazine group used for the treatment of ulcerative colitis showed a decreased mortality rate (1/10) (10%). Chlorella vulgaris administration (300mg/kg) in acetic acid-induced colitis decreased the mortality rate to (20/10) (20%). Meanwhile, the co-administration of chlorella vulgaris (300 mg/kg b.w) with sulfasalazine led to a marked decrease in the mortality rate (0/10) (0%).

### *Disease activity index*

DAI of the control and other treatment groups is illustrated in Table .5 and Figure 2B. Data revealed significant ( $p \leq 0.05$ ) decrease in DAI in the Acetic Acid group compared with the normal control group. The sulfasalazine group demonstrated a significant decrease in DAI compared with the control-positive group. Similarly, the chlorella vulgaris group (300 mg/kg bw) in acetic acid-induced colitis caused a pronounced decline in DAI in contrast with the control-positive group. Meanwhile, the co-administration of chlorella vulgaris (300mg /kg bw) with sulfasalazine showed a significant ( $p \leq 0.05$ ) improvement in DAI compared with the control positive group.

### *Scoring severity of colitis*

In terms of macroscopic damage score, acetic acid-positive colitis rats showed a significant ( $p \leq 0.05$ ) increase in damage score compared with the negative untreated ones. However, all other treatment groups showed a significant ( $p \leq 0.05$ ) decrease in damage scores compared with the positive control group (Table. 5 and Fig.2C).

### *Body weight*

The effect of *C. vulgaris* on body weight is demonstrated in Figure 2D. Concerning body weight, the data obtained indicated a decrease in the positive control group compared with the negative control group. However, in the sulfasalazine group, there was an increase in body weight. Simultaneously, simultaneous supplementation of chlorella vulgaris (300 mg/kg bw) in acetic acid-induced colitis resulted in an improvement in body weight compared with the control positive group. Chlorella vulgaris (300 mg/kg bw) without colitis induction caused a pronounced increase in body weight. Meanwhile, chlorella vulgaris (300 mg/kg bw) along with

sulfasalazine revealed significant ( $p \leq 0.05$ ) increase in body weight compared with the control positive group.

### *Colon weight and length*

The colon weight of the control-positive group revealed significant ( $p \leq 0.05$ ) improvement in contrast to the control-negative group. In contrast, the sulfasalazine group showed a significant decrease in colon weight compared with the control-positive group. Chlorella vulgaris (300 mg/kg bw) without colitis induction caused no change in colon weight compared with the control negative group. Supplementation of chlorella vulgaris (300 mg/kg bw) in acetic acid-induced colitis colon weight showed pronounced improvement compared with the control-positive group. In the same manner, chlorella vulgaris (300mg /kg bw) along with sulfasalazine revealed significant ( $p \leq 0.05$ ) increase in colon weight as matched with the control positive group Table .5 and Fig.3A.

Furthermore, the control-positive group showed significant ( $p \leq 0.05$ ) decrease in colon length compared with the control-negative group Table .5 and Fig.3B and photo1&2. However, the sulfasalazine group revealed a significant ( $p \leq 0.05$ ) increase in colon length in contrast to the control-positive group. Chlorella vulgaris (300 mg/kg bw) without colitis induction caused no change in colon length compared with the control negative group. A significant ( $p \leq 0.05$ ) increase in colon length was detected in chlorella vulgaris (300mg /kg bw) in acetic acid-induced colitis or its combination with sulfasalazine groups compared with the control positive group.

### *Colon weight/length ratio*

The colon weight/length ratio in the control and different treated groups is recorded in Table. 5 and Fig. 3C. The weight/length ratio data reflected a significant ( $p \leq 0.05$ ) increase in the control-positive group compared with the control negative group. On the other hand, the sulfasalazine group revealed a significant ( $p \leq 0.05$ ) decrease in the weight/ length ratio of the colon in contrast to the control positive group. Chlorella vulgaris (300 mg /kg bw) without colitis induction caused no change in Colon weight/length ratio compared with the control negative group. Supplementation of chlorella vulgaris alone or in combination with sulfasalazine in acetic acid-induced colitis showed a significant ( $p \leq 0.05$ ) decrease in weight/length ratio of colon in comparison with the control positive group.

### *Haematological finding*

Data explored in Table .6 and Figure .4A-D show leukograms in the control and different treatment groups. Data demonstrated a considerable ( $P \leq 0.05$ ) rise in WBC, lymphocyte, monocyte, and granulocyte counts in the acetic acid-induced colitis

group compared with the control negative group. In contrast, the sulfasalazine group revealed a significant decline in WBC, lymphocyte, monocyte, and granulocyte counts compared with the control positive group. *Chlorella vulgaris* (300 mg/kg bw) without colitis induction caused no significant change in the leukogram compared with the control negative group. Supplementation of *Chlorella vulgaris* (300 mg /kg bw) in acetic acid-induced colitis caused significant ( $p \leq 0.05$ ) decrease in WBC, lymphocyte, monocyte, and granulocyte counts compared with the control positive group. In the same manner, *Chlorella vulgaris* (300mg /kg bw) along with sulfasalazine revealed significant ( $p \leq 0.05$ ) decrease in WBCs, lymphocytes, monocytes, and granulocytes count matched with the control positive group.

#### *Lipid peroxidation and antioxidant biomarkers*

Lipid peroxidation and antioxidant parameters in the control and different treated groups were portrayed in Table.7 and Figure.5A-D. The levels of MDA and NO were significantly elevated ( $p \leq 0.05$ ) in the colon tissue homogenate in the control positive group (A.A) compared with the control negative group. However, the colitis group showed a significant decline in GSH and CAT in comparison with the control negative group. In contrast, the sulfasalazine group revealed a significant ( $p \leq 0.05$ ) decrease in MDA and NO content and a significant increase in GSH and CAT in contrast with the control positive group. Regarding *Chlorella vulgaris* (300 mg/kg bw) supplementation in the colitis group induced by acetic acid, a significant ( $p \leq 0.05$ ) decline in colon tissue content of MDA and NO was observed compared with the control positive group. An increase in GSH and CAT was found in contrast with the control positive one. In a similar manner, the co-administration of *Chlorella vulgaris* (300mg /kg bw) with sulfasalazine resulted in a significant ( $p \leq 0.05$ ) decrease in MDA and NO in contrast with the control positive group. Conversely, noticeable improvements in GSH and CAT levels were observed compared with the positive control group.

#### *Histopathological findings*

Histopathological examination of the control intestinal mucosa showed normal characteristics, including a well-organised structure with columnar epithelial cells creating crypts and villi. The submucosa is devoid of inflammatory cell infiltration Figure 6A. Conversely, pathological lesions in the colon from rats subjected induced colitis by AA showed up significant inflammatory infiltration and destruction of the colonic mucosa, deep erosive lesions, widespread necrosis along the mucosa, and loss of epithelial integrity. Furthermore, submucosal oedema, haemorrhage, and inflammatory cell infiltration appeared to disturb normal tissue architecture Figure .6B.

Sulfasalazine treatment, on the other hand, resulted in moderate improvements in the therapy group (G3), as shown by a modest improvement in epithelial coverage integrity and crypt organisation. Nonetheless, there was less oedema in the submucosa, in addition to the persistence of inflammatory cell infiltration, especially in the mucosal layer, and slight superficial epithelial degeneration Figure.6C. The administration of *Chlorella vulgaris* to healthy animals showed normal general histological architecture of the mucosa and submucosa. However, there is a remarkable mononuclear cell infiltration in the lamina propria and slight goblet cell proliferation Figure.6D. In the same pattern, treating the rats with *Chlorella vulgaris* before inducing colitis led to mucosal protection, with markedly reduced acetic acid-induced destructive reaction in addition to clear expansion of goblet cell proliferation. Also, there is an inflammatory cell infiltration clearly observed in lamina propria Figure.6E. On the other hand, co-treatment involving the combination of *Chlorella vulgaris* and sulfasalazine showed normal histological features as observed in the non-treated control group without notable inflammatory reaction but with slight villi elongation, indicating a significant regenerative effect Figure.6F. These histological findings highlight the potential benefit of *Chlorella vulgaris* in mitigating the negative impacts of acetic acid-induced ulcerative colitis. Control of immune cell infiltration and restoration of colon tissue architecture are clear indications.

#### *Immunohistochemistry finding*

In the immunohistochemical analysis, the percentage of apoptotic cells exhibiting immune reactivity was most obvious in group 2 Figure.7B. This finding was notably distinct from the control group Figure.7A, which displayed the lowest level of caspase-3 enrichment. In group 5 (the diseased group pre-treated with *Chlorella vulgaris*, 300 mg/kg), there was only marginal improvement in the apoptosis percentage Figure.7E when compared with both the therapeutic group (group 3) and group 4 (Figure 7C and D), respectively. Corresponding to the H&E results, Group 6 (the diseased group that received co-treatment of *Chlorella vulgaris* at 300 mg/kg and sulfasalazine) displayed a low apoptotic percentage of T.7F, which closely resembled that of the control group. No significant differences were observed between the two groups.

#### *Molecular investigation*

Our findings revealed that administration of A.A altered the expression analysis of NF- $\kappa$ B (Nuclear factor kappa B) and IL10 (Interleukin 10) genes. NF- $\kappa$ B gene as a marker for colon inflammation was significantly upregulated ( $p \leq 0.05$ ), IL10 as an anti-inflammatory marker was decreased significantly ( $p \leq 0.05$ ) in the control-positive rats as compared

with the control negative group Table.9. while supplying chlorella vulgaris at a dose of (300 mg/kg b.w) in A.A-induced colitis group downregulated NF- $\kappa$ B gene and upregulated IL10 gene expression when compared with colitis animals as showed in Figure.8A&B. Co-administration of chlorella vulgaris (300mg /kg bw with sulfasalazine) resulted in a significant ( $p \leq 0.05$ ) decline in NF- $\kappa$ B gene expression and enhancement in IL10 gene expression.

### **Discussion**

Ulcerative colitis (UC) is a commonly prevalent inflammatory bowel disease (IBD) that significantly affects quality of life [38]. Although the development of UC involves numerous genetic and immunological factors, its precise cause remains the subject of ongoing research. The production of UC has been linked to multiple inflammatory mediators and reactive oxygen species [39;40]. The acetic acid (AA)-induced UC model is well researched and straightforward to implement in experiments [41].

The AA-induced colitis rat model is a thoroughly validated animal model that exhibits many characteristics common to human ulcerative colitis, including melena, colonic shortening, severe diarrhoea, bloody stools, mucosal ulcerations, inflammatory cell infiltration, and weight loss [42]. AA-induced colitis, which results from extensive intracellular acidification, leads to the degradation of mucosal barriers, damaging the colonic epithelium. This damage triggers the activation of cells that release inflammatory cytokines, including monocytes and macrophages [43]. This model displays inflammatory [44] and oxidative responses that imitate the pathogenesis of IBD in humans [45]. Consequently, AA-induced colitis could serve as an appropriate model for testing agents that may possess anti-inflammatory and antioxidant properties.

In this study, the intrarectal application of acetic acid notably decreased the body weight of rats. Weight loss in colitis stems from nutrient deficiencies owing to diminished appetite, aversion to food, or malabsorption, along with the quick loss of body fluids through colorectal bleeding and diarrhoea. Additionally, TNF- $\alpha$  and IL-6 significantly contribute to weight loss in colitis through the release of neuropeptides that suppress appetite and lead to cachexia [46].

A recent study demonstrated a significant rise in DAI and macroscopic damage in control-positive rats compared with normal-negative rats. This increase in DAI was attributed to severe ulceration and tissue necrosis accompanied by inflammatory infiltrates and goblet cell hyperplasia, as revealed by the findings of histopathological assessments. This was further corroborated at an increased mortality rate of 40%. Our results are in accordance with those of Ghazy, Mokhbatly et al. [47].

Meanwhile, the control positive rats exhibited a marked increase in colon weight with an obvious reduction in colon length compared with the normal negative rats. This may be attributed to the influx of neutrophils and macrophages to the injury site, leading to increased thickness of the colonic wall and a corresponding rise in colonic weight. At the same time, cell turgor, submucosal oedema, vascular dilatation, and goblet cell hyperplasia were observed, and these results parallel with Jaguar, Niphadkar et al. [48].

Haematological changes caused by tissue destruction are significant clinical symptoms of inflammatory bowel disorders. Thus, an examination of haematological parameters might be used to evaluate the degree of disease status of colitis. With regard to leukogram parameters (WBCs, absolute number of lymphocytes, Granulocytes and Monocytes), Our findings revealed a substantial rise in total WBC count and absolute count of lymphocytes, granulocytes, and monocytes in the acetic acid group compared with the control negative group. However, WBC values function as inflammatory indices in everyday clinical practise to determine UC. The larger number of WBCs in the acetic acid group may be due to the infiltration of inflammatory cells derived as lymphocytes and neutrophils because of the increase in inflammatory response during colitis in experimental rats [49; 50].

IBD is primarily caused by oxidative stress and a depleted free radical scavenging mechanism that regulates the production of ROS and iNOS [51]. The increase of both ROS and iNOS will result in reduced catalase and glutathione antioxidants, which activate the reactive oxygen metabolite cascade and lead to lipid peroxidation (LPO) [52]. Increased oxidative stress was observed in AA-induced UC rats, which was validated by elevated levels of lipid peroxidation, as indicated by increases in MDA and NO levels. NO is generated by iNOS and has been recognised as inflammatory mediator [53].

In a recent study, the control-positive animals exhibited a significant increase in MDA and NO; with marked inhibition in CAT and GSH compared with the control-negative group. These results are consistent with those obtained in [54; 55]. ROS and free radicals produced by migrating neutrophils attack cellular macromolecules, disrupting epithelial cells, and causing significant colon damage [56]. Furthermore, ROS cause extensive oxidation of cell membrane phospholipids, proteins, and DNA. Such oxidation creates additional stimulation of more neutrophils and macrophage infiltration into the injured tissue. As a result, the intestinal mucosa has complex enzymatic and non-enzymatic complex antioxidant defence mechanisms to regulate ROS levels. Inflamed colon tissues consume GSH and CAT to neutralise oxidative stress, resulting in a reduction in glutathione (GSH) and catalase (CAT)

levels, which attempt to heal and repair damaged cells.

ROS-induced lipid peroxidation produces malondialdehyde (MDA). Therefore, the higher MDA in acetic acid (4%) caused colitis in rats, leading to an increase in lipid peroxidation and significant cell damage [57]. Some inflammatory cells, such as granular leukocytes (neutrophils) or granular leukocytes (monocytes and macrophages), create nitric oxide (NO), as do epithelial cells from inflamed colon tissue in the extravascular compartment. As a result, higher NO content in experimental colitis is recognized as an indicator of inflammation [58;59].

In this study, *C. vulgaris* significantly inhibited MDA levels while increasing GSH levels and CAT activities in the colon, indicating that it has antioxidant capacity, which is key in its anti-inflammatory action. *Chlorella vulgaris* contains a plethora of antioxidants, including polyphenols, vitamin C, lutein, carotenoids, and tocopherol, in addition to protein, fat, minerals, and other vitamins [60;61,62]. *Chlorella vulgaris* decreases oxidative stress and scavenges ROS, both directly and indirectly, by boosting antioxidative pathways and enzymes [63].

AA administered intrarectally resulted in considerable histological changes such as colonic thickness, hyperaemia, inflammatory infiltration, and goblet cell hyperplasia. Other investigators reported similar findings [64,65] that confirm the present results. Macroscopic examination of the colon showed a considerable increase in the weight/length ratio of rats, which is the result of significant tissue oedema, necrosis, goblet cell hyperplasia, and inflammatory cell infiltration [66; 67]. The severity of colitis caused by AA in the colon was assessed in all rats. The primary characteristics of UC, including mucosal erosion, mucosal necrosis, ulceration, inflammation, and bleeding, were noted following the induction of UC compared with the normal control rats. *Chlorella vulgaris*, either alone or with Sulfasalazine, improved the AA-induced impairment, as demonstrated by a lower drop in body weight, colon weight ratio, DAI Score, ulceration, and improved mucosal content, as displayed in Figure 2. This resulted in significant protection. *C. vulgaris* may protect against UC by decreasing the release or synthesis of inflammatory mediators produced by AA or by increasing mucous content and inhibiting apoptotic damage. Polyphenols may have a mitigating effect on disorders linked to oxidative stress and inflammation [68;69,70].

Apoptosis is a programmed cell death process that occurs during the natural turnover of damaged cells. Apoptosis is also regarded as a component of a defence mechanism activated by tissue damage and immunological reactions induced by various disease

conditions [71]. Dysregulation of apoptosis is a critical factor in the pathogenesis of UC. Furthermore, immunohistochemical detection in the current study indicated high expression of caspase-3 (an apoptotic marker) in the A.A-treated group compared with the control animals. The AA-treated group demonstrated cell injury that caused DNA damage, resulting in the release of cytochrome c) pro-apoptotic proteins (from mitochondria into the cytoplasm and the activation of caspase-3 and apoptosis at the end stage. This is consistent with previous investigations [33]. *Chlorella vulgaris* has been employed as a protein source for humans and as an alternative to antibiotics in animal production [72]. The results of our investigation explain the influence of *Chlorella vulgaris* on the apoptotic state in UC. *Chlorella vulgaris* treatment resulted in a reduction in caspase-3 expression, showing that *Chlorella vulgaris* reduces colonic ulceration through suppression of apoptosis. This outcome is in agreement with [73] that tested the anti-apoptotic properties of *Chlorella vulgaris* in illness models. The transcription factor NF- $\kappa$ B (a marker for colon inflammation) is inactive when coupled with I $\kappa$ B (inhibitor of nuclear factor kappa B), and its activation depends on oxidative stress caused by free radicals [74]. The nucleus contains active NF- $\kappa$ B subunits that regulate inflammatory genes and play a significant role in the immunological process of IBD [75]. NF- $\kappa$ B increases oxidative stress and inflammatory cytokines, which can induce colonic epithelial damage and colitis [76]. The current study found that A.A treatment significantly increased NF- $\kappa$ B levels. These findings support previous research indicating that A.A positivity leads to increased NF- $\kappa$ B activation in a rat model of colitis [77;78].

Interleukin 10 (IL-10) is a powerful anti-inflammatory cytokine that plays a critical, and often essential, role in avoiding inflammatory and autoimmune diseases [79;80]. IL10 deficiency or abnormal expression can improve the inflammatory response to microbial challenge, but it can also play a role in the development of inflammatory bowel disease and a variety of autoimmune illnesses [81;82]. In an experimental colitis model in rats, AA significantly reduced IL-10 expression [83]. ROS and pro-inflammatory mediators participate in the onset of apoptosis [84]. The potential effect of *Chlorella vulgaris* in suppressing apoptosis could be connected to a reduction of lipid peroxidation and inflammation. Supplementation with *C. vulgaris* resulted in a marked decrease in NF- $\kappa$ B and an increase in IL10 expression compared with the control group. These results are in accordance with the results of Ran, Chen *et al.* [85]; zayat, Dehpour *et al.* [86]. Sibi and Rabina [87] demonstrated that treatment with *Chlorella vulgaris* extracts suppresses the inflammatory response by decreasing the production of NO, PGE<sub>2</sub>, TNF- $\alpha$  and IL-6 in LPS-activated RAW 264.7 cells *in vitro*. This postulates



that *C. vulgaris* may be a natural source of anti-inflammatory drugs due to its considerable anti-inflammatory activity. Significantly, the combination of *Chlorella vulgaris* and Sulphasalazine in acetic acid-induced colitis offered more protection and was more effective than using either substance alone. This was evidenced by the lowest mortality rate (0%), significant decrease in DAI, macroscopic damage, colon weight, colonic NO, MDA, NF- $\kappa$ B and Caspase-3 gene expression levels, and necrotic effects in colon tissues. The white blood cell count was also dramatically reduced following colitis induction. Body weight, colon length, GSH, Catalase, and IL10 gene expression levels all showed a significant rise. histopathological and immunohistochemistry findings were identical to the negative control group, owing to an improvement in growth performance and health condition [88]. *Chlorella vulgaris* not only modulates the inflammatory response of acetic acid-induced colitis but also has a major nutritional value because of its abundance of chlorophyll pigment and key amino acids essential for human growth and health. Furthermore, significant concentrations of calcium,

phosphorus, iodine, manganese, iron, and vitamins such as A, B1, B2, B3, B6, B12, C-67, and E were found [89].

### Conclusion

In conclusion, *Chlorella vulgaris* effectively treats acetic acid-induced ulcerative colitis in rats by reducing inflammation, oxidative stress, and apoptosis in colonic tissues. These results postulate that *chlorella vulgaris* may have an anti-ulcerative colitis impact in the treatment of UC.

### Funding statement

This work was funded by Kafrelsheikh University.

### Conflicts of interest

There are no conflicts to declare. The authors declared no competing interests.

### Acknowledgement

For the Kafrelsheikh University for financial support for this work.

**TABLE 1. Scoring of disease activity index (DAI).**

Score	Weight loss %	Stool consistency	Occult/gross bleeding
0	0	Normal	Normal
1	1-5%	-	-
2	5-10%	Loose stools	Occult blood
3	10-15%	-	-
4	> 20%	Diarrhea	Gross bleeding+ mucous

**TABLE 2. Criteria for scoring of gross morphologic damage of colon:**

Score	Appearance
0	Normal
1	Localized hyperemia, no ulcer
2	Ulceration without hyperemia
3	Ulceration with inflammation at one site
4	Two or more sites of discrete ulceration and inflammation

**TABLE 3. Primer sequences of the genes investigated by real-time RT-PCR Forward (F) and reverse primer (R) sequence of  $\beta$ -actin, NF $\kappa$ B and IL-10 and Gene bank accession numbers:**

Gene	Primer sequence (5'-3')	Accession No. References
Rat $\beta$ -actin	AGTGTGACGTTGACATCCGTA	NM_031144.3 (34)
	GCCAGAGCAGTAATCTCCTTCT	
Nuclear factor kappa B (NF $\kappa$ B)	TGGGACGACACCTCTACACA	XM_006233360.4 (35)
	GGAGCTCATCTCATAGTTGTCC	
Interleukin 10 (IL-10)	CTGGAGTGAAGACCAGCAAAGG	NM_012854 (36)
	GGAGAAATCGATGACAGCGTCG	

**TABLE 4. Mortality rate of control and different treated groups:**

	Total no	1 <sup>st</sup> day	2 <sup>nd</sup> day	3 <sup>rd</sup> day	4 <sup>th</sup> day	5 <sup>th</sup> day	6 <sup>th</sup> day	7 <sup>th</sup> day	Mort. rate %
Control negative	10	0	0	0	0	0	0	0	0
Control Positive (A.A)	10	2	1	0	1	0	0	0	40%
A.A + Sulphasalazine	10	1	0	0	0	0	0	0	10%
C.V (300mg /kg BW)	10	0	0	0	0	0	0	0	0
A.A + C.V (300mg/kgBW)	10	0	1	1	0	0	0	0	20%
A.A + Sulphasalazine+ C.V (300mg /kg BW)	10	0	0	0	0	0	0	0	0

Values are Means  $\pm$  standard error. Mean values with different letters at the same column differ significantly.

**TABLE 5. DAI and colon lesion parameters (mean  $\pm$  SE) in control and different treated groups.**

	DAI	Severity of Colitis	Colon weight (g)	Colon length (cm)	weight/length ratio
Control negative	0.0 $\pm$ 0.0 <sup>b</sup>	0.0 $\pm$ 0.0 <sup>d</sup>	0.82 $\pm$ 0.03 <sup>c</sup>	12.56 $\pm$ 0.16 <sup>a</sup>	0.07 $\pm$ 0.002 <sup>c</sup>
Control Positive (A.A)	2.51 $\pm$ 0.44 <sup>a</sup>	3.80 $\pm$ 0.20 <sup>a</sup>	1.7 $\pm$ 0.08 <sup>a</sup>	8.9 $\pm$ 0.33 <sup>c</sup>	0.19 $\pm$ 0.01 <sup>a</sup>
A.A + Sulphasalazine	0.97 $\pm$ 0.31 <sup>b</sup>	1.80 $\pm$ 0.20 <sup>bc</sup>	1.3 $\pm$ 0.09 <sup>b</sup>	11.00 $\pm$ 0.15 <sup>b</sup>	0.12 $\pm$ 0.006 <sup>b</sup>
C.V (300mg /kg BW)	0.00.0 <sup>b</sup>	0.0 $\pm$ 0.0 <sup>d</sup>	0.87 $\pm$ 0.05 <sup>c</sup>	12.60 $\pm$ 0.29 <sup>a</sup>	0.07 $\pm$ 0.004 <sup>c</sup>
A.A + C.V(300mg /kg BW)	1.18 $\pm$ 0.40 <sup>b</sup>	2.00 $\pm$ 0.31 <sup>b</sup>	1.24 $\pm$ 0.05 <sup>b</sup>	11.60 $\pm$ 0.18 <sup>ab</sup>	0.11 $\pm$ 0.004 <sup>b</sup>
A.A + Sulphasalazine + C.V(300mg /kg BW)	0.61 $\pm$ 0.26 <sup>b</sup>	0.80 $\pm$ 0.37 <sup>cd</sup>	0.96 $\pm$ 0.04 <sup>c</sup>	12.30 $\pm$ 0.20 <sup>a</sup>	0.08 $\pm$ 0.004 <sup>c</sup>

Values are Means  $\pm$  standard error. Mean values with different letters at the same column differ significantly, Disease Activity Index (DAI).

**TABLE 6. Leukogram (Mean  $\pm$  SEM) in control and different treated groups.**

	WBCs ( $10^3/\mu\text{l}$ )	Lymphocyte ( $\times 10^3/\mu\text{l}$ )	Granulocytes ( $\times 10^3/\mu\text{l}$ )	Monocytes ( $\times 10^3/\mu\text{l}$ )
Control negative	9.9 $\pm$ 0.12 <sup>c</sup>	7.60 $\pm$ 0.15 <sup>d</sup>	1.86 $\pm$ 0.12 <sup>c</sup>	0.30 $\pm$ 0.04 <sup>c</sup>
Control Positive (A.A)	36.2 $\pm$ 1.21 <sup>a</sup>	22.84 $\pm$ 0.85 <sup>a</sup>	10.90 $\pm$ 0.23 <sup>a</sup>	2.46 $\pm$ 0.21 <sup>a</sup>
A.A + Sulphasalazine	15.30 $\pm$ 0.15 <sup>b</sup>	11.14 $\pm$ 0.19 <sup>bc</sup>	3.38 $\pm$ 0.07 <sup>b</sup>	0.76 $\pm$ 0.02 <sup>b</sup>
C.V (300mg /kg BW)	10.82 $\pm$ 0.1 <sup>c</sup>	8.080 $\pm$ 0.13 <sup>d</sup>	2.16 $\pm$ 0.06 <sup>c</sup>	0.40 $\pm$ 0.04 <sup>bc</sup>
A.A + C.V (300mg /kg BW)	17.40 $\pm$ 0.9 <sup>b</sup>	12.50 $\pm$ 0.74 <sup>b</sup>	4.06 $\pm$ 0.04 <sup>bd</sup>	0.80 $\pm$ 0.05 <sup>b</sup>
A.A+ Sulphasalazine+ C.V (300mg /kg BW)	12.06 $\pm$ 0.17 <sup>c</sup>	9.10 $\pm$ 0.17 <sup>cd</sup>	2.46 $\pm$ 0.11 <sup>cd</sup>	0.48 $\pm$ 0.037 <sup>bc</sup>

Values are Means  $\pm$  standard error. (n=9) Mean values with different letters at the same column differ significantly at (p  $\leq$  0.05). White blood cells (WBCs).

**TABLE 7. Lipid peroxidation and antioxidant parameters (Mean± SEM) in control and different treated groups.**

	MDA (nmol/g.tissue)	NO (µmol/g.tissue)	Catalase (U/g.tissue)	GSH (mg/g.tissue)
Control negative	20.10±0.87 <sup>c</sup>	9.90±0.38 <sup>cd</sup>	16.66±0.46 <sup>bc</sup>	47.50±0.97 <sup>ab</sup>
Control Positive (A.A)	43.26±1.61 <sup>a</sup>	29.72±1.80 <sup>a</sup>	8.88±0.55 <sup>d</sup>	20.70±1.35 <sup>d</sup>
A.A + Sulphasalazine	33.52±1.38 <sup>b</sup>	17.64±0.64 <sup>b</sup>	11.78±0.31 <sup>c</sup>	34.24±0.79 <sup>c</sup>
C.V (300mg /kg BW)	20.48±0.53 <sup>c</sup>	9.20±0.22 <sup>d</sup>	18.44±0.58 <sup>ae</sup>	50.52±1.68 <sup>a</sup>
A.A + C.V (300mg /kg BW)	29.24±0.67 <sup>b</sup>	20.20±0.48 <sup>b</sup>	12.52±0.33 <sup>c</sup>	38.40±0.50 <sup>c</sup>
A.A +Sulphasalazine+ C.V (300mg /kg BW)	23.10±0.35 <sup>c</sup>	13.28±0.43 <sup>c</sup>	14.74±0.40 <sup>b</sup>	44.80±1.39 <sup>b</sup>

Values are Means ± standard error. Mean values with different letters at the same column differ significantly. Malondialdehyde (MDA), nitric oxide (NO), reduced glutathione (GSH).

**TABLE 8. Inflammatory and degenerative changes count for H&E in control and different treated groups.**

	Mucosal ulceration	Mucosal necrosis	Hemorrhage	Edema	Inflammation
Control negative	-	-	-	-	-
Control Positive (A.A)	+++	+++	++	+++	+++
A.A + Sulphasalazine	-	+	-	-	++
C.V(300mg /kg BW)	-	-	-	-	+
A.A + C.V (300mg /kg BW)	-	+	-	-	+
A.A +Sulphasalazine+ C.V (300mg /kg BW)	-	-	-	-	+

Score of lesions; (- negative; + = mild; ++ = moderate; +++ = severe).

**TABLE 9. NFκB and IL10 gene expression in control and different treated groups.**

	NFKB	IL10
Control negative	1±0 <sup>c</sup>	1±0 <sup>a</sup>
Control Positive (A.A)	11.73±0.67 <sup>a</sup>	0.21±0.02 <sup>c</sup>
A.A + Sulphasalazine	4.44±0.41 <sup>b</sup>	0.67±0.04 <sup>b</sup>
C.V (300mg /kg BW)	1 ± 0 <sup>c</sup>	1 ± 0 <sup>a</sup>
A.A + C.V (300mg /kg BW)	4.82±0.29 <sup>b</sup>	0.71±0.01 <sup>b</sup>
A.A +Sulphasalazine+ C.V (300mg /kg BW)	1.79±0.21 <sup>c</sup>	0.90±0.03 <sup>a</sup>

Values are Means ± standard error. Mean values with different letters at the same column differ significantly. Nuclear factor kappa B (NFKB), and Interleukin 10 (IL10).

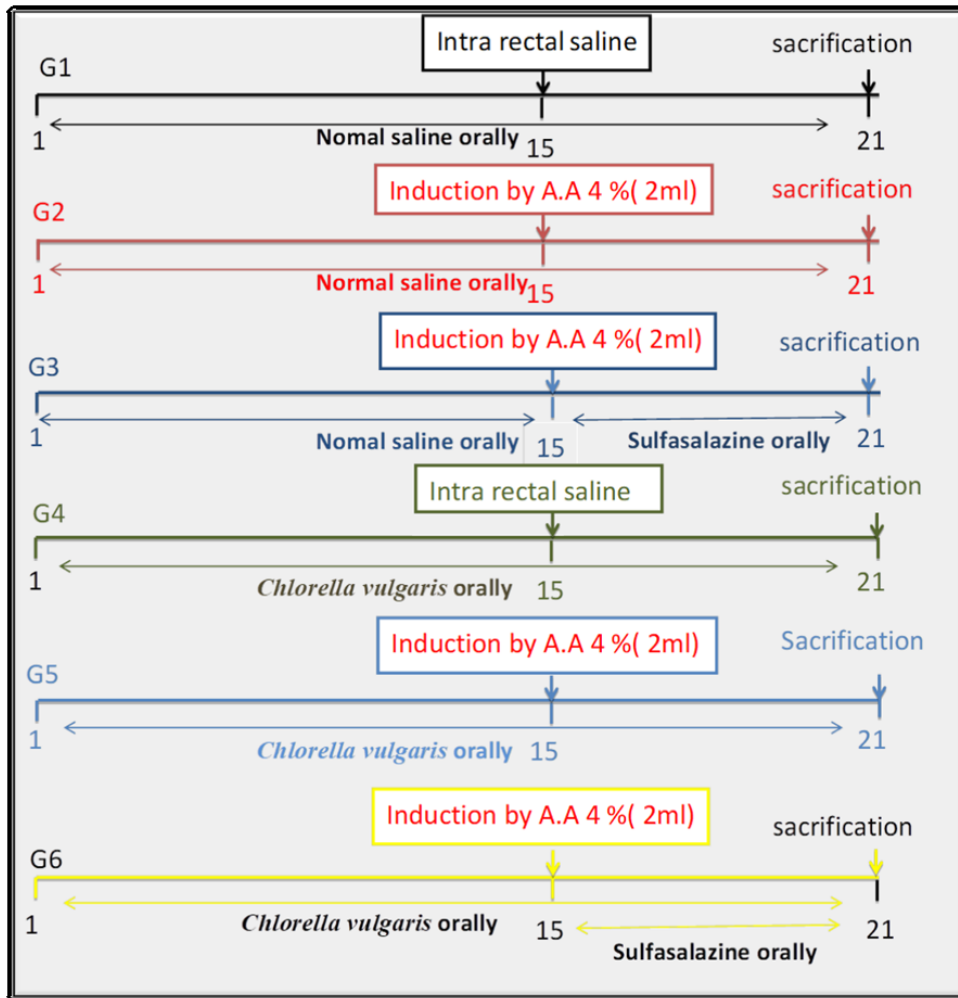


Fig.1. Experimental design.

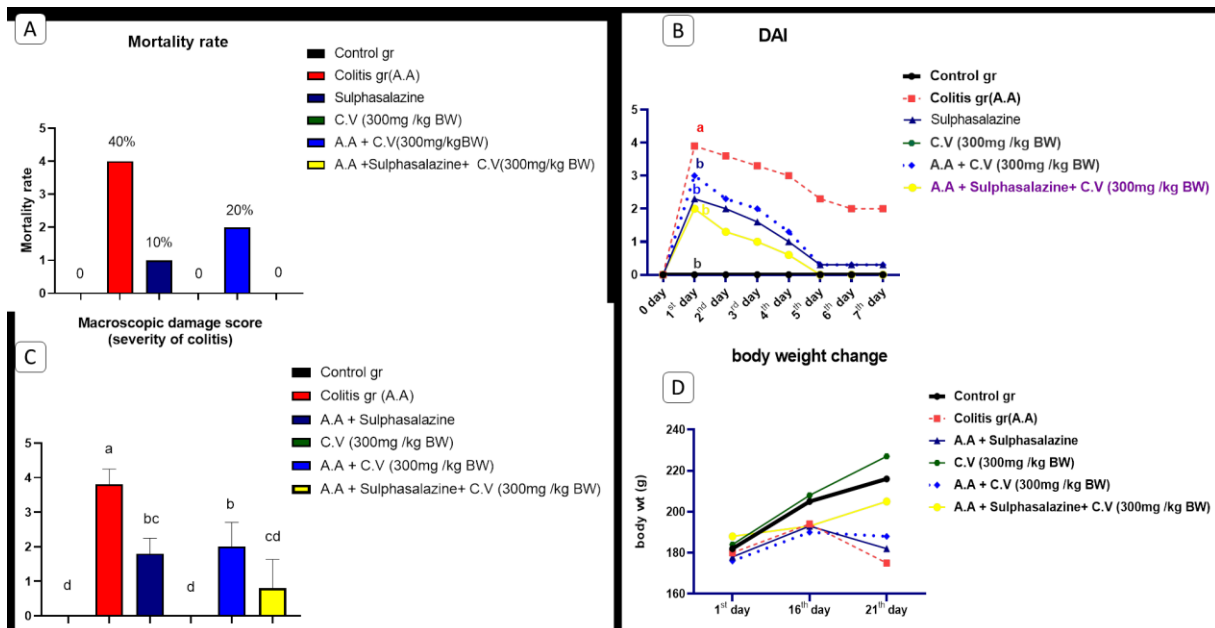


Fig. 2. A) Mortality rate in control and different treated groups, B) Disease Activity Index (DAI) in control and different treated groups, C) Macroscopic damage score in control and different treated groups, D) Body weight change in control and different treated groups.

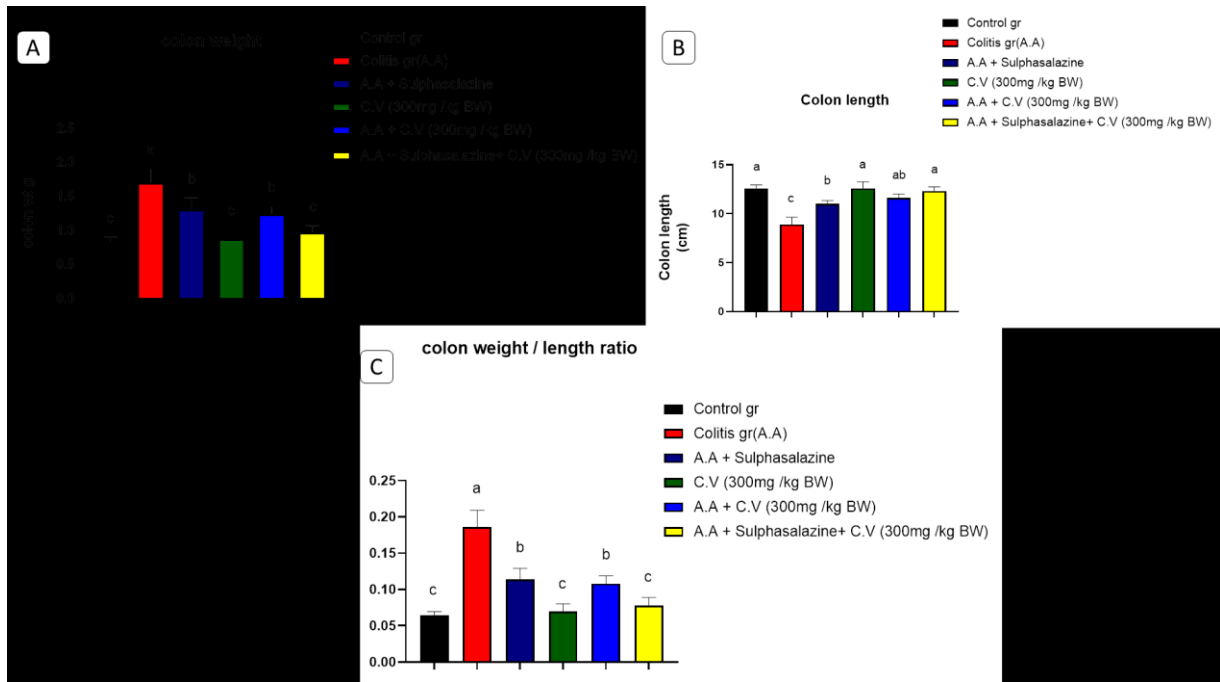


Fig. 3. A) Colon weight in control and different treated groups, B) Colon length in control and different treated groups, C) Colon weight/ length ratio in control and different treated groups,


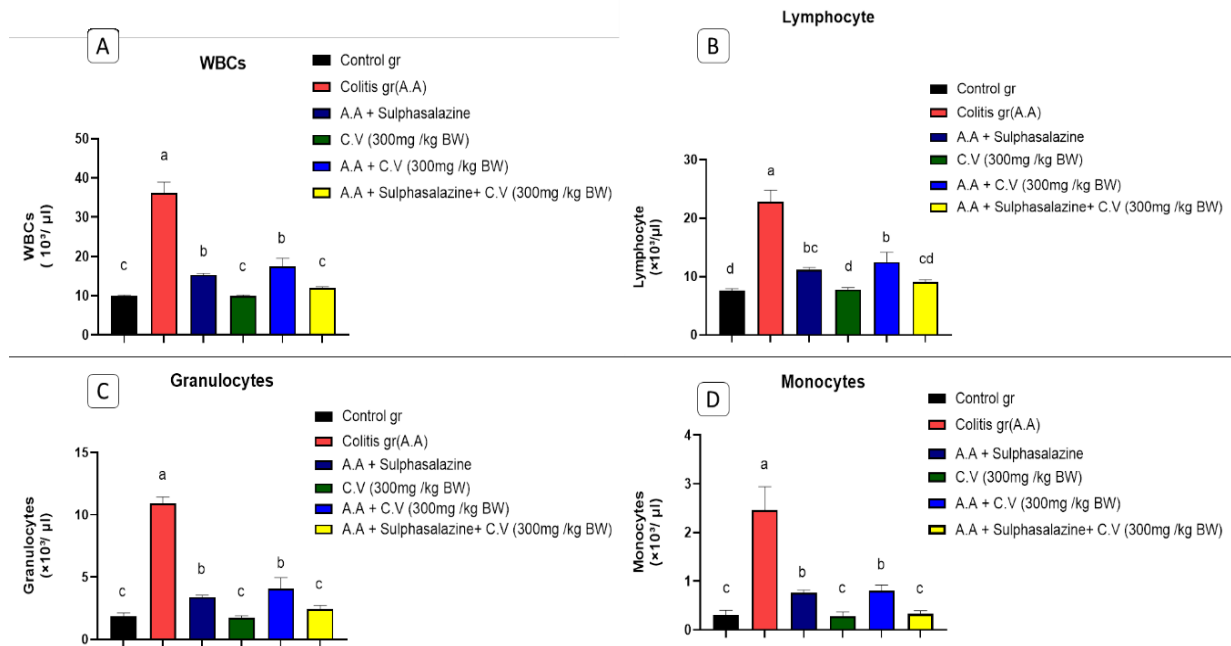
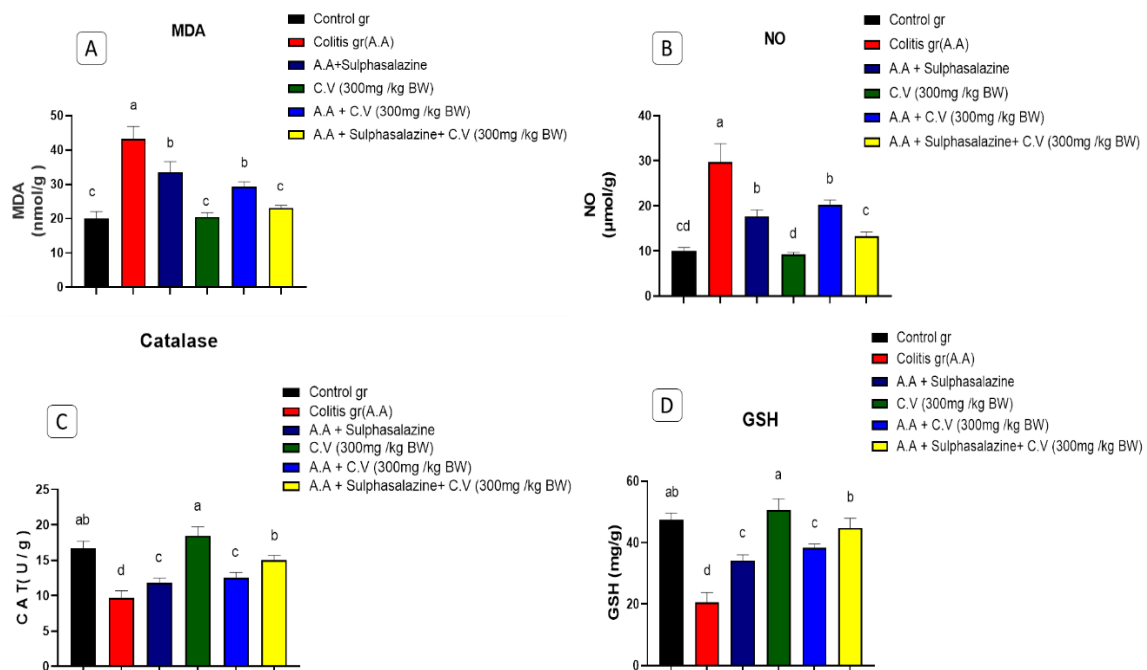


Photo 1. Severity of colitis in control and different treated groups. Photo 2: Colon length in control and different treated groups. G1: Control negative G2: Control Positive (A.A) G3: A.A + Sulphasalazine , G4: C.V (300mg /kg BW) G5: A.A + C.V (300mg /kg BW) G6: A.A+ Sulphasalazine + C.V (300mg /kg BW)



**Fig. 4.** A) WBCs count  $10^3/\mu\text{l}$  in control and different treated groups, B) Lymphocytes  $10^3/\mu\text{l}$  in control and different treated groups, C) Granulocytes  $10^3/\mu\text{l}$  in control and different treated groups, D) Monocytes  $10^3/\mu\text{l}$  in control and different treated groups.



**Fig. 5.** A) MDA (nmol/g) in control and different treated groups, B) Nitric acid ( $\mu\text{mol/g}$ .tissue) in control and different treated groups, C) CAT (U/g) in control and different treated groups, D) GSH (mg/g) in control and different treated groups.

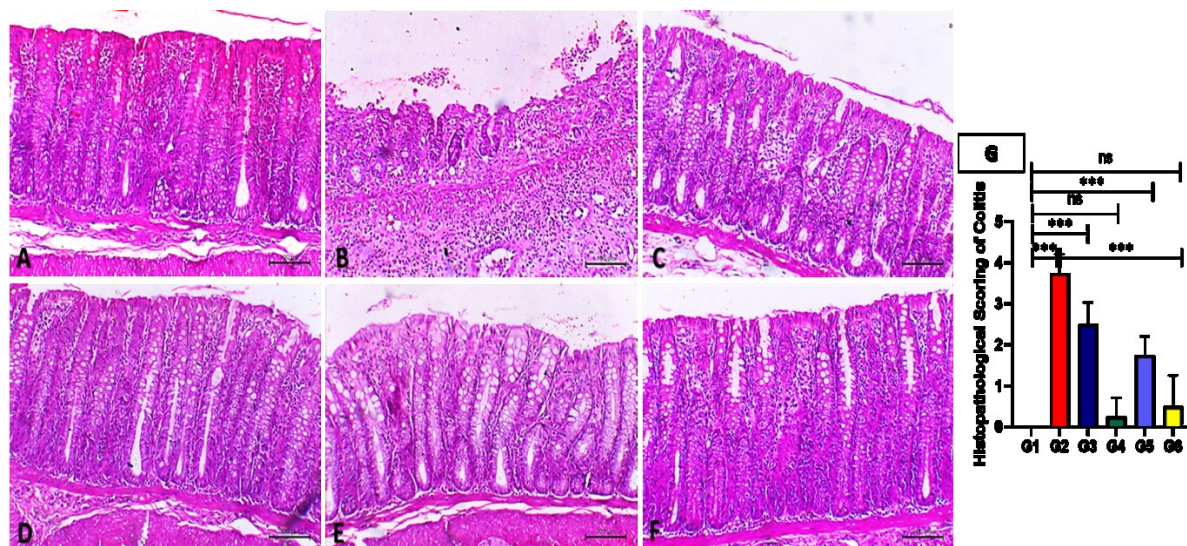


Fig. 6. (A, B, C, D, E and F): demonstrates colon sections stained with H&E showing the effect of chlorella vulgaris and sulfasalazine on acetic acid-induced ulcerative colitis. Colonic sections from control group (16A) illustrate normal mucosa including surface epithelium and crypts. Colonic sections from the acetic acid-induced colitis group (16B) showing marked necrosis of the mucosal lining with oedema of submucosa and marked inflammatory cells infiltration. Sections from the therapeutic sulfasalazine-treated group (16C) showing moderate inflammatory cell infiltration and mild superficial epithelial necrosis. Colonic section from normal group treated with chlorella vulgaris (16D) showing mononuclear cell infiltration in lamina propria and slight increase of goblet cells. Colonic section from colitis group pre-treated with chlorella vulgaris (16E) showing marked reduction in inflammatory cell infiltration except for some infiltration in lamina propria and evident expansion of goblet cell proliferation. Colonic section from colitis group pre-treated with chlorella vulgaris & post treated with sulfasalazine (16F) resembled the histological features observed in the non-treated control group. H&E, bar = 100  $\mu$ m. (16G) Scoring of colitis. \*\*\*,  $P < 0.001$ ; ns= not significant on Student's t test.

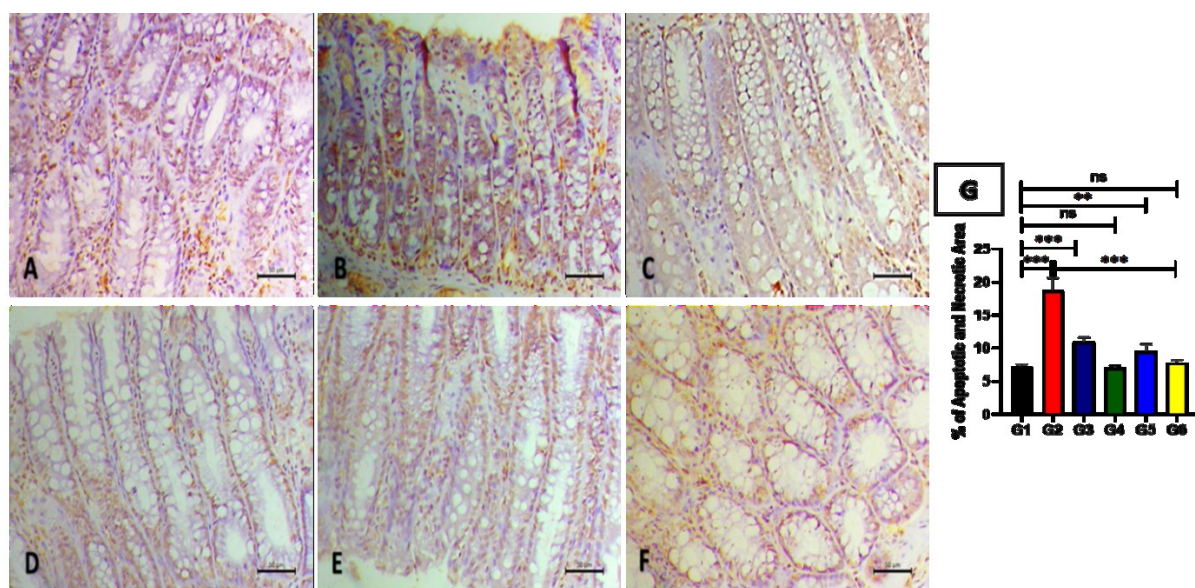
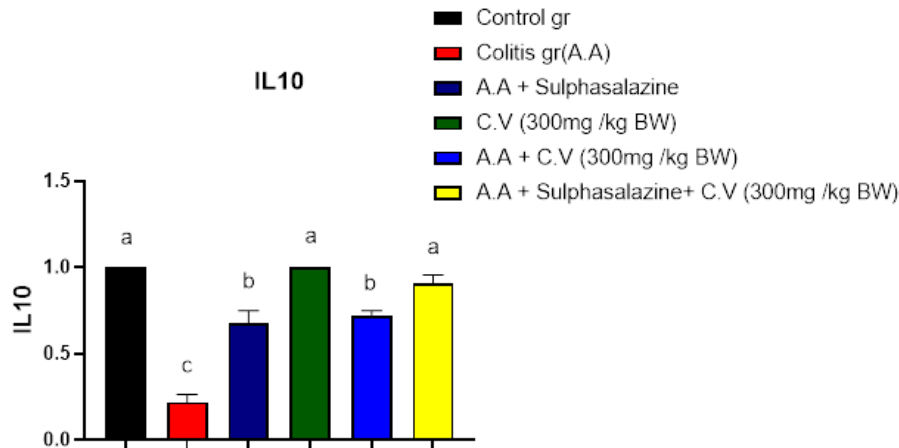


Fig. 7. In the immunohistochemical analysis, the percentage of apoptotic cells exhibiting immune reactivity was most obvious in group1 (Fig. 7B). This finding was notably distinct from the control group (Fig.7A), which displayed the lowest level of caspase 3 enrichment. In group 5 (the diseased group pre-treated with chlorella vulgaris, 300 mg/kg), there was only marginal improvement in the apoptosis percentage (Fig.7E) when compared to both the therapeutic group (group 3) and group 4 (Fig. 7C & 7D, respectively). Corresponding to the H&E results, Group 6 (the diseased group that received co-treatment of *C. vulgaris* at 300 mg/kg and sulfasalazine) displayed a low apoptotic percentage (Fig. 7F), which closely resembled that of the control group. There was no significant difference between these two groups.



**Fig. 8.** Level of relative expression of IL10/B actin gene in control and different treated groups.

### References

- Thippeswamy, B. S., Mahendran, S., Biradar, M. I., Raj, P., Srivastava, K., Badami, S. and Veerapur, V. P. Protective effect of embelin against acetic acid induced ulcerative colitis in rats. *European Journal of Pharmacology*, **654**(1), 100–105 (2011). <https://doi.org/10.1016/j.ejphar.2010.12.012>
- El-Azab, N. E.-E., Salem, M. Y. and Elsalam, S.A. A histological and immunohistochemical study of different therapeutic modalities for experimentally induced ulcerative colitis in rats. *The Egyptian Journal of Histology*, **39**(1), 12-24. (2016).
- Karlinger, K., Györke, T., Makö, E., Mester, A. and Tarján, Z. The epidemiology and the pathogenesis of inflammatory bowel disease. *European Journal of Radiology*, **35**(3), 154–167(2000). [https://doi.org/10.1016/s0720-048x\(00\)00238-2](https://doi.org/10.1016/s0720-048x(00)00238-2)
- Aleman-Cosme, E., Sáez-González, E., Moret, I., Mateos, B., Iborra, M., Nos, P., Sandoval, J. and Beltrán, B. Oxidative Stress in the Pathogenesis of Crohn's Disease and the Interconnection with Immunological Response, Microbiota, External Environmental Factors, and Epigenetics. *Antioxidants* (Basel, Switzerland), **10**(1), 64(2021). <https://doi.org/10.3390/antiox10010064>
- Gyuraszova, M., Kovalcikova, A. and Gardlik, R. Association between oxidative status and the composition of intestinal microbiota along the gastrointestinal tract. *Medical Hypotheses*, **103**, 81–85(2017). <https://doi.org/10.1016/j.mehy.2017.04.011>.
- Bourgonje, A. R., Feelisch, M., Faber, K. N., Pasch, A., Dijkstra, G. and van Goor, H. Oxidative Stress and Redox-Modulating Therapeutics in Inflammatory Bowel Disease. *Trends in molecular medicine*, **26**(11), 1034–1046. (2020). <https://doi.org/10.1016/j.molmed.2020.06.006>
- Zenlea, T. and Peppercorn, M. A. Immunosuppressive therapies for inflammatory bowel disease. *World Journal of Gastroenterology*, **20**(12), 3146–3152 (2014). <https://doi.org/10.3748/wjg.v20.i12.3146>
- Siegel C. A. Review article: explaining risks of inflammatory bowel disease therapy to patients. *Alimentary Pharmacology & Therapeutics*, **33**(1), 23–32. (2011). <https://doi.org/10.1111/j.1365-2036.2010.04489.x>
- Deng, R. and Chow, T.J. Hypolipidemic, antioxidant, and anti-inflammatory activities of microalgae *Spirulina*. *Cardiovasc Ther.*, **28**, e33–45(2010);
- Jung, H.A., Jin, S.E., Ahn, B.R, Lee, C.M. and Choi, J.S. Anti-inflammatory activity of edible brown alga *Eisenia bicyclis* and its constituents fucosterol and phlorotannins in LPS-stimulated RAW264.7 macrophages. *Food Chem. Toxicol.*, **59**, 199 (2013).
- Panahi, Y., Darvishi, B., Jowzi, N., Beiraghdar, F. and Sahebkar, A. *Chlorella vulgaris*: A Multifunctional Dietary Supplement with Diverse Medicinal Properties. *Current Pharmaceutical Design*, **22**(2), 164–173 (2016). <https://doi.org/10.2174/1381612822666151112145226>
- Bauer, L.M., Vieira Costa, J.A., Conteno da Rosa, A.P. and Santos, L.O. Growth stimulation and synthesis of lipids, pigments and antioxidants with magnetic fields in *Chlorella kessleri* cultivations. *Bioresour. Technol.*, **244**, 1425–1432 (2017).
- Sikiru, A.B., Arangasamy, A., Alemmede, I.C., Egena, S.S.A. and Bhatta, R. Dietary supplementation effects of *Chlorella vulgaris* on performances, oxidative stress status and antioxidant enzymes activities of prepubertal New Zealand White rabbits. *Bull. Natl. Res. Cent.*, **43** (1), 162(2019).
- Abd El Latif, A., Assar, D.H., Elkaw, E.M., Hamza, H.A., Alkhalifah, D.H.M., Hozzein, W.N. and Hamouda, R.A. Protective role of *Chlorella vulgaris* with Thiamine against Paracetamol induced toxic effects on haematological, biochemical, oxidative stress parameters and histopathological changes in Wistar rats. *Sci. Rep.*, **11**(1), 3911(2021). <https://doi.org/10.1038/s41598-021-83316-8>.



15. Mokhbatly, A.A., Ghazy, E.G., Abdelhady, D.H., Abdo, W. and Abdelwahab, M. Ameliorative effect of *Spirulina platensis* against diclofenac sodium-induced hepatotoxicity in broilers: hematological, biochemical, antioxidant, immunological and Histopathological study. *Assiut Vet. Med. J.*, **64** (156), 164-177 (2018).
16. Elbially, Z.I., Assar, D.H., Abdelnaby, A., Abu Asa, S., Abdelhice, E.H., Ibrahim, S.S., Abdel-Daim, M.M., Almeer, R. and Atiba, A. Healing potential of *Spirulina platensis* for skin wounds by modulating bFGF, VEGF, TGF- $\beta$ 1 and  $\alpha$ -SMA genes expression targeting angiogenesis and scar tissue formation in the rat model. *Biomedicine and Pharmacotherapy*, **137**, 111349 (2021).
17. Abd El-Hack, M.E., Abdelnour, S., Abdo, M., Sakr, M.A., Khafaga, A.F., Mahgoub, S.A., Elnesr, S.S., Gebriel, M.G. Microalgae in modern cancer therapy: Current knowledge. *Biomed. Pharmacother.*, **111**, 42–50 (2019).
18. Barkia, I., Saari, N. and Manning, S.R. Microalgae for high-value products towards human health and nutrition. *Marine Drugs*, **17**, 304 (2019). <https://doi.org/10.3390/md17050304>
19. Barbosa Bezerra, G., de Menezes de Souza, L., Dos Santos, A. S., de Almeida, G. K., Souza, M. T., Santos, S. L., Aparecido Camargo, E., Dos Santos Lima, B., de Souza Araújo, A. A., Cardoso, J. C., Gomes, S. V., Gomes, M. Z. and de Albuquerque, R. L., Júnior. Hydroalcoholic extract of Brazilian red propolis exerts protective effects on acetic acid-induced ulcerative colitis in a rodent model. *Biomedicine and Pharmacotherapy*, **85**, 687–696(2017). <https://doi.org/10.1016/j.biopha.2016.11.080>
20. Adriana Estrella, G. R., María Eva, G. T., Alberto, H. L., María Guadalupe, V. D., Azucena, C. V., Sandra, O. S., Noé, A. V. and Francisco Javier, L. M. Limonene from *Agastache mexicana* essential oil produces antinociceptive effects, gastrointestinal protection and improves experimental ulcerative colitis. *Journal of Ethnopharmacology*, **280**, 114462. (2021). <https://doi.org/10.1016/j.jep.2021.114462>
21. Fattahian, E., Hajhashemi, V., Rabbani, M., Minaïyan, M. and Mahzouni, P. Anti-inflammatory Effect of Amitriptyline on Ulcerative Colitis in Normal and Reserpine-Induced Depressed Rats. *Iranian Journal of Pharmaceutical Research : IJPR*, **15** (Suppl), 125–137(2016).
22. Fan, L.-H., Zhang, Y.-T., Cheng, L.-H., Zhang, L., Tang, D.-S. and Chen, H.-L. Optimization of Carbon Dioxide Fixation by *Chlorella vulgaris* Cultivated in a Membrane-Photobioreactor”, *Chem. Eng. Technol.*, **30**, 1094 – 1099 (2007). DOI: 10.1002/ceat.200700141
23. Zainul Azlan, N., Mohd Yusof, Y. A. and Makpol, S. *Chlorella vulgaris* Ameliorates Oxidative Stress and Improves the Muscle Regenerative Capacity of Young and Old Sprague-Dawley Rats. *Nutrients*, **12**(12), 3752(2020). <https://doi.org/10.3390/nu12123752>
24. He, Z., Zhou, Q., Wen, K., Wu, B., Sun, X., Wang, X. and Chen, Y. Huangkui Lianchang Decoction Ameliorates DSS-Induced Ulcerative Colitis in Mice by Inhibiting the NF-kappaB Signaling Pathway. *Evidence-based Complementary and Alternative Medicine : eCAM.*, 1040847(2019). <https://doi.org/10.1155/2019/1040847>
25. Motta, J. P., Flannigan, K. L., Agbor, T. A., Beatty, J. K., Blackler, R. W., Workentine, M. L., Da Silva, G. J., Wang, R., Buret, A. G. and Wallace, J. L. Hydrogen sulfide protects from colitis and restores intestinal microbiota biofilm and mucus production. *Inflammatory Bowel Diseases*, **21**(5), 1006–1017(2015). <https://doi.org/10.1097/MIB.0000000000000345>
26. Schalm, S. W., Heytink, R. A., Van Buuren, H. R. and De Man, R. A. Acyclovir, oral, intravenous and combined with interferon for chronic HBsAg-positive hepatitis. *Journal of Hepatology*, **3** Suppl 2, S137–S141(1986). [https://doi.org/10.1016/s0168-8278\(86\)80112-x](https://doi.org/10.1016/s0168-8278(86)80112-x)
27. Dewi, D. C. and A. J. F. M. I. Durachim. Analysis of Blood Sample Lysis Rate on Hemoglobin Examination Results Using Rayto RT. 7600 Auto Hematology Analyzer. *Folia Medica Indonesiana*, **50** (4), 262-264 (2014).
28. Ohkawa, H., Ohishi, N. and Yagi, K. Assay for lipid peroxides in animal tissues by thiobarbituric acid reaction. *Analytical Biochemistry*, **95**(2), 351–358 (1979). [https://doi.org/10.1016/0003-2697\(79\)90738-3](https://doi.org/10.1016/0003-2697(79)90738-3)
29. Ingram, G. J. A. Combustion of organic compounds by ignition in oxygen-determination of carbon and hydrogen, ROYAL SOC CHEMISTRY THOMAS GRAHAM HOUSE, SCIENCE PARK, MILTON RD, CAMBRIDGE, **86**, 411(1961).
30. Aebi, H. Catalase in vitro. *Methods in Enzymology*, Elsevier. **105**, 121-126 (1984).
31. OWENS, C. W., & BELCHER, R. V. A COLORIMETRIC MICRO-METHOD FOR THE DETERMINATION OF GLUTATHIONE. *The Biochemical journal*, **94**(3), 705–711. (1965). <https://doi.org/10.1042/bj0940705>
32. McDonald, J. and Pilgram, T. Nuclear expression of p53, p21 and cyclin D1 is increased in bronchioloalveolar carcinoma. *Histopathology*, **34**(5), 439-446 (1999).
33. Ali, A. A., Abd Al Haleem, E. N., Khaleel, S. A. and Sallam, A. S. Protective effect of cardamonin against acetic acid-induced ulcerative colitis in rats. *Pharmacological Reports, PR*, **69**(2), 268–275(2017). <https://doi.org/10.1016/j.pharep.2016.11.002>
34. Wen, Z. S., Du, M., Tang, Z., Zhou, T. Y., Zhang, Z. S., Song, H. H., Xiang, X. W. and Han, X. Y. Low Molecular Seleno-Aminopolysaccharides Protect the Intestinal Mucosal Barrier of Rats under Weaning Stress. *International Journal of Molecular Sciences*, **20**(22), 5727 (2019). <https://doi.org/10.3390/ijms20225727>

35. Kamel, E. O., Hassanein, E. H. M., Ahmed, M. A. and Ali, F. E. M. Perindopril Ameliorates Hepatic Ischemia Reperfusion Injury Via Regulation of NF- $\kappa$ B-p65/TLR-4, JAK1/STAT-3, Nrf-2, and PI3K/Akt/mTOR Signaling Pathways. *Anatomical Record (Hoboken, N.J. : 2007)*, **303**(7), 1935–1949 (2020). <https://doi.org/10.1002/ar.24292>
36. Mueller, K., Blum, N. M. and Mueller, A. S. Examination of the Anti-Inflammatory, Antioxidant, and Xenobiotic-Inducing Potential of Broccoli Extract and Various Essential Oils during a Mild DSS-Induced Colitis in Rats. *ISRN Gastroenterology*, **710856** (2013). <https://doi.org/10.1155/2013/710856>
37. Zhang, L., Shi, Y., Yan, M. and Zhang, G. Modulatory action of withaferin-A on oxidative damage through regulation of inflammatory mediators and apoptosis via PI3K/AKT signaling pathway in high cholesterol-induced atherosclerosis in experimental rats. *Journal of Biochemical and Molecular Toxicology*, **36**(10), e23154(2022). <https://doi.org/10.1002/jbt.23154>
38. Gajendran, M., Loganathan, P., Jimenez, G., Catinella, A. P., Ng, N., Umaphathy, C., Ziade, N. and Hashash, J. G. A comprehensive review and update on ulcerative colitis. *Disease-a-month: DM*, **65**(12), 100851(2019). <https://doi.org/10.1016/j.disamonth.2019.02.004>
39. Arafa, E.A., Mohamed, W.R., Zaher, D.M. and Omar H.A.. Gliclazide attenuates acetic acid-induced colitis via the modulation of PPAR $\gamma$ , NF- $\kappa$ B and MAPK signaling pathways, *Toxicology and Applied Pharmacology*, **391**, 114919(2020).
40. Oliveira, R.G., Damazo, A.S., Antonielli, L.F., Miyajima, F., Pavan, E., Duckworth, C.A. Lima, J., Arunachalam, K. and Martins, D.T.O. Dilodendron bipinnatum Radlk extract alleviates ulcerative colitis induced by TNBS in rats by reducing inflammatory cell infiltration, TNF- $\alpha$  and IL-1 $\beta$  concentrations, IL-17 and COX-2 expressions, supporting mucus production and promotes an antioxidant effect, *Journal of Ethnopharmacology*, **269**, 113735(2021)
41. Rashidian P. Dejbani, Karami Fard K., Abdollahi, A., Chamanara, M., Dehpour, A., Hasanvand, A. Bupropion Ameliorates Acetic Acid-Induced Colitis in Rat: the Involvement of the TLR4/NF- $\kappa$ B Signaling Pathway. *Inflammation*, **43**, 1999-2009 (2020)
42. Elson, C.O.; Sartor, R.B.; Tennyson, G.S. and Riddell, R.H. Experimental models of inflammatory bowel disease. *Gastroenterology*, **109**, 1344–1367(1995).
43. Shahid, M.; Raish, M.; Ahmad, A.; Bin Jordan, Y.A.; Ansari, M.A.; Ahad, A.; Alkharfy, K.M.; Alaoifi, A.L. and Al-Jenoobi, F.I. Sinapic Acid Ameliorates Acetic Acid-Induced Ulcerative Colitis in Rats by Suppressing Inflammation, Oxidative Stress, and Apoptosis. *Molecules*, **27**, 4139 (2022). <https://doi.org/10.3390/molecules27134139>
44. Wu, C.C. Tung, Y.T., Chen, S.Y., Lee, W.T., Lin, H.T. and Yen, G.C.. Anti-Inflammatory, Antioxidant, and Microbiota-Modulating Effects of Camellia Oil from *Camellia brevistyla* on Acetic Acid-Induced Colitis in Rats, *Antioxidants* (Basel, Switzerland), **9** (1),58 (2020).
45. Esiringü, F., Fatmanur T., Füsün, A., Şule, C. C., Filiz, B., Seda, M. and Sari, K. Investigation of the effect of intra-colonic melatonin gel formulation on acetic acid-induced colitis. *Drug Deliv.*, **7**,2318-2326 (2016).
46. Hunschede, S., Kubant, R., Akilen, R., Thomas, S. and Anderson, G. H. Decreased appetite after high-intensity exercise correlates with increased plasma interleukin-6 in normal weight and overweight/obese boys. *Current Developments in Nutrition*, **1**(3), e000398 (2017).
47. Ghazy, E. W., Mokhbatly, A.-A., Keniber, S.S. and Shoghy, K.M. "SYNERGISTIC AMELIORATIVE EFFECT OF Lactobacillus AND Spirulina platensis AGAINST EXPERIMENTAL COLITIS IN ALBINORATS: ANTIOXIDANT, HISTOPATHOLOGICAL AND MOLECULAR STUDIES." *Slov. Vet. Res.*, **56** (Suppl 22), 553–569(2019). DOI 10.26873/SVR-793-2019
48. Jagtap, A. G., Niphadkar, P. V. and Phadke, A. S. Protective effect of aqueous extract of *Bombax malabaricum* DC on experimental models of inflammatory bowel disease in rats and mice. *Indian Journal of Experimental Biology*, **49**(5), 343–351 (2011).
49. González, M. A., Gonzalez-Rey, E., Rico, L., Büscher, D. and Delgado, M. Adipose-derived mesenchymal stem cells alleviate experimental colitis by inhibiting inflammatory and autoimmune responses. *Gastroenterology*, **136**(3), 978–989. (2009). <https://doi.org/10.1053/j.gastro.2008.11.041>
50. Parihar, N. and Bhatt, L. K. Topotecan alleviates acetic acid-induced ulcerative colitis in rats via attenuation of the ROR $\gamma$ T transcription factor. *Life Sciences*, **328**, 121915 (2023). <https://doi.org/10.1016/j.lfs.2023.121915>
51. Bhattacharyya, A.; Chattopadhyay, R.; Mitra, S. and Crowe, S.E. Oxidative stress: An essential factor in the pathogenesis of gastrointestinal mucosal diseases. *Physiol. Rev.*, **94**, 329–354(2014).
52. Baumgart, D. C. and Sandborn, W. J. Inflammatory bowel disease: clinical aspects and established and evolving therapies. *Lancet (London, England)*, **369**(9573), 1641–1657 (2007). [https://doi.org/10.1016/S0140-6736\(07\)60751-X](https://doi.org/10.1016/S0140-6736(07)60751-X)
53. de las Heras, B., Abad, M. J., Silván, A. M., Pascual, R., Bermejo, P., Rodríguez, B. and Villar, A. M. Effects of six diterpenes on macrophage eicosanoid biosynthesis. *Life Sciences*, **70**(3), 269–278(2001). [https://doi.org/10.1016/s0024-3205\(01\)01402-3](https://doi.org/10.1016/s0024-3205(01)01402-3)
54. Baumgart, D. C. and Sandborn, W. J. J. Inflammatory bowel disease: clinical aspects and established and evolving therapies. *Lancet*, **369**(9573), 1641-1657 (2007).
55. Mokh, A., Abdelhady, D., Ghazy, E., Aboumosalem, H. and Goda, W. Sesame oil mitigates initiation stage of diethylnitrosamine hepatocarcinogenesis in rats. *Slovenian Veterinary Research*, **56**(22), 487-498(2019).

56. Helal, M. G. and Abd Elhameed, A. G. Graviola mitigates acetic acid-induced ulcerative colitis in rats: insight on apoptosis and Wnt/Hh signaling crosstalk. *Environ. Sci. Pollut. Res. Int.*, **28**(23), 29615-29628(2021).
57. Akgun, E., Çaliskan, C., Celik, H., Ozutemiz, A., Tuncyurek, M. and Aydin, H. Effects of N-acetylcysteine Treatment on Oxidative Stress in Acetic Acid-induced Experimental Colitis in Rats. *Journal of International Medical Research*, **33**(2), 196-206 (2005). doi:10.1177/147323000503300207
58. Gomaa, A. M. S., Abd El-Mottaleb, N. A. and Aamer, H. A. Antioxidant and anti-inflammatory activities of alpha lipoic acid protect against indomethacin-induced gastric ulcer in rats. *Biomedicine and Pharmacotherapy*, **101**, 188–194(2018).  
https://doi.org/10.1016/j.biopha.2018.02.070
59. Cervantes-García, D., Bahena-Delgado, A. I., Jiménez, M., Córdova-Dávalos, L. E., Ruiz-Esparza Palacios, V., Sánchez-Alemán, E., Martínez-Saldaña, M. C. and Salinas, E. Glycomacropptide Ameliorates Indomethacin-Induced Enteropathy in Rats by Modifying Intestinal Inflammation and Oxidative Stress. *Molecules* (Basel, Switzerland), **25**(10), 2351(2020).  
https://doi.org/10.3390/molecules25102351
60. Yamagishi, S., Nakamura, K. and Inoue, H. Therapeutic potentials of unicellular green alga Chlorella in advanced glycation end product (AGE)-related disorders, *Med. Hypotheses*, **65** (5), 953–955(2005).
61. Jeong, H., Kwon, H.J. and Kim, M.K. Hypoglycemic effect of Chlorella vulgaris intake in type 2 diabetic Goto-Kakizaki and normal Wistar rats. *Nutr. Res. Pract.*, **3** (1), 23–30(2009).
62. Azzat, O., Yap, S. W., Sopia, H., Madiha, M. M., Hazreen, M., Shailah, A., Wan, J. W., Nur, S. A., Srijit, D., Musalmah, M. and Yasmin, A. M. Modulation of oxidative stress by Chlorella vulgaris in streptozotocin (STZ) induced diabetic Sprague-Dawley rats. *Advances in Medical Sciences*, **55**(2), 281–288. (2010). https://doi.org/10.2478/v10039-010-0046-z
63. Hanieh, B., Zahra, D., Elyas, N., Enas, R. A., Abbas, A., Ali, K. K., Mehdi, B., Golnaz, R., Alireza, M., Pegah, R., Naseh, P. The effects of Chlorella vulgaris on cardiovascular risk factors: A comprehensive review on putative molecular mechanisms. *Biomedicine & Pharmacotherapy*, **162**, 114624(2023).
64. Ahmad, H., Verma, S. and Kumar, V.L. Effect of roxithromycin on mucosal damage, oxidative stress and pro-inflammatory markers in experimental model of colitis, Inflammation research: *Official Journal of the European Histamine Research Society*, **67**, 147-155(2018).
65. Ercan, G., Yigitturk, G. and Erbas, O. Therapeutic effect of adenosine on experimentally induced acute ulcerative colitis model in rats, *Acta Cirurgica Brasileira*, **34**, e201901204(2020).
66. Harputluoglu, M. M., Demirel, U., Yücel, N., Karadağ, N., Temel, I., Firat, S., Ara, C., Aladağ, M., Karıncaoğlu, M. and Hilmioğlu, F. The effects of Gingko biloba extract on acetic acid-induced colitis in rats. *The Turkish Journal of Gastroenterology*, **17**(3), 177–182 (2006).
67. El-Abhar, H. S., Hammad, L. N. A. and Gawad, H. S. A. Modulating effect of ginger extract on rats with ulcerative colitis. *Journal of Ethnopharmacology*, **118**(3), 367–372 (2008).
68. Shapiro, H.; Singer, P.; Halpern, Z. and Bruck, R. Polyphenols in the treatment of inflammatory bowel disease and acute pancreatitis. *Gut*, **56**, 426–435(2007).
69. Minaiyan, M.; Asghari, G.; Taheri, D.; Saeidi, M. and Nasr-Esfahani, S. Anti-inflammatory effect of Moringa oleifera Lam. seeds on acetic acid-induced acute colitis in rats. *Avicenna J. Phytomed.*, **4**, 127–136(2014).
70. Saldanha, E.; Saxena, A.; Kaur, K.; Kalekhan, F.; Ponemone, V.; Fayad, R.; Rao, S.; George, T.; Baliga, S. Chapter 23—Polyphenols in the prevention of ulcerative colitis: A revisit. In Dietary Interventions in Gastrointestinal Diseases: Foods, Nutrients, and Dietary Supplements; *Academic Press*: Cambridge, MA, USA, pp. 277–287(2019).
71. Elmore, S. Apoptosis: a review of programmed cell death. *Toxicologic Pathology*, **35**(4), 495-516(2007).
72. Yan, L. and Lim, S.. Effect of fermented chlorella supplementation on growth performance, nutrient digestibility, blood characteristics, fecal microbial and fecal noxious gas content in growing pigs. *Asian-Australasian Journal of Animal Sciences*, **25**(12),1742(2012).
73. Ibrahim, I. A., Shalaby, A. A., Abd Elaziz, R. T. and Bahr, H. I. Chlorella vulgaris or Spirulina platensis mitigate lead acetate-induced testicular oxidative stress and apoptosis with regard to androgen receptor expression in rats. *Environmental Science and Pollution Research International*, **28**(29), 39126–39138(2021). https://doi.org/10.1007/s11356-021-13411-w .
74. Rahman, I., Marwick, J. and Kirkham, P. Redox modulation of chromatin remodeling: impact on histone acetylation and deacetylation, NF-kappaB and pro-inflammatory gene expression. *Biochemical Pharmacology*, **68**(6), 1255–1267(2004). https://doi.org/10.1016/j.bcp.2004.05.042 (2004).
75. Atreya, I., Atreya, R. and Neurath, M. F. NF-kappaB in inflammatory bowel disease. *Journal of Internal Medicine*, **263**(6), 591–596 (2008).. https://doi.org/10.1111/j.1365-2796.2008.01953.x .
76. Amirshahrokhi, K. Acrylamide exposure aggravates the development of ulcerative colitis in mice through activation of NF-κB, inflammatory cytokines, iNOS, and oxidative stress. *Iranian Journal of Basic Medical Sciences*, **24**(3), 312–321(2021). https://doi.org/10.22038/ijbms.2021.52233.11816.
77. Ran, Z. H., Chen, C. and Xiao, S. D. Epigallocatechin-3-gallate ameliorates rats colitis induced by acetic acid. *Biomedicine and*

- Pharmacotherapy*, **62**(3), 189–196(2008). <https://doi.org/10.1016/j.biopha.2008.02.002>.
78. Li, X., Liu, X., Zhang, Y., Zhang, Y., Liu, S., Zhang, N., Li, Y. and Wang, D. Protective effect of *Gloeostereum incarnatum* on ulcerative colitis via modulation of Nrf2/NF- $\kappa$ B signaling in C57BL/6 mice. *Molecular Medicine Reports*, **22**(4), 3418–3428(2020). <https://doi.org/10.3892/mmr.2020.11420>
79. Kühn, R., Löhler, J., Rennick, D., Rajewsky, K. and Müller, W. Interleukin-10-deficient mice develop chronic enterocolitis. *Cell*, **75**(2), 263–274(1993).. [https://doi.org/10.1016/0092-8674\(93\)80068-p](https://doi.org/10.1016/0092-8674(93)80068-p)
80. Sabat, R., Grütz, G., Warszawska, K., Kirsch, S., Witte, E., Wolk, K. and Geginat, J. Biology of interleukin-10. *Cytokine & Growth Factor Reviews*, **21**(5), 331–344(2010). <https://doi.org/10.1016/j.cytogfr.2010.09.002>
81. Gazzinelli, R. T., Wysocka, M., Hieny, S., Scharon-Kersten, T., Cheever, A., Kühn, R., Müller, W., Trinchieri, G. and Sher, A. In the absence of endogenous IL-10, mice acutely infected with *Toxoplasma gondii* succumb to a lethal immune response dependent on CD4<sup>+</sup> T cells and accompanied by overproduction of IL-12, IFN- $\gamma$  and TNF- $\alpha$ . *Journal of Immunology* (Baltimore, Md. : 1950), **157**(2), 798–805(1996).
82. Sellon, R. K., Tonkonogy, S., Schultz, M., Dieleman, L. A., Grenther, W., Balish, E., Rennick, D. M. and Sartor, R. B. Resident enteric bacteria are necessary for development of spontaneous colitis and immune system activation in interleukin-10-deficient mice. *Infection and Immunity*, **66**(11), 5224–5231(1998). <https://doi.org/10.1128/IAI.66.11.5224-5231.1998>.
83. Hashem, H., Hussein, S., & El senosi, Y. Lycopene mitigates experimental colitis in rats by inhibiting oxidative stress-mediated inflammation and apoptosis. *Benha Veterinary Medical Journal*, **39**(1), 16-21(2020).. doi: 10.21608/bvmj.2020.37614.1236 (2020).
84. Simon, H. U., Haj-Yehia, A. and Levi-Schaffer, F. Role of reactive oxygen species (ROS) in apoptosis induction. *Apoptosis : an International Journal on Programmed Cell Death*, **5**(5), 415–418(2000). <https://doi.org/10.1023/a:1009616228304>
85. Ran, Z. H., Chen, C. and Xiao, S. D. Epigallocatechin-3-gallate ameliorates rats colitis induced by acetic acid. *Biomedicine & Pharmacotherapy*, **62**(3), 189–196(2008). <https://doi.org/10.1016/j.biopha.2008.02.002>
86. Rezayat, S. M., Dehpour, A. R., Motamed, S. M., Yazdanparast, M., Chamanara, M., Sahebgharani, M. and Rashidian, A. *Foeniculum vulgare* essential oil ameliorates acetic acid-induced colitis in rats through the inhibition of NF- $\kappa$ B pathway. *Inflammopharmacology*, **26**(3), 851–859(2018).. <https://doi.org/10.1007/s10787-017-0409-1>
87. Sibi, G. and Rabina, S. Inhibition of Pro-inflammatory mediators and cytokines by *Chlorella Vulgaris* extracts. *Phcog Res.* **8**, 118-22(2016).
88. Kang, H.K., Salim, H.M., Akter, N., Kim, D.W., Kim, J.H., Bang, H.T., Kim, M.J., Na, J.C., Hwangbo, J., Choi, H.C. and Suh, O.S. Effect of various forms of dietary *Chlorella* supplementation on growth performance, immune characteristics, and intestinal microflora population of broiler chickens. *Journal of Applied Poultry Research*, **22**(1), 100-108(2013).
- Carl S., Bachar, Z., Othmane, M., Pierre-Yves, P. and Carlos, V. Morphology, composition, production, processing and applications of *Chlorella vulgaris*: A review." *Renewable and Sustainable Energy Reviews*, **35**, 265-278 (2014).

## تعمل الكلوريل فيلجاويز على تخفيف التهاب القولون الناجم عن حمض الأسيتيك بشكل فعال في الجرذان عن طريق تثبيط NF-κB وCaspase-3، مع تنشيط تعبير IL10

هدير أبو مسلم<sup>1</sup>، عبد الله أ. مخابلي<sup>1</sup>، وائل م. جودة<sup>2</sup>، عماد غازي<sup>1</sup>، محمد ف. أبو العزب<sup>1</sup>، آلاء عبد العاطي<sup>3</sup>، زيزي إبراهيم البيلي<sup>4</sup>\* و دعاء ح. عصر<sup>1</sup> \*

<sup>1</sup> قسم الباثولوجيا الإكلينيكية - كلية الطب البيطري - جامعة كفر الشيخ - كفر الشيخ 33516 - مصر .

<sup>2</sup> قسم الباثولوجيا الإكلينيكية - كلية الطب البيطري - جامعة دمنهور - مصر .

<sup>3</sup> قسم الباثولوجيا - كلية الطب البيطري - جامعة كفر الشيخ - كفر الشيخ 33516 - مصر .

<sup>4</sup> قسم تصنيع الأسماك والبيوتكنولوجيا - كلية علوم الثروة السمكية والمصايد - جامعة كفر الشيخ - كفر الشيخ 33516 - مصر .

### الملخص

التهاب القولون التقرحي (UC) هو حالة صحية مزمنة تتميز بتكوين التهاب وقرحة في القولون والمستقيم. على الرغم من أن الكلوريل فيلجاريز (C.V) تمتلك خصائص مضادة للالتهابات ومزايا علاجية إضافية، إلا أنه لم يتم بحث فعاليتها في علاج التهاب القولون. يهدف بحثنا إلى فحص الخصائص المضادة لالتهاب القولون *Chlorella vulgaris* باستخدام نموذج التهاب القولون في الجرذان المحدث بحمض الأسيتيك. تم توزيع 60 ذكراً من فئران ويستار (150-170 جم) بشكل عشوائي على ست مجموعات، بما في ذلك المجموعة الضابطة، وحمض الأسيتيك (تم تلقيها 2 مل 4٪ من حمض الأسيتيك جرعة واحدة عبر المستقيم في اليوم الخامس عشر بواسطة قسطرة بلاستيكية للأطفال)، وسولفاسالازين (100 مجم). /كجم من وزن الجسم)، والكلوريل فقط (300 ملجم/كجم من وزن الجسم)، والكلوريل (300 ملجم/كجم من وزن الجسم) مع حمض الأسيتيك والكلوريل عند (300 ملجم/كجم من وزن الجسم) بالاشتراك مع السلفاسالازين (100 ملجم/كجم من وزن الجسم عن طريق الفم). تم ذبح بالحيوانات المصابة بالتهاب القولون في اليوم السابع بعد التخدير وتم الحصول على الدم الكامل لتحليل الدم لتقييم التغيرات العيانية والنسجية والتحليل الكيميائي المناعي والجزئي لحماية الغشاء المخاطي للقولون من الخلايا الالتهابية التسلل والتدمير، والآفات التاكلية العميقة، وذمة النخر، وفقدان السلامة الظهارية، ارتبطت بقدرة الكلوريل على تحسين المعلمات الدموية، والسمات العيانية، وتم تخفيض مستويات المالونديالدهيد (MDA) وأكسيد النيتريك (NO)، في حين تم تخفيض مستويات مضادات الأكسدة / الأكسدة. تمت استعادة التوازن، كما يتضح من زيادة نشاط الكاتلاز وانخفاض مستويات الجلوتاثيون، وتثبيط الالتهاب عن طريق تقليل NF-κB وعلامة موت الخلايا المبرمج كاسباس 3 في الأنسجة القولونية، وبالتالي منع موت الخلايا المبرمج. في الختام، تعمل *Chlorella vulgaris* بشكل فعال على تحسين UC الناجم عن AA في الفئران عن طريق تقليل الالتهاب، وموت الخلايا المبرمج، والإجهاد التأكسدي، في أنسجة القولون. ولذلك، يمكن أن يكون الكلوريل الشائع خياراً مناسباً لعلاج التهاب القولون التقرحي.

**الكلمات الدالة:** التهاب القولون. كلوريل فيلجاريز. حمض الاسيتيك؛ سلفاسالازين. مضادات الأكسدة، التعبير الجيني، الفئران.