

The preventive properties of Mastic gum (*Pistacia lentiscus*) aqueous extract on rats with stomach ulcers

Asmaa Mahmoud A. Mohamed

Faculty of Specific Education- Home Economics Department – Aswan University

Abstract

Gastric ulcers are common conditions that affect a large percentage of people worldwide. Modern medications have numerous negative consequences of treating illnesses as well as being costly. Therefore, the purpose of our study was to examine and compare the effects of mastic gum aqueous extract (100, 200, and 300 mg/kg of body weight) on the rats suffering from stomach ulcers. Five groups of thirty rats were created: group one was served as a negative control and the second group with the gastric ulcers was kept as the positive control group. The other three groups with gastric ulcer were received the three different doses of mastic aqueous extract. In comparison to the positive group, the treated groups with the mastic aqueous extract exhibited a substantial improvement in pH values, an improvement in ulcer regions, and an increase in healing rate. In addition, the improvement in the activities of the antioxidant enzymes CAT, GPx, and SOD. Based on this results, we deduce that aqueous mastic extracts at varying concentrations (100, 200, and 300 mg/kg body weight) protect rats' stomachs from developing acute experimental stomach ulcers.

Keywords: Mastic gum (*Pistacia lentiscus*), Stomach Ulcers

1- INTRODUCTION

Gastric ulcers are widespread illnesses that affect a significant portion of the global population. (Insaf, 2018) The hallmark of peptic ulcer disease is the breakdown of the gastrointestinal tract's inner lining due to either pepsin or gastric acid release. It penetrates the stomach epithelium's muscularis propria layer. Usually, it affects the proximal duodenum and stomach. The jejunum,

distal duodenum, or lower esophagus could be affected. Patients with gastric ulcers typically have epigastric pain 15–30 minutes after eating, whereas duodenal ulcer patients typically experience pain 2–3 hours later. (**Kelly et al., 2009 and Talia et al., 2023**).

Herbal medicines with therapeutic potential emerge as appealing alternative treatments, despite the contemporary era's great advancements in the medical business. Because herbal medicines are more compatible with the human body and have less side effects, they continue to be the go-to option for treating a wide range of illnesses for roughly 75–80% of the world's population, mostly in underdeveloped nations (**Nahida et al., 2012**).

Mastiha, also known as *Pistacia lentiscus var. Chia* or *Pistacia lentiscus L. var latifolius* Coss, is a naturally occurring aromatic resin derived from the trunk and branches of the mastic tree. Chios mastic gum is another name for it (**Ierapetritis, 2010**). Greek traditional medicine has been using gum mastic for more than 2500 years, primarily for gastrointestinal conditions like gastralgia and peptic ulcers. Mastic is mentioned and recommended as a healing ingredient in the writings of Greek physicians, including Dioscorides and Galen. These days, it is utilized in dentistry, fragrance, chewing gum manufacturing, Mediterranean cooking, as a flavoring, and in Greek traditional medicine to treat gastritis and prevent peptic ulcers (**Paraschos et al., 2012**).

The medicinal potential of Chios mastic gum has also been demonstrated through clinical treatments and experiments. 2015 saw the European Medicines Agency (EMA) designate *Pistacia lentiscus L.* resin, also known as mastic, as an herbal medicinal substance with traditional usage for two therapeutic indications: moderate dyspeptic disorders and skin inflammation/healing of minor wounds. Chios mastic gum has been extensively used in food

supplements, cosmetics, and pharmaceutical goods in recent years. It is also being studied in the field of pharmacotechnology (**Vasiliki *et al.*, 2020**).

The current study objective was to examine and contrast the effects of varying doses (100, 200, and 300 mg/kg of body weight (b.wt.) of mastic gum aqueous extract on the pH values and volume of gastric juice, ulcer length, and curative ratio of gastric ulcer in rats. Reliable parameters for data comparison were presented, including activities of antioxidant enzymes (SOD, GPX, and CAT). A stomach ulcer's histopathological examination was completed.

2- MATERIALS AND METHODS

2.1 Materials

2.1.1 Herbs

Mastic gum was purchased as crude dried material from a local Company for Medicinal Plants and Herbs, Cairo, Egypt.

2.1.2 Animals

Thirty male albino rats, Sprague Dawley strain weighing 160±5g, were obtained from the Laboratory Animal Colony, Helwan, Egypt.

2.2 Methods:

2.2.1 Preparation of Mastic Gum Aqueous Extract

Using 10g of dried material and 100 ml of distilled water, the aqueous extract of mastic gum was made by boiling it for five minutes at 100°C. After that, they were filtered and concentrated using a Rotary vapor apparatus. Then the extract was stored at -20°C until used (**Kassi *et al.*, 2004**).

2.2.2 Preparation of the Basal Diet

The basal diet (AIN-93M) was formulated to meet recommended nutrients levels for rats as mentioned by **Reeves *et al.*, (1993)**.

2.2.3 Experimental Design

Before beginning the trial, to acclimate all animals was kept in healthy circumstances with humidity, temperature (20–25°C), and light (12–hour light–12–hour dark cycle) and were also fed a baseline diet and given access to water on a free-choice basis. Then after an acclimation, rats were split into five groups of the same weight and quantity (six rats each group). The first main group was kept as a negative control group and fed the basal diet and given orally saline solution at a volume of 1 ml/100 gm b.wt. The remaining animals (n = 24) were given oral ethanol (0.5 ml/100g) to induce gastric ulcer as described by **Hollander *et al.*, (1985)**. Then the affected rats by stomach ulcers were divided into four groups. The second group was the positive control and feed on the basal diet, while the third, fourth and fifth groups were fed a diet and given orally the aqueous extract of mastic by a tube feeding for two weeks at a dose of 100, 200, and 300 mg/kg b. wt., respectively.

2.2.4 Gastric Ulcer Index

During this investigation, the methodology outlined by **Agrawal *et al.*, (2000)** was utilized. In summary, all rats were anaesthetized with an overdose of diethyl ether, removed their stomachs, and then had saline rinsed after receiving ethanol for four hours. A test tube was used to collect the gastric juice. After that, stomachs were opened along their larger curvature, cleaned with saline, and checked for gastric ulcers under a dissecting microscope. The ulcer index was calculated by adding the lengths of all the ulcers in each animal. The following formula was used to determine the curative ratio for each group:

$$\text{Curative ratio (CR)} = (\text{LC-LT/LC}) \times 100$$

LC: The length of gastric ulcer in positive group

LT: The length of gastric ulcer in treated group.

2.2.5 Determination of Gastric Juice Acidity

Acidity degree (pH) of gastric juice was determined by using pH meter apparatus (HI 9021).

2.2.6 Determination of Gastric Juice Volume

Collected gastric juices were centrifuged at 500 rpm for 5 minutes then separated and measured volume by graduated cylinder.

2.2.7 Assessment of Antioxidant Enzymes

Assays the activities of antioxidant enzymes glutathione peroxidase (GPX), superoxide dismutase (SOD) and catalase (CAT) were estimated according to described methods by (Paglia and Valentine, 1979), (Spitz and Oberley, 1989) and (Sinha, 1972), respectively.

2.2.8 Histopathological Examination

The stomachs of all scarified rats were removed and submerged in a 10% formalin solution. After that, the fixed stomach specimens underwent trimming, washing, and dehydration in progressively higher alcohol grades. After being cleaned with xylol, the specimens were embedded in paraffin, sectioned at a thickness of 4-6 microns, and stained with hematoxylin and eosin stain to examine the stomach, as per the instructions provided by (Carleton, 1979).

2.2.9 Statistical Analysis

The mean value \pm standard error (SE) was used to express the results. The Dunk test, a multiple range post-hoc test, was used in the statistical analysis utilizing SPSS, PC statistical software (Verion 18.0 SPSS Inc., Chieago, USA). ANOVA, or one-way analysis of variance, was used to analyze the data. $P < 0.05$ was used to determine whether the values were substantially different (Snedecor and Cochran, 1980).

3. RESULTS AND DISCUSSION

3.1. PH of Gastric Juice

The results indicated that there is a significant decrease in the pH value of gastric juice of the positive group, compared to that of the control group. While the pH values of gastric juice increased in the treated groups with mastic aqueous extract, compared to the positive group. The PH values in rat treated with mastic gum aqueous extract at different doses are listed in **Table (1)**. When compared to the positive group, the treated group with a 300 mg/kg of b wt. extract had the best results. These findings corroborate with a study of **Al-Zahid, (1993)** who split 24 rats into three groups: six animals were in the control group, six animals had reserpine-induced peptic ulcers, and twelve animals received mastic treatment. Both forms of ulcers are fully treated with mastic because it provides a barrier against stomach acids. These findings are in line with research (**Da-Eun et al., 2014**) showing that mastic gum can reduce the production of stomach acid by controlling the hormone system linked to histamine.

Table (1): The effect of different doses of Mastic gum aqueous extract on the pH values of gastric juice

Groups		Parameter as Mean \pm SE
		pH of gastric juice
Control group		5.98 \pm 0.08 ^a
Positive group		4.62 \pm 0.13 ^c
Treated groups with aqueous extracts at a doses of :	100mg/kg b. wt.	5.46 \pm 0.13 ^b
	200mg/kg b. wt.	5.84 \pm 0.08 ^a
	300mg/kg b. wt.	6.04 \pm 0.37 ^a

Each value is shown as mean \pm SE, mean in the same column with different superscript letters differ significantly ($P \leq 0.05$).

3.2. Volume of Gastric Juice

The volume of gastric juice (cm³) of treated rats with varying dosages of the aqueous extract of mastic is displayed in **Table 2**. The results demonstrated that the volume of gastric juice significantly increased in the positive group, compared to that of the healthy control group, it significantly reduced in the treatment groups, compared to the positive group.

3.3. Length of Gastric Ulcer

The results in **Table 2** showed significant decreases in the stomach ulcer lengths (mm) in treated rats with the different doses of mastic aqueous extract compared to the positive group.

Table (2): The effect of different doses of Mastic gum aqueous extract on volume of gastric juice (cm³), length of gastric ulcer (mm) and Curative ratio

Groups		Parameters	Volume	Length	Curative ratio
Control group			1.86 ± 0.13 ^d	0.00 ± 0 ^e	100.00 ± 0 ^a
Positive group			4.80 ± 0.21 ^a	6.90 ± 0.12 ^a	0.00 ± 0 ^c
Treated groups with aqueous extracts at a doses of :	100mg/kg b. wt.		3.28 ± 0.21 ^b	4.24 ± 0.20 ^b	38.50 ± 3.96 ^d
	200mg/kg b. wt.		2.94 ± 0.37 ^c	2.64 ± 0.13 ^c	61.72 ± 2.15 ^c
	300mg/kg b. wt.		2.00 ± 0.12 ^d	1.26 ± 0.15 ^d	81.72 ± 2.30 ^b

Each value is shown as mean ± SE, mean in the same column with different superscript letters differ significantly (P ≤ 0.05).

3.4 Curative Ratio

The findings in **Table 2** demonstrated a significant improvement in the healing rates in the treated groups with mastic aqueous extract; In the third group healing rates were 38.50 ± 3.96, while the fifth group healing rates were 81.72 ± 2.30 after receiving 300mg/kg b. wt. of mastic aqueous extract. These

findings support the study of **Abdel-Jalil *et al.*, (2005)** who suggested that mastic gum's antioxidant and anti-secretory qualities might also contribute to its anti-ulcer effect. According to this study, eating Pistacia Atlantica gum every day for a month alleviates the symptoms of diabetic gastroparesis (**Fatemeh *et al.*, 2018**). These findings are in line with research of **Neda *et al.*, (2019)** who indicated that Pistacia Atlantica gum extract may be useful in protecting rats from developing stomach ulcers brought on by ethanol.

3.5 Glutathione Peroxidase (GPX), Catalase (CAT), and Superoxide Dismutase (SOD).

The body has an intricate system of defense against free radicals, which can be divided into first, second, third and even fourth line defense antioxidants. This system depends on radical invasion. Endogenous enzymatic and non-enzymatic antioxidants: their function and efficacy as the first line of defense. In order to prevent free radicals from harming essential biomolecules and eventually bodily tissues, these molecules work together to combat them. They are significant and essential to the complete antioxidant defense strategy based on how they react to general free antioxidants, which essentially consist of glutathione peroxidase (GPX), catalase (CAT), and superoxide dismutase (SOD) (**Ighodar and Akinloye, 2018**). In comparison to the positive group, the results in Table 3 indicated that there a significant rise in the activities of glutathione peroxidase (GPX), catalase (CAT), and superoxide dismutase (SOD) in treated rats with mastic gum aqueous extract. These outcomes concurred with the earlier discoveries of **Fkour *et al.*, (2017)** who indicated that P. Atlantica mastic extract has a suitable effect on wound healing and can be employed as a natural antioxidant. Researchers are interested in Pistacia species because of their diverse biological properties, including the ability to act as an antioxidant, antimicrobial, and anti-inflammatory. These properties are primarily attributed

to the presence of various phenolic components, which have been studied in the plant's leaves, kernels, and hulls (**Hosseinzadeh *et al.*, 2012**). Apart from its conventional application in treating stomach ulcers, mastic resin has been shown to possess anti-bacterial, antifungal, antioxidant, hepatoprotective, and anti-carcinogenic qualities in products derived from *P. lentiscus* (**Landau *et al.*, 2014** and **Fakour *et al.*, (2017)**).

3.6 Thiol-Containing Tripeptide Glutathione (GSH)

Thiol-containing tripeptide glutathione (GSH) is essential for both signaling pathways and the body's defense against oxidative damage. Glutathione disulfide (GSSG) is the product of oxidation of GSH. Oxidative stress and cell functioning are shown by the molar ratio and amounts of GSH and GSSG. Growing importance are medical applications for glutathione status restoration and assessment of redox homeostasis in diverse clinical conditions (**Péter *et al.*, 2009**). As shown in Table 3, The tripeptide glutathione (GSH) level was found to be lower in the positive group than in the control group and to be higher in the groups that received mastic aqueous extract treatment.

Table (3): The Effect of different doses of Mastic gum aqueous extract on antioxidant enzymes (SOD, GPX, CAT and GSH)

Parameters	SOD	CAT	GPx	GSH
Control group	760.3± 34.68 ^c	57.67± 23.02 ^c	45.33± 18.00 ^a	2.98± 0.20 ^b
Positive group	749.7± 47.39 ^d	66.33 ± 23.02 ^b	40.67± 12.58 ^{a,b}	2.33± 0.58 ^c
100mg/kg b. wt.	925.7± 27.51 ^a	73.33± 13.42 ^a	37.67± 8.62 ^c	3.43± 0.66 ^a
200mg/kg b. wt.	904.0± 45.63 ^b	68.67 ± 7.09 ^b	37.67± 11.93 ^c	3.19± 1.10 ^{a,b}
300mg/kg b. wt.	929.0± 32.18 ^a	75.67± 6.11 ^a	35.00 ± 7.81 ^d	3.56± 0.54 ^a

Each value is shown as mean ± SE, mean in the same column with different superscript letters differ significantly ($P \leq 0.05$).

Histopathological Examinations:

Rats from group 1's stomachs demonstrated, under a microscope, the typical histoarchitecture of the gastric layers—mucosa, submucosa, muscularis, and serosa (Figs. 1, 2 & 3). Submucosal edema, congestion of mucosal blood vessels, focal necrosis of the gastric mucosa associated with mucosal inflammatory cell infiltration, and submucosal inflammatory cell infiltration were among the histopathologically damaged stomachs of the rats in group 2 (Figs. 4, 5, 6 & 7). These results are consistent with the study **Arawwawala et al., (2010)**. Ethanol-induced gastric ulcer is a usual, convenient animal model for the investigation of gastro protective drugs. The role of ethanol is explained by its ulcerogenic effect. Ethanol progresses disarrangement in mucosal microcirculation and ischemia, produces free radicals, and releases endothelium. A few sections from group 3 were investigated, and while some showed no histopathological abnormalities (Figs. 8 & 9), other sections showed submucosal edema (Figs. 10, 11 & 12), congestion of submucosal blood vessels (Fig. 10), and infiltration of submucosal inflammatory cells (Figs. 11 & 12).

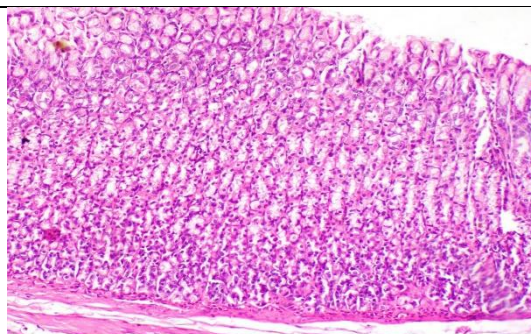


Fig. (1)Rat stomach photomicrograph from group 1 displaying the typical gastric layer histoarchitecture (H & E stain, X 100).

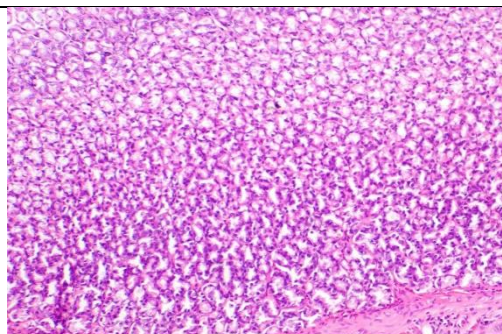


Fig. (2): Rat stomach from group 1 photomicrograph displaying the typical gastric layer histoarchitecture (H & E stain, X 100).

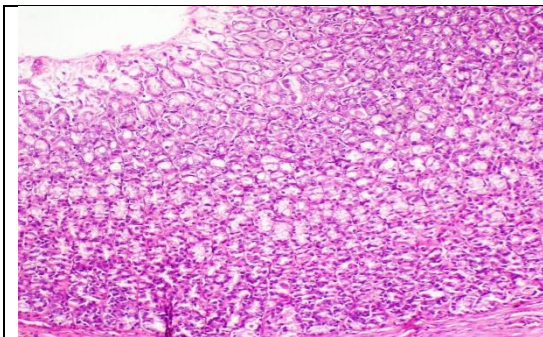


Fig. (3): Rat stomach photomicrograph from group 1 displaying the typical gastric layer histoarchitecture (H & E stain, X 100).

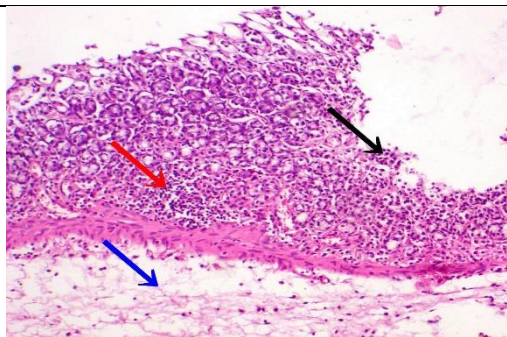


Fig. (4): Photomicrograph of stomach of rat from group 2 showing focal necrosis of gastric mucosa (black arrow) associated with mucosal inflammatory cells infiltration (red arrow) and submucosal edema (blue arrow) (H & E stain, X 100).

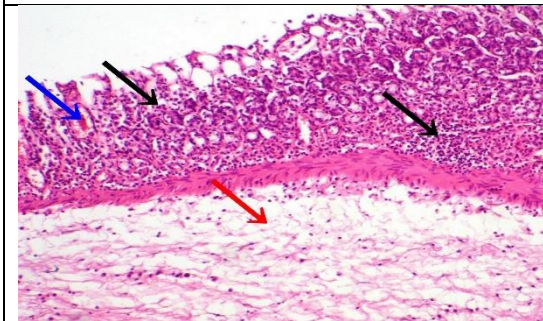


Fig. (5): Photomicrograph of rat stomach from group 2 demonstrating submucosal edema (red arrow), congestion of mucosal blood vessels (blue arrow), and focal necrosis of the gastric mucosa associated with infiltration of mucosal inflammatory cells (black arrow) (H & E stain, X 100).

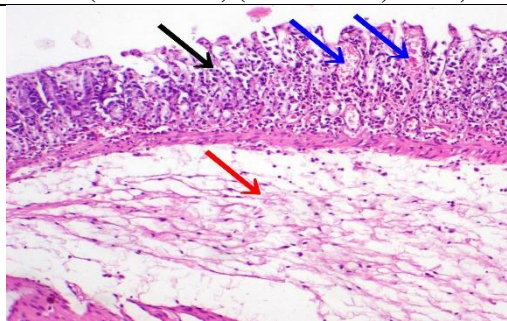


Fig. (6): A photomicrograph of a rat from group 2's stomach demonstrates submucosal edema (red arrow), an infiltration of mucosal inflammatory cells (black arrow), and focal necrosis of the gastric mucosa. (H & E stain, X 100).

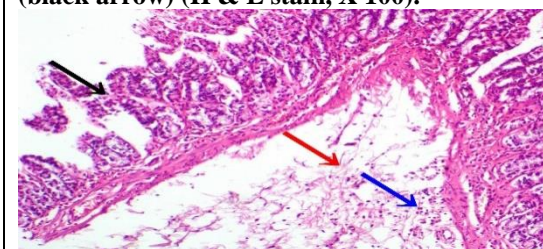


Fig. (7): A photomicrograph of a rat from group 2's stomach demonstrating infiltration of inflammatory cells (blue arrow), submucosal edema (red arrow), and focal necrosis of the stomach mucosa (H & E stain, X 100).

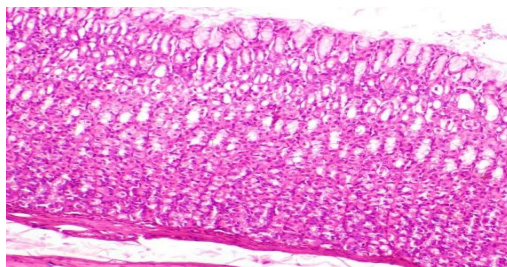


Fig. (8): Histopathological abnormalities absent from the stomach photomicrograph of a rat from group 3. (H & E stain, X 100).

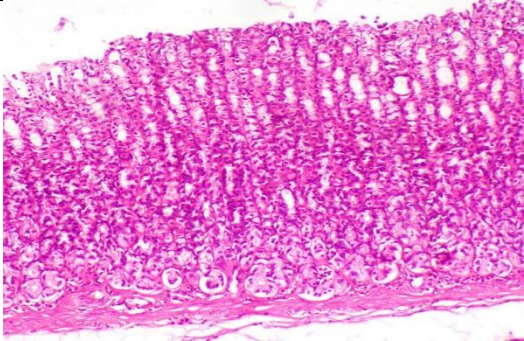


Fig. (9): Histopathological abnormalities absent from the stomach of a rat from group 3. (H & E stain, X 100).

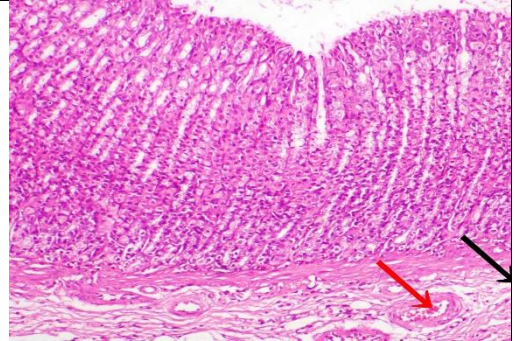


Fig. (10): Photomicrograph of a rat from group 3's stomach demonstrating submucosal blood vessel congestion (red arrow) and submucosal edema (black arrow). (H & E stain, X 100).

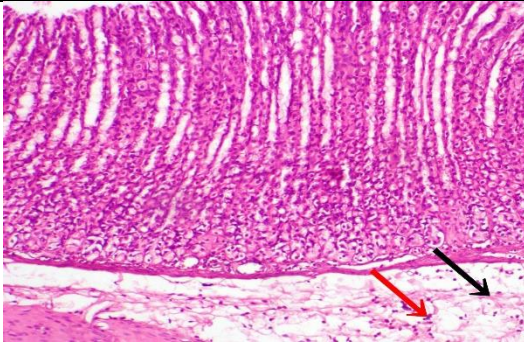


Fig. (11) :Photomicrograph of a rat's stomach from group 3 demonstrating submucosal edema (black arrow) and a little infiltration of inflammatory cells (red arrow).(H & E stain, X 100).

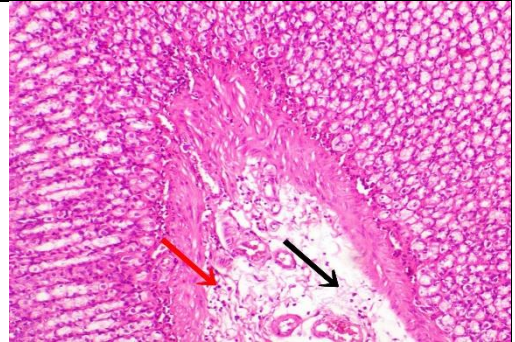


Fig. (12): A photomicrograph of a group 3 rat's stomach demonstrating a little infiltration of inflammatory cells and submucosal edema (black arrow) (H & E stain, X 100).

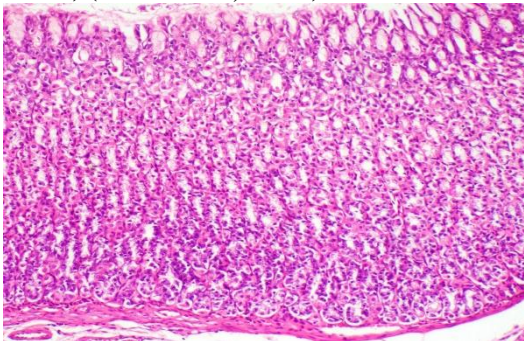


Fig. (13): Rat from group 4's stomach photomicrograph demonstrating no histopathological damage (H & E stain, X 100).

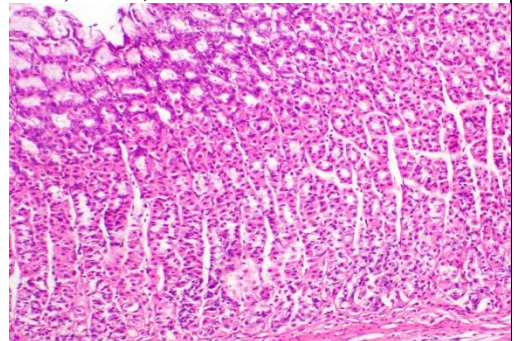


Fig (14) : Rat from group 4's stomach photomicrograph demonstrating no histopathological damage (H & E stain, X 100).

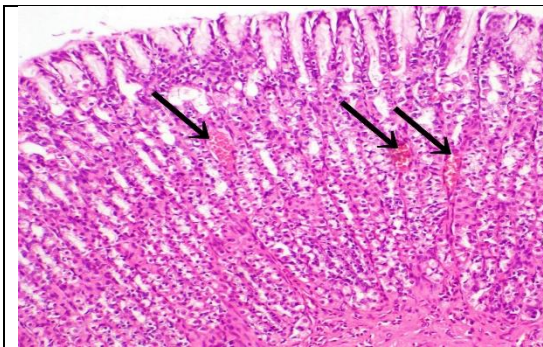


Fig. (15): Photomicrograph of group 4 rat stomach demonstrating mucosal blood vessel congestion (black arrow)(H & E stain, X 100).

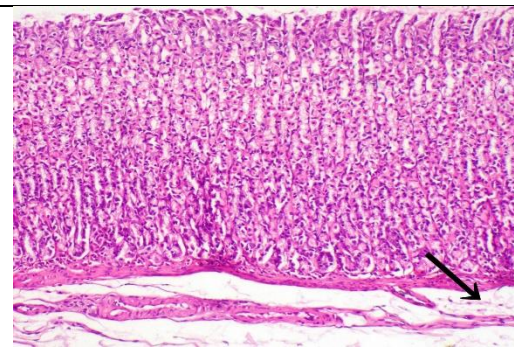


Fig. (16): Rat photomicrograph from group 4 exhibiting mild submucosal edema (black arrow) (H & E stain, X 100).

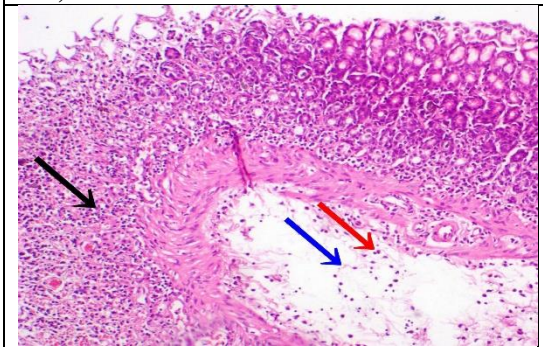


Fig. (17): A photomicrograph of a rat from group 4's stomach reveals submucosal edema (blue arrow), a few inflammatory cells infiltration (red arrow), and mucosal inflammatory cell infiltration (black arrow). (H & E stain, X 100).

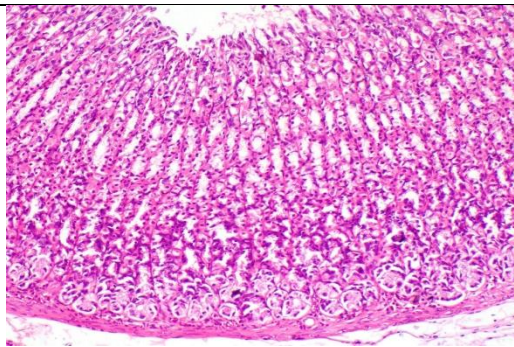


Fig. (18): Rat stomach from group 5 photomicrograph displaying histologically normal gastric layers (H & E stain, X 100).

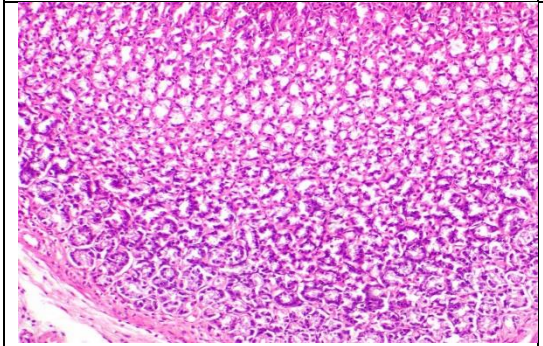


Fig. (19): Rat stomach from group 5 photomicrograph displaying histologically normal gastric layers (H & E stain, X 100).

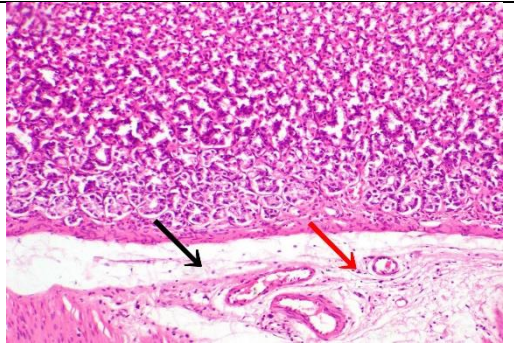


Fig. (20): Rat from group 5's stomach photomicrograph displaying a small amount of submucosal edema (black arrow) and a small infiltration of inflammatory cells (red arrow) (H & E stain, X 100).

REFERENCES

- **Abdel Galil M., Evan I., Saad Azza E., Bistawroos M., Salah Abo Ziet Har M. and Abdel Motaal A. (2005):** Effect of mastic gum, and vitamin e on ethanol/hcl-induced gastric ulcers in rats. Journal of the Egyptian Society of Toxicology. 32 (Supp.): 99-108.
- **Arawwawala L.D., Thabrew M. I. and Arambewela L. S. (2010):** Gastroprotective activity of *Trichosanthes cucumerina* in rats. J Ethnopharmacol. 127(3):750-4.
- **Agrawal A., Roo V., Sairam K., Joshi V. and Goel R. (2000):** Effect of piper longgum linn, zingiber officinal is linn and ferule species n gasric ulceration and secretion in rats. Exper. Bio. 38, 994-998.
- **Carleton H. (1979):** Histological techniques, 4th Ed, London, Oxford University Press, New York, USA, Toronto.
- **Constantinos G., and Stamatios T. (2010):** Current Evidence on the Anticancer Potential of Chios Mastic Gum, Nutr Cancer.; 63(8):1174-84.
- **Da-Eun N., Ok Kyung K., Tae Jin S., Jum Kyun L. and Kwon-Tack H. (2014):** Inhibitory Effects of Chios Mastic Gum on Gastric Acid Secretion by HistamineRelated Pathway in a Rat Model and Primary Parietal Cells. J Korean Soc Food Sci., Nutr 43(10), 1500- 1509.
- **Fatemeh M., Roshanak S., Mahdi Y., Masoud M., Azadeh S. and Kambiz A. (2018):** Effect of *Pistacia atlantica kurdica* gum on diabetic gastroparesis symptoms: a randomized, triple-blind placebo-controlled clinical trial. Electronic Physician. 10(7): 6997–7007.
- **Fkour S.h., Heydari S., Akradi L. and Rahimi A.R. (2017):** Effect of *Pistacia atlantica* Mastic Extract on Experimental Wound Healing and Various Biochemical Parameters of Blood Serum in Rabbit Models. Journal of Medicinal Plants. 16(63):78-91.

- **Hosseinzadeh H., Sajadi Tabassi S. A., Milani Moghadam N., Rashednia M. and Mehri S. (2012):** Antioxidant activity of Pistacia Vera fruit leaves and gum extracts. Iranian. J. Pharm. Res., 11: 879-87.
- **Ierapetritis D. (2010):** The Geography of the Chios Mastic Trade from the 17th through to the 19th Century. Ethnobot. Res. Appl., 8, 153–167.
- **Ighodaro O.M. and Akinloye O.A. (2018):** First line defence antioxidants-superoxide dismutase (SOD), catalase (CAT) and glutathione peroxidase (GPX): Their entire antioxidant defence gridfundamental role in the Alexandria Journal of Medicine.54(4): 287-293.
- **Insaf M. B ., Manel A., Zine C.A., Catherine F. , Samira M., Karim L. , Nacira S., Saadi B., Jean-Marc C. and Chafia T.B. (2018):** Gastro-protective, therapeutic and anti-inflammatory activities of Pistacia lentiscus L. fatty oil against ethanol-induced gastric ulcers in rats 224, 273-282.
- **Kassi, E., Papoutsi Z. and Fokialakis N. (2004):** Greek plant extracts exhibit selective estrogen receptor modulator (SERM)-like properties. J. Agric. Food Chem. 52, 6956-6961.
- **Kelly S. M., Guilherme E. N. D., Meri E. F. P., Anderson L. F., Alba Regina. M. S. B., Clélia A. H. L., José, M. B. F. and Leônia M. B. (2009):** Flavonoids with gastroprotective activity, Molecules2009 Mar 3;14(3):979-1012.
- **Nahida S.H., Ansari A.N. and Siddiqui P. L. (2012):** A review on Photochemistry and Pharmacological Properties. International Journal of Pharmacy and Pharmaceutical Sciences. 4(4): 16-20.
- **Neda S. K., Ardeshir A., Annahita R., Fatemeh G. and Marzieh A. (2019):** Pashmforosh Gastroprotective Effects of Pistacia atlantica Extract onEthanol-Induced Gastric Ulcers in Rats Jundishapur J Nat Pharm Prod. In Press (In Press):e13635.

-
- **Paraschos S., Mitakou S. and Skaltsounis A. L. (2012):** Chios Gum Mastic: A Review of its Biological Activities. *Curr. Med. Chem.*, 19, 2292–2302.
 - **Paglia D.F. and Valentine W.N. (1979):** Studies on glutathione and glutathione characterization of erythrocytes glutathione peroxidase. *J Lab Clin Med*; 70:158-69.
 - **Péter M., Gyula W., Eszter K. and Sándor T. (2009) :** Determination of glutathione and glutathione disulfide in biological samples: An in-depth review *Journal of Chromatography B* Volume 877, Issue 28, 15 October 2009, Pages 3331-3346.
 - **Sinha K.A. (1972):** Colorimetric assay of catalase enzyme. *Anal. Biochem.*; 47:328-30.
 - **Snedecor G. and Cochran W. (1980):** *Statistical methods*, 7th Ed., Iowa State University Press, Ames, USA.
 - **Spitz D.R. and Oberley L.W. (1989):** An assay for superoxide dismutase activity in mammalian tissue homogenates. *Anal. Biochem.*; 179: 8-18.
 - **Talia F. M., Karthik G. and Kevin S. (2023):** *Peptic Ulcer Disease, Treasure Island (FL): StatPearls Publishing;* <https://www.ncbi.nlm.nih.gov/books/NBK534792/>.
 - **Vasiliki K., Pachi Eleni V., Petros G., Konstantinos S., Aikaterini A., Apostolis A., Sofia M. and Maria H. (2020):** Traditional uses, phytochemistry and pharmacology of Chios mastic gum (*Pistacia lentiscus* var. Chia, Anacardiaceae): A review . *Journal of Ethnopharmacology*. 254(23): 112485.
 - **Zahid Z.R. (1993) :** Mastic treatment of induced ulcer *Pakistan Journal of Pharmacology*. 1993; 10 (2): 53-60

الملخص العربي

الخصائص الوقائية للمستخلص المائي لصمغ المستكة (الفسق العسقي) على الفئران المصابة بقرحة المعدة

أسماء محمود احمد محمد

كلية التربية النوعية - قسم الاقتصاد المنزلي - جامعة أسوان

قرحة المعدة هي حالة شائعة تؤثر على نسبة كبيرة من الناس في جميع أنحاء العالم. الأدوية الحديثة لها عواقب سلبية عديدة في علاج الأمراض. بالإضافة إلى كونها مكلفة. لذلك كان الغرض من دراستنا هو فحص ومقارنة تأثيرات ١٠٠ و ٢٠٠ و ٣٠٠ ملجم/كجم من المستخلص المائي لصمغ المستكة على الفئران المصابة بقرحة المعدة. تم إنشاء خمس مجموعات مكونة من ثلاثين فأراً: مجموعة واحدة كانت بمثابة السيطرة، والمجموعة الثانية كانت مجموعة إيجابية مع القرحة. تلقت ثلاث مجموعات جرعات مختلفة من المستخلص المائي للمستكة. تم تقدير العوامل التالية: مستويات الرقم الهيدروجيني، حجم عصير المعدة، منطقة القرحة، معدل الشفاء، الإنزيمات المضادة للأكسدة، والتحقيق النسيجي للمعدة. بالمقارنة مع المجموعة الإيجابية، أظهرت المجموعات المعالجة بالمستخلص المائي للمستكة تحسناً كبيراً في قيم الرقم الهيدروجيني، وتحسناً في مناطق القرحة، وزيادة في سرعات الشفاء. عند مقارنتها بالمجموعة الإيجابية، زادت أيضاً إنزيمات الكاتلاز المضادة للأكسدة (CAT)، والجلوتاثيون بيروكسيداز (GPX)، وديسموتاز الفائق أكسيد (SOD). وبناء على ذلك نستنتج أن المستخلصات المائية للمستكة بتركيزات مختلفة (١٠٠، ٢٠٠، ٣٠٠ ملجم/كجم من وزن الجسم) تحمي معدة الفئران من الإصابة بقرحة المعدة التجريبية الحادة.

الكلمات المفتاحية المستكة (الفسق العسقي) وقرحة المعدة