



## CASE REPORT

### “SIGMOID CANCER IN A NON-REDUCTIBLE INGUINAL HERNIA: A CASE REPORT AND REVIEW OF THE LITERATURE.”

**Rosa Martinez Castro,<sup>1</sup> Jose Felipe Reoyo Pascual,<sup>1</sup> Oscar Vidal Doce,<sup>1</sup> Jesus Aldea Martinez,<sup>2</sup> Juan Luis Seco Gil<sup>1</sup>**

<sup>1</sup>Department of General and Digestive Surgery. General Yagüe Hospital Burgos, <sup>2</sup>Department of Radiology. General Yagüe Hospital. Burgos, Spain

Correspondence to: Rosa Martinez Castro, Email: martinez\_ros@gva.es

#### Abstract

**Aim:** Inguinal hernia and cancer of the colon are two common diseases, but the form of presentation of colon cancer contained within an inguinal hernia sac is rare, with only 28 cases having been published up to the present time.

**Methods:** A review was carried out of the clinical cases published in the world literature, as well as Tables summarising these cases published on the Internet. We add a case treated by us, and we have prepared a new, updated and extended Table.

**Results:** We present a Table with 36 cases of incarcerated hernias in the colon published up to the present time. All were males with ages between 44 and 95 years (mean 72.5 years). Twenty-nine cases were contained within a left inguinal hernia (80.55%) and 7 (19.44%) within a right one. The most frequent location was the left colon in 31 cases (86.1%) and five in the right colon. Nine (25%) of the colon cancers were found to be perforated. Preoperative diagnosis was made in 8 cases (22.2%), 5 using opaque enema, one with opaque enema and sigmoidoscopy, one using colonoscopy and CT, and in our case using CT. The exclusive inguinal approach route was only performed on 4 patients.

**Conclusion:** On being presented with an incarcerated inguinal hernia associated with an intestinal obstruction, the combination of a colon cancer contained within it must be ruled out using imaging techniques, both to confirm the diagnosis, and also to plan the surgical technique.

**Keywords:** Colon cancer; inguinal hernia; Incarcerated inguinal hernia.

#### INTRODUCTION

Inguinal hernia is a common disease which is found to be incarcerated in 10% of cases, with intestinal contents that may cause intestinal obstruction and/or necrosis.<sup>(1)</sup>

Lejars classified malignant tumours of the hernia sac into three groups. Intrasaccular: primary tumours of an organ contained within the hernia, saccular: primary (mesothelioma) or metastatic (which affect the peritoneum of the sac), and extrasaccular: of the spermatic cord structures.<sup>(2)</sup>

The presence of colon cancer within the hernia sac makes up less than 0.5% of its contents,<sup>(3)</sup> but a definitive preoperative diagnosis is desirable for the appropriate treatment of the cancer as well as the repair of the inguinal hernia.

It is due to the rarity of this combination that we decided to review the literature on this condition, collecting a total of 36 cases, including the one treated in our Department of Surgery, and to prepare a Table of the cases. Table 1.

## PATIENTS AND METHODS

We performed a literature search of "primary colon tumour contained in an inguinal hernia sac" using the SACYL server for the library archives of our hospital (<http://bu-hgy.C17.es>) in Pubmed and in the Elsevier data base ([www.elsevier.es](http://www.elsevier.es)). We also extended the search to the Spanish Medical Index (Indice Médico Español (IME)) to include cases published in the Spanish literature not referenced up to the present time.

We prepared a Table mentioning the author, year of publication, patient ages, location of the hernia, colon cancer site, and whether or not it was perforated on its presentation. Gender has not been included as all the cases currently published are in males. Other variables as regards the diagnosis and surgical technique are mentioned in the Results and Discussion.

Metastatic cases of colon cancer contained within an inguinal hernia (omentum with implants or carcinomatosis of the hernia sac), on being different diseases from the ones we are looking for, were not included.

### **We also include a description of our Clinical Case:**

A 65 year-old male, with a history of C3-C7 cervical myelopathy with motor involvement with preserved sensitivity of 5 years of onset and tetraplegia, who was seen in the Emergency Department due to vague abdominal pains and absence of bowel movements, and breaking wind for the past 3 days. On clinical examination he had a giant left incarcerated scrotal-inguinal hernia, protruding and distended abdomen, tympanic, with metallic noises on auscultation.

**Laboratory results:** 19,200 leucocytes (87% neutrophils). Glucose 191 mg/dL.

**Abdominal X-Ray:** signs of intestinal obstruction, with increased bowel sounds in the small intestine.

**Pelvis-Abdomen CT:** there was a marked dilation of the colon and small intestine up to the sigmoid, which was herniated at left scrotal level, with uptake by the wall and corkscrew vessels and parietal thickening; findings

compatible with a left sigmoidal scrotal-inguinal hernia, with signs of ischaemia of associated loop. Although it was difficult to assess, the herniated sigmoid had a focal thickening which did not rule out an associated neoplasm. There was a solid, hypodense lesion in the VI hepatic section suggestive of metastasis (to evaluate with ultrasound after the acute process). (Fig. 1)

He was operated on under general anaesthesia using a left inguinal incision, with examination of the contents of the hernia sac, which had small intestinal loops and the sigmoid colon obstructed by a stenosing tumour mass, adhered to the bottom of the hernia sac, with no signs of ischaemia or perforations. A resection of the sigmoid was performed, with side-to-side mechanical anastomosis, closure of the mesocolon with absorbable sutures, and a reduction of the same to the inside of the abdominal cavity through the internal inguinal orifice. Haemoplasty was performed with a large polypropylene plug, using a Rutkow Robbins technique and leaving a scrotal drain.

**Histopathology Diagnosis:** Large intestine with a moderately differentiated Duckes Stage C adenocarcinoma, which respected the surgical resection margins. Lymphatic ganglia (6): one adenocarcinoma metastasis in one (1) near the tumour. Chronic reactive lymphadenitis in five (5).

During his progression, he recovered intestinal transit, but high losses persisted by nasogastric probe and loop dilation of the small intestine in the simple x-ray, for which a CT of the abdomen was performed on the 12th day postoperative which reported: no pneumoperitoneum or ascites collections or suspicions of peritonitis observed. There was dilation of the small intestinal loops, but no dilation observed in the terminal ileum or colon, which was, in principle, suggestive of intestinal obstruction. There was no free peritoneal fluid.

The patient was re-intervened on the 12th day after surgery by mid-line sub-umbilical laparotomy, finding a jejunal obstruction due to adherence of a loop to the previous sigmoid anastomosis and the left pelvis. This loop was freed, with no pus or faecal contents or free peritoneal fluid being observed. The water tightness of the sigmoidal anastomosis was checked by injecting methylene blue through a rectal probe. There was no evidence of a leak, and the examination was concluded by washing and drainage next to the sigmoid anastomosis in the left iliac fossa.

His progress was satisfactory, being discharged 26 days after his first surgical operation.

The post-operative PET confirmed F18-FDG uptake in the liver related to the previously mentioned hepatic SOL in segment VI in the CT study.

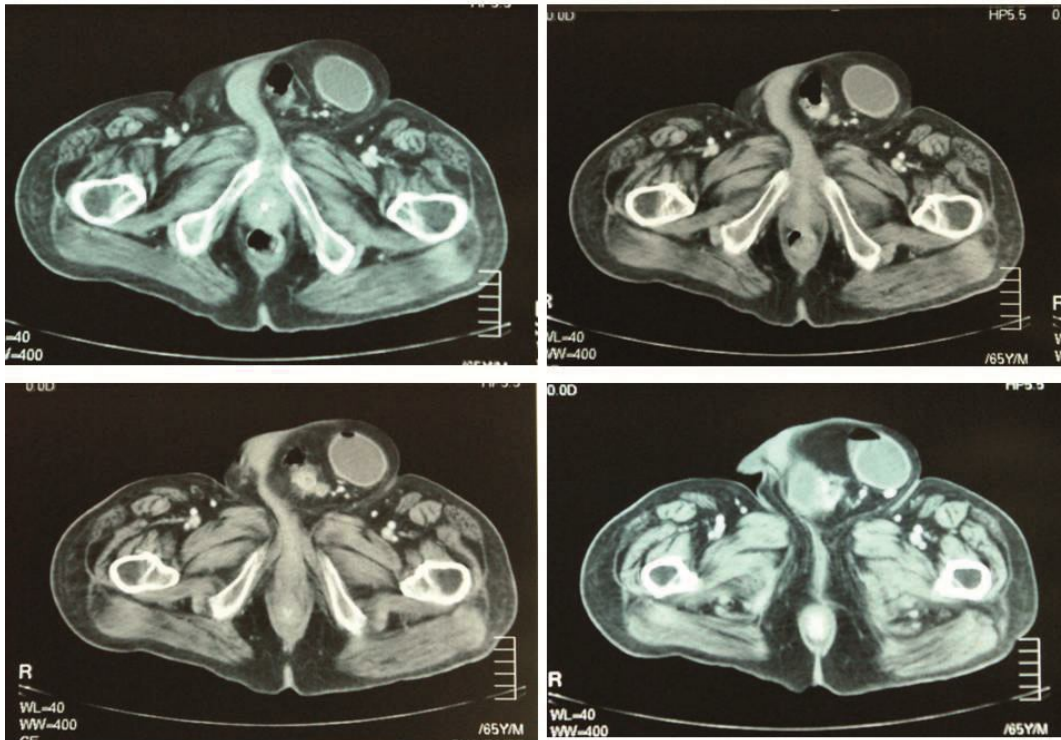
**Table 1. Register of colon cancer within an inguinal hernia.**

Reference	Year	Age	Side	Organ	Perforated	Case
Gerhardt <sup>b,10</sup>	1938	54	L	Sigmoid	Yes	1
Fieber <sup>a,b</sup>	1955	60	L	Sigmoid		2
Bruce <sup>a,b,17</sup>	1958	66	L	Sigmoid		3
Lookanoft <sup>a,b</sup>	1960	67	L	Sigmoid		4
Griffiths <sup>a,b</sup>	1964	74	L	Sigmoid		5
Lees <sup>a,b</sup>	1962	68	L	Sigmoid		6
Silberman <sup>a,b</sup>	1969	62	R	Blind		7
Dross <sup>a,b</sup>	1973	76	R	Blind		8
		73	-	Sigmoid		9
		-	-	Colon		10
		-	-	Colon		11
Horvath <sup>b</sup>	1974	71	L	Sigmoid		12
Gross <sup>a,b</sup>	1980	86	R	Ascending		13
		73	L	Sigmoid		14
Javors <sup>a,18</sup>	1981	77	L	Sigmoid	Yes	15
		84	L	Sigmoid		16
Kanzer <sup>a,b</sup>	1983	70	L	Sigmoid		17
Sriram <sup>a,b</sup>	1986	63	L	Sigmoid		18
		85	R	Blind		19
Pappas <sup>a,b,4</sup>	1987	80	L	Sigmoid	Yes	20
Lafferty <sup>a,b</sup>	1989	86	L	Sigmoid		21
		75	L	Sigmoid		22
		66	L	Sigmoid		23
Rosal <sup>12</sup>	1989	75	L	Sigmoid		24
Knecht <sup>a</sup>	1990	95	L	Sigmoid		25
Hale y Solla <sup>a</sup>	1991	85	L	Sigmoid		26
Birolini <sup>5</sup>	1998	84	L	Sigmoid		27
Tan <sup>a,19</sup>	2003	62	L	Sigmoid		28
Kouraklis <sup>a,16</sup>	2003	79	L	Sigmoid	Yes	29
Boormans <sup>7</sup>	2006	44	R	Sigmoid	Yes	30
Benfatto <sup>14</sup>	2006	72	R	Blind	Yes	31
Sakorafas <sup>15</sup>	2008	85	R	Sigmoid	Yes	32
Slater <sup>8</sup>	2008	66	L	Sigmoid		33
		73	L	Sigmoid	Yes	34
Ruiz-Tobar <sup>11</sup>	2009	67	L	Sigmoid	Yes	35
Martínez-Castro	2010	65	L	Sigmoid		36

a. Adapted from the Table by Boormans.

b. Adapted from the Table by Slater.

c. L = left; R = right.



**Fig 1. CT that shows sigmoid cancer in a non reducible inguinal hernia.**

## RESULTS

The first Table on cases of colon cancer contained inside an inguinal hernia was published by Pappas<sup>(4)</sup> in 1987 with 12 cases and extended to 14 cases in 1998 by Birolini.<sup>(5)</sup> Matsumoto published another Table in 2000 with 25 cases, but included 4 cases of metastatic cancer contained within the hernia sac, including his own case.<sup>(6)</sup>

Boormans, constructed an original Table in 2006, based on a review of the English literature in Medline, with 25 cases of intrahernial cancer of the colon,<sup>(7)</sup> but omitted the cases of Gerhardt and Hovath already mentioned by Pappas.

In 2008 Slater extended the Matsumoto Table to 27 cases, adding his 2 clinical cases.<sup>(8)</sup>

In Table 1 we have compiled a total of 36 cases of intrahernial cancer of the colon, published up to the present time, including the one treated by us.

All the cases reviewed occurred in males, a reason why gender has not been included in our Table.

The ages at presentation varied between 44 and 95 years

(mean, 72.5).

The most frequent side was on the left, with 29 cases (80.55%) and 7 (19.44%) in a right inguinal hernia. The organ most involved was the left colon-sigmoid with 31 cases (86.1%). The 5 cases of cancer of the right colon were in a left inguinal hernia. Two sigmoid cases were contained in a right inguinal hernia (cases 30 and 32) and two were perforated on diagnosis.

Nine cases (25%) had perforations, 6 cases in a left hernia (20.68% of all the cancers contained in left inguinal hernia) and 3 in a right hernia (42.85% of the right inguinal hernias). The 2 sigmoid cases contained in a right inguinal hernia were perforated.

The pre-operative diagnosis of intrahernial cancer of the colon was made in 8 cases (22.2%), 5 using an opaque enema (cases, 2, 5, 16, 24 and 27) one with opaque enema and sigmoidoscopy (case 3), one using colonoscopy and CT (case 35) and another with CT (case 36).

The "exclusive" inguinal approach was only performed in 4 patients (cases 24, 29, 34 and 36).

## DISCUSSION

The form of presentation of a cancer of the colon contained within an inguinal hernia sac is rare, with a frequency of less than 0.5%.<sup>(2)</sup> The idea of the rarity of its presentation arose from the fact that in a review carried out in 2006 by Gurer on the uncommon contents in the sac of 1,950 inguinal hernias, not one case of cancer of the colon was mentioned.<sup>(9)</sup>

From the first case published by Gerhardt<sup>(10)</sup> in 1938 until the last publication by Ruiz-Tobar in 2009 only 28 cases have been reported in the world literature.<sup>(11)</sup> There are 3 published cases in Spain, that of Rosal<sup>(12)</sup> in 1989, Ruiz-Tobar in the English literature, and ours.

In 2006 Boormans reviewed the English literature in Medline and published a Table with 25 cases of primary cancer of the colon contained within an inguinal hernia.<sup>(7)</sup> In 2008 Slater published another Table with 27 cases, which included 4 metastatic cases, excluded from our review.<sup>(8)</sup> We have updated and completed both Tables, introducing cases not mentioned in the English or Spanish literature until now.

The objective of this review is to look in depth into this form of presentation of cancer of the colon, to attempt to improve the preoperative diagnosis, to look for the best surgical approach route and the minimum maneuvers to include in the surgical technique for a correct treatment of the cancer and the hernia. Due to being cases isolated in time, and not having any follow-up available, we were unable to find out their long-term prognosis or outcome. But, perhaps by updating these cases we can encourage our colleagues to register and follow-up future cases, with which we can widen our experience and be able to draw reliable conclusions.

All the cases were in males, which could be due to the higher incidence of inguinal hernia, as well as the higher prevalence of colon cancer in men. However, Avidan, in his prospective case-control study, did not find any relationship between inguinal hernia and cancer of the colon.<sup>(13)</sup>

Although it is considered to be more frequent in elderly patients with long-standing large hernias, this disease must also be excluded in younger adults, as shown by case 30 who was a patient of 44 years-old.

It was more frequently located in the left colon (86.1%), and is situated within a left inguinal hernia in 93.1% of cases. However, we must not forget that a sigmoid cancer can also be found in a right inguinal hernia, as in cases 30 and 32.

The 25% of the cases who had perforations and /or an abscess, although, the tumour was in a more advanced stage, should have a better prognosis than in its intra-abdominal location, since the inguinal canal would provide a barrier to the spread of infection by limiting this to the inguinal region and avoiding peritonitis. The

cases of "perforated" cancer of the colon are more than twice as frequent inside a right inguinal hernia (42.85% compared to 20.68% in the left).<sup>(7,14,15)</sup>

Although Kouraklis<sup>(16)</sup> is quoted as the first reference to perforated cancer of the colon in an inguinal hernia, Gerhardt already mentioned the presence of an abscess as a surgical finding in his clinical case, a sign of perforation of the colon.<sup>(10)</sup>

Preoperative diagnosis is of great importance for planning the surgical technique. Bruce, in 1958, concluded that incarceration was the most significant diagnostic factor in a previously reducible inguinal hernia, which was attributed to two factors: the disproportionate size of the tumour compared to the diameter of hernia sac neck and the presence of inflammation and/or neoplastic extension of the tumour into the wall of the hernia sac.<sup>(17)</sup>

The routine study of the colon before any intervention is not justified, since it has not been shown that there is a relationship between cancer of the colon and hernias,<sup>(13)</sup> thus reserving this for hernias that have recently become symptomatic or with symptoms that lead to the suspicion of cancer of the colon.<sup>(4)</sup>

Opaque enema has been traditionally used in 6 cases (16.6%) to complete the study of an inguinal hernia with a dilated colon within it.<sup>(17,18)</sup> In the last 2 cases, CT was preferred as the most sensitive and easy to use test, even in emergency, and when the inguinal hernia was incarcerated. Colonoscopy, which must be used to confirm the diagnosis whenever surgery can be deferred, has the disadvantage of its very difficult technique in finding the colon within the inguinal hernia.<sup>(11,17)</sup>

**The difficult decision of the primary approach:** Inguinal, laparotomy or combined, will depend on the preoperative diagnosis, local conditions of the hernia and the patient. The most used approach in the majority of cases was combined, by the inguinal route and laparotomy after confirming the diagnosis, with the intention of curative treatment of the cancer and /or resolving local complications, such as perforation and abscess.

Someone defend the extended inguinal approach (Rutherford-Morrison oblique incision) as sufficient for a curative resection of the cancer in cases where there is no perforation or abscess, on being a good access for the left colon and to the inguinal region in patients of high surgical risk.<sup>(8,12,16)</sup>

Birolini defended repair using the pre-peritoneal approach according the Stoppa technique, which provides good access to the peritoneal cavity for resection of the cancer of the colon and the implanting of suitable bilateral pants prosthesis. Although the intrahernial colon cancer required performing a small inguinal incision to widen the external inguinal opening

and to be able to reduce the sigmoid contained in the hernia sac.<sup>(5)</sup>

In cases of inguinal hernia associated with intestinal contents, simple invagination of the hernia sac is not sufficient, as it needs to be opened and inspected, particularly if it is associated with an intestinal obstruction. The presence of blood or faeces in the hernia sac requires ruling out perforated colon cancer, and if the sac contents are already limited to the abdominal cavity or does not justify it, to investigate it using laparotomy.<sup>(8,15)</sup>

In our case the primary decision of a single inguinal approach was motivated firstly, due to the reasonable doubt of the radiology which made the primary diagnosis of a strangulated inguinal hernia, with doubtful tumour mass in the sigmoid, in a patient with a high surgical risk, in an emergency situation and with a giant scrotal-inguinal hernia with intestinal contents, made it difficult to be reduced by the abdominal approach. Once the diagnosis was confirmed during surgery and a resection of the tumour with sufficient margins being possible, the presence of probable liver metastasis (stage IV) made a more radical removal of the tumour by laparotomy unnecessary.

It seems to us that the inguinal approach is preferred choice, particularly in cases of incarcerated inguinal hernia and emergency surgery, as the best way to confirm the diagnosis and whether it is possible to remove the tumour by the same route to avoid the introduction of tumour cells into the inguinal canal in the event of perforating the tumour. In a second time, during the same surgical operation, if the conditions of the patient permit it or in deferred, laparotomy allows a more radical resection of the cancer of the colon and to treat complications such as peritonitis secondary to a perforation.

In conclusion on being presented with an incarcerated inguinal hernia, with intestinal contents inside it and a bowel obstruction, it is essential to make an estimated preoperative diagnosis using imaging techniques (ultrasound, CT, opaque enema, colonoscopy), to confirm the diagnosis and plan the surgery: type of anaesthesia (spinal/general), approach route (inguinal/abdominal) and treatment in one or two times of the colon cancer and the inguinal hernia.

## REFERENCES

1. McFayden BV, Mathis CR. Inguinal herniorrhaphy: complications and recurrences. *Semin. Laparosc. Surg.* 1994;1:128-40.
2. Lejar J. Neoplasmes herniaires et peri-herniaires. *Gaz. Hosp* 1889;62:801-11.
3. Yoell JH. Surprises in hernial sacs: diagnosis of tumors by microscopic examination. *Calif. Med.* 1959;91:146-8.
4. Pappas D, Romeu J, Dave PB, Subietas AS. Colonic carcinoma in an inguinal hernia sac: case report and review of the literature. *Mount Sinai J Med.* 1987;54:162-4.
5. Birolini C, Utiyama EM, Rodrigues AJ, Birolini D. The association of inguinal hernias and colon cancer. A technical strategy based upon three patients. *Hernia.* 1998;2:139-43.
6. Matsumotto G, Ise H, Inque H, Ogawa H. Metastatic Colon carcinoma found within an inguinal hernia sac: report of a case. *Surg Today.* 2000;30:74-77.
7. Boormans JL, Hesp W, Teune T, Plaisier P. Carcinoma of the sigmoid presenting as a right inguinal hernia. *Hernia.* 2006;10:93-6.
8. Slater R, Amatya U, Shorthouse AJ. Colonic carcinoma presenting as strangulated inguinal hernia: report of two cases and review of the literature. *Tech. Coloproctol.* 2008;12:255-8.
9. Gurer A, Ozdogan M, Ozlem N, Yildirim A, Kulacoglu H, Aydin R. Uncommon content in groin hernia sac, *Hernia.* 2006;10:152-5.
10. Gerhardt F. *Dtsch. Z. Chir. Ccl.* 1938:742.
11. Ruiz-Tobar J, Ripalda E, Beni R, Nistal J, Monroy C, Carda P. Carcinoma of the sigmoid colon in an incarcerated inguinal hernia. *Can. J. Surg.* 2009;52:31-2.
12. Rosal R, Dávila D, Olavarrieta L, Medrano J, Narbona B. *Cir. Española.* 1989;XLVI:740-2.
13. Avidan B, Sonnenberg A, Bhatia H, Aranha G, Schnell TG, Scotag SJ. Inguinal hernia is not a sign of colon cancer: results of a prospective screening trial. *Aliment Pharmacol Ther.* 2002;16:1197-201.
14. Benfatto G, Catania G, Tenaglia L, Lo Menzo E, Centoze D, Jiryis A. Abscess and cecum carcinoma in inguinal hernia: case report. *G. Chir.* 2006;27:262-4.
15. Sakorafas GH, Peros G. Obstructing sigmoid cancer in a patient with a large, non-reducible inguinal hernia: the obvious diagnosis is not always the correct one. *Eur. J. of Cancer Care.* 2008;17:72-3.
16. Kouraklis G, Kouskos E, Glinavou A, Rakopoulos J, Karatzas G. Perforated carcinoma of the sigmoid colon in an incarcerated inguinal hernia: report of a case. *Surgery today.* 2003;33:707-8.
17. Bruce AW, Stewart AM. Carcinoma of the colon occurring in an inguinal hernia. *British Institute of Radiology.* 1958;31:280-1.
18. Javors BR, Bryk D. Colonic obstruction within inguinal hernia. *J. Can. Assoc. Radiol.* 1981;32:162-3.
19. Tan GY, Guy RJ, Eu KW. Obstructing sigmoid cancer with local invasion in an incarcerated inguinal hernia. *ANZ. J. Surg.* 2003;73:80-2.