



## ORIGINAL ARTICLE

# IS TOPICAL NITROGLYCERIN SUPERIOR TO INTERNAL SPHINCTEROTOMY IN THE MANAGEMENT OF CHRONIC ANAL FISSURE?

By

Gouda El-labban, Galal El-Gazzaz, Emad Hokkam

Department of General Surgery, Faculty of Medicine, Suez Canal University, Ismailia, Egypt

Correspondence to Emad Hokkam, Email: ehokkam@gmail.com

### Abstract

**Aim:** To compare the effectiveness of local glyceryl trinitrate (GTN) versus internal sphincterotomy in the management chronic anal fissure.

**Methods:** Eighty patients with chronic anal fissure were enrolled in the study. They were divided into two groups; group (1) included 40 patients treated with topical GTN 0.2% on liposomal base applied to the anoderm twice daily and group (2) included 40 patients treated with internal sphincterotomy. We compared the effectiveness of both techniques in the management chronic anal fissure

**Results:** In group 1, healing of fissures occurred in 85% of patients after 8 weeks therapy. Headache as a side effect developed in 65% of patients. In group 2, healing occurred in 97.5% of patients after 8 weeks. Incontinence to flatus occurred in 3 patients (7.5%), mild soiling in 2 patients (5%) and one patient developed wound infection. All complications were temporary except for one patient with persistent incontinence to flatus. At the end of 8 weeks both groups were equal in pain scoring.

**Conclusion:** Topical GTN should be the initial treatment in chronic anal fissure while internal sphincterotomy may be reserved for patients who not respond to GTN therapy and those with severe pain (as healing is faster with sphincterotomy).

**Keywords:** Fissure in ano, chemical, nitroglycerin.

### INTRODUCTION

Anal fissure is one of the most painful conditions encountered in surgical practice, and cause considerable morbidity and reduction in quality of life.<sup>(1)</sup> It is a linear tear in the lining of the distal anal canal below the dentate line. It affects all age groups, with equal

incidence across the sex. The classical presentation is anal pain during or after defecation accompanied by the passage of blood with stool. In addition, purities ani may occur in up to 50% of cases.<sup>(2)</sup>

Subcutaneous lateral internal sphincterotomy remains the golden standard for management of chronic anal

fissure because of its simplicity, rapid healing and low recurrence rate. Disadvantages of lateral internal sphincterotomy include; disturbance of continence, bleeding, fistula, abscess, cost and time of recovery.<sup>(3)</sup> These have led to search for another mode of therapy or pharmacological way to create a temporary or reversible sphincterotomy, one that would lower the sphincter pressure only until the fissure healed.<sup>(4)</sup>

Many topical pharmacological agents have been introduced to treat the chronic anal fissure in nonsurgical way.<sup>(5-7)</sup> Local glyceryl trinitrate GTN is the most famous of them. It can reduce the increased anal canal pressure caused by the hypertonic internal anal sphincter and improve the anodermal blood flow, as the surgical internal sphincterotomy do. Reversible chemical sphincterotomy produced by local GTN could be used to enhance healing of the anal fissure with minimal side effects thus avoid the need for operative intervention.<sup>(8)</sup>

Topical GTN can be used with liposomal base as a delivery system, liposomes are most useful for being able to transfer and deliver active ingredient to the application site effectively and rapidly.<sup>(9)</sup> In view of this, the optimal therapeutic strength could be achieved by adding GTN to liposomal base in the treatment of chronic anal fissure. In the present work, we aimed to study the effectiveness of local GTN versus surgical internal sphincterotomy (as a gold standard procedure) in the management of chronic anal fissure.

## PATIENTS AND METHODS

This study was carried out as a clinical prospective randomized controlled study. It was carried on patients who were diagnosed clinically as chronic anal fissure and attended to the surgery outpatient clinic, Suez Canal University Hospital. Patients were excluded from the study in cases of presence of any other anal problem (piles or fistulae), any previous anal surgery, patients with systemic diseases (diabetes mellitus, chronic liver disease and collagen diseases), and patients under treatment with nitrates for other diseases, e.g. ischemic heart diseases. Pregnant and children were also excluded from the study.

All patients were subjected to full detailed history stressing on symptoms of anal fissure including anal pain during and after defecation, bleeding, discharge and itching. Possible cause of anal fissure as history of constipation and anal trauma were also reported. Digital rectal examination was performed to assess the spasm and tenderness. The presence of linear ulcer in the distal anal canal, indurations and sentinel skin tag, with the previous symptoms were enough for clinical diagnosis.

Chronic anal fissure was diagnosed if duration of the symptoms (pain-bleeding) was more than 6 weeks with fibres of the internal anal sphincter visible at the base of the fissure. Associated pathology may include marginal indurations, sentinel 'pile' distally and a fibro-epithelial polyp at the apex.<sup>(10)</sup> Each patient in the study was

informed in detail about the aim of the work and the type of the procedure. A fully informed written consent was obtained from him/her prior to the study.

Eighty patients were enrolled in the study; they were randomly allocated to one of two groups (Group 1 & Group 2) using the odd and even number randomization technique.

**Group (1)**, included 40 patients with chronic anal fissure and subjected to treatment with local GTN 0.2% cream (in liposomal base). Each patient was instructed to apply about 0.5 g "per size amount" of GTN manually at distal end of the anal canal (lower half of the anal canal verge) twice daily for eight weeks. All patients were advised to receive stool softeners and fiber supplements diets. Patients with persistent fissure at the end of the treatment period and those who cannot tolerate treatment with the GTN were subjected to surgical sphincterotomy.

**Group (2)**, included 40 patients with chronic anal fissure and subjected to surgical treatment with lateral internal sphincterotomy. All patients were treated by the same surgeons using a uniform method of lateral internal sphincterotomy in the lithotomy position. The technique involves insertion of an anal retractor which leads to stretching of the distal internal sphincter. The intersphincteric groove, which marks the distal end of the internal sphincter, becomes easily palpable. A narrow blade scalpel is introduced through the perianal skin at the left lateral aspect of the canal between the anoderm and the internal sphincter. When the tip reaches the dentate line, the blade is turned outwards, and the internal sphincter muscle is divided with the blade. Direct gentle pressure was applied to the site of the division for few minutes to assure perfect haemostasis.<sup>(11)</sup>

Maximum anal resting pressure MARP was measured in every patient in each group before the onset of treatment and at a steady state after 8 weeks. All patients in each group were followed up at 2-weeks intervals for 8 weeks. In each follow up visit, the patient was evaluated for the following:

- 1- Pain: as assisted by visual analogue score (VAS). Patients were asked to indicate a point on 100 mm line, one end of the line represent no pain on defecation and the other represent worst pain that they could not tolerate.
- 2- Presence of bleeding.
- 3- Fissure healing: the anus was examined by inspection to assess healing of the fissure which means its complete epithelization.
- 4- Appearance of any adverse effect.

All patients were followed up for three months for evidence of recurrence of the fissure and the presence of possible side effects.

## RESULTS

Eighty patients were enrolled in the study. They were divided into two groups. Group one (40 patients) were subjected to treatment with local GTN 0.2% cream while group two (40 patients) were subjected to surgical treatment of the fissure with lateral internal sphincterotomy.

In group 1, sixteen patients (40%) were male and the other 24 patients (60%) were females. The age ranged from 18 to 58 years with median age of 36 years. Those who presented with anal pain were 40 patients (100%), with anal pain and constipation were 28 patients (70%) and with anal pain and bleeding were 16 patients (40%). Thirty five patients (87.5%) have posterior anal fissure, 4 patients (10%) have posterior and anterior anal fissure and one patient (2.5%) has anterior anal fissure.

In group 2, fourteen patients (35%) were males and 26 patients (65%) were females. The age ranged from 20 to 60 years with median age of 38 years. Those who presented with anal pain were 40 patients (100%), with anal pain and constipation were 30 patients (75%) and with anal pain and bleeding were 14 patients (35%). Thirty one patients (77.5%) have posterior anal fissure and 9 patients (22.5%) with anterior and posterior anal fissure.

The main pre treatment MARP was  $123 \pm 46$  cm H<sub>2</sub>O in group (1) while it was  $119 \pm 39$  cm H<sub>2</sub>O in group (2). Both values were comparable to each other. The mean value of MARP was dropped by 41.5% to reach  $72 \pm 31.1$  cm H<sub>2</sub>O by the end of eight weeks in group 1; it was statistically significant (P value < 0.0001). In group 2, the mean MARP was dropped by 42.9% to reach  $68.2 \pm 31.3$  cm H<sub>2</sub>O after eight weeks postoperatively; it was also statistically significant (P value < 0.0001). The difference in reduction of MARP between topical GTN and sphincterotomy was not statistically significant showing that both modalities of treatment were equally effective in reducing the MARP in chronic anal fissure.

By the end of the 8th week, the mean pain score recorded from patients in group (1) fell from  $77 \pm 21$  to  $6 \pm 4$ . Most of the patients (39/40) had no bleeding. The fissures were completely healed (by inspection) in thirty four patients (85%). At the beginning of the treatment; 26 patients (65%) developed headache as a side effect but it decreased gradually by time till no patients had headache after the 6th week. Only one patient developed recurrence after 3 months of follow up. The six patients who did not respond to GTN therapy together with the patient who developed recurrence were subjected to surgical sphincterotomy.

After two months postoperatively, the mean pain score of the patients in group (2) decreased from  $82 \pm 02$  to  $4 \pm 3$ . No patients had bleeding. The fissures were completely healed (by inspection) in thirty nine patients (97.5%). Although some complications has been reported in the

early postoperative period in the form of incontinence to flatus, (7.5%), mild soiling (5%) and wound infection (2.5%), none of them was persistent after 3 months except for one patient who had incontinence to flatus. Detection of the complications was achieved by the patient's complaint and per rectal examination.

When comparing both groups, we found that the two mean pain score were comparable to each other by the end of the 8th week. However, the mean pain score in group 2 dropped faster than that of group 1 (Fig. 1). This clearly indicates that lateral internal sphincterotomy relive pain much earlier as compared to GTN therapy. Although bleeding stopped in both groups by the end of the treatment period, it had much time to stop in group 2 than group 1. As regards fissure healing; GTN was comparable to lateral internal sphincterotomy (34 patients with GTN versus 39 patients with sphincterotomy (P= 0.261) (Fig 2).

## DISCUSSION

Most patients with a chronic anal fissure have elevated resting anal pressures caused by hypertonicity of the internal anal sphincter and this seems to play an important role in pathogenesis of anal fissure. Local ischemia may also be important, as there is a relative hypoperfusion at the posterior commissure of the anal canal in most people.<sup>(12)</sup>

The aim of treatment is to reduce the anal hypertonia, which may improve the anodermal blood flow and heal the fissure. For a long time, lateral internal sphincterotomy was the gold 'standard' in treatment, producing rapid symptom relief and healing rates of over 90%, but it is now less popular as disturbances in continence can occur in up to 30 % of patients.<sup>(13)</sup> This has led to the search for non surgical alternative to lower the resting anal pressure and to heal the fissure without threatening anal continence.<sup>(14)</sup>

Recognition of organic nitrates as the non- adrenergic, non- cholinergic neurotransmitter mediating relaxation of the internal anal sphincter has initiated the wide-spread use of organic nitrates in the treatment of chronic anal fissure. These agents are metabolized at a cellular level to release NO which, in turn, mediate relaxation of the internal anal sphincter by increasing cGMP level within the smooth muscle cells.<sup>(15)</sup>

The present study compared GTN therapy to lateral internal sphincterotomy in the management of chronic anal fissure. We found that both techniques reduce the MARP effectively and without statistical significance. The same finding is also obtained by Mishra et al.<sup>(8)</sup> Many other studies reported that topical GTN ointment brought about a dramatic drop in the resting pressure in the upper anal canal<sup>(16,17)</sup> which makes it superior to other agents like xylocaine or proctosedyl.<sup>(18)</sup>

Lund and Scholefield<sup>(19)</sup> and Jonas et al<sup>(20)</sup> showed that

twice application of topical GTN heals two-third of fissures after eight weeks. Our study has a relative high success rate (85%); it may be attributed to the use of liposomal base which increase penetration of GTN in the internal anal sphincter.

On the other hand, Hyman and Cataldo<sup>(21)</sup> found that topical GTN was only effective in approximately one-

half of patients and often cause headache (75%) than treat the symptoms. This study has a very high incidence of adverse reaction than our study and we think that it is attributed to the high concentration of GTN (0.3%) than ours (0.2%) and also for being applied to the anoderm three times per day compared to 2 times only in our study.

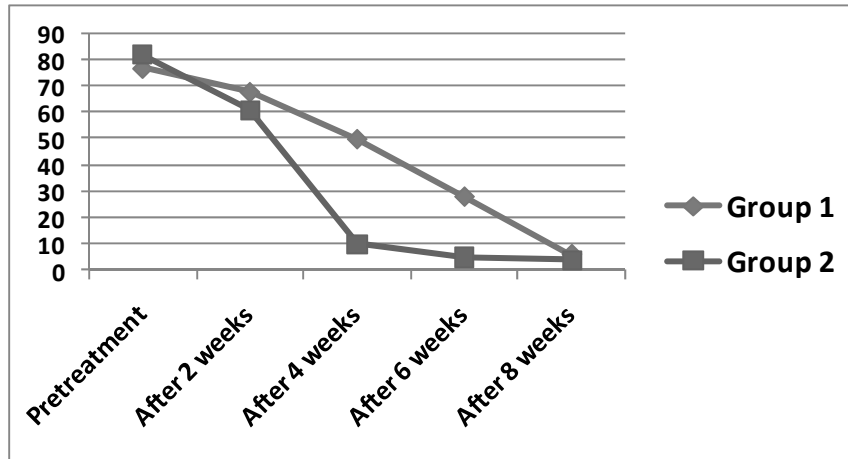


Fig 1. Pain score improvement in the two groups.

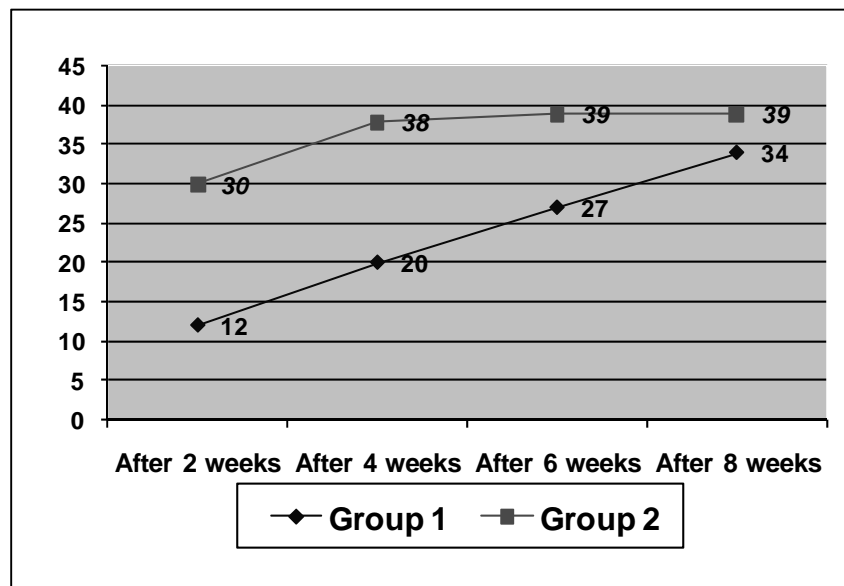


Fig 2. Healing of the fissure in the two groups.

Our study have shown that all patients in both groups had reported a dramatic reduction in mean pain score which is consistent with the study Khanzada and Samad<sup>(22)</sup> who reported 96% pain relief in GTN group as compared to 92% in sphincterotomy group after 6 weeks.

In agreement with our study, Oettle<sup>(23)</sup> randomized 24 patients for treatment with sphincterotomy or local GTN; all 12 patients healed following sphincterotomy while 10 of 12 patients healed with local GTN (P=0.239). However, a multicenter trial involving 82 patients and conducted by Richard et al<sup>(24)</sup> concluded that lateral

internal sphincterotomy was superior to topical GTN in the treatment of chronic anal fissure. The same was also obtained by another multicenter, randomized, controlled trial by Brown et al.<sup>(25)</sup> It may be due to the extremely low concentration of the GTN (.25%) used in both studies.

The present study showed that sphincterotomy relieves pain much earlier as compared to GTN, but after 4 weeks of treatment, pain relief in the two groups is comparable. Healing in the sphincterotomy group was also much earlier as compared to GTN but this initial advantage was lost by the end of the 8th week. Lateral internal sphincterotomy has a significant incidence of minor short-term complications in the form of incontinence, soiling and wound infections which are usually self-limited. It also requires surgical expertise, theater, time, and day care beds. GTN, on the other hand, is a safe and simple procedure with possible mild and tolerable headache.

Because topical GTN is safe and well-tolerated, and because pain relief and healing are comparable with lateral internal sphincterotomy, we suggest that conservative treatment with GTN should be the initial treatment for chronic anal fissure. Lateral internal sphincterotomy should be reserved for patients with severe disabling pain (because pain relief is much faster), and for those who not respond to conservative therapy with GTN.

## REFERENCES

1. Leah S, Rick G. Are non-surgical treatments for anal fissure effective? *Can Fam Physician*. 2000;46:1063-5.
2. Sailer M, Bussen D, Dubus ES, Fuchs KH, Thiede A. Quality of life in patient with benign anorectal disorder. *Br J Surg*. 1998;85:1719-26.
3. Rotholtz NA, Bun M, Mauri M, Bosio R, Peczan CE, Mezzadri NA. Long term assessment of fecal incontinence after lateral internal sphincterotomy. *Tech Coloproctol*. 2005;9:115-8.
4. Lund JN, Scholefield JH. The etiology and treatment of anal fissure. *Br J Surg*. 1996;83:1335-44.
5. Sajid MS, Vijaynagar B, Desai M, Cheek E, Baig MK. Botulinum toxin vs glyceryltrinitrate for the medical management of chronic anal fissure: a meta-analysis. *Colorectal Dis*. 2008;10:541-6.
6. Tranqui P, Trottier DC, Victor C, Freeman JB. Nonsurgical treatment of chronic anal fissure: nitroglycerin and dilatation versus nifedipine and botulinum toxin. *Can J Surg*. 2006;49:41-5.
7. Medhi B, Rao RS, Prakash A, Prakash O, Kaman L, Pandhi P. Recent advances in the pharmacotherapy of chronic anal fissure: an update. *Asian J Surg*. 2008;31:154-63.
8. Mishra R, Thomas S, Maan M, Hadke NS. Topical nitroglycerin versus lateral internal sphincterotomy for chronic anal fissure. *ANZ J Surg*. 2005;75:1032-5.
9. Wilson A, Pitt B, Song Li. Complex role of CpG liposomal delivery of DNA and oligonucleotides. *Biosci Reps*. 2002;22:309-22.
10. Bhardwaj R, Parker MC. Modern perspectives in the treatment of chronic anal fissures. *Ann R Coll Surg Engl*. 2007;89:472-8.
11. Kiyak G, Korukluoğlu B, Kuşdemir A, Şişman IC, Ergül E. Results of lateral internal sphincterotomy with open technique for chronic anal fissure: evaluation of complications, symptom relief, and incontinence with long-term follow-up. *Dig Dis Sci*. 2009;54:2220-4.
12. Lund J, Binch C, McGrath J, Sparrow RA, Scholefield JH. Topographical distribution of blood supply to the anal canal. *Br J Surg*. 1999;86:496-8.
13. Khubchandani I, Reed J. Sequelae of internal sphincterotomy for chronic fissure in ano. *Br J Surg*. 1989;76:431-4.
14. Jonas M, Scholefield J. Anal fissure and chemical sphincterotomy. *Recent advances in surgery*, Eds Taylor I and Jonsone CD, Churchill Livingstone. 2001;24:115-24.
15. Carapeti E, Kamm M, McDonald P, Chadwick SJ, Melville D, Phillips RK. Randomised controlled trial shows that glyceryl trinitrate heals anal fissures, higher doses are not more effective and there is a high recurrence rate. *Dis Colon Rectum*. 1999;44:727-30.
16. Guillemot F, Leroi H, Lone YC, Rousseau CG, Lamblin MD, Cortot A. Action of in situ nitroglycerin on upper anal canal pressure of patients with terminal constipation. A pilot study. *Dis Colon Rectum*. 1993;36:372-6.
17. Loder PB, Kamm MA, Nicholls R, Phillips RK. Reversible chemical sphincterotomy by local application of glyceryl trinitrate. *Br J Surg*. 1994;81:1386-94.
18. Maan M, Mishra R, Thomas S, Hadke NS. Randomized, double blind trial comparing topical nitroglycerine with xylocaine and Proctosedyl in idiopathic chronic anal fissure. *Indian J Gastroentero*. 2004;23:91-3.
19. Lund J, Scholefield J. A randomized prospective, double blinded, placebo controlled trial of glyceryl trinitrate ointment in the treatment of anal fissure. *Lancet*. 1997;349:11-4.
20. Jonas M, Amin S, Wright JW, Neal KR, Scholefield JH. Topical 0.2 % glyceryl trinitrate ointment has short-lived effect on resting anal pressure. *Dis Colon Rectum*. 2001;44:1640-3.
21. Hyman N, Cataldo P. Nitroglycerin ointment for anal fissure. Effective treatment or just a headache? *Dis Colon Rectum*. 1999;42:383-5.
22. Khanzada TW and Samad A. Chronic anal fissure; topical glyceryl trinitrate versus lateral internal Sphincterotomy. *Professional Med J*. 2007;14:318-22.

23. Oettle G. Glyceryl trinitrate vs. sphincterotomy for treatment of chronic fissure in ano: A randomized, controlled trial. *Dis Colon Rectum*. 1997;40:1318-20.
24. Richard CS, Gregoire R, Plewes EA, Silverman R, Burul C, Buie D, et al. Internal sphincterotomy is superior to topical nitroglycerin in the treatment of anal fissure; results of randomized, controlled trial by Canadian Colorectal Surgical Trials Group. *Dis Colon Rectum*. 2000;43:1048-57.
25. Brown CJ, Dubreuil D, Santoro L, Liu M, O'Connor BI, McLeod RS. Lateral internal sphincterotomy is superior to topical nitroglycerin for healing chronic anal fissure and does not compromise long-term fecal continence: Six-year follow-up of a multicenter, randomized, controlled trial. *Dis Colon Rectum*. 2007;50:442-8.