

SURGICAL QUIZ

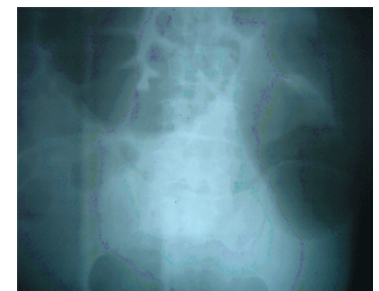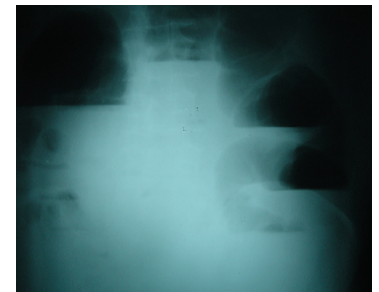
By
Egyptian Group for Colorectal Surgeons
Ahmed A Abou-Zeid

Professor of Surgery Ain Shams University

Email: ahabaz@hotmail.com

Erect and supine abdominal X- ray of a 63 year old male patient complaining of absolute constipation and abdominal distension for 3 days. History was otherwise insignificant. On examination the abdomen was distended but soft. PR examination was insignificant. What would be the next action?

1. Conservative treatment: NG tube, iv fluids, monitoring
2. Urgent exploration
3. Urgent contrast enema and proceed
4. Investigate for GI pathology
5. Laxatives and send home



Send your answer to ejs@ess-eg.org

The correct answer and a short comment on the condition will be presented in the next issue of the journal.

The correct answer for previous Photo Quiz (Vol 28, No 1, January, 2009)

The right answer is: (1) Surgery is essential.

We can notice in this CT that the urinary bladder contains air, which indicates the presence of a colovesical fistula. This is a known complication of diverticular disease of the colon. In the presence of colovesical fistula, surgery is essential because the fistula will neither close spontaneously nor will it close by any conservative measure. Surgery is indicated even if the patient is asymptomatic because the fistula represents a continuous source of urinary tract infection that might eventually end in renal failure.

