

Radiographic Interpretations of Some Cardiac Affections in Dogs

Torad, F.A.

Dept. of Surgery, Anesthesiology and Radiology, Fac. of Vet. Med, Cairo University, Egypt.

Received: 06/09/2009

Accepted: 17/09/2009

SUMMARY

Radiographic examination is still a valuable routine procedure for diagnosing cardiopulmonary diseases and assessing their response to treatment.

Methodology: In the present study, thoracic radiography was carried out on 47 clinical cases of dogs that suffered from cardiac problem- and five apparently healthy mongrel dogs that were used as a control for normal radiography of the canine heart. The diseased dogs were of both sexes and of ages that ranged between 45 days and 12 years.

Results: The recorded affections were; persistent right aortic arch (2), microcardia (2), left atrial dilatation (6), right ventricular dilatation (9), generalized cardiomegaly (18), pericardial effusion (8), hypertrophic cardiomyopathy (1) and pneumopericardium (1).

All radiographic findings of both normal and diseased canine hearts were described.

Conclusion: thoracic radiography still constitutes the cornerstone for diagnosing and evaluating cardiopulmonary diseases through providing direct and immediate information about cardiac size and shape, and indirectly through assessing the cardiopulmonary circulation which reflects the degree of heart failure.

INTRODUCTION:

The heart is the largest structure of the mediastinum, and the dominant organ within the thoracic cavity. The size, position and shape of the cardiac silhouette vary greatly among different species, breeds and individuals (Hamlin, 1960, Wyburn and Lawson, 1967; Buchannan, 1972 and Suter and Lord, 1984).

Radiographic examination is a routine procedure for diagnosing cardiac diseases and assessing the response to treatment (Suter and Lord 1971). Radiographic findings are not consistently specific enough to lead to derivation of a definitive diagnosis without supportive clinical evidence (Schelling, 2001).

The heart chambers can be roughly defined by a line connecting the apex to the tracheal bifurcation and a second line perpendicular to the base-apex axis and positioned at the level of the ventral aspect of the caudal vena cava (Tilley and Goodwin, 2001). The cardiac width has been defined as between 2.5 intercostal spaces in deep-chested conformation breeds as Setters, Afghans and Collies and 3.5 intercostal spaces in barrel-chested conformation breeds as Dachshunds and Bulldogs (Schelling, 2001).

Owens et al (1982) mentioned that the most common congenital heart defects are; patent ductus arteriosus, pulmonic stenosis, aortic stenosis, ventricular septal defect, tetralogy of fallot and persistent right fourth aortic arch. Lord and Suter (1999) added that, the most common acquired heart diseases are mitral insufficiency, tricuspid insufficiency, hypertrophic cardiomyopathy and pericardial effusion.

Persistent right aortic arch is a vascular ring anomaly causes stricture of the esophagus

where most dogs regurgitate solid food and usually noted soon after weaning (Owens et al, 1982 and Larcher et al 2006). Radiographically, the cardiac silhouette is normal with enlarged esophagus cranial to the cardiac base (Suter and Lord, 1984).

Schwartz et al (1971); Silverman and Suter (1975) and Feldman (1977) reported that reduced cardiac size (microcardia) is encountered less commonly than cardiomegaly. The majority of animals with small cardiac silhouette are either cachectic or have circulatory problems.

Tilley and Goodwin (2001) stated that the radiographic signs of left atrial enlargement include dorsal elevation of the cardiac portion of the trachea and carina, enlargement and straightening of the caudodorsal portion of the cardiac silhouette and loss of the caudal waist.

Rawlings and Lewis (1977) and Boujon et al (2003) found that the radiographic signs of right ventricular enlargement include increased sternal contact of the cranial cardiac margin, with elevation of the cardiac apex from the sternum and enlarged cardiac silhouette at the 6 to 11 o'clock position.

Suter and Lord (1984) stated that cardiac enlargement and cardiomegaly are neutral terms which cover both an increased size due to a growth in muscle mass (hypertrophy) and an

enlarged chamber size due to an increased filling with blood (dilatation).

Radiographic signs of pericardial effusion include, generalized enlargement of cardiac silhouette in a basket ball conformation, increased sternal contact and pleural effusion secondary to cardiac tamponade (Buchanan and Bucheler, 1995; Kittleson and Kienle, 1998 and Fewes et al, 2008).

Canine cardiomyopathy characterized by generalized cardiomegaly, marked left atrial dilatation and may show evidence of left heart failure (pulmonary edema) and/or right heart failure (pleural effusion). In dorsoventral projection, the cardiac silhouette is enlarged and assumes a "Valentine" shape (Harpster, 1991; Isachc, 1995; Sisson et al, 2000 and Abraham et al, 2007).

The purpose of this study is to direct the attention of veterinarians to the role of radiography in diagnosis and differentiation of some cardiac diseases and to describe the specific radiographic changes of these diseases in dogs.

MATERIALS AND METHODS

Forty seven dogs were diagnosed clinically as suspected to have cardiac diseases. These dogs were among the clinical cases admitted to both the surgery clinic at the Faculty

of Veterinary Medicine, Cairo University and some private clinics during the period between October 2005 and October 2008.

These dogs were of both sexes and their ages were varied between 45 days and 12 years. These dogs were of different breeds including; German shepherd (22), Griffon (12), Great Danes (6), Bull Mastiff (2), Irish Setter (2), Yorkshire Terrier (2) and Boxer (1).

Case history, clinical examination and radiography were done for each clinical case and all data were recorded.

Ventro-dorsal and right-lateral views were taken for each dog. Exposure factors (kilovolt and milliampere) were justified for each animal according to its body weight and position taken. Positive contrast radiography (barium meal) was used in two cases suspected to have persistent right aortic arch in order to clarify the status of the esophagus.

Five adult apparently healthy mongrel dogs were used as a model to clarify the normal radiographic appearance of the canine heart.

RESULTS

NORMAL RADIOGRAPHIC APPEARANCE OF CANINE HEART:

Right lateral thoracic radiograph revealed that, the right cardiac chambers are positioned more cranially while the left

chambers are positioned caudally. Division of the four cardiac chambers can be estimated by drawing two lines perpendicular on each other.

The dorsal cardiac margin includes both atria, pulmonary arteries and veins, the cranial and caudal vena cavae and the aortic arch. The cranial border is formed by both the right ventricle and right atrial appendage, resulting in the radiographically defined cranial waist. The caudal margin is formed by the left atrium and left ventricle, with the atrioventricular junction defined as the radiographic caudal waist. The aorta is seen superimposed over the right atrium. The aortic arch extends caudodorsally to form the descending aorta. (Fig.1).

Ventro-dorsal radiograph showed that, the canine heart appears as an elliptical opacity with its base-apex axis orientation approximately 30 degrees to the left of the midline (Fig.2). The aortic arch is within the mediastinum and is invisible.

Congenital heart diseases:

Vascular ring anomalies: Persistent right aortic arch:

Persistent right aortic arch was recorded in 2 dogs. The first was one year old German shepherd while the second was 45 days old Yorkshire terrier. Both dogs were suffering from persistent regurgitation shortly after feeding which noted soon after weaning in the Yorkshire puppy.

Contrast radiography revealed, the presence of esophageal dilatation cranial to the heart (Fig.3). The dilated esophagus depresses the trachea and heart ventrally. The semisolid contrast medium causes a larger dilatation of the esophagus in the prestenotic area and a marked dilatation in the post stenotic region (Fig.4). The saccular, contrast-filled cranial esophagus, which extends into the cervical region narrows abruptly at the level of the fourth intercostal space dorsal to the heart.

Acquired heart diseases:

Microcardia (hypovolemic heart or shocked heart):

Microcardia was incidentally reported in 2 German shepherd dogs. Radiographically, the heart appeared smaller than normal as the cardiac silhouette takes up a smaller percentage of the available space. The heart appeared more vertical and narrower (approximately 2 intercostal space in width) (Fig.5 and 6). One dog showed mild degree of pleural effusion (Fig. 6).

Left atrial dilatation:

Left atrial dilatation was recorded in 6 dogs. All cases were aged dogs (8-12 years), and of different breeds. Abnormal heart sounds were recorded. Radiographically, the caudal border appeared straighter, as the left atrium enlarged and the distance between the carina and the caudal waist increased. The caudal waist

appeared more shallow or lost and the caudal border appeared slightly more perpendicular. The caudal portion of the trachea and carina elevated dorsally and consequently dorsal displacement of the main stem bronchi (Fig. 7).

Right ventricular dilatation:

Right ventricular dilatation was diagnosed in 9 cases. The animals were suffering dyspnea and frequent cough. Radiographically, they showed increased sternal contact of the cranial cardiac margin, elevation of the cardiac apex from the sternum and rounding of the cardiac silhouette with increased cardiac width (Fig.8). In ventro-dorsal view, the cardiac silhouette showed enlargement at 6 to 11 o'clock position, the right ventricle assumes an inverted "D" sign with shifting of the cardiac apex to the left (Fig.9).

Generalized cardiomegaly:

Generalized cardiomegaly was recorded in 18 dogs. The animals were aged dogs (7-12 years) and of different breeds. The dogs were suffering dyspnea, open mouth respiration, exercise intolerance and some cases showed cyanosed mucous membranes and syncope. Radiographically, the dogs with generalized cardiomegaly showed variable degrees of enlargement of two or more cardiac chambers. In moderate cardiomegaly, the cardiac silhouette appeared enlarged with increased cardiac width (approximately 3.5:4 intercostal space),

increased sternal contact and the trachea appeared dorsally elevated (Fig 10). In severe cardiac enlargement, the cranial heart border appeared straighter and more perpendicularly oriented, the caudal heart border also appeared straighter. The caudal waist of the heart appeared shallow and the trachea appeared parallel to the thoracic spines where the distance between the trachea and the thoracic spines appeared greatly reduced (Fig. 11).

Pericardial effusion:

Pericardial effusion was diagnosed in 8 cases. Dogs were of different ages (2-10 years) and of different breeds. Radiographically, the dogs with pericardial effusion showed generalized enlargement of the cardiac silhouette in a "basket ball" conformation, elimination of normal cardiac margins on all views, increased sternal contact of the cranial cardiac margin and convex bulging of the caudal margin with dorsal elevation of the trachea (Fig. 12).

Hypertrophic cardiomyopathy:

One case of hypertrophic cardiomyopathy was recorded in a 2-year-old Yorkshire terrier. Radiographically, the cardiac silhouette assumes a "Valentine" shape with marked right atrial dilatation. The lung opacity increased with congestion of pulmonary vessels (Fig.13).

Pneumopericardium:

One case of pneumopericardium was incidentally recorded in a German shepherd dog. The dog suffered pneumothorax and the

pericardium appeared as radio-opaque line surrounding the heart and separated from the cardiac silhouette by very narrow radiolucent space (Fig. 14).

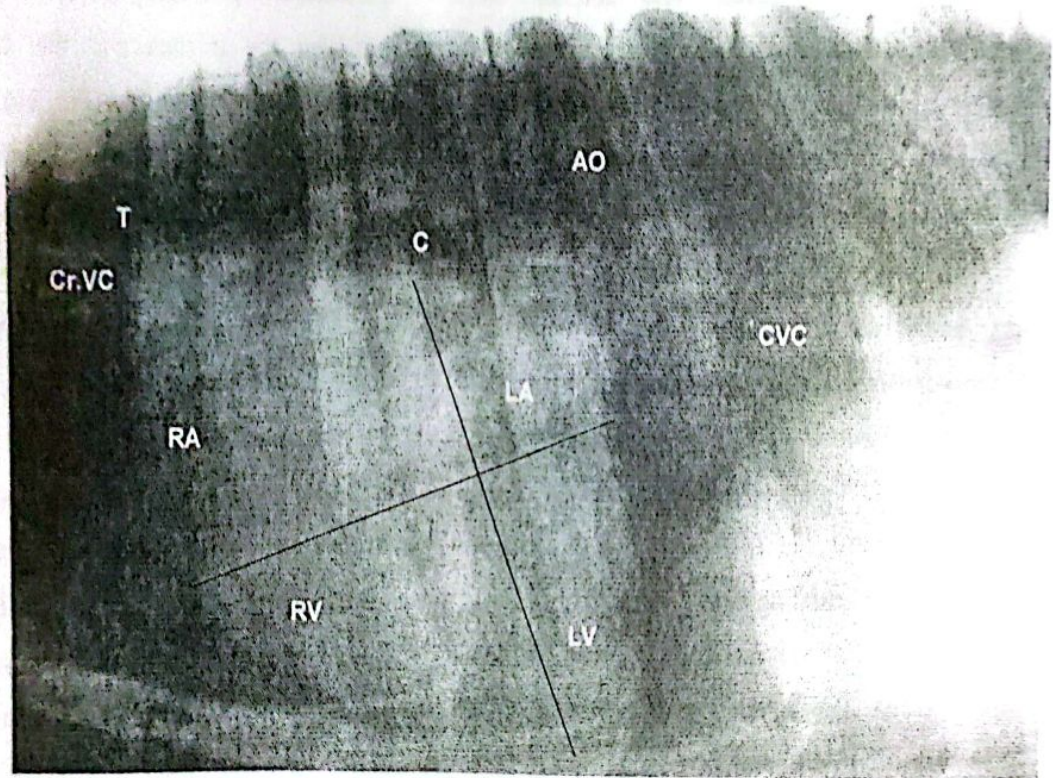


Fig.(1): Normal right lateral thoracic radiograph of a dog: Cranial vena cava(Cr.VC), Trachea(T), Right atrium(RA), Left atrium(LA), Right ventricle(RV), Left ventricle(LV), Carina(C), Caudal vena cava(CVC) and Aorta(AO).

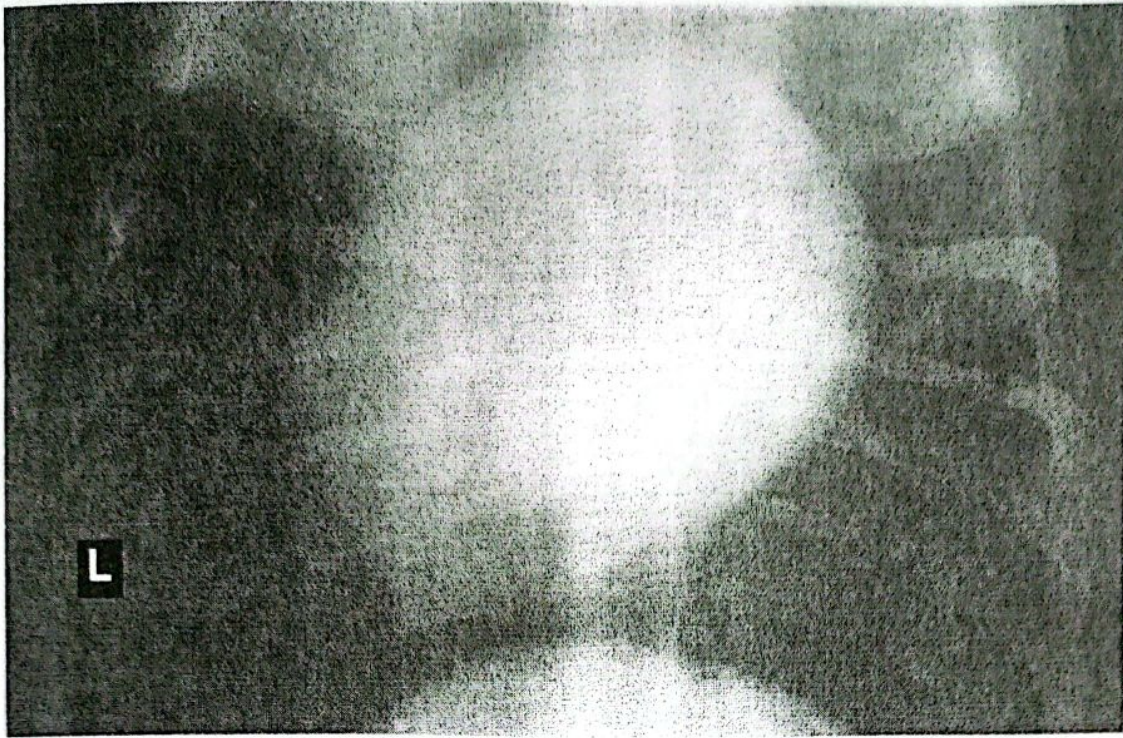


Fig.(2): Normal ventro-dorsal thoracic radiograph of a dog. The cardiac apex shifted to the left side.

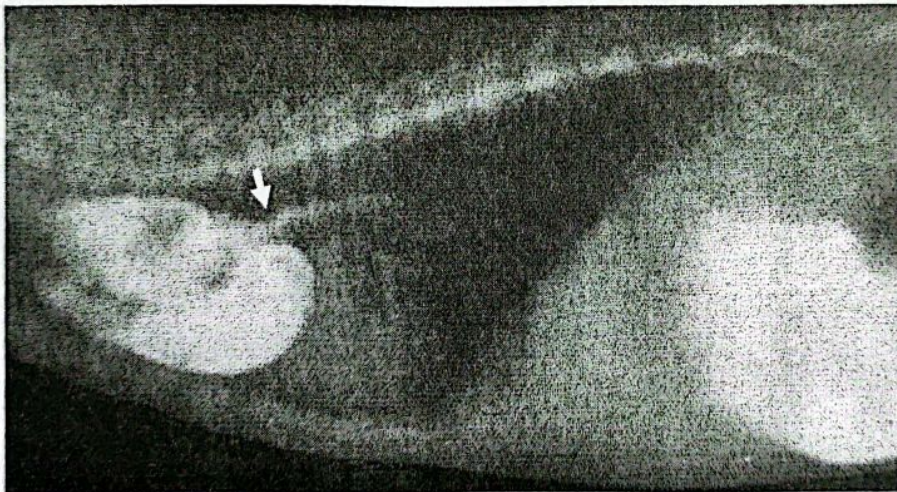


Fig.(3): Right-lateral thoracic radiograph of a 45-day-old Yorkshire puppy with vascular ring anomaly showing a prestenotic esophageal dilatation, narrowed region near the cranial heart base (arrow) with normal post cardiac esophagus.

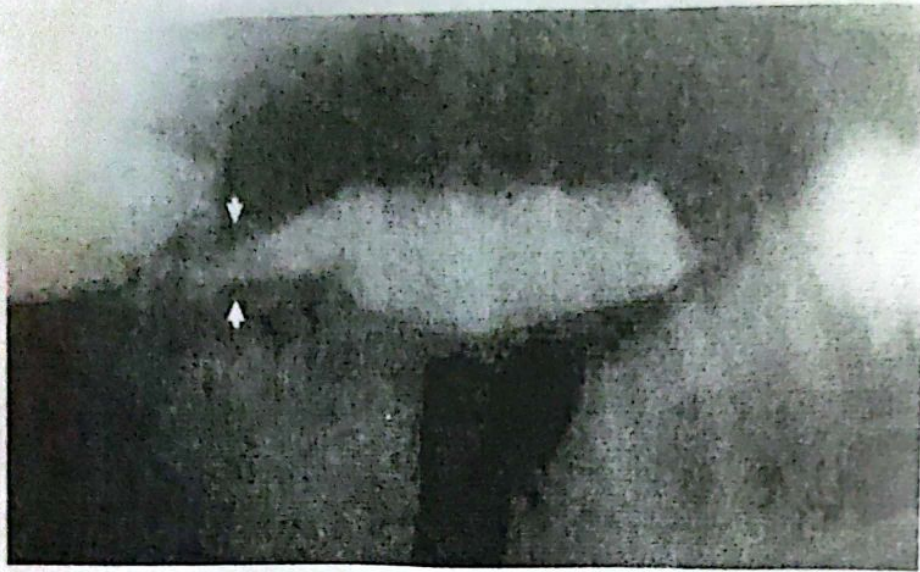

Fig.(4): Right lateral thoracic radiograph of one-year-old German Shepherd dog with persistent right aortic arch showed a large dilatation of the esophagus in the prestenotic area and a marked dilatation in the poststenotic region. The esophagus narrows abruptly at the level of fourth intercostal space dorsal to the heart (arrows).

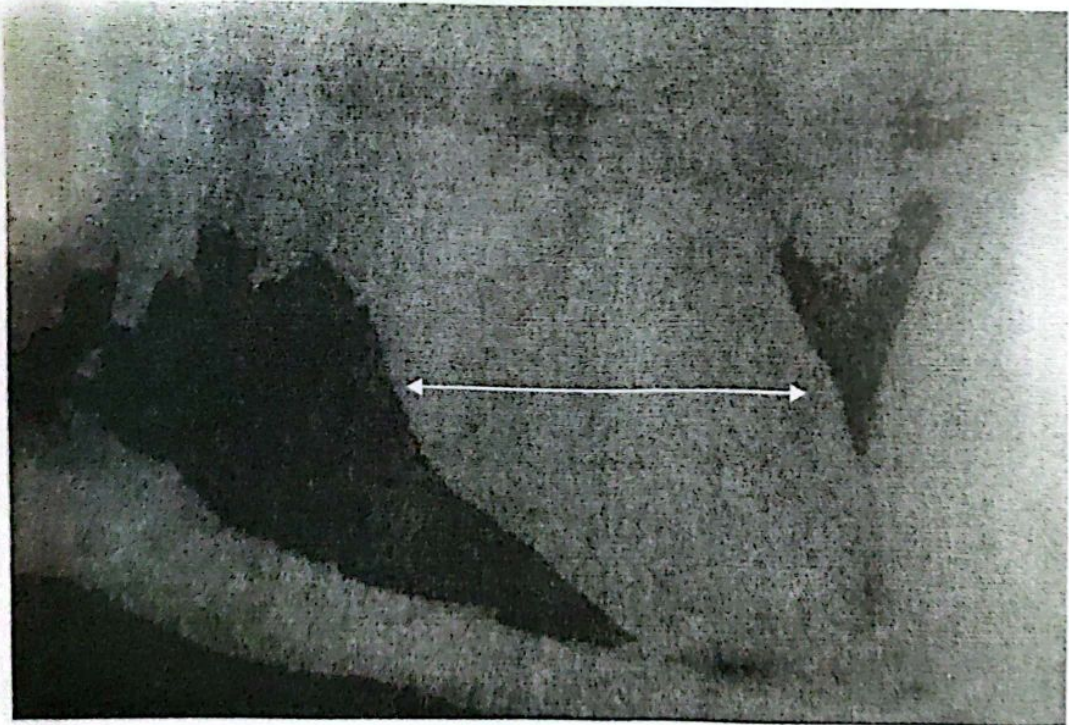


Fig. (5): Right lateral thoracic radiograph of a 3-year-old German shepherd dog showed microcardia. The heart appears small, approximately 2 intercostal spaces in width (white line). Notice that the cardiac apex is separated from the sternum.

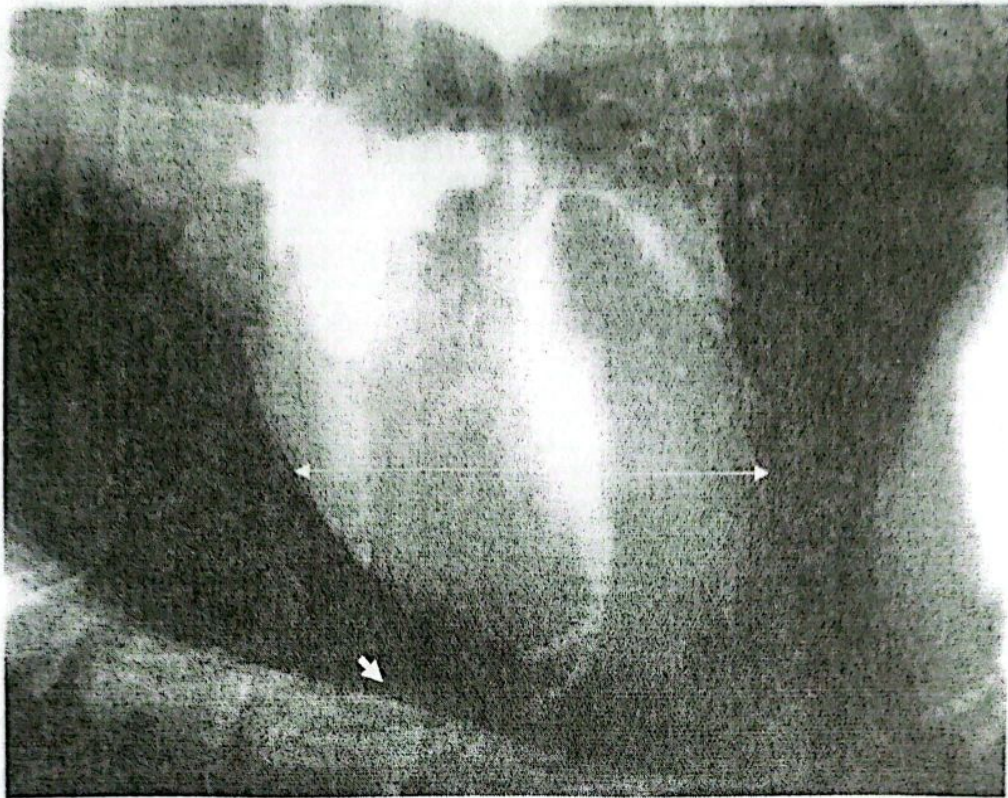


Fig.(6): Right lateral thoracic radiograph of a 5-year-old German Shepherd dog with microcardia. The heart appeared small, vertical and narrower. Mild pleural effusion near the cardiac apex (arrow).

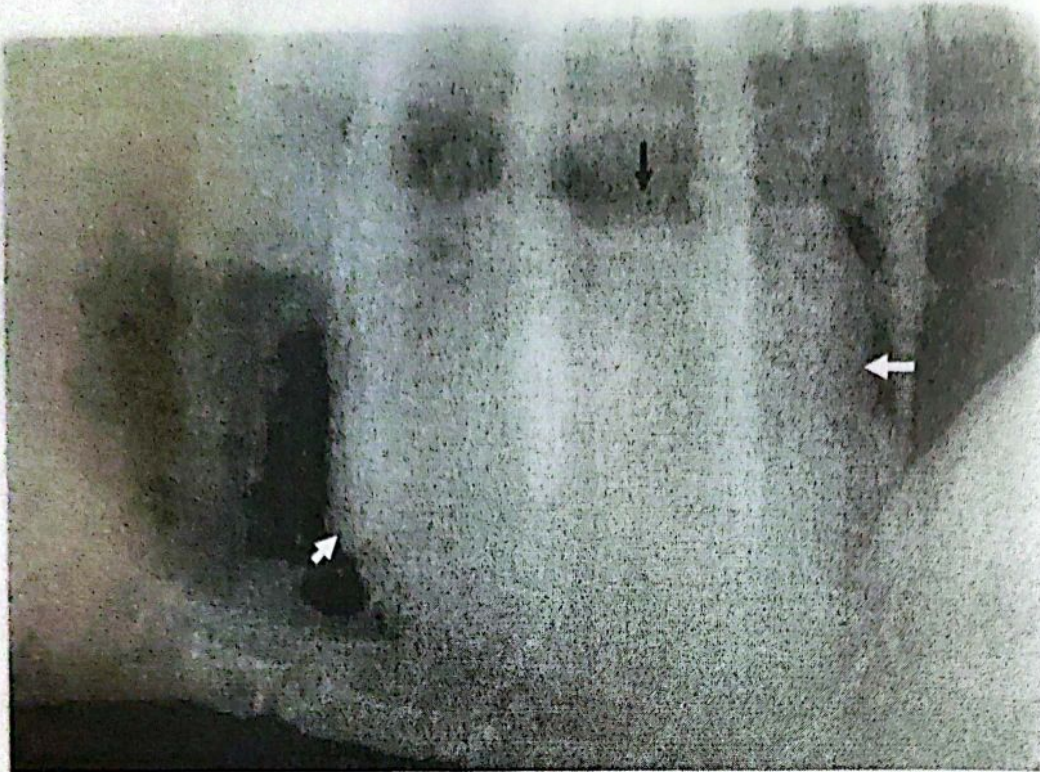


Fig.(7): Right lateral thoracic radiograph of a 9-year-old Griffon dog with left atrial dilatation showed enlarged left atrium with lost caudal waist of the cardiac silhouette in comparison with the cranial waist (white arrows). The caudal part of the trachea, carina and main stem bronchi elevated dorsally (black arrow).

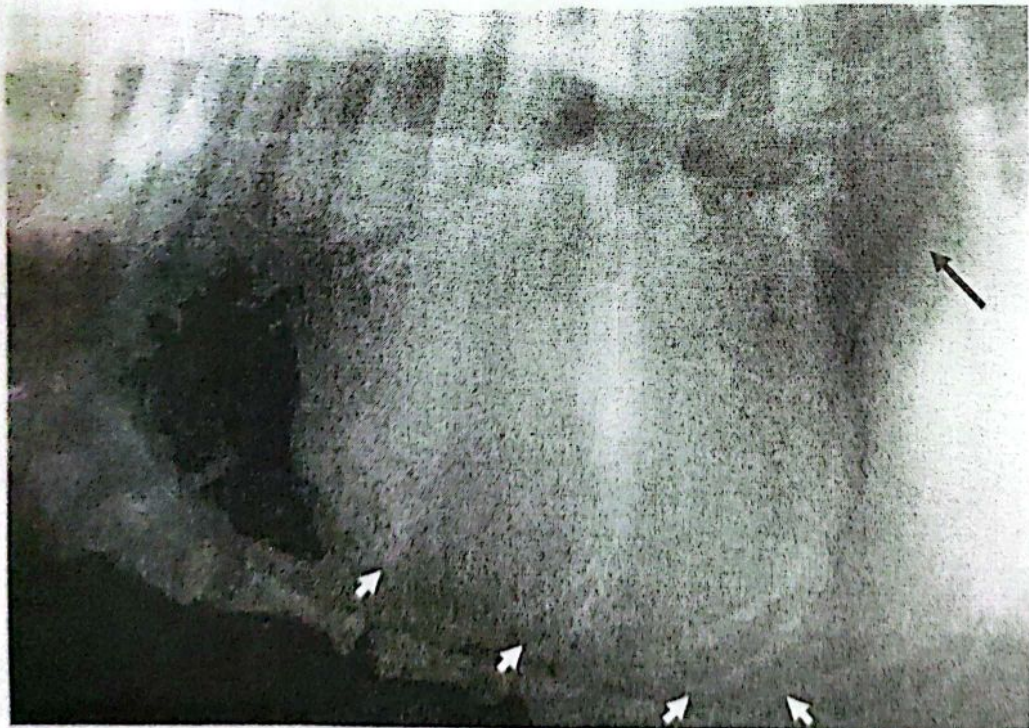


Fig.(8): Right lateral thoracic radiograph of a 5-year-old Mastiff dog with right ventricular enlargement showed increased sternal contact of the cranial cardiac margin (white arrows). Dorsal elevation of the caudal vena cava (black arrow).

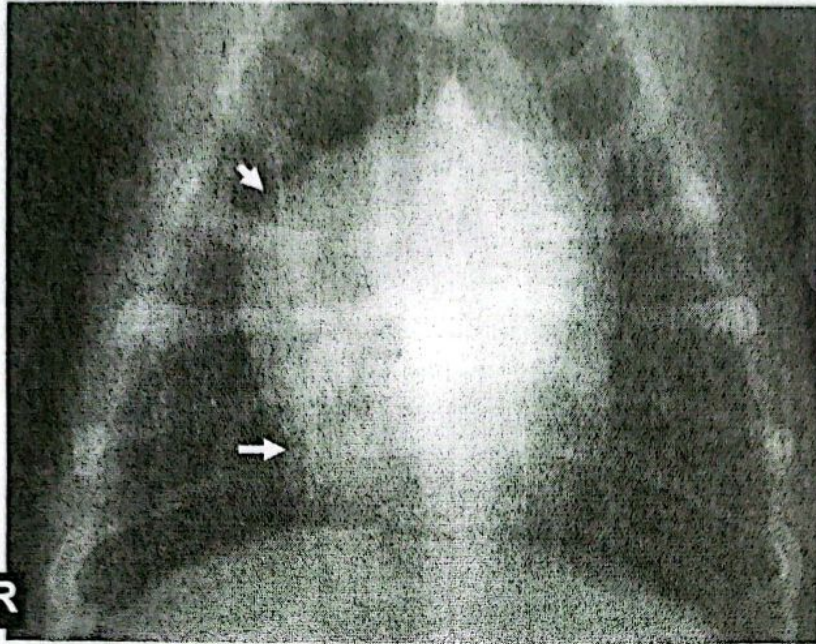


Fig.(9): Ventro-dorsal thoracic radiograph of the same dog with right ventricular enlargement showed enlarged cardiac silhouette at the 6 to 11 o'clock position (arrows), with characteristic inverted 'D' sign.

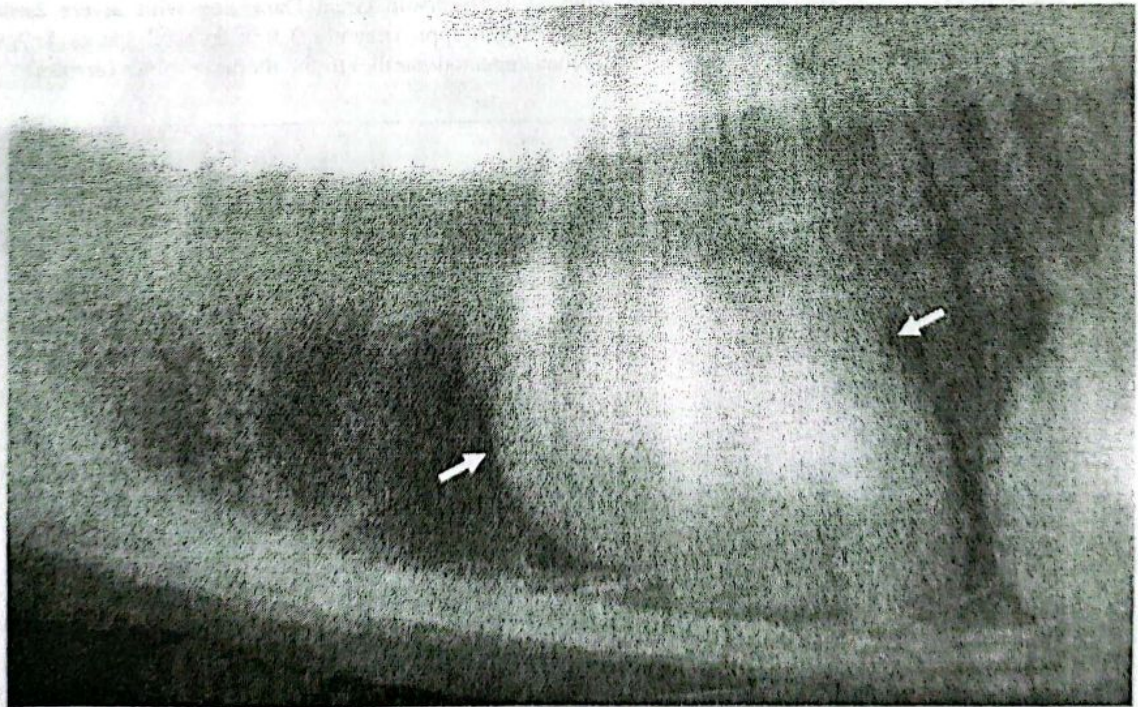


Fig.(10): Right lateral thoracic radiograph of a 10-year-old Irish setter dog with moderate cardiomegaly showed increased sternal contact with dorsally elevated trachea. The cranial and caudal waists appeared shallow (arrows).

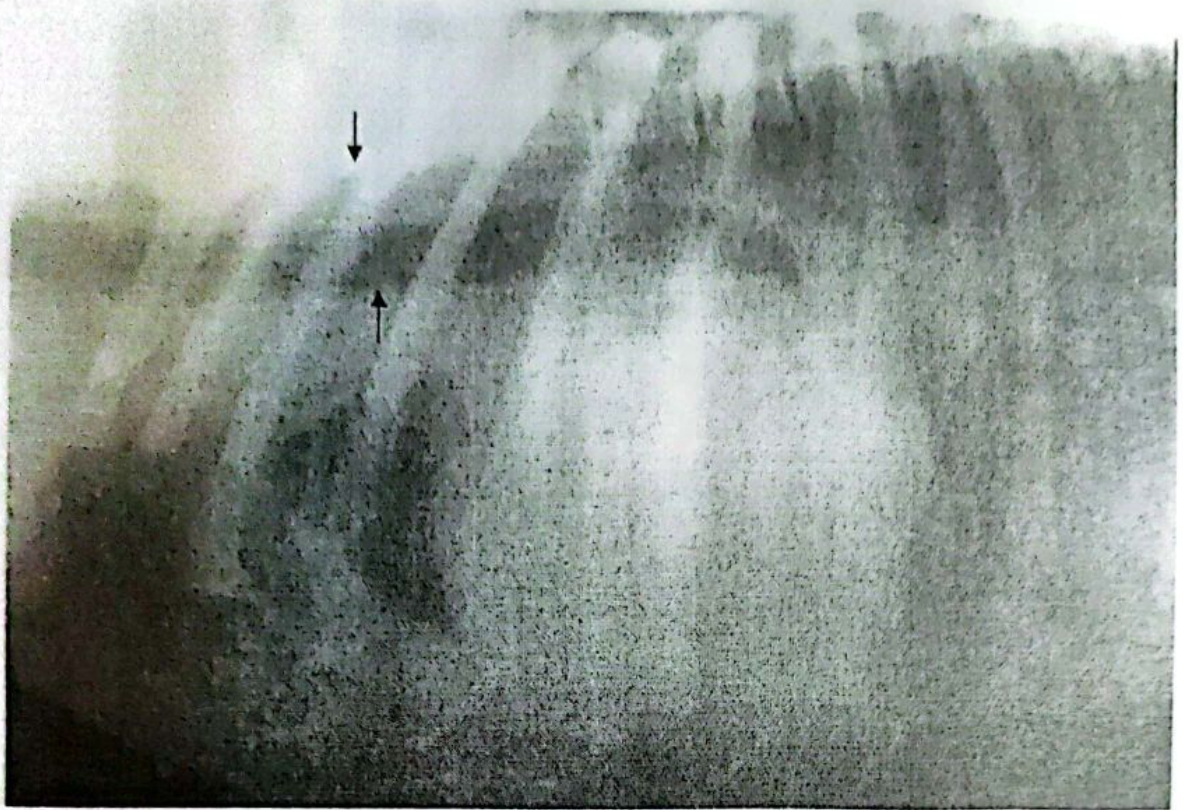

Fig.(11): Right lateral thoracic radiograph of a 7-year-old Great Dane dog with severe cardiomegaly showed increased cardiac silhouette width (approximately 3.5 intercostal spaces). Absence of cranial and caudal waists. The trachea appeared parallel to the thoracic spines (arrows).

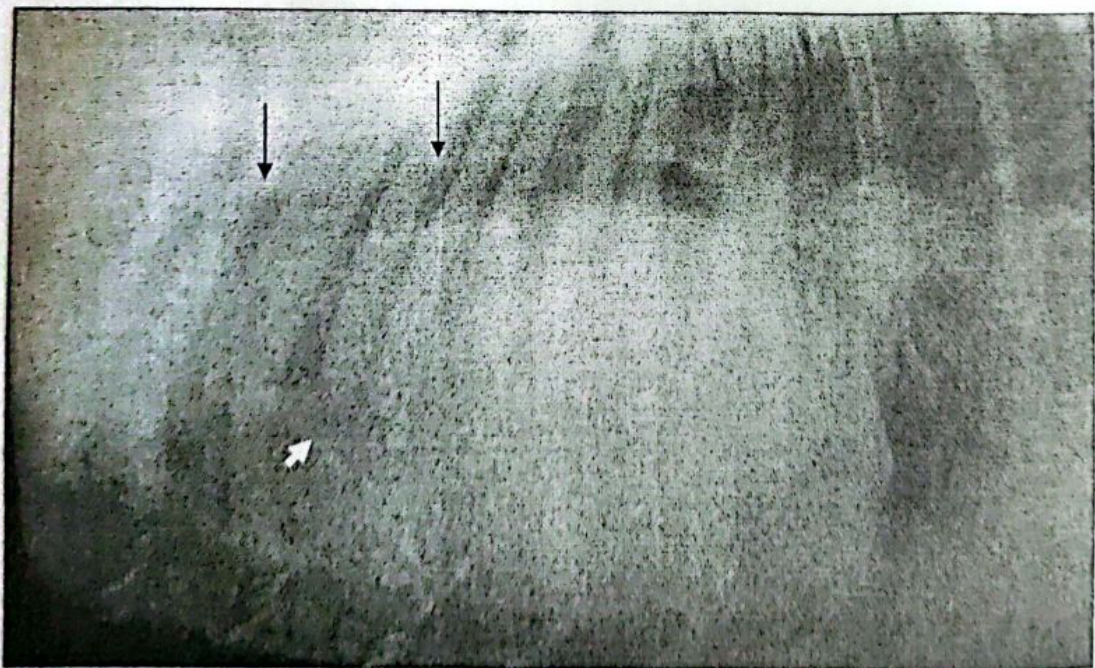


Fig.(12): Right lateral thoracic radiograph of a 3-year-old German Shepherd dog with pericardial effusion. The cardiac silhouette is rounded (basket ball). Increased lung opacity (pulmonary edema), with marked pleural effusion (white arrow). The angle between the thoracic spines and the trachea is diminished to the point of becoming parallel (black arrows).

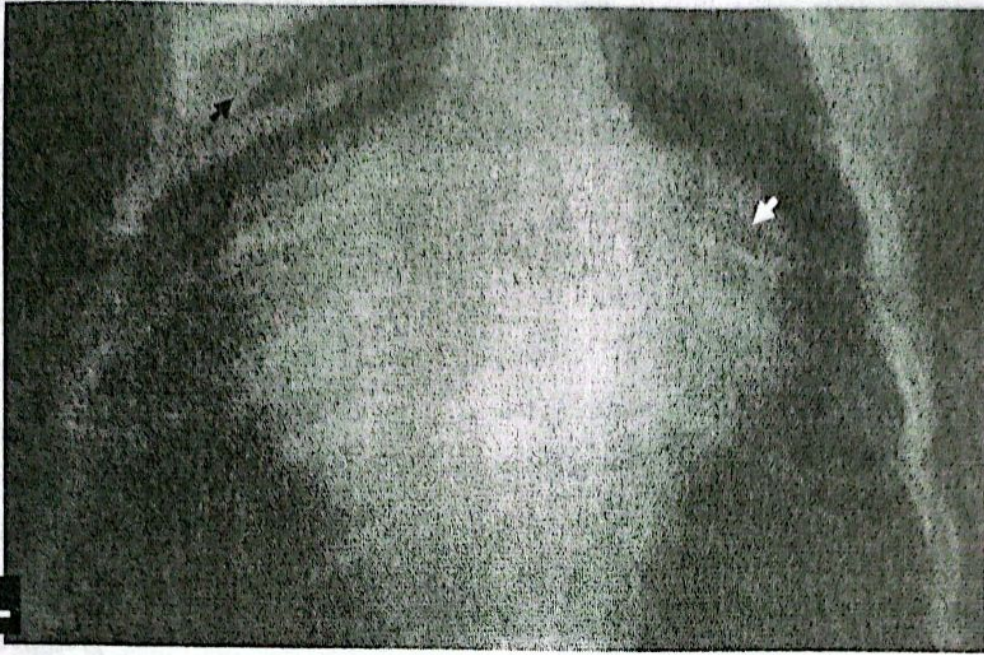


Fig.(13): Vento-dorsal radiograph of a 2-year-old Yorkshire terrier with hypertrophic cardiomyopathy showed Valentine shape cardiac silhouette with marked right atrial dilatation (white arrow) and congestion of pulmonary vessels (black arrow).

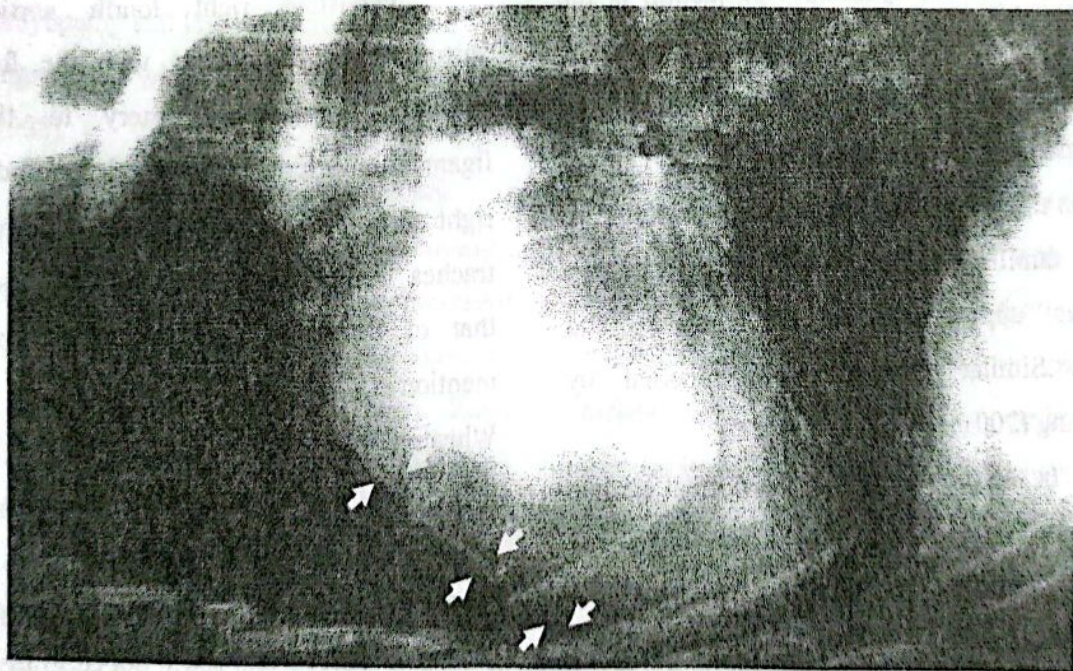


Fig.(14): Right lateral thoracic radiograph of a 3-year-old German Shepherd dog with pneumopericardium. The pericardium appeared as a thin radio-opaque line surrounding the cardiac silhouette and separated by very narrow radiolucent space (arrows).

DISCUSSION

This study was designed to evaluate the role of radiography in diagnosing cardiac diseases; therefore the cases were classified according to their radiographic appearance.

There were subtle differences in cardiac conformation and position when comparing the right versus the left lateral radiographic projections. These differences were not significant enough to warrant further discussion. Similar findings were mentioned by Tilley and Goodwin (2001). Although the dorsoventral projection is preferred over the ventrodorsal projection but the symmetric projection is the ultimate goal with patient compliance determining which projection is attainable, so the right lateral and ventrodorsal projections were used in the present work as these projections are more familiar to the veterinarians and the animals appear to be more stable and comfortable. Similar findings were reported by Schelling (2001).

In the present work, the normal cardiac silhouette is approximately 2.5-3 intercostal space in lateral view while in ventro-dorsal view, the normal heart at the widest point occupies approximately two-thirds of the width of the thoracic cavity.

It is impossible to detect a specific heart defect by routine thoracic radiography. It was

difficult to see a patent ductus arteriosus, pulmonic stenosis, or an interarterial septal defect. Instead, the radiographer can detect the abnormal cardiac silhouette which is produced by a response which the heart made to the physiologic stress of abnormal circulation being created by the lesion we seek to identify (Hamlin, 1968).

Persistent right aortic arch is a vascular ring anomaly caused by a disturbance in the normal development of the aortic arch and its branches that encircles the primitive trachea and esophagus. A result that agrees with that mentioned by (Larcher, 2006).

Persistent right fourth aortic arch surrounds the esophagus with the following structures: pulmonary artery to the left, ligamentum arteriosum to the left and dorsally, right aortic arch to the right and heart base and trachea ventrally. The condition is essentially that of esophageal obstruction as was also mentioned by (Reed and Bonasch 1964; Wheaton, et al, 1984 and Shires and Liu, 1994).

Persistent right aortic arch resulted in prestenotic saccular, contrast-filled cranial esophagus that narrows abruptly at the level of the fourth intercostal space dorsal to the heart. Similar findings were mentioned by Suter and Lord (1984). The motility of the caudal esophagus is impaired to varying degrees so, the

caudal segment of the esophagus is uniformly and permanently dilated.

Regarding cases of microcardia, as a result of small sized heart, the long cardiac axis is shorter so the trachea appeared farther than normal away from the spine. A small heart resulted from decreased venous return. An explanation that agreed with (Suter and Lord 1984 and Fox et al, 1999).

Left atrial enlargement resulted in dorsal elevation of the caudal portion of the trachea, carina, and subsequently dorsal displacement of the main stem bronchi. The left atrium may enlarge in response to left-sided volume overload as in case of mitral insufficiency, cardiomyopathy and left ventricular failure. This is in agreement with (Murphy et al, 1985 and Fox, 1988).

Right ventricular enlargement is determined by accentuated heart convexity cranial to the apex which causes increased sternal contact. The trachea is usually elevated where it passes over the cranial heart. Right ventricular enlargement may results from high resistance to ventricular ejection (pulmonary hypertension), tricuspid insufficiency, cardiomyopathy, cor pulmonale, dirofilariasis and some congenital heart diseases as pulmonic stenosis, patent ductus arteriosus and ventricular septal defect. Similar result was obtained by

(Feldman et al, 1981; Ware and Bonagura, 1988 and Oswald and Orton, 1993).

Generalized cardiomegaly is determined by the size of the heart compared with the thorax and by displacement of the adjacent structures. The heart appeared wider in the cranio-caudal and transverse projections, while in severe cardiomegaly, the cardiac silhouette appeared more rounded than normal. In this respect, the cardiac silhouette generally enlarges in response to volume overload or myocardial failure or both. Volume overload may be caused by vulvular incompetence or severe bradycardia. Myocardial failure can not be directly assessed by radiography; it may be determined by echocardiography, cardiac catheterization and angiography, as was also reported by (Buchannan and Bucheler, 1995).

The classic radiographic appearance of pericardial effusion is that of a large, round cardiac silhouette with lacking of an apex or other structural details. As a point of differentiation from generalized cardiomegaly due to heart diseases, the left atrium is not prominent (Gibbs et al, 1982).

The most frequently identified cause of pericardial effusion and cardiac tamponade is cardiac neoplasm (Berg and Wingfield, 1983; Thomas, 1989 and Buchannan, 1992) while idiopathic pericardial effusion is the most frequently reported non-neoplastic disorder

causing cardiac tamponade in dogs (De Mardon et al, 1987).

In regards to cardiomyopathy, hypertrophic cardiomyopathy and congestive cardiomyopathy are the most common forms of cardiomyopathy.

A result which coincided with that mentioned by (Oyama et al, 2008). Radiographically, hypertrophic cardiomyopathy characterized by generalized cardiomegaly with marked left atrial dilatation, so the cardiac silhouette assumes the valentine shape. This is in agreement with Fox et al (1999) and Sanderson (2006). Pulmonary venous congestion and edema occurred due to heart failure.

Pneumopericardium is a very rare cardiac disease recorded incidentally in a case of pneumothorax where the pericardium appeared separated from the cardiac silhouette by very narrow radiolucent space. This affection occurred as a result of traumatic pneumothorax and consequently pericardial tear occurred.

In conclusion, thoracic radiography forms the cornerstone for evaluation of cardiopulmonary diseases. Its value is to provide direct information about cardiovascular size and shape, indirectly; assess cardiopulmonary circulation and reflects the degree of heart failure.

REFERENCES

- Abraham, W.T.; Feldman, D.S. and Carnes, C.A. (2007): Chronic cardiac resynchronization therapy and reverse ventricular remodeling in a model of non ischemic cardiomyopathy. *Live Sciences*, 81(14):1152-1159
- Berg, R.J. and Wingfield W. (1983): Pericardial Effusion in the dog: A review of 42 cases. *J. Am. Anim. Hosp. Aas.*, (20): 721
- Boujon, C. E. and Amberger, C. N. (2003): Arrhythmogenic right ventricular cardiomyopathy in a Boxer. *J. of Vet. Cardiology*, (5):35-40
- Buchanan, J.W. (1972): Radiology of the heart. 39th annual meeting, Am. Anim. Hosp. Assoc. p.78-86.
- Buchanan, J.W. (1992): Causes and prevalence of cardiovascular disease. *JAVMA*, 212:209-218
- Buchanan, J.W. and Bucheler, J. (1995): Vertebral scale system to measure canine heart size in radiographs. *JAVMA*, 206:194-199
- De Mardon, E.; Prymak, C. and Hendricks, J. (1987): Idiopathic hemorrhagic pericardial effusion in eight dogs. *JAVMA*, (191): 324
- Feldman, E.C. and Tyrell, J.B. (1977): Hypoadrenocorticism. *Vet.Clinic North Am.*, (7):555-581
- Feldman, E.C.; Nimmo-Wilki, J.S. and Pharr, J.W. (1981): Eiesnmengers syndrome in the dog. *J. Am. Anim. Hosp. Assoc.* (17): 447.
- Fews, D.; Scase, T.J. and Battersby, I.A. (2008): Therapeutic pericardiocentesis in the dog and cat. *J. of Comparative Pathology*, (138):224-228
- Fox, P.R. (1988): Feline cardiomyopathy. In *Canine and Feline cardiology*. 1st ed., New York, Churchill Livingstone: p435.
- Fox, P.R., Sisson, D. and Moise, NS (1999): Feline cardiomyopathy. In *Canine and Feline cardiology*. W.B. Sounder, Philadelphia, 2nd edition.,

- Gibbs, C.; Gaskell, C.J.; Darke, P.G and Wotton, G.(1982): Idiopathic pericardial hemorrhage in dogs: A review of 14 cases. *J. of Small Anim. Practice*, (23): 483-490
- Hamlin, R.L. (1960): Radiographic anatomy of the heart and great vessels in healthy living dogs. *J .Am. Vet. Med. Assoc.*,(136):265-273
- Hamlin, R.L. (1968): Analysis of the cardiac silhouette in dorsoventral radiographs from dogs with heart disease. *J.A.V.M.A.*, 153(11):1446-1460
- Harpster, N.K. (1991): Boxer cardiomyopathy: A review of the long term benefits of antiarrhythmic therapy. *Vet. Clinic of North America. Small animal practice*, (21): 989-1009
- Isachc, S. (1995): Recommendations for the diagnosis of heart disease and the treatment of heart failure in small animals. In manual of canine feline cardiology. 2ed edition Philadelphia, W.B. Saunders: pp 374-381
- Kittleson, MD and Kienle, RD (1998): Small animal cardiovascular medicine. Mosby, St. Louis, 1st edition.
- Larcher, T.; Abadie, J.; Roux, F.; Deschamps, J. and Wyers, M. (2006): Persistent left cranial vena cava causing esophageal obstruction and consequently megaesophagus in a dog. *J of Comparative Pathology*, (135):150-152
- Lord, PF and Suter PF (1999): Radiology. pp 107-129. In Text book of canine and feline cardiology. W.B. Saunders, Philadelphia, 2nd edition.
- Murphy, M.L.; Blue, L.R. and Thenabada, M. (1985): The reliability of the routine chest roentgenogram for determination of heart size based on specific ventricular chamber evaluation at postmortem. *Invest. Radiol.*, 20:21
- Oswald, G.P. and Orton, E.C. (1993): Patent ductus arteriosus and pulmonary hypertension in related Pembroke Welsh corgis. *JAVMA*, (202):76-82
- Owens, J.M.; Biery, D.N. and Tennant, J. (1982): Radiographic interpretation for the small animal clinician. Ralsoton Purina Co., St. Louis, Missouri.
- Oyama, M.A. ; Stephan, R.E. and Lehnart, S. (2008): Arrhythmogenic right ventricular cardiomyopathy (10)1-10
- Rawlings, C.A. and Lewis, R.E. (1977): Right ventricular enlargement in heartworm disease. *Am. J. Vet. Res.* 38(11):1801-1805
- Reed J.H. and Bonasch, H. (1964): The surgical treatment of a persistent right aortic arch and patent ductus arteriosus in a dog. *Can. VET. J.*, (5):240-249.
- Sanderson, S. (2006): Taurine and Carnitine in canine cardiomyopathy. *Vet. Clinic of North America*, (36): 1325-1343
- Schelling, C.G. (2001): Radiology of the heart; in manual of canine and feline cardiology. *Feline Cardiology*. W.B. Saunders, Philadelphia, 2nd edition.
- Schwartz, A.; Wilson, G.P.; Hamlin, R.L.; Swenber, J. and Termin, P. (1971): Constrictive pericarditis in two dogs. *J. Am. Vet. Med .Assoc.*, (159): 763-776
- Shires, P.K. and Liu, W. (1994): Persistent right aortic arch in dogs. *J. Am. Anim. Hosp. Asso.*, (17):773
- Silverman, S. and Suter, P. (1975): Influence of inspiration and expiration on canine thoracic radiograph. *J.Am.Vet. Med.Assoc.*, (166): 502-510
- Sisson, D.; Thomas, W. and Keene, B.(2000): Primary myocardial disease in the dog. In textbook of veterinary internal medicine. 5th ed. Philadelphia, W.B. Saunders: pp 874-895
- Vet. Med. J., Giza. Vol. 57, No.3. (2009)*

- Suter, P.F. and Lord, P.F. (1971): A critical evaluation of the radiographic findings in canine cardiovascular diseases. *J.A.V.M.A.*, 158(3):358-371
- Suter, PF and Lord PF (1984): Thoracic radiography of the dog and cat. W.B. Sounder, Philadelphia, 1st edition
- Thomas, W.B. (1989): Pericardial disorders .In Textbook of veterinary internal medicine. 3rd ed .Philadelphia, WB Saunders, p:1132 Vol. XI .Pheladelia ,WB Saunders, p:647
- Tilley, LP and Goodwin, JK (2001): Manual of canine and feline cardiology. W.B. Saunders, Philadelphia, 2nd edition.
- Ware, W.A. and Bonagura, J.D. (1988): Multiple congenital cardiac anomalies and Eisenmenger s syndrome in dog. *Can. Vet. J.* (10): 932
- Wheaton, L.G.; Blevins, W.E. and Weirich, N. (1984): Persistent right aortic arch associated with other vascular anomalies in two cats. *JAVMA*, (184): 848
- Wyburn, R.S. and Lawson, D.D. (1967): Simple radiography as an aid to the diagnosis of heart disease in the dog. *J. Small Anim. Pract.*, (8):163-170.

الاستنتاجات الاشعاعية لبعض اصابات القلب في الكلاب

فيصل عبد الصمد

قسم الجراحة و التخدير و الاشعة كلية الطب البيطري جامعة القاهرة

لا يزال الفحص بلاشعه ذو قيمة في تشخيص الامراض القلبية الرئوية وكذلك في تقييم الاستجابة للعلاج

في هذه الدراسة تم عمل اشعه صدرية لعدد 47 حالة اكلينيكية في الكلاب تعاني من مشاكل قلبية.

كذلك تم الفحص بالاشعه الصدرية لعدد 5 كلاب طبيعیه وذلك لتصوير القلب فيها كمجموعه ضابطه.

وقد كانت الكلاب المصابه من كلا الجنسين وتراوحت اعمارها بين 45 يوم و 12 سنه. وفي هذه الدراسة تم تشخيص الاصابات التاليه: القوس الوتيني الايمن المستمر (2)-صغر القلب (2)-تمدد اذيني ايسر (6)-تمدد بطيني ايمن (9)-تضخم عام في القلب (18)-انسكاب تاموري (8)-داء عضله القلب المتضخم (1)-استرواح التأمور (1).

وقد تم مناقشه كل نتائج الفحص بلاشعه في كلا من الكلاب المصابه والسليمه. وقد خلصت الدراسة الي ان فحص الصدر بلاشعه يمثل حجر الزاويه في تشخيص الامراض القلبية الرئوية من خلال الامداد بالمعلومات السريعه والمباشره عن حجم وشكل القلب وكذلك بشكل غير مباشر عن طريق تقييم دوره الدمويه القلبية الرئوية والتي تعكس درجه الفشل في عضله القلب.