

**Original
Article**

CONCURRENT CHEMORADIOTHERAPY FOLLOWED BY ADJUVANT CHEMOTHERAPY WITH CISPLATIN AND DOCETAXEL FOR ADVANCED HEAD AND NECK CANCER

Hussein Omar¹, Wafaa Ashour¹, Azza Nasr¹, Mohamed Hassan² Hassna Al-Ghamdi¹

¹King Abdul Aziz Hospital and Oncology Center, ²Erfan Hospital, Jeddah, Saudi Arabia

ABSTRACT

Background: Concurrent chemoradiotherapy (CRT) is the most effective approach in controlling advanced head and neck cancer. Cisplatin is the most extensively cytotoxic agent investigated concurrently with radiation therapy as well as in neoadjuvant and adjuvant setting, also the taxanes (paclitaxel and docetaxel) have demonstrated significant activity in head and neck cancer so we started this study to confirm the efficacy of concurrent chemoradiotherapy followed by three cycles of adjuvant chemotherapy (cisplatin and docetaxel) in treating patients with locoregional advanced head and neck cancer.

Patient and Methods: Between February 2003 and August 2005, 36 patients with advanced head and neck cancer were treated at King Abdul Aziz Hospital and Oncology Center Jeddah, with a full course of conventional radiotherapy (70 Gy). Patients were scheduled to receive two cycles of concurrent cisplatin (100mg/m²) administered on weeks one and five of radiotherapy. Subsequently a further three cycles of adjuvant chemotherapy comprising a combination of cisplatin (60mg/m²) and docetaxel (60mg/m²) repeated every three weeks. All patients were assessed for response immediately after the concomitant phase and at two months after completion of treatment. Follow up was maintained for a range from 6 to 36 months. Toxicity profile, pattern of failure, two years disease free and overall survival rates were estimated.

Results: The median age of patients was 44 years with male to female ratio of 2.3:1. 64% of the patients had a primary tumor of the nasopharynx. Undifferentiated carcinoma was the major pathological subtype. The planned dose of radiotherapy was completed in 92% of patients, and 83% completed the three cycles of adjuvant chemotherapy. Mucositis and neutropenia were the commonly recorded side effects, with no reported toxic death. 31 patients went into complete remission (CR) after the first phase of treatment. Another three patients were turned into CR after the adjuvant phase. During the period of follow up, five patients relapsed (three locoregional & two systemic relapse). The estimated two year disease free and overall survival rates were 78% and 89% respectively.

Conclusion: Concurrent chemoradiotherapy had improved the results of treatment in patients with advanced head and neck cancer concerning locoregional control, disease free survival and overall survival; however more was achieved, especially concerning reduction of distant failure, by addition of adjuvant chemotherapy. Docetaxel in combination with cisplatin is reported to be an effective combination in the adjuvant setting.

Key Words: Head and neck cancer, docetaxel, concurrent chemoradiotherapy

Corresponding Author: Hussein Omar, Assistant professor, Kasr Al-Aini Hospitals, Cairo, Egypt
Tel.:(+202)3626246

INTRODUCTION

Squamous cell carcinoma of the head and neck is the sixth common cancer. Approximately 60,000 new cases diagnosed annually world wide, over 60% are locoregionally advanced (stage III and IV) at diagnosis. For those patients, complete surgical excision combined with preoperative or post operative radiotherapy is not always a therapeutic option.^{1,2}

To improve outcomes in locoregional advanced head and neck cancer, a multidisciplinary approach is a key element. However the integration of these approaches remains a challenge. The strongest evidence to date, established concurrent chemoradiotherapy (CRT) as the most effective approach in controlling advanced disease. This has been demonstrated for head and neck cancer in general, as well as for specific subsites, such as

nasopharynx, oropharynx and larynx.³

Although a variety of cytotoxic agents have been studied, Cisplatin is the most extensively investigated. The data from many recent trials using standard radiation fractionation, with or without high dose single agent cisplatin given every three weeks, have been reported in the last two years⁴⁻¹⁰. Most of these trials showed that the combined regimen was superior to radiation therapy alone in locoregional control or organ preservation, some of them also showed improvement in overall survival.^{5,8-10}

A common finding, however, is that 100mg/m² of cisplatin given every three weeks during the course of radiotherapy (three doses) substantially increases the

severity of mucositis, apparently more than radiotherapy regimens without chemotherapy. In addition, cisplatin induces systemic toxicity requiring intensive premedication and supportive care. Recent data from many trials suggest that a cumulative cisplatin dose of approximately 200mg/m², independent of the schedule, might be sufficient to yield a beneficial antitumor effect.¹¹⁻¹³

The survival benefit of adding neoadjuvant or adjuvant chemotherapy to concurrent chemoradiotherapy for locoregional advanced head and neck cancer is currently investigated. The US intergroup trial 00-99 was the first randomized study to show significant survival benefit by adding cisplatin (CDDP) concurrent with RT followed by adjuvant CDDP and fluororacil (FU). A 25% improvement in the two years overall survival (OS) rate compared to RT alone was demonstrated in the initial report⁴. Moreover an updated analysis of survival figures revealed a continued improvement of the five years disease free and overall survival¹⁴. These findings are recently confirmed by Joseph et al.¹⁵ who demonstrated improvement in the distant metastasis control in addition to the survival benefit. In addition Kohono N.¹⁶ concluded that concurrent regimens should be supplemented with adjuvant chemotherapy in all patients particularly those with advanced N- stage.

The taxanes (paclitaxel and docetaxel) have demonstrated significant activity in head and neck cancer. This activity and the relative nonoverlapping toxicities with platinum have prompted the investigation of various chemotherapy regimens combining taxanes with platinum as neoadjuvant or adjuvant therapy for advanced head and neck cancer.¹⁷

Following the previous results we started a phase II study to confirm the efficacy of concurrent chemoradiotherapy followed by three cycles of adjuvant chemotherapy for patients with locoregional advanced head and neck cancer concerning the immediate locoregional control figures, disease free and overall survival. In addition pattern of failure and toxicity profile will be outlined.

Patients and Methods

Between February 2003 and August 2005, 36 patients with advanced head and neck cancer were treated at King Abdul Aziz Hospital and Oncology Center, Jeddah, Saudi Arabia with concurrent chemoradiotherapy followed by three cycles of adjuvant chemotherapy (Cisplatin and Docetaxel). The protocol was approved by the ethical committee and informed consents had been obtained from all patients.

Patients 18 years or older with Eastern Cooperative Oncology Group performance status of 0 or one, and

who had histologically confirmed stage III or IV but M0, squamous cell carcinoma of the nasopharynx, oropharynx, hypopharynx, larynx, tonsil or oral cavity and were previously untreated were eligible for this trial.

Patients were required to have adequate bone marrow, renal and hepatic functions. The disease was staged according to the 2002 classification of the American Joint Committee on cancer.

All patients underwent staging work up including physical examination, complete blood work (complete blood picture, kidney function tests and liver function tests), chest X-ray, abdominal ultrasound, computed tomography or magnetic resonance imaging of head and neck. Additional tests include fiberoptic triple endoscopy, bone scan, renogram and dental evaluation.

All patients were planned to receive a full course of radiotherapy to a dose of 70 Gy (1.8-2 Gy / fraction) using 6-MV linear accelerator. All fields were treated once daily⁵, times a week. Radiotherapy started with two lateral opposing facialcervical fields to cover the primary tumor and neck lymph nodes to a dose of 40 Gy. After 40 Gy, to avoid further irradiation to the spinal cord, the posterior border of the lateral fields was displaced anteriorly. Additional 20 Gy was delivered to the reduced upper lateral fields followed by another 10 Gy boost to primary lesion, and the posterior neck nodes was supplemented with 10 Gy (electron beam therapy) if it was negative and 25-30 Gy if it has positive nodes. Anterior facial field may be added for nasal and ethmoidal extension of tumor. The lower neck and suprclavicular fossae were treated with an anterior field to 50 Gy.

Patients were scheduled to receive two cycles of concurrent cisplatin (100mg/m² i.v. infusion) administered on weeks one and five of RT. Subsequently a further three cycles of adjuvant chemotherapy comprising a combination of cisplatin (60mg/m² as two hours i.v. infusion) and docetaxel (60mg m² as 1 hour i.v. infusion) repeated every three weeks. Treatment modifications were carried out according to the following scheme: CDDP was omitted for a cycle during the concurrent RT phase if the minimum hematologic criteria were not met (absolute neutrophils count > 1,000/ μ L and platelet count > 100,000/ μ L). During the adjuvant phase, deferment of the chemotherapy by up to a maximum of two weeks was allowed if the same hematologic criteria were not met. Chemotherapy was also discontinued in the event of patient refusal, physician's decision for fear of RT compromise and unacceptable toxicities such as severe sepsis or renal impairment. Every effort was taken not to delay or break the course of RT.

All patients were assessed for response immediately after the concomitant phase and at two months after completion of treatment. This assessment includes

physical examination, CT scan or MRI of the primary and neck nodes. Endoscopy and biopsy was performed from any suspicious lesions.

Patients were followed clinically on monthly base for the first year and every three months from the second year. Radiological evaluation by CT Scan or MRI of the primary and neck nodes, as well as chest X-ray were performed annually or whenever there is suspicious of tumor recurrence, while abdominal ultrasound and bone scan were performed whenever there was a suspicious of distant metastasis.

Statistical analyses were performed using SPSS 10 software. Disease free survival and over all survival estimates were calculated according to Kaplan- Meier methods.

RESULTS

Between February 2003 and August 2005 a total of 36 patients were recruited onto study. Data collection was done June 2006 with a follow up ranged from 6 to 36 months. Patient characteristics, primary site distribution, and primary and nodal staging are shown in table 1.

Patient's characteristics

The median age of our patients was 44 years (range 18-73 years). Twenty five patients were males, with male to female ratio of 2.3:1. The majority of our patients

Table 1 : Patients characteristics.

Characteristics	No. of Patients (36)	%
Sex		
Male	25	69
Female	11	31
Age, years		
Median	44 years	
Range	18-73 years	
Primary site of the tumor		
Nasopharynx	23	64
Hypopharynx	4	11
Larynx	5	14
Oropharynx	2	5
Tonsil	1	3
Buccal mucosa & cheek	1	3
T-Stage		
T1	0	0
T2	5	14
T3	15	42
T4	16	44
N-Stage		
N0	3	8
N1	11	31
N2	18	50
N3	4	11
Pathology		
Differentiated	13	36
Undifferentiated	23	64

(64%) had a primary tumor of the nasopharynx. Eighty six percent had T3 and T4 disease and sixty one percent had N2 and N3 disease. Undifferentiated carcinoma was the major pathological subtype (64%) (Table 1).

Treatment Compliance

70% of our patients fully complied with the treatment protocol. Eleven out of 36 patients were deviated either during the concomitant CRT phase of treatment or during the adjuvant phase or both. Nine patients had treatment deviation during the concurrent CRT component; four patients had received only one cycle of chemotherapy during this phase; three of them due to toxicity (all of them had a deviation for the radiotherapy component as well) and one patient refused the 2nd cycle of concurrent chemotherapy.

Protocol deviation for the RT component included three patients who received a total RT dose of no more than 68 Gy and 7 patients who had a gap during the radiotherapy treatment of more than one week (Table 2).

Table 2: Compliance to radiotherapy.

Radiotherapy	No.	%
Completed uninterrupted to full dose	28	78
Completed uninterrupted but under dose	1	3
Completed with gap to full dose	5	14
Completed with gap and under dose	2	5

Six patients had a reduced number of chemotherapy cycles during the adjuvant phase of the trial, two of them completed the concomitant CRT phase of treatment. This reduction in the number of adjuvant cycles was secondary to treatment toxicity (Five patients) or patient refusal (One patient) (Table 3).

Table 3: Compliance to adjuvant chemotherapy.

Number of cycles	No.	%
3	30	83
2	5	14
1	1	3

Treatment toxicity

For hematologic toxicity, the incidence of severe neutropenia was higher during the adjuvant phase of treatment than during CRT phase (19% and 6%, respectively) however the incidence of anemia was equivalent in both the initial and adjuvant phases of treatment (6% and 8%, respectively). On the other hand for none hematological toxicity, the incidence of oropharyngeal mucositis was significantly higher in the CRT phase of treatment (25% in CRT and 3% in adjuvant phase). Details of other types of toxicity are listed in table 4.

Table 4: Treatment toxicity.

Criteria	Concomitant chemo radiotherapy Grade III & IV		Adjuvant chemotherapy Grade III & IV	
	No	%	No	%
Neutropenia	2	6	7	19
Anemia	2	6	3	8
Thrombocytopenia	0	0	0	0
Mucositis	9	25	1	3
Nausea & Vomiting	3	8	5	14

*NCI common toxicity criteria

Patient outcomes

All patients were assessed for response immediately after the concomitant CRT phase of treatment, where all patients showed a marked response to this phase of treatment, 31 patients went into complete remission (CR). The other five patients achieved partial response (PR), however three of them were turned into CR after the adjuvant phase of treatment (Table 5).

During the period of follow up, five patients out of 34 who went into CR relapsed (three locoregional and two systemic relapse) from those with systemic relapse one patient developed bone metastases and the other one developed lung metastases (Table 5).

Table 5: Patient Outcomes.

	Criteria	No.	%
Immediate response	CR after CRT	31	86.1
	CR after adj. T	34	94.4
disease Control	Local Failure	3	8.8
	Distant metastasis	2	5.8
two year survival	Disease Free survival		78
	Overall Survival		89

The median disease free survival (DFS) was 20.5 months (range 7 -36) and the estimated two year DFS was 78%. The median overall survival (OAS) was not reached however the estimated two years OAS was 89% as seen in the Kaplan – Meier disease free survival and overall survival curves shown in figures 1 and 2.

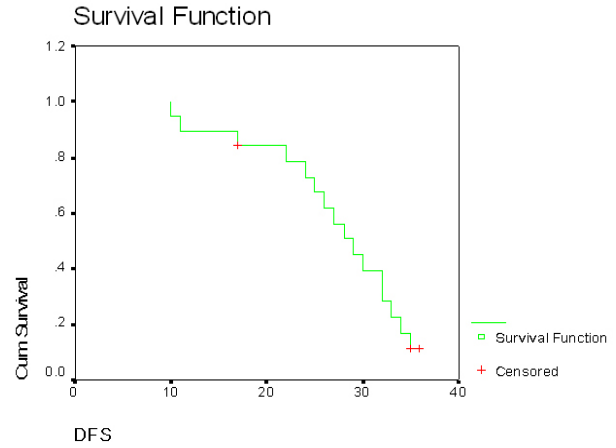


Fig. 1: Kaplan Meier disease free survival curve For 34 patients with advanced head and neck cancer who achieved CR after treatment.

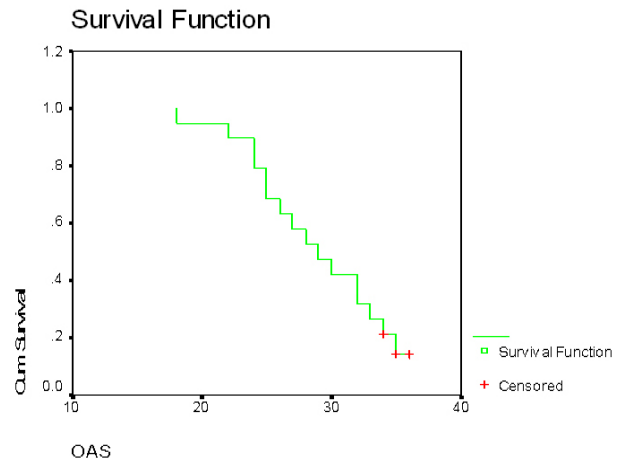


Fig. 2: Kaplan Meier overall survival curve for 36 patients with advanced head and neck cancer treated by concomitant chemoradiotherapy and adjuvant chemotherapy.

DISCUSSION

Although the collective data are strong in establishing the superiority of the combination of radiation with concurrent chemotherapy relative to standard radiation fractionation alone in the management of locally advanced head and neck cancer, there is variability of clinical trials in patient selection and regimens, leading to continuing debate as to which combined regimen should be considered standard. Furthermore, many questions remain to be answered, including whether the cisplatin dose can be altered to reduce acute and late toxicities without diminishing efficacy and whether neoadjuvant or adjuvant chemotherapy further improves the outcome of concurrent radiation and chemotherapy.¹¹

The randomized trial coordinated by the swiss group for clinical cancer research¹² was designed to address

one of these questions, the total cisplatin dose was reduced (i.e. from the usual three to two cycles) and this approach seems to reduce the severity of systemic toxicity and mucositis without diminishing the impact on locoregional control and potentially on occult metastasis. This finding is consistent with the data of a phase III trial in nasopharyngeal carcinoma from the National Cancer Center of Singapore¹³. The data from these two trials along with the observation from other studies showed that a substantial fraction of patients could not receive the third planned cisplatin dose of 100mg/m², suggesting that a cumulative cisplatin dose of approximately 200mg/m², independent of the schedule, might be sufficient to yield a beneficial anti tumor effect.

Although much has been achieved in the way of improving DFS and OS by administering chemotherapy concurrently with RT, more is to be desired, especially concerning reduction of distant failure if adjuvant chemotherapy will be added. Different scheduling of adjuvant chemotherapy seems to have an additive effect.^{4,14-16}

Docetaxel is an active agent against squamous cell carcinoma of the head and neck. It was also active in cell lines less sensitive to cisplatin indicating that no cross resistant exists between the two agents, so they can be combined successfully in adjuvant setting.¹⁷

In the present study, the median age of our patients was 44 years (range 18-73 years) with male to female ratio of 2.3: 1 this finding was reported previously in the same center¹⁰ and in other western studies^{14,15}. Undifferentiated pathology was the most common subtype (64%). This incidence was slightly higher than that reported in western studies which lie in the range of 50%.⁴

T4 comprised 44% of patients in this study; this figure is closely similar to a previous study done in the same center (41%)¹⁰, however in western studies the incidence varies from 30% to 75%.^{5,15}. N2 and N3 patients represent 61%, a similar incidence reported in most of other studies in the range from 50-60%.^{4,10,15}. 25% of our patient had treatment deviation during the concurrent CRT component. In Joseph et al.¹⁵ this figure was 41%, also 92% of our patient completed the planned radiation dose this is higher than that reported by David et al.⁵ who reported only 84%, this high incidence of treatment deviation and under dosage in these two western studies may be explained by the high incidence of treatment toxicities during the concomitant phase of treatment as the patients in those studies received three cycles of chemotherapy during this phase however our patients received only two cycles. 83% of our patients completed the three cycles of adjuvant chemotherapy as planned versus 57% in Joseph et al study¹⁵; this may be related to the high percentage of patients who refused adjuvant chemotherapy in his trial (21%).

Regarding the toxicity profile in the current study, G-III –IV mucositis was the commonest side effect during the concurrent CRT phase (25%) this incidence was lower than that reported by Hadir et al.¹⁰ in the same center (48%), and other western studies where this incidence varied from 40% to 48% (5,15). The simple explanation is that the mucositis was enhanced by the more cycles of chemotherapy given during CRT phase (Two in our study versus three in the other studies). The lower incidence of GIII-IV mucositis in our study was also reflected to the lower incidence of gap during the radiotherapy treatment, which was 19% in our study versus 35% in Hadier et al.¹⁰ study.

Concerning the response to treatment, we found that the concurrent CRT phase of treatment achieved a complete response (CR) of 86.1% and the adjuvant phase of treatment boosted this response to 94.4%, this incidence is slightly higher than that reported by Joseph et al.¹⁵ who reported CR of 86% at the end of both phases of treatment, however this incidence is lower than that achieved by Hadir et al.¹⁰ who achieved 100% CR this may be explained by the nature of the disease itself, as this study was concerning of nasopharyngeal carcinoma patients only, however our study include nasopharyngeal carcinoma patients and other sites of the head and neck cancers.

At the time of data collection, three patients got a locoregional recurrence (90.8% locoregional control). This figure is slightly lower than that reported in the inter group trial⁴ who reported 96.7% local control at three years and also lower than that reported by Hadir et al.¹⁰ 93.5%, moreover the incidence of distant metastases was 5.8% in our study, while it was 19.3% in a previous study on the same center at three years of follow up¹⁰, this improvement in the incidence of distant metastases may be explained by the addition of Docetaxel as a new active agent in this study during the adjuvant setting. This incidence was 56.9% in a previous study in the same center where patients treated with radiotherapy alone.

Regarding the survival data in the current study, the estimated two years disease free survival rate was 78% this finding is similar to the study of Joseph et al.¹⁵ who reported 77%, however it is slightly lower than that reported in a previous study¹⁰ in the same center used concomitant chemoradiotherapy and adjuvant chemotherapy for treatment of nasopharyngeal tumors only who reported (81%). On the other hand, if we compare our results with that reported by Brockstein et al.⁸ who treated his patients with concomitant chemoradiotherapy without adjuvant chemotherapy, we found that our results is evidently higher (78% versus 69%).

The estimated two years overall survival in the current study was 89% this figure was similar to that reported by Hadir et al.¹⁰ and Joseph et al.¹⁵ who reported 90%

and 88% respectively and it is higher than that reported by Brockstein et al.⁸ who used concurrent CRT alone and reported 71% overall survival.

CONCLUSION

Concurrent chemoradiotherapy has produced improved results in patients with advanced head and neck cancers concerning locoregional control, disease free survival and overall survival, however more was achieved, especially concerning reduction of distant failure, by addition of adjuvant chemotherapy.

Docetaxel in combination with cisplatin is proved to be an effective combination in this setting, however we could not ignore the occurrence of some side effects such as mucositis and neutropenia that lead to treatment gap during radiotherapy and delay of some chemotherapy cycles, this necessitate that future therapeutic strategies should focus on decreasing the rate of these toxicities by the use of growth factors, in addition to full nutritional support.

REFERENCES

- Jemal A, Tiwari RC, Murray T, Ghafoor A, Samuels A, Ward E, et al. Cancer statistics, 2004. *CA Cancer J Clin* 2004 Jan-Feb;54(1):8-29.
- Baselga J, Trigo JM, Bourhis J, Tortochaux J, Cortes Funes H, Hitt R, et al. Phase II multicenter study of the antiepidermal growth factor receptor monoclonal antibody cetuximab in combination with platinum-based chemotherapy in patients with platinum-refractory metastatic and/or recurrent squamous cell carcinoma of the head and neck. *J Clin Oncol* 2005 Aug 20;23(24):5568-77.
- Pignon JP, Bourhis J, Domenge C, Designe L. Chemotherapy added to locoregional treatment for head and neck squamous-cell carcinoma: Three meta-analyses of updated individual data. MACH-NC Collaborative Group. Meta-Analysis of Chemotherapy on Head and Neck Cancer. *Lancet* 2000 Mar 18;355(9208):949-55.
- Al Sarraf M, LeBlanc M, Giri PG, Fu KK, Cooper J, Vuong T, et al. Chemoradiotherapy versus radiotherapy in patients with advanced nasopharyngeal cancer: Phase III randomized Intergroup study 0099. *J Clin Oncol* 1998 Apr;16(4):1310-7.
- Adelstein DJ, Li Y, Adams GL, Wagner H, Jr, Kish JA, Ensley JF, et al. An intergroup phase III comparison of standard radiation therapy and two schedules of concurrent chemoradiotherapy in patients with unresectable squamous cell head and neck cancer. *J Clin Oncol* 2003 Jan 1;21(1):92-8.
- Forastiere AA, Goepfert H, Maor M, Pajak TF, Weber R, Morrison W, et al. Concurrent chemotherapy and radiotherapy for organ preservation in advanced laryngeal cancer. *N Engl J Med* 2003 Nov 27;349(22):2091-8.
- Cooper JS, Pajak TF, Forastiere AA, Jacobs J, Campbell BH, Saxman SB, et al. Postoperative concurrent radiotherapy and chemotherapy for high-risk squamous-cell carcinoma of the head and neck. *N Engl J Med* 2004 May 6;350(19):1937-44.
- Brockstein B, Haraf DJ, Rademaker AW, Kies MS, Stenson KM, Rosen F, et al. Patterns of failure, prognostic factors and survival in locoregionally advanced head and neck cancer treated with concomitant chemoradiotherapy: A 9-year, 337-patient, multi-institutional experience. *Ann Oncol* 2004 Aug;15(8):1179-86.
- Denis F, Garaud P, Bardet E, Alfonsi M, Sire C, Germain T, et al. Final results of the 94-01 French Head and Neck Oncology and Radiotherapy Group randomized trial comparing radiotherapy alone with concomitant radiochemotherapy in advanced-stage oropharynx carcinoma. *J Clin Oncol* 2004 Jan 1;22(1):69-76.
- Meir H, Ashour W, Talaat E, Omer H, Al-Moubark M. Concomitant chemoradiotherapy followed by adjuvant chemotherapy in locally advanced nasopharyngeal carcinoma. *Med J Cairo Univ* 2003;71(3 Suppl):181-90.
- Ang KK. Concurrent radiation chemotherapy for locally advanced head and neck carcinoma: Are we addressing burning subjects? *J Clin Oncol* 2004 Dec 1;22(23):4657-9.
- Huguenin P, Beer KT, Allal A, Rufibach K, Friedli C, Davis JB, et al. Concomitant cisplatin significantly improves locoregional control in advanced head and neck cancers treated with hyperfractionated radiotherapy. *J Clin Oncol* 2004 Dec 1;22(23):4665-73.
- Wee J, Tan EH, Tai BC, Wong HB, Leong SS, Tan T, et al. Phase III randomized trial of radiotherapy versus concurrent chemoradiotherapy followed by adjuvant chemotherapy in patients with AJCC/UICC (1997) stage 3 and 4 nasopharyngeal cancer of the endemic variety. Annual Meeting Proceedings of the ASCO Meeting 2004;23:487.
- Al-Sarraf M, LeBlanc M, Giri PGS, Fu K, Cooper J, Vuong T, et al. Superiority of five year survival with chemo-radiotherapy (CT-RT) vs radiotherapy in patients (Pts) with locally advanced nasopharyngeal cancer (NPC). intergroup (0099) (SWOG 8892, RTOG 8817, ECOG 2388) phase III study: final report (abstr 905). *Proc Am Soc Clin Oncol* 2001;20:227a.
- Wee J, Tan EH, Tai BC, Wong HB, Leong SS, Tan T, et al. Randomized trial of radiotherapy versus concurrent chemoradiotherapy followed by adjuvant chemotherapy in patients with American Joint Committee on Cancer/International Union against cancer stage III and IV nasopharyngeal cancer of the endemic variety. *J Clin Oncol* 2005 Sep 20;23(27):6730-8.
- Kohno N. The role of chemotherapy for advanced oro and hypopharyngeal cancer. *Auris Nasus Larynx* 2004 Jun;31(2):113-8.
- Schrijvers D, Vermorken JB. Role of taxoids in head and neck cancer. *Oncologist* 2000;5(3):199-208.