

The efficiency of Intra-articular injection of amphotericin B in inducing arthritis in experimental Equine model

Shamaa, A*, Mokbel, A**, El-Tookhy, O***, and Mostafa, A****

*Surgery, Anesthesiology and Radiology Dept., Faculty of Veterinary Medicine. Cairo Univ., Egypt.

**Rheumatology and Rehabilitation, Faculty of Medicine. Cairo Univ., Egypt.

***Surgery, Anesthesiology and Radiology, Faculty of Veterinary Medicine, Cairo Univ., Egypt.

****Pathology, National Cancer Institute. Cairo Univ., Egypt.

Received: 19/12/2010

Accepted: 28/12/2010

SUMMARY

This study was carried out to verify the clinical efficiency of amphotericin B to induce arthritic changes when injected intra-articularly in equines and to correlate to the histopathological findings. Twenty mg Amphotericin B were injected in right radio-carpal joints of 9 donkeys. Animals were grouped equally into three groups based on the observation time -period after injection-(3, 6 and 9 weeks) to evaluate the different degrees of arthritis. Clinical, radiological, histopathological assessments together with synovial fluid analysis were done.

The arthritic changes were observed in all groups. Acute inflammatory reaction developed few hours post injection manifested by lameness, swelling of the joint with significant increase in total protein, enzymes, cell count

and mucin precipitation. Macroscopic findings were limited to discoloration of the articular cartilage, few hemorrhagic areas in the joint capsule with slight roughness of the articular surface in old cases. Radiographic arthritic evidences included synovial capsular swelling in acute cases and narrowing of the joint space in chronic ones. Histopathological changes revealed degeneration and thinning of both cartilage and bone, synovitis, capsulitis and osteophytes formation. The cartilage matrix lost its architecture with fibrous replacement.

In conclusion: different degrees of persistent arthritis could be achieved with a single IA injection of amphotericin B in Equine. Joints of these experimental animals are considered as a model of arthritis and can be used for testing different recent treatment techniques.

Keywords: amphotericin B, arthritis, equine, model, synovial analysis

INTRODUCTION

Arthritis is a complex, self-perpetuating series of events associated with number of risk factors including mechanical, biochemical and genetic factors (Johnson, et al., 1994, Boileau et al., 2004, Holderbaum et al., 2005 and Mandelbaum et al., 2005). It is one of the most commonly diagnosed orthopedic problems both in human and animals. The pathology and pathogenesis are similar in the most common forms of human and animals (Bendele, et al., 1999).

Many reasons contributed to the difficulty of studying osteoarthritis (OA), e.g. the disease occurs naturally with fairly slow progression hence the period for treatment is comparatively long. Also, the low sensitivity of diagnostic tools and the low availability of diseased tissues explain why research on animal models remained highly dynamic (Ameye et al., 2006) and have had contributed to the understanding of basic mechanisms of joint disease (Van den Berg, 2009).

Animal models of OA commonly used in testing are generally either naturally occurring in aging animals or surgically induced models (Bendele, et al., 1999 and Van den Berg, 2001). Other animal models of OA include genetically

modified mice, as well as enzymatically or chemically induced models (Van den Berg, 2001).

Over the past century, several methods for chemical induction of OA have been described. Axhausen (1910) and Burchardt(1924) used an application of tincture of iodine or ammonium hydroxide. Seeliger (1926) and Key (1932) used I A injection of HCl. Weissman, et.al. (1965) induced acute and chronic arthritis by streptolysine. Later on, Edwards, et al., (1977), Bowman, et al., (1983) and Fahmy, et al., (1994) used amphotericin B for induction of OA in equines. Amphotericin B is an antifungal Polyene antibiotic obtained from a strain of *Streptomyces nodosus*. The drug acts by binding to sterols in the cell membrane of susceptible fungi with a resultant change in membrane permeability allowing leakage of intracellular components. Mammalian cell membranes also contain sterols and it has been suggested that the damage to these cells and fungal cells may share common mechanisms (Bonagura, 2000).

The aim of the present study is in two folds: 1) to assess the effect of amphotericin B in inducing different degrees of arthritis and to correlate the clinical findings with the radiological and histopathological ones; 2) establishment of animal models of arthritis to

be used to evaluate and improve various diagnostic and therapeutic techniques.

MATERIALS AND METHODS

All experimental procedures in this study were approved by the committee of research ethics in Faculty of veterinary medicine, Cairo University and the work was carried out under the medical supervision of the Faculty Veterinarians.

Animals and groups:

This work was done on 18 carpal joint (nine donkeys), aging between 2–4 years and weighing between 150–200 Kg. Animals were obtained, housed and supervised at the Department of Surgery, Anesthesiology and Radiology, Faculty of Veterinary Medicine, Cairo University. They were fed a standard diet and had water ad lib. Donkeys were numbered and randomly assigned into three equal groups according to the follow up period after the I A injection of amphotericin-B. These groups were, Group one (3 weeks), Group two (6 weeks) and Group three (9 weeks). The right joint of each animal was used in the experimental work for induction of arthritis, whereas the left one was the control.

The work procedures included: a) Examination and Preparation of animals; b) Induction of OA and c) Follow-up and

assessment for 3, 6, and 9 weeks post injection of Amphotericin B.

A- Preparation:

All animals in this work were subjected to complete visual inspection and clinical examination. Only sound animals, without any motion abnormalities, were included in this study. Animals were prepared with Ivermectin preparation. X-ray filming of the carpal joints prior to any interference was done. The settings of the x-ray machine were 50Kv and 2mA/sec exposure time and FFD 90cm. Four different views of the carpal joint were performed (Lateral view; anterior-posterior view; cranio-palmer view and lateral flexed). The degree of arthritic changes was scored using a 0 to 4 scale adapted from Crawford, et al. (1991, Table 1). Radiographs were made for each carpus of each animal on day 0, and on weekly afterwards.

B- Induction of arthritis:

Once an animal was approved for the study, the appropriate forelimb carpal region was prepared with shaving hair and aseptic skin preparation using a povidone iodine scrub and 70% isopropyl alcohol swabs. Two ml of synovial fluid were aspirated into (EDTA) tubes for analysis from the right and left carpal joints by introducing a sterile 18-gauge needle at the radio-carpal space. One ml of each sample was used for determinations of total white cell count, total erythrocyte count, total

protein and mucin clot characteristics. The remainder of the sample was stored at -20°C for subsequent determination of alkaline phosphatase (ALP), Lactic acid dehydrogenase (LDH), Alanine aminotransferase (ALT) and aspartate aminotransferase (AST) levels.

At the same procedure, the right carpal joint received a single shot of IA injection of 2 ml Amphotericin B (10mg) while the left carpal joint received 2 ml sterile saline as a control. The degree of lameness was scored using a 1 to 5 scale adapted from Crawford, et al. (1991; Table 2). To score the severity of lameness, each animal was evaluated for lameness twice weekly and assigned a lameness score. To eliminate inter-observer variation, all lameness scores were assigned by the veterinarian blinded to treatment with training and expertise in equine lameness assessment.

Intra-observer variability was assessed periodically by randomly selecting animals for repeated assessment to ensure consistency of scoring. All lameness examinations were performed on even, non-sloped concrete floors free of obstructions and debris. Each lameness score was determined by watching the animal walk a minimum of 10 m in a straight line, turn, and walk back to the starting point. In order to have consistent time intervals between samplings or observations, these procedures

were conducted on the same experimental day for each group.

C-Synovial fluid analysis

C.1- Physical characters: The appearance and color of the synovial fluid were evaluated at the time of arthrocentesis. The tendency of a sample to clot was recorded. The mucinous precipitate quality was determined by adding 0.5ml of synovial fluid to 2ml of 2% acetic acid and mixing rapidly with glass rod as described by Van Pelt et al., (1963). The mucin clot was graded as follows: (1) Normal (N) a light, ropey clump in a clear solution, (2) Fair (F) a light soft mass in slightly turbid solution, (3) Poor (P) a small friable mass in a turbid solution and (4) Very poor (VP) a few flacks in a very turbid solution. For statistical purposes, a numerical value was assigned to each descriptive classification of mucinous precipitation, N= 4, F= 3, P= 2 and VP= 1. The relative viscosity of each synovial sample was determined with viscometer.

C.2- Cytological examination: Counting red and white blood cells in the synovial fluid samples was performed using a Neubauer haemocytometer. Synovial smears were performed directly from the synovial fluid. The centrifugation was performed in case of synovial fluids with low cellular content and smears were made from the sediment. The smear was air dried, fixed with methyl alcohol

and stained with May-Grunewald Giemsa stains. Sample of synovial fluid in which gross evidence of blood observed were excluded (Knottenbelt, 2006).

C.3- Biochemical analysis: The total protein was measured. The activities of enzymes (ALP, LDH, ALT and AST) in synovial fluid samples were estimated.

D-Macroscopical examination:

Necropsy was performed on each animal. The skin was removed from the Carpi and transverse cuts were made with a band saw through the radius just above the distal epiphysis and through the metacarpus below the carpo-metacarpal joint. The carpal canal was removed to allow complete extension of the carpus. The carpus was then opened at radio-carpal joint, metacarpal joint. The synovial membrane and fibrous joint capsule could be examined. The cartilage surface of the bone, each cut, also, was carefully examined.

E-Microscopical examination:

All cases were fixed in 10% neutral buffer formalin. Decalcification of tissue cases were done by using 8% formic acid decalcifying solution in distilled water. The decalcifying solution was renewed every 48 hours until softening of the tissues. The decalcified cases were then trimmed, washed and dehydrated in ascending grades of alcohol, cleared in xylene, embedded in paraffin,

sectioned at 4–6 μ m thickness and stained with haematoxyline and eosin (H&E) as well as Masson's Trichrome (MT) stain for detection of collagen fibers. Sections were evaluated under light microscopy and morphologically classified in accordance with Table 3, based on the histological scoring system of Mankin et al. (1971). In this study, grades of observed alterations were summed to graduate morphological lesions in each analyzed section. The sum of all characteristics, analyzed in each histological section, allowed for a better evaluation of cartilage morphology, as well as, to characterize the phase of the arthritis. The larger the sum of the score the more severe was the degenerative process in the articular cartilage.

RESULTS

Mild degree of OA was achieved 3-weeks post-injection with amphotericin B while the moderate and severe degrees were achieved after 6 and 9 weeks respectively. The different degrees of OA were assessed using the following parameters

1-Clinical lameness and swelling

The signs began within 3 hours post injection in the form of acute swelling as a result of joint capsule distention (Score 3) that persist and appear as enlargement of joint

circumference with average increase 1 ± 0.24 cm in comparison to the control joint. The lameness reach the top after 6 hours which persist for 3 days then decreased till the end of the experiment (score 2) and could detected by palpation and passive movement of carpal joint.

2. Radiological findings

The radiological examination revealed progressive changes in the carpal joint. There was marked soft tissue swelling (Score 2) for the first 3 days (Figure 1a&b), which decreased gradually to reach (Score 1) at 9 weeks. In the meantime, osteoarthritic changes in form of gradual narrowing of the joint space and thinning of the articular surface were progressively developing with time and could be noticed at 9 weeks (Figure 1c).

3-Synovial fluid analysis:

Physical, cytological and biochemical characteristics of synovial fluid analysis of all animal models of OA are summarized in table (4) and figure (2).

4- Macroscopical appearance:

Macroscopic appearance of the experimental induction groups showed slight yellowish discoloration of the articular surface with slight hemorrhagic areas at the joint capsule.

5-Microscopical appearance:

In sections of all cases, the more frequent histological findings that reflected the

degenerative effect of the drug were the presence of cartilage surface irregularities and fibrillation, edema, hypocellularity and reduction of metachromatic staining intensity.

The synovium showed focal papillary proliferation together with hyperemic dilated vessels and mild lymphocytic infiltration in joints injected with Amphotericin B of the 3 induction groups. It was observed that there was a cumulative effect of the drug with increase of the score through the 3 groups.

The 1st group (3 weeks post induction): Superficial zone fibrillation and fissures with diffuse hypercellularity and slightly decreased metachromatic staining. Mankin score ranged from 3 – 6, (Figure 3). The 2nd group (6 weeks post induction): Superficial zone fibrillation, irregularity with fissures in superficial and middle zone, hypocellularity and small erosions, and slightly decreased metachromatic staining. Mankin score ranged from 7 – 9, (Figure 4). The 3rd group (9 weeks post induction): a layer of roughened granulation tissue, or pannus was noticed protruding over the surface of the cartilage. Under the pannus the cartilage was eroded and destroyed with penetration of subchondral bone by blood vessels. Marked reduced metachromatic staining was observed. Mankin score ranged from 9 – 12, (Figures 5&6).

Table (1): Crawford et al., (1991) Radiographic score system

Radiographic evaluation
0 = normal
1 = synovial effusion and/ or mild joint distension
2 = marked joint distension with no bone or cartilage change
3 = minimal bone changes, osteophytes < 2 mm, with joint distension, no evidence of bone lysis or cartilage loss
4 = severe bone changes, osteophytes > 2 mm, with or without evidence of cartilage loss and/or bone lysis

Table (2): Crawford, et al. (1991) lameness score system

Lameness evaluation
1 = no evidence of lameness
2 = lameness barely detectable by expert observer
3 = lameness easily detectable, with noticeable head nod
4 = severe lameness, with marked head nod, and bearing weight on affected limb
5 = severe lameness characterized by non-weight bearing on affected limb

Table (3): Parameters of qualitative morphological evaluation of articular cartilage in experimentally induced arthritis (system of Mankin, et al., 1971)

Feature	Grade	Feature	Grade
I – Cartilage structure		II – Cellularity	
a) normal	0	a) normal	0
b) fibrillation in the superficial zone	1	b) diffuse hypercellularity	1
c) fibrillation in the middle zone	2	c) clones	2
d) irregularities in the superficial zone	3	d) hypocellularity	3
e) fissures	4		
f) erosion	5		
g) pannus	6		
III – Metachromatic staining			
a) normal	0		
b) slight reduction	1		
c) moderate reduction	2		
d) severe reduction	3		
e) absent	4		

*Modified by Mankin et al., 1971

Table (4): Summary of the physical, cytological and biochemical characteristics of synovial fluid analysis of the induction

	Viscosity	Appearance	Mucin ppt	Clot	pH	Total protein	AST	ALT	AIK	LDH	WBCs	RBCs
Control	15.5±3.0	Colorless & clear	4	-ve	7.31±0.04	1.56±0.06	15.33±2.76	6±2	12±2.0	36.5±11.5	33.33±7.3	10.66±10.66
3 weeks	10.91±1.09	pale yellow & clear	3.33±0.33	+ve	6.99±0.06	3.56±0.04	38±4.0	42.66±6.6	57±5.0	136.66±8.6	248.33±19.3	601±89
6 weeks	7.83±1.3	Yellow & clear	2.66±0.23	+ve	6.91±0.11	3.58±0.38	64.66±4.4	75.33±5.3	92.66±4.6	256.66±16.6	680±40.0	261.33±11.3
9 weeks	5.66±1.9	Yellow & turbid	2.33±0.19	+ve	6.75±0.9	4.66±0.4	82.66±2.4	88±4.0	133.33±2.6	435.33±20.0	796.66±50.4	183.33±16.7

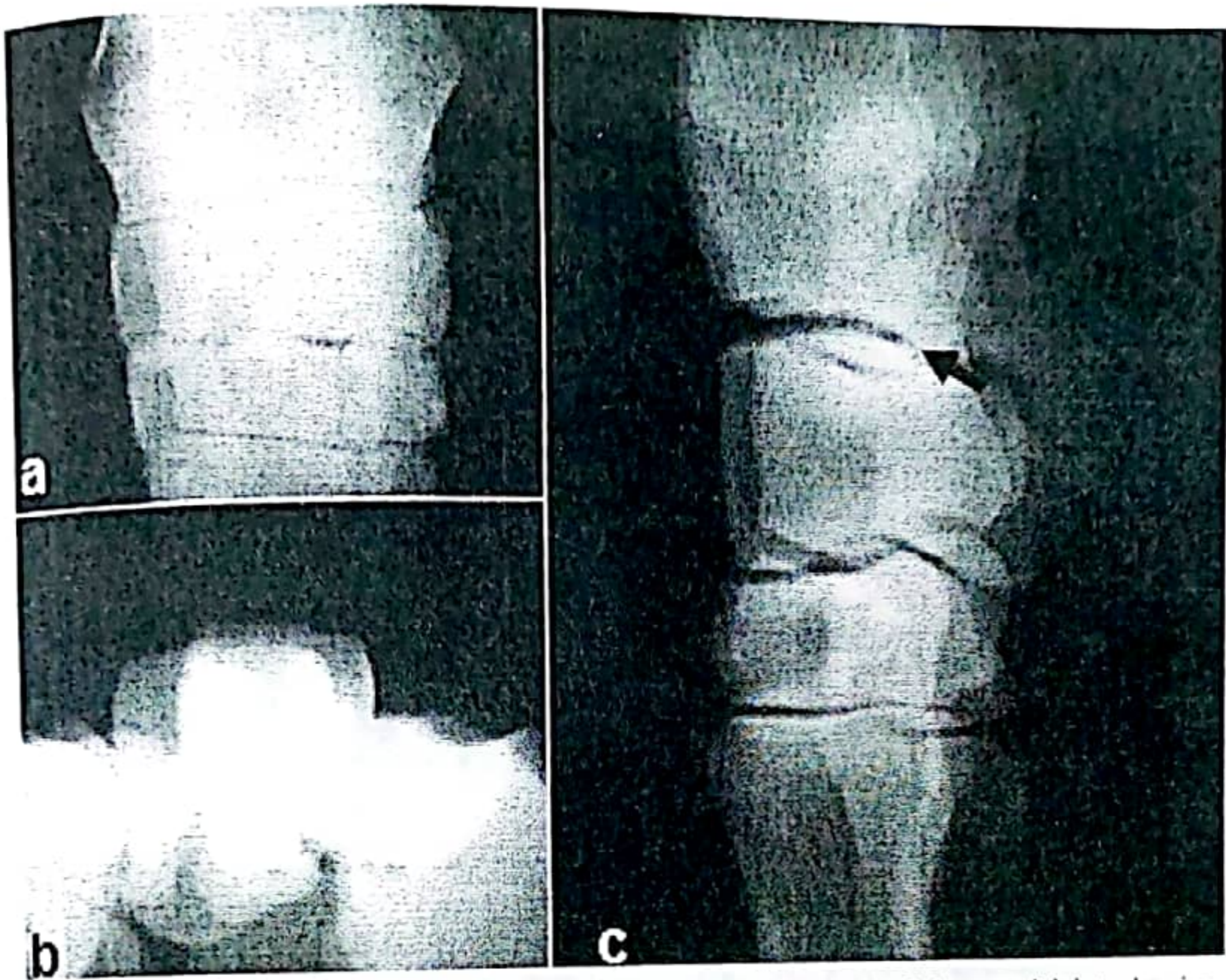


Fig (1): Antero-posterior radiographic image (a) and lateral flexed (b) of the carpal joint, showing arthritic changes manifested by marked soft tissue swelling (Score 2) at 3days post injection of Amphotericin B (arrows). (c): Lateral radiographic image of the carpal joint, showing arthritic changes manifested by slight swelling (Score 1) and narrowing of joint space (Score 3) at 9weeks post injection of Amphotericin B (arrow).

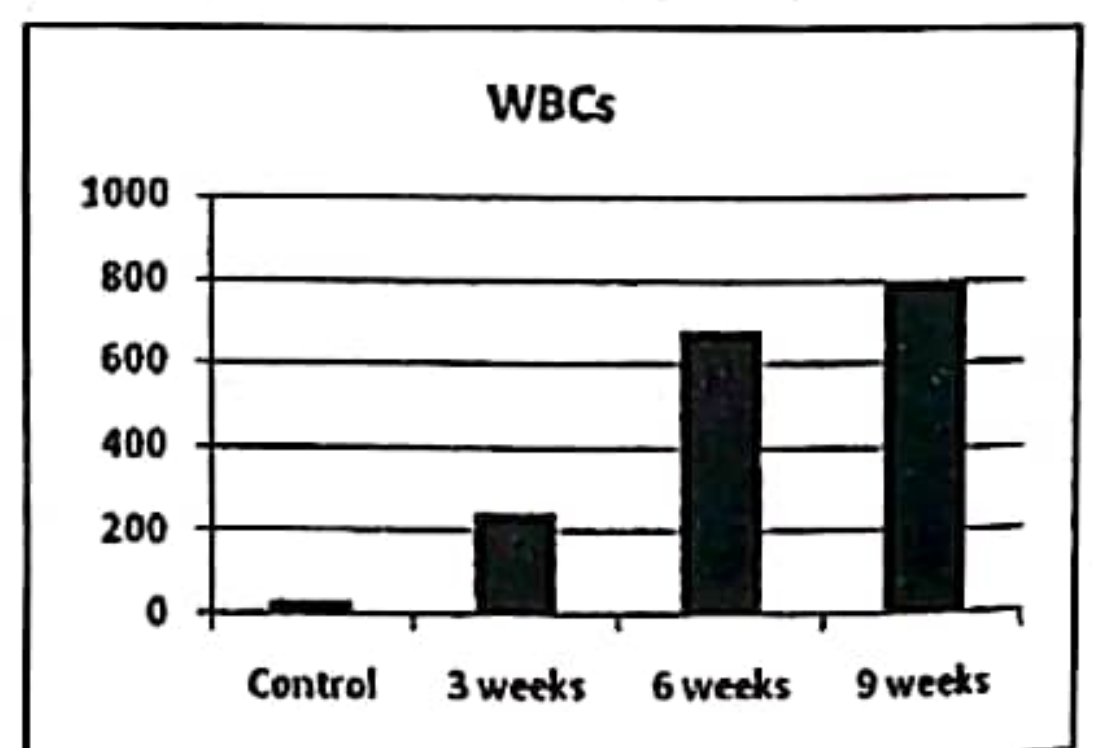
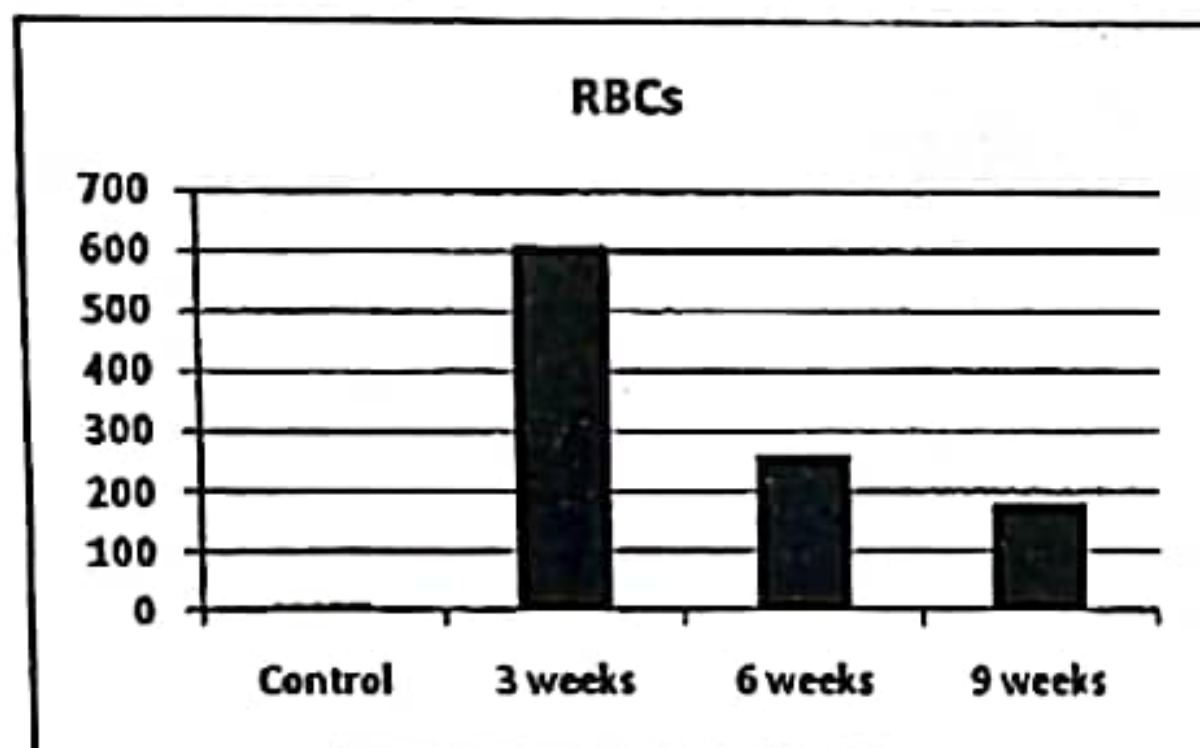
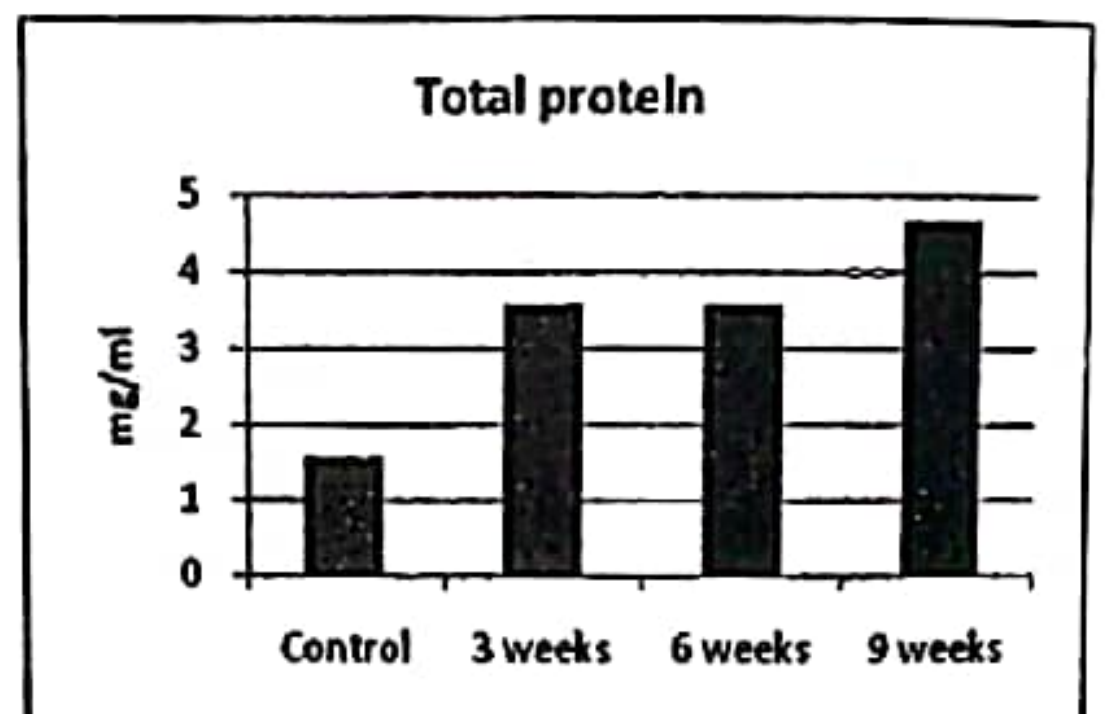
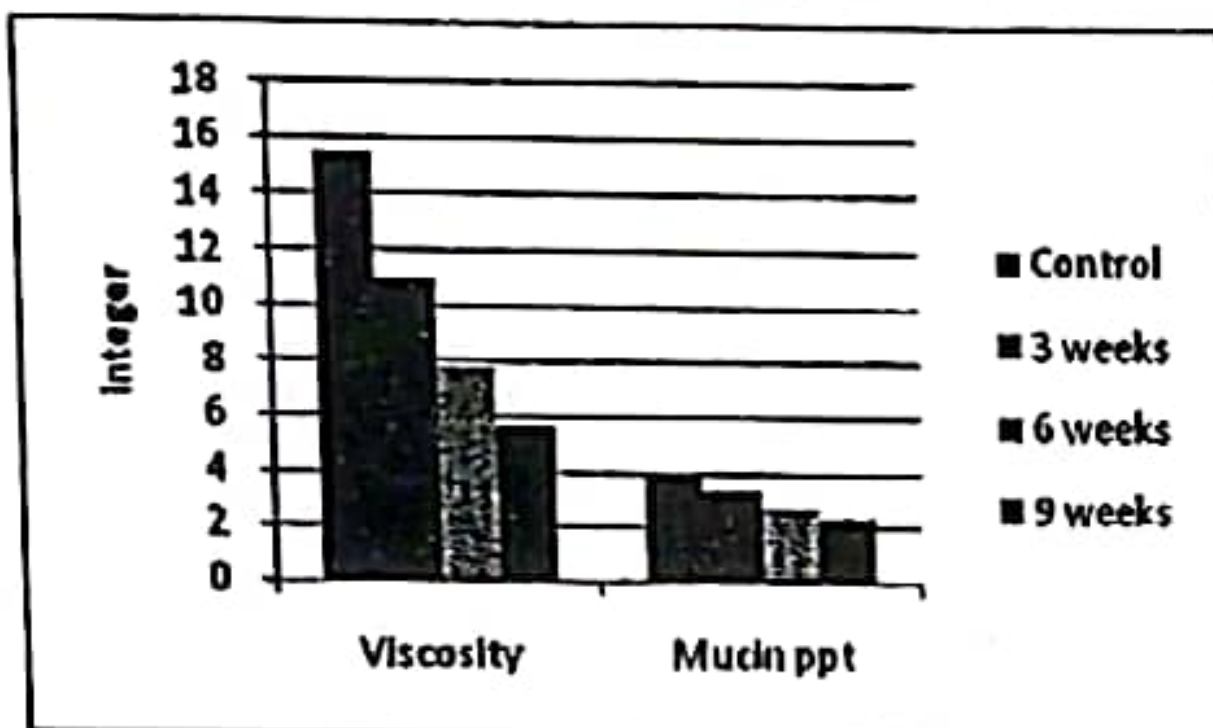
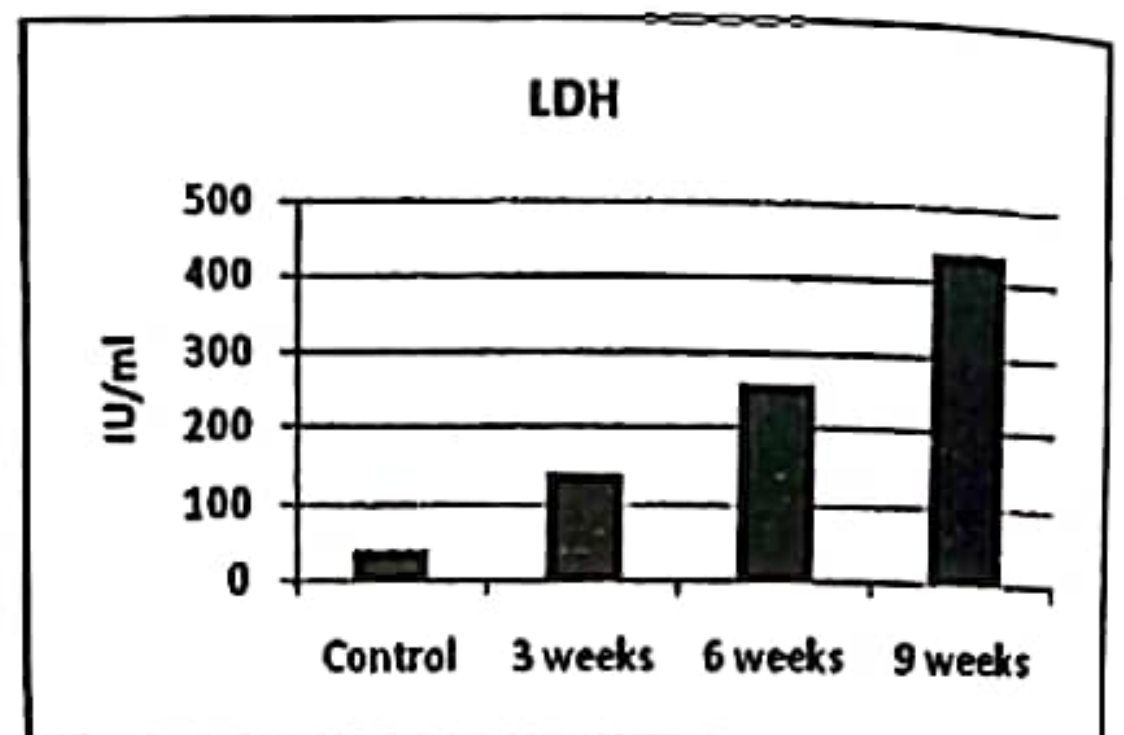
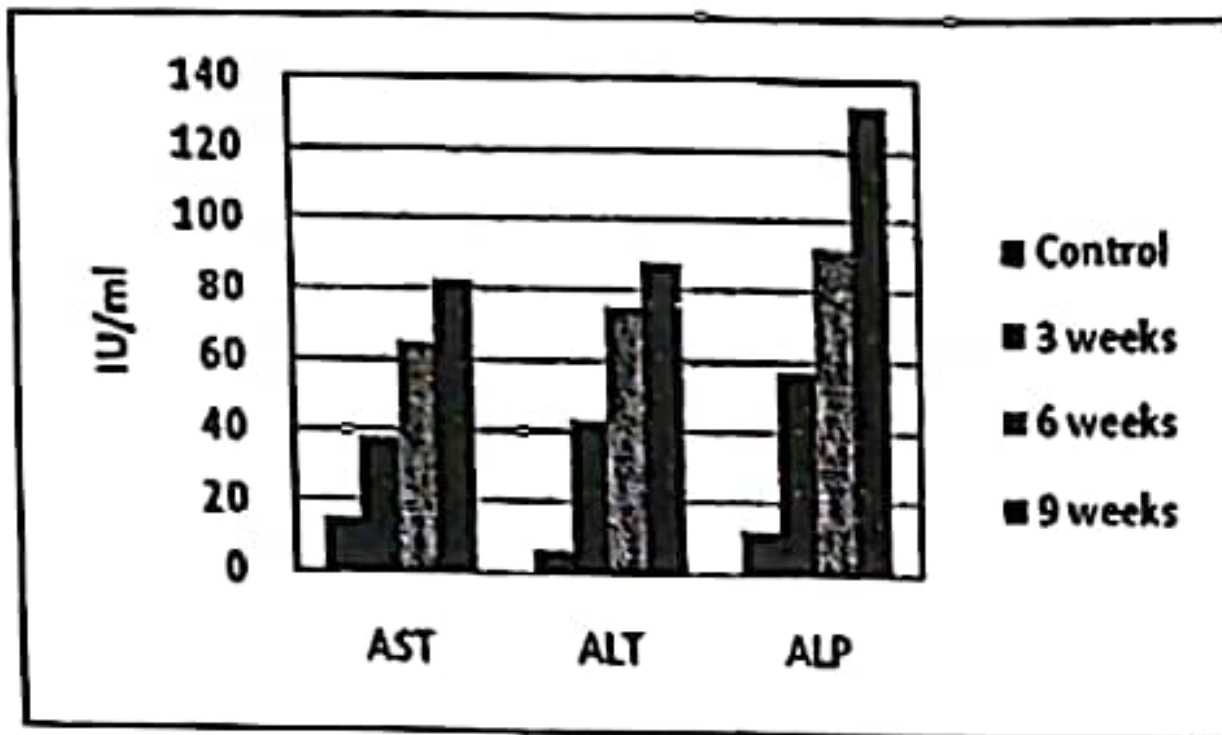


Fig (2): Histograms showing physical, cytological and biochemical characteristics of synovial fluid analysis of the control and experimental groups.




Fig (3): photomicrograph graph of articular cartilage 3 weeks post induction of OA showing: a) Superficial zone fibrillation (arrow) with diffuse hypercellularity (H&E, 100x); b) Slightly decreased metachromatic staining with fissures (arrows) in superficial zone (MT, 100x).

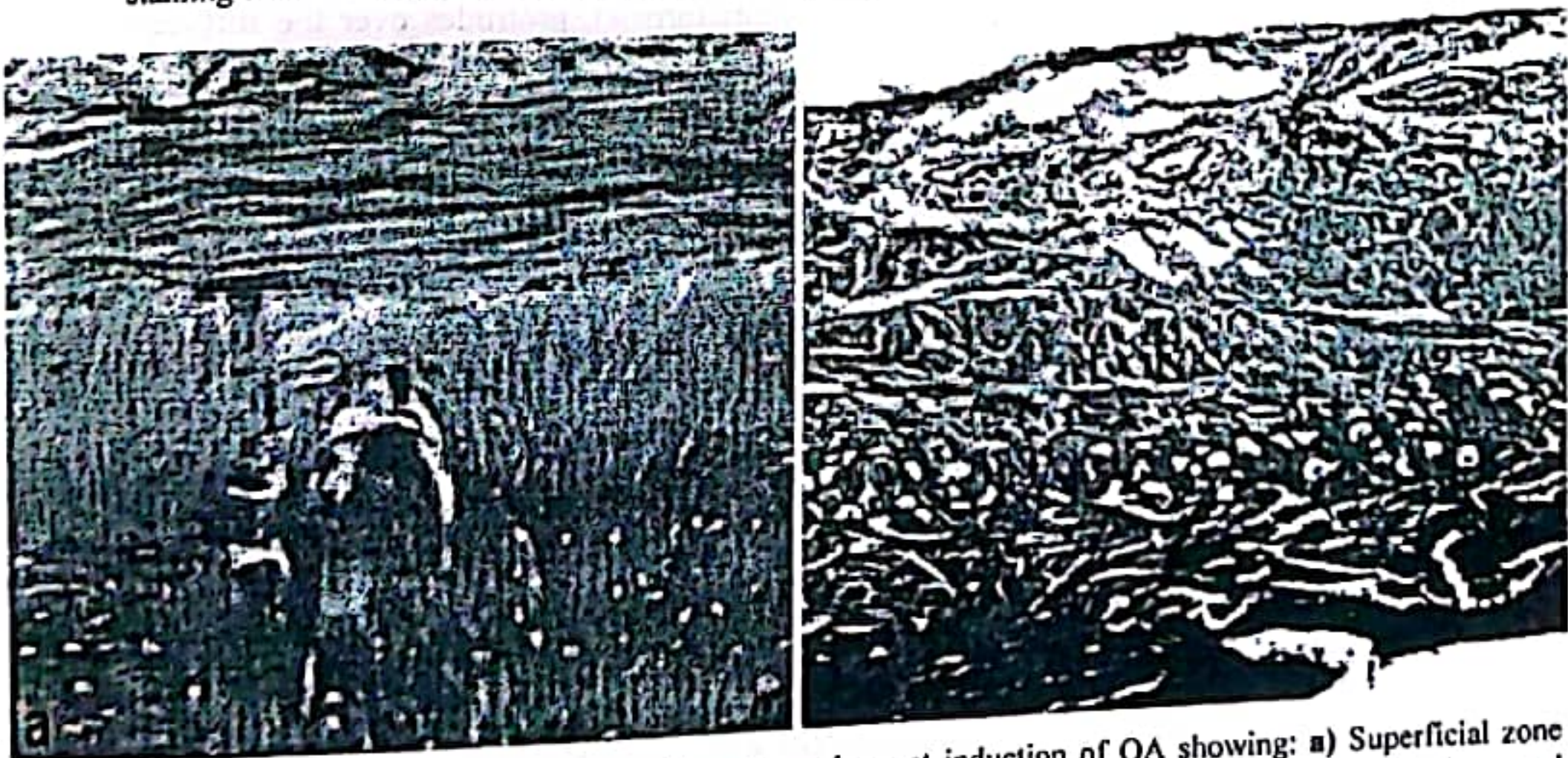


Fig (4): photomicrograph graph of articular cartilage 6 weeks post induction of OA showing: a) Superficial zone fibrillation, irregularity, hypocellularity and small erosions (H&E, 100x); b) Slightly decreased metachromatic staining with fissures in superficial & middle zone (MT, 100x).

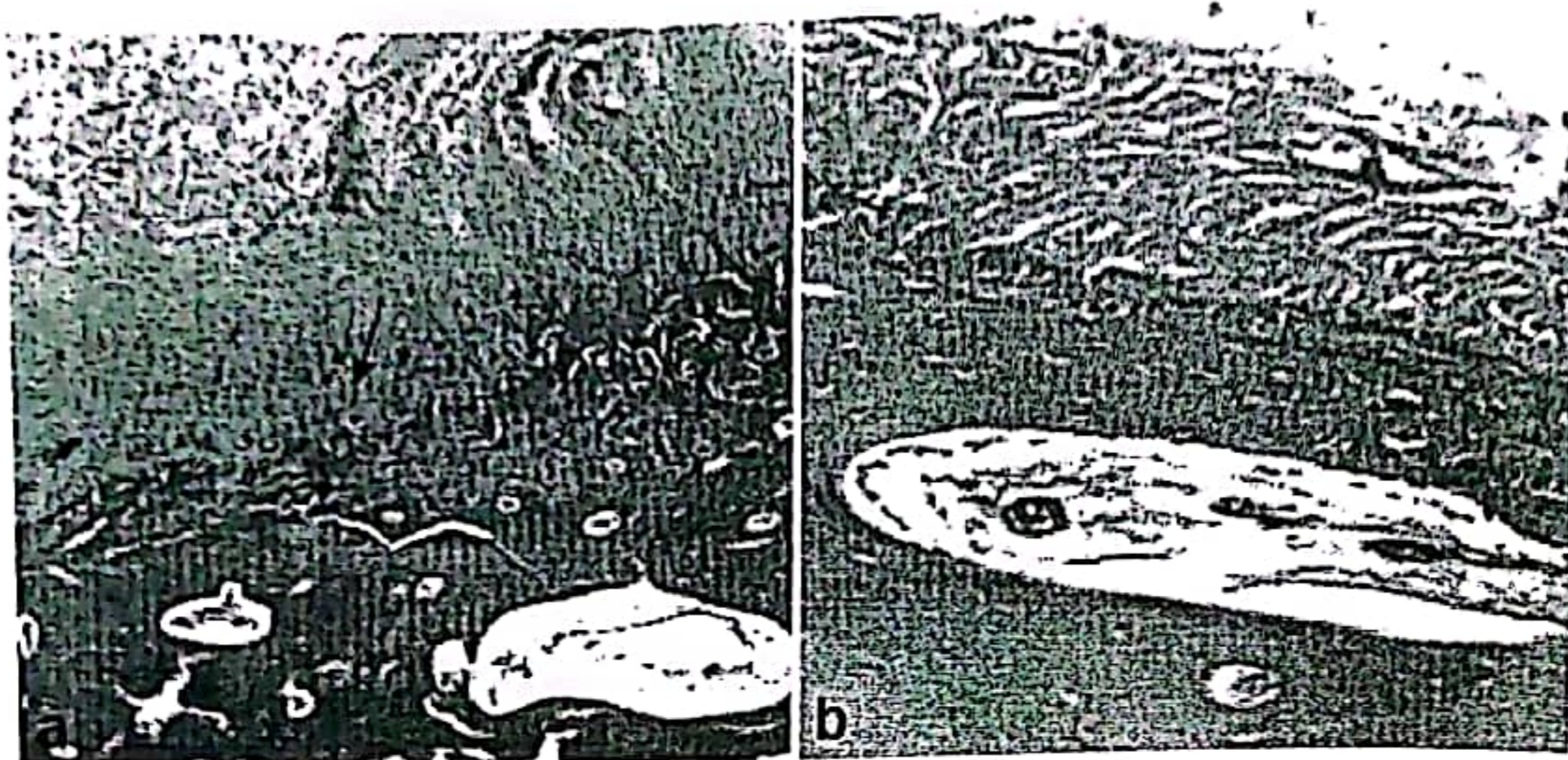


Fig (5): photomicrograph graph of articular cartilage 9 weeks post induction of OA showing: (a&b) a layer of roughened granulation tissue, or pannus (arrow), protrudes over the surface of the cartilage. Under the pannus the cartilage is eroded and destroyed (H&E, 100x).




Fig (6): photomicrograph graph of articular cartilage 9 weeks post induction of OA showing: a) Complete loss of cartilage, pannus formation with penetration of subchondral bone by blood vessels (H&E, 100x) and b) Markedly reduced metachromatic staining with loss of chondrocytes (MT, 100x).

DISCUSSION

The use of animal models is influential in understanding the etiology and the pathogenic mechanisms of arthritis as well as other medical conditions. Animal models have contributed considerably to the understanding of the arthritic processes and concomitant cartilage and bone destruction (Van den Berg, 2009) and

subsequently it have been used in evaluating the clinical outcomes of potential anti-arthritis drugs (Bendele, et al., 1999).

Different techniques were used to create animal models of arthritis. Various animal species has been used as models of traumatic or surgically induced arthritis. Traumatic OA does occur in humans, and therefore these models may mimic aspects of pathogenesis and

pathology. One important difference however is that humans with a traumatic injury generally discontinue use of the affected limb. Animals in the same situation generally do not. Therefore, the disease progression is usually much more rapid in the animal models (Bendele, et al., 1999).

Chemically induced models of OA in horses have been established through IA injection of chemicals such as polyene antibiotics; cFilipin (McIlwraith, et al., 1979 and McIlwraith, 1990), and Amphotericin B (McIlwraith, et al., 1981, Bowman, et al., 1983), Freund's adjuvant (Hamm, et al., 1984), and sodium monoiodoacetate (Trotter, et al., 1989). However, none of these experimental models reproduced completely the clinical and pathological changes seen.

The dosage of Amphotericin B required to induce arthritis varied. Suominen, et al., (1999) reported that IA injection of Amphotericin B consistently resulted in aseptic arthritis in horses. Twenty mg of Amphotericin B as a single IA injection in the right intercarpal joint was enough to induce aseptic arthritis in 24 Standard bred horses (Marttinen, et al., 2006). These results are comparable with those of Crawford, et al., (1991) who reported that synovitis was induced in the middle carpal joints (MCJ) of ponies by injecting 10 mg of Amphotericin B into that joint on day 1 of the

experiment. In studies of evaluating lameness, pain, and the effectiveness of certain non-steroidal anti-inflammatory agents and other pain alleviating agents, Bowman, et al., (1983); Crawford, et al., (1991); Fahmy, et al., (1994); Hegazy, et al., (1994) used Amphotericin B to induce arthritis in horses utilizing a single IA injection of 10 mg Amphotericin B. The induced arthritis could be examined biochemically as early as few hours post injection and histopathologically after one week and progressively afterwards.

In order to provide a longer period, greater degree of lameness and for a more severe arthritis model, Amphotericin B was used in three injections in a second group where multiple doses of 10 mg of Amphotericin B in the right MCJs on days 1, 4, and 18 of the experiment were received (Crawford, et al., 1991).

Amphotericin B was selected for the present study to create an arthritis model that would exhibit lameness for several weeks following a single IA injection similar to that used by Crawford, et al., (1991) and that could be used for later evaluation of recent cell treatment technique.

Arthritis was experimentally induced in the radio-carpal joint of 9 donkeys by a single IA injection of 2ml of 10mg of Amphotericin B. Symptoms of acute inflammatory reaction

developed 3 hours post injection and included lameness and swelling of the joint. The severity of lameness and the degree of swelling varied. Suominen, et al., (1999) reported lameness of the 5th grade on lameness scoring system on day 0 after a single injection of 10mg Amphotericin B. In our study, lameness could be detected during normal gait in the first week (score 3) and appeared on passive flexion of the carpal joint after that. Later on lameness started to improve (score 2) till the end of the experiment indicating that acute inflammation was turning on to the chronic degenerative form. However, lameness that persisted longer was possibly as a result of more delayed effect of Amphotericin B as mentioned by Fahmy, et al., (1994).

The fact that Amphotericin B has an early toxic effect on cartilage matrix as well as synovial membrane leading to synovitis and capsulitis explains the swelling of the concomitant joint that appeared as enlargement of joint circumference with average increase 1 ± 0.24 cm in comparison to the control limb. In addition it has direct toxic effect on chondrocyte resulting in osteoarthritic changes in the injected joint (Fahmy, et al., 1994) with increased synovial production and reduction of desorption (Fournier, et al., 1969) and thickening of joint capsule. Such clinical arthritic symptoms declined gradually.

The recognized macroscopic findings were limited to the discoloration of the articular cartilage from the normal bluish-white into a yellowish color and some hemorrhagic areas in the joint capsule. Slight roughness of the articular surface was felt in the severe cases. This could be a result of the somatic toxic effect by a material released from the ruptured lysosomes on the joint compartment. An observation that resembles the tissue reaction found in rabbit joint after injection of streptolysine S (Weissman, et al., 1965) Filipin (McIlwraith, et al., 1979 and McIlwraith, 1990), and amphotericin B (McIlwraith, et al., 1981, Bowman, et al., 1983) in equines.

Radiographic arthritic evidence in the form of synovial capsule swelling was found in all animals with Amphotericin B treated joints after 3 weeks. Narrowing of the joint space was seen in the severe cases. All changes increased in severity in relation to the experimental time due to the progression of joint destruction. These results run hand to hand with those reported by McIlwraith, et al., (1979) Bowman et al., (1983) and Fahmy, et al., (1994). In the meantime the histopathological examination of the arthritic joints confirmed these results.

Synovial fluid analysis of great value to the equine practitioner as a mean of determining the cause, type (inflammatory or non-inflammatory), duration and the stage of

the disease (acute inflammatory phase or degenerative phase or destructive phase). It was found that there is a close correlation between the enzyme activity in the synovial fluid especially ALP, LDH, AST, ALT and severity of the changes in the joint as a result of disease. All these findings are useful in therapeutic management and its follow up as reported in our present experimental work and that described by Ropes (1957) and VanPelt (1971).

Intra-articular injection of Amphotericin B consistently resulted in a significant increase in the immune reactivity of matrix metalloproteinase MMP-8 and activity of both the latent and active forms of MMP-2 and -9, MMP-9 levels declined to pre-induction levels within 2 weeks, whereas levels of MMP-2 remained still high after 5 weeks (Marttinen, et al., 2006). Such results proved that after acute arthritis induction by IA injection of Amphotericin B; elevated MMP activity is present in the joint for several weeks to a degree that could promote cartilage degradation.

Relying on the present results, the model of chemically induced arthritis could be classified into three main stages. The first acute inflammatory stage is characterized by highly significant increase in the total protein, LDH, ALP and AST which could be considered as indicator. An increase in monocytes,

neutrophils and mucin precipitation was also recorded. These findings agree with those reported by Mackay-Smith (1962); Hunt (1965); Anon (1966) and McIlwraith, et al., (1979), McIlwraith (1990) and Crawford, et al. (1991). The increase in total WBCs count in the synovial fluid is attributed to an increase in capillary permeability which permits the higher molecular weight protein fraction to enter the joint (Curtis, 1964). The permanent passage and retention of proteins in synovial fluid was reported by Cohen (1967) and Schubert et al. (1968). The second moderate stage of chemically induced arthritis (6 weeks-second phase) was characterized by progressive changes of the synovial fluid levels (increase AST, ALT, ALP, LDH and WBCs, monocyte and neutrophil count with decrease in viscosity and mucinous precipitation) indicating progressive destruction of the articular cartilage. The third severe stage of chemically induced arthritis (9 weeks-third phase) was characterized by progressive changes of the synovial fluid levels till the end of the study. It was characterized at first by reduction in neutrophiles count and an increase in ALP, AST and LDH levels, In addition to increase in monocytes. These changes in synovial parameters can be interpreted as a result of the synovial membrane inflammation as well as massive matrix destruction which were

confirmed by the pathological examination (McIlwraith, 1981 and Clyne, 1987).

Histopathological changes included degenerative changes in the cartilage and bone in addition to synovitis and capsulitis in the form of loss of cartilage matrix architecture, fibrous replacement of cartilage, osteophyte formation, cartilage loss and thinning. These findings are more or less similar to those obtained by Crawford, et al., (1991). Articular cartilage degradation consistently began as early as 3 weeks after induction. Early in pathogenesis, the profile of cartilage degradation initially reflects the edema and elimination of the superficial layer, and development of fissures into the mid-zone that are commonly observed during early stages of human OA (Aigner et al., 2007). The model also exhibits features that are characteristic to late-stage of human OA. At later time, loss of subchondral bone density and trabecular architecture were also present and are reminiscent of human OA as described by Felson et al., 2000 and Sarzi-Puttini, et al., 2005. Ultimately, these properties are likely to persist to end-stage OA, where joint failure occurs and invasive arthroplastic intervention is required.

Appleton et al., 2007 described a surgical method for induction of osteoarthritis in the knee joint of rats by surgery involving anterior

cruciate ligament transaction (ACL-T) and partial medial meniscectomy and reported similar histopathological results. However, authors assume that chemical induction of OA is better as it is an easy, rapid and less invasive technique.

In conclusion, having a model to evaluate parameters after lameness and arthritis induction is very important for evaluation of pharmacological agents, establishment of dosing regimens and to assess different treatment methodologies. Amphotericin B at 20 mg by IA injection provides an effective (time/severity) model for lameness in equine. Moreover the histopathological degenerative changes obtained by chemical induction are comparable with the findings of surgical method for OA induction.

REFERENCES

- Aigner, T., Sachse, A., Gebhard, P. M. and Roach, H. I. (2007): Osteoarthritis: pathobiology – targets and ways for therapeutic intervention. *Adv Drug Delivery Rev.* 58(2):128-149.
- Ameys, L. G. and Young, M. F. (2006): Animal Models of Osteoarthritis: Lessons Learned While Seeking the 'Holy Grail'. *Curr Opin Rheumatol* 18(5):537-547.
- Anon, M. (1966): Joint lameness: Etiology and treatment. *Mod. Vet. Pract.* 47(5) 51-92.
- Appleton, T. G., McErlain, D. D., Pitelka, V., Schwartz, N., Bernier, S. M., Henry, J. L., Holdsworth, D. W. and Beler, F. (2007): Forced mobilization accelerates pathogenesis:

characterization of a preclinical surgical model of osteoarthritis Arthritis Research & Therapy. 9(1): R13

Axhausen, G. (1910): Kritisches und Experimentelles zur Genese der Arthritis deformans, insbesondere die Bedeutung der aseptischen Knochen- und Knorpelnekrose. Arch. Klin. Chir. XCIV, 331.

Bendele, A., McAbee, T., Senello, G., Frazier, J., Chlipala, E., McCabe, D. (1999): Efficacy of sustained blood levels of interleukin-1 receptor antagonist in animal models of arthritis: comparison of efficacy in animal models with human clinical data. Arthritis Rheum 42:498-506.

Boileau, C., Martel-Pelletier, J., Guévremont, M., Pelletier, J. P., Poirier, F. and Reboul, P. (2004): Galectin-3 in osteoarthritis: from a protective to a destructive role. Arthritis Res Ther, 6 (Suppl 3):20

Bonagura, J. D. (2000): Kirk's Current Veterinary Therapy XIII. W.B.Saunders Company.327

Bowman, K. F., Purohit, R. C., Ganjam, V. K., Pechman, R. D. Jr. and Vaughan, J. T. (1983): Thermographic evaluation of corticosteroid efficacy in amphotericin B-induced arthritis in ponies. Am J Vet Res; (44): 51-56.

Burch-Haredt, H. (1924): Experimentelle Untersuchungen über die Beziehungen der Gelenk funktion zur Arthritis deformans. Arch. Klin. Chir. CXXXII 725-739

Clyne, M. J. (1987): Pathogenesis of degenerative joint disease. Eque.Vet. J., 19(1):15-18.

Cohen, A. S. (1967): Laboratory diagnostic procedures in rheumatic diseases. Arch. Rheu., 67(5):11-25-1126.

Crawford, W. H., Houge, J. C., Neirby, D. T., Di Mino, A. and Di Mino, A. A. (1991): Pulsed radio frequency therapy of experimentally induced arthritis in ponies. Can J Vet Res. (55):76-85.

Curtis, P. H. (1964): Changes produced in synovial membrane and synovial fluid by diseases. J. Bone joint Surg., 47-A: 1495.

Edwards, G. B. and Vaughan, L. C. (1977): Infective arthritis of the elbow joint in horses. Vet. Rec. 193:227.

Fahmy, A. S., Hegazy, A. A., Abdelhamied, M. A., Shamaa, A. A. and Schimke, E. (1994): Clinical, Biochemical and Histopathological studies on arthritis in equine. Vet. Med. J., Giza. 42(1):305-320.

Felson, D. T., Lawrence, R. C., Dieppe, P. A., Hirsch, R., Helmick, C. G., Jordan, J. M., Kington, R. S., Lane, N. E., Nevitt, M. C., Zhang, Y., et al. (2000): Osteoarthritis: new insights. Part 1: the disease and its risk factors. Ann Intern Med. 133:635-646.

Fournier, G., Ayotte, R. and Laurin, C. A. (1969): Pathogenesis of joint effusions: An experimental study. Can. Med. Assoc. J. 100:242.

Hamm, D., Goldman, J. and Jones, E. W. (1984): Polysulfated glycosaminoglycan: a new intra-articular treatment for equine lameness. Vet Med. 6: 811-816.

Hegazy, A. A., Fahmy, L. S., Fahmy A. S., Abdelhamied, M. A., Shamaa, A. A. and Schimke, E. (1994): Evaluation of the effects of intra-articular injection of dimethylsulfoxide on chemically induced arthritis in equines. Vet. Med. J. Giza. 42:221-243.

Holderbaum, D., Malvitz, T., Ciesielski, C. J., Carson, D., Corr, M. P. and Moskowitz, R. W. (2005): A newly described hereditary cartilage debonding syndrome. Arthritis Rheum. 52(10):3300-4.

Hunt, M. D. (1965): Traumatic arthritis in young thoroughbreds. Proc. R. Soc. Med. 58:370-372.

Johnson, B., Mosier, D. A., Morton, R. J. and Confer, A. W. (1994): Experimental

- Brucella abortus* strain-19 arthritis in young cattle. *Journal of Veterinary Diagnostic Investigation*, 6(1):56-61
- Key, J. A. (1932): The production of chronic arthritis by the injection of weal acids, distilled water and salt solution into joints. Annual Meeting of Am. Ortho Asso. Toronto. 16:67-83.
- Knottenbelt, D. C. (2006): *Saunders Equine Formulary*. Saunders Elsevier 1st Edition.
- Mackay-Smith, M. P. (1962): Pathogenesis and pathology of equine arthritis. *J. Am. Vet. Med. Assoc.*, 141(10): 1246-1248.
- Mandelbaum, B. R., Silvers, H. J., Watanabe, D. S., Knarr, J. F., Thomas, S. D., Griffin, L. Y., Kirkendall, D. T. and Garrett, W. J. r. (2005): Effectiveness of a neuromuscular and proprioceptive training program in preventing anterior cruciate ligament injuries in female athletes: 2 year follow up. *Am J Sport Med* 33, 1003-1011.
- Mankin, H. J., Dorfman, H., Lipiello, N. and Zarins, A. (1971): Biochemical and metabolic abnormalities in articular cartilage from osteo-arthritic human hips II: Correlation of morphology with biochemical and metabolic data. *J. Bone Joint Surg. Am.*, (53-A):523-537.
- Martinen, P. H., Raulo S. M., Suominen, M. M. and Tulamo, R. M. (2006): Changes in MMP-2 and -9 activity and MMP-8 reactivity after amphotericin B induced synovitis and treatment with bufexamac. *J. Vet. Med.* 53:311-318.
- McIlwraith, C. W. (1981): Idiopathic synovitis, traumatic and degenerative joint disease, In proceedings. *Am. Assoc. Eq. Pract.* 125-139.
- McIlwraith, C. W. and Van Sickle, D. C. (1981): Experimentally induced arthritis of the equine carpus: histologic and histochemical changes in articular cartilage. *Am J Vet Res.* 42(2): 209-217.
- McIlwraith, C. W., Fessler, J. F., Blevins, W. R., Page, E. H., Rebar, A. H., Van Sickle, D. C. and Coppoc, G. L. (1979): Experimentally induced arthritis of the equine carpus: clinical determinations. *Am J Vet Res* 40(1): 11-19.
- McIlwraith, C. W. (1990): Ultrastructural and histochemical studies of filipin induced equine arthritis. In: Todhunter R.J.; LUST, G. Pathophysiology of synovitis: Clinical signs and examination in horses. *Comp. Cont. Educ. Pract. Vet.*, (12):980-992.
- Ropes, M. W. (1957): Examination of synovial fluid. *Bull Rheum. Dis.* 7:21-22.
- Sarzi-Puttini, P., Cimmino, M. A., Scarpa, R., Caporali, R., Parazzini, F., Zaninelli, A., Atzeni, F. and Canesi, B. (2005): Osteoarthritis: an overview of the disease and its treatment strategies. *Semin Arthritis Rheum*, 35(1 Suppl 1):1-10.
- Schubert, M. and Hamerman, D. (1968): A primer on connective tissue biochemistry. Lea &Febiger, Philadelphia. pp. 166-168.
- Seeliger, P. (1926): Ein Beitrag zur pathologischen Physiologie der Gelenke im Hinblick auf die Arthritis deformans. *Dtsch. Z. Chir.* 198, 11.
- Suominen, M. M., Tulamo, R. M., Puupponen, L. M. and Sankari, S. M. (1999): Effects of intra-articular injections of bufexamac suspension on amphotericin B-induced aseptic arthritis in horses. *Am J Vet Res.* 60(12):1467-73.
- Trotter, G. W., Yovich, J. V., McIlwraith, C. W. and Norrdin, R. W. (1989): Effects of intramuscular polysulfated glycosaminoglycan on chemical and physical defects in equine articular cartilage. *Can J Vet Res.* 53: 224-230.
- Van den Berg, W. B. (2001): Lessons from animal models of osteoarthritis. *Curr Opin Rheumatol.* 13(5):452-456.

Van den Berg, W. B. (2009): Lessons from animal models of arthritis over the past decade. *Arthritis Res Ther.* 11(5):250.

Van Pelt, R. W. and Connor, G. H. (1963): Synovial fluid from the normal bovine tarsus. A cellular constituents, volume and gross appearance. *Am.J.Vet.Res.*, 24:112.

Van Pelt, R. W. (1971): Effect of intra-articular injection of flumithasone suspension in joint diseases in horses. *J.Am.Vet.Med.Ass.* 159:739.

Weissman, G., Becher, B. and Wiedermann, G. (1965): Studies on lysosomes. VII Acute and chronic arthritis produced by intra articular injections of Streptolysis S. *Am. J. Pathol.* 46: 129-140.