

**Original  
Article**

**COLOR DOPPLER ULTRASOUND AS AN OBJECTIVE ASSESSMENT TOOL FOR RESPONSE TO CHEMOTHERAPY IN LOCALLY ADVANCED BREAST CANCER**

**Ehab Hassan<sup>1</sup> and Ahmed Fathy<sup>2</sup>**

<sup>1</sup>Oncology Department, Faculty of Medicine, Cairo University, <sup>2</sup>Radiology Department, National Institute of Urology, Egypt

---

**ABSTRACT**

---

**Aim of the Study:** In our part of the world, the majority of the patients with breast cancer present with locally advanced disease and require neo-adjuvant chemotherapy as the primary treatment modality. It is essential to monitor the response to chemotherapy in these patients. Clinical examination as the sole criterion of response assessment is entirely subjective and fallacious. Magnetic Resonance Imaging (MRI) and Computed Tomography (CT) are expensive. The role of Doppler ultrasonography as an imaging modality for this purpose is therefore being evaluated.

**Patients and Methods:** A prospective study was undertaken of 25 cases of locally advanced breast carcinoma (LABC) and Color Doppler sonography was used for the sequential assessment of response to chemotherapy. The response assessed on the basis of clinical examination and Color Doppler was compared with the histological response. The parameters assessed on Color Doppler were a change in the number of flow signals, maximum flow velocity (Vmax), pulsatility index (PI) and resistivity index (RI). Responses were analysed statistically using the Pearson correlation coefficient (r) and Kappa statistics ( $\kappa$ ). The sensitivity, specificity, positive predictive & negative predictive values for predicting complete histological response were calculated. This work was done in Saudia Arabia

**Results:** Color Doppler showed a sensitivity of 88.88% for predicting complete histological response. The negative predictive value of color Doppler was 92.3%. A significant correlation was obtained between color Doppler and histopathological response.

**Conclusion:** Color Doppler was found to be an objective and effective tool or modality compared with clinical evaluation in sequential response assessment, especially for predicting complete histological response.

---

**Key Words:** Breast cancer, neo-adjuvant chemotherapy, tumor response and Color Doppler.

---

**Corresponding Author:** Ehab Ahmed Hassan, 123 Abd El-Aziz AlSaud Street , Manial, Cairo, Egypt, Tel.: 0123481619, E-mail : ehabhas@hotmail.com

---

**INTRODUCTION**

---

Many patients with breast cancer present with advanced disease at the time of presentation. Increased breast health awareness has led to earlier stage distribution among breast cancer patients; however locally advanced tumors remain a major source of morbidity and mortality specially in the developing and underdeveloped countries.<sup>1,2</sup>

Patients with locally advanced breast cancer have a poor prognosis due to difficulty in achieving local control and eventual development of distant metastases when treated by single modality. Multimodality strategies represent a major advance in management of these difficult cancers. The current standard of care is neo-adjuvant chemotherapy to improve operability, followed by surgery and radiation therapy. Primary response to induction therapy is an excellent surrogate marker of success in eradicating micrometastases, as patients experiencing a complete pathologic response have a statistically significant survival advantage<sup>2</sup>, hence an

accurate assessment of chemotherapeutic response is crucial. Clinical examination of the breast has to date been the most widely used approach for response assessment, having the advantages of being simple, quick, easy and non-invasive. However, this method varies among observers, is influenced by many factors such as skin thickness, edema and obesity<sup>3,4</sup> and could result in overestimation of tumour size<sup>5</sup>. In today's era of evidence-based medicine, the efficacy of clinical examination alone is increasingly being questioned. Clinical evaluation alone for assessing tumor response to neo adjuvant chemotherapy in breast carcinoma (WHO and UICC criteria)<sup>6</sup> shows limitations in practicality and reliability. Warr et al. estimated the error in categorization of response by comparing measurements of several physicians on real or simulated malignant lesions<sup>7</sup>. They found false categorization of partial response (based on a comparison of two measurements of the same lesion) to the tune of 1.3% and 12.6% for large and small simulated nodules, respectively.

In view of the importance of assessment of chemotherapeutic response in breast carcinoma, confident noninvasive assessment of response remains one of the “holy grails” of medicine today. The various non-invasive methods being advocated are mammography, B mode sonography, magnetic resonance imaging (MRI), computed tomography (CT), positron emission tomography (PET) and Color Doppler sonography. Fiorentino et al. in their study of 141 patients have questioned the utility of mammography for monitoring chemotherapy response<sup>8</sup>. They suggested that mammography does not provide additional useful information over clinical examination in the majority of cases. MRI, though a sensitive imaging modality, is not cost effective. Among the various available methods, a method related to angiogenic activity should provide more functional evidence of viable tumor cells and so overcome the limitations of conventional methods<sup>9</sup>. A significant number of studies have shown that [18F]fluoro-deoxyglucose positron emission tomography (FDG PET) is able to detect, stage and monitor breast cancer with high sensitivity and specificity<sup>10-13</sup>. Assessment of treatment response should be possible earlier as compared with conventional imaging modalities, because changes in tumor metabolism precede a reduction of tumor size. Color Doppler ultrasonography, which can demonstrate neovascular characteristics in breast tumors, can potentially serve as an independent functional method for objectively measuring tumor response to chemotherapy. The present study was conducted with the aim of establishing the potential role of Color Doppler ultrasonography as a response assessment tool for locally advanced breast carcinoma following neoadjuvant chemotherapy.

## **PATIENTS AND METHODS**

---

This prospective study was undertaken in 25 patients with locally advanced breast carcinoma, showing presence of hypervascular signals in breast masses on pre-chemotherapy Color Doppler ultrasonography, and who received neoadjuvant chemotherapy. The patients were in the age range of 30 to 65 years with a mean age of  $44.52 \pm 10.24$  years and all were histologically proven cases of invasive ductal carcinoma. Of the twenty-five patients included in the study, five patients had breast lump as the only presenting symptom, while 20 patients had other associated symptoms along with the breast lump including mass in the axilla, ulceration/fungation, pain and nipple discharge. Clinically, the tumor diameter ranged from 4.9-10.3cms with a mean of  $7.48 \pm 1.72$ cms. The duration of symptoms ranged from 2-24 months and the mean duration was 9.5 months. All patients received 3-4 cycles of neoadjuvant chemotherapy FAC (a combination 5-Fluorouracil, Doxorubicin and Cyclophosphamide) at three weekly intervals prior to mastectomy. Patients were clinically evaluated prior to chemotherapy and finally prior to surgery. The breast lump was measured

along two diameters perpendicular to each other using Vernier calipers<sup>10</sup> and the mean diameter was calculated. Clinical tumor volume ( $V_c$ ) was calculated using the formula for the volume of a sphere,  $V_c = \pi/6 \times d^3$  where  $d$  = mean diameter in centimeters. A single experienced radiologist performed Sonographic and Color Doppler examination. In order to avoid bias, the sonologist was blinded to the patient’s clinical profile, treatment history, response status and the pre-chemotherapy findings when assessing the pre-surgery findings. The mass was scanned by using a LA39, 11 MHz probe (LOGIQ 4000L, GE Medical Systems). The scan was done in multiple planes to include the whole breast and axilla. Normal and 13-mode images were taken to define the tumor margins. The probe was held orthogonal to the skin and moved over the tumor till maximum diameter was demonstrated. Two measurements were made perpendicular to each other and the thickness of the lesion was recorded using the equipment’s electronic calipers. Sonographic tumor volume ( $V_s$ ) was calculated using the formula for the volume of an ellipsoid,  $V_s = \pi/6 \times d_1 \times d_2 \times D$  where  $d_1$ ,  $d_2$  = diameter of tumor in centimeters  $D$  = depth of tumor in centimeters.

The breast lump seen on normal and B mode was then evaluated using Color Doppler sonography. Standardized machine settings were used to optimize sensitivity to low velocity and low volume blood flow (wall filter-low frequency; dynamic range-60 dB; persistence- short; colour threshold-50). Data acquisition was limited to a region of interest (“Color box”) containing the tumor. The number of flow signals, maximum flow velocity ( $V_{max}$ ), resistivity index (RI) and pulsatility index (PI) of intratumoral vessels were recorded. The number of flow signals was assessed by manual counting of pixels inside the tumor mass. Peritumoral flow was not taken into account for assessment.

Evaluation was done prior to chemotherapy and prior to surgery. Clinical response was calculated as a percentage of change in the tumor volume ( $V_c$ ). The percentage of change in sonographic tumor volume ( $V_s$ ),  $V_{max}$ , RI and PI was recorded. A change in the number of flow signals was also noted. An experienced pathologist who was blinded to the clinical response status of the patient evaluated the mastectomy specimen and the extent of post chemotherapy changes was assessed. Response assessed on the basis of various criteria was graded as shown in table 1.

## **Statistical Analysis**

The grades of response were compared and analyzed with the help of Pearson correlation coefficient and Kappa statistics. Sensitivity, specificity, positive predictive values (PPV) and negative predictive values (NPV) of various parameters for assessing complete pathological response were calculated.<sup>14</sup>

**Table 1:** Grades of response.

	Grades	Criteria
Tumor size, RI, PI, Vmax	1	Increase/No change/<25%
	2	25-50% decrease
	3	>50% decrease
	4	Complete disappearance of mass (tumor volume) / complete disappearance of the flow signals (RI, PI, Vmax)
Number of flow signals	1	No change/ Increase
	2	Decrease with >1 persistent flow signal
	3	Decrease with single persistent flow signal
	4	Complete disappearance of flow signals
Post mastectomy histology	1	No pathological changes
	2	Minimal pathological changes
	3	Moderate pathological changes
	4	Total annihilation of tumor tissue

Abbreviations: RI Resistivity Index, PI Pulsatility Index, V max Maximum Flow Velocity.

**RESULTS**

Twenty-four (96%) of 25 patients showed a clinical regression in tumor volume following chemotherapy. Five cases (20%) had complete disappearance of the lesion. Sonographically the tumor diameter ranged from 1.08-5.6 cms with a mean of  $3.62 \pm 1.33$  cms. Twenty-three (92%) of 25 patients showed a sonographic regression in tumor volume following chemotherapy. The mean RI of tumoral blood flow was  $0.789 \pm 0.259$  at the time of presentation. Eleven (44%) of 25 patients showed regression of RI following chemotherapy while two patients showed an increase in RI. The mean PI of tumoral blood vessels at the time of presentation was  $1.450 \pm 0.579$ . Nine (36%) of 25 patients showed regression in PI following chemotherapy while four (16%) patients showed an increase in PI. Mean Vmax for tumoral blood flow at the time of presentation was  $0.375 \pm 0.305$  m/sec. Thirteen (52%) of 25 patients showed regression in Vmax following chemotherapy. Twelve patients (48%) showed complete disappearance of flow signals following chemotherapy and hence RI, PI and Vmax could not be recorded post-chemotherapy. The response was assessed on the basis of Doppler parameters as shown in table 2. Figure 1 and 2 show the changes in intratumoral flow signals following chemotherapy.

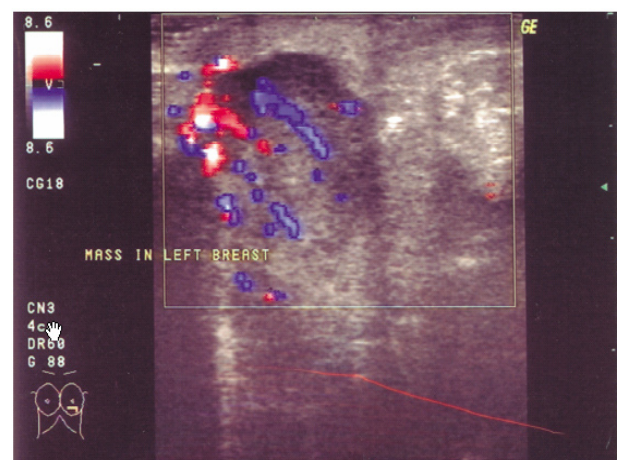
Nine patients (36%) showed histological complete response to chemotherapy referred to as total annihilation while 8 patients (32%) each showed minimal and moderate changes in the form of stromal fibrosis,

**Table 2:** Doppler response with reference to various evaluabl parameters.

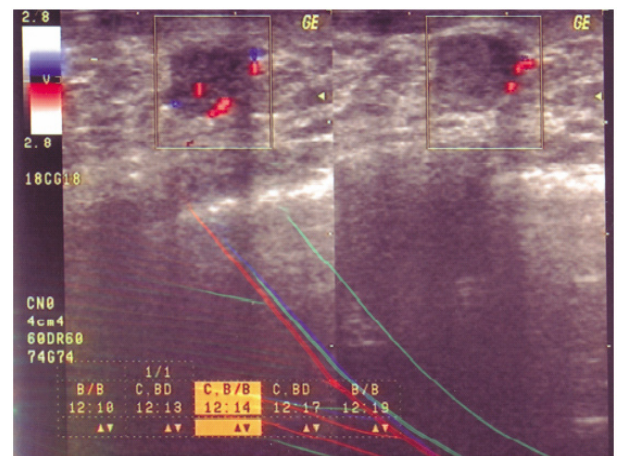
Grade of Response	No. of patients (n=25)			
	RI	PI	V max	No. of flow signals
1	9+2* (44%)	5+4** (36%)	1 (4%)	1 (4%)
2	2 (8%)	3 (12%)	6 (24%)	10 (40%)
3	0	1 (4%)	6 (24%)	2 (8%)
4	12 (48%)	12 (48%)	12 (48%)	12 (48%)

\*Two patients showed an increase in RI  
 \*\*Four patients showed an increase in RI

Abbreviations: RI: Resistivity Index, PI: Pulsatility Index, V max: Maximum Flow Velocity.



**Fig. 1:** Color Doppler showing flow signals before chemotherapy.



**Fig. 2:** Color Doppler showing disappearance of flow signals in the tumor following chemotherapy.

lymphocytic infiltrates and tumor necrosis. (Table 3). Correlation of various parameters assessed in the study with the histological response is summarized in Table 4. Color Doppler showed a sensitivity of 88.88% in predicting complete histological response. The negative predictive value of Color Doppler is 92.3% and is higher in comparison to that of clinical evaluation. (Table 5)



**Table 3:** Histological Response to Chemotherapy.

Grade of Response	No	%
1	0	0
2	8	32
3	8	32
4	9	36

**Table 4:** Correlation of Various Modalities with Histology.

Assessment parameter	Correlation coefficient		Kappa statistics		
	R	P value	K	P value	Agreement
Clinical	0.65	≤0.001	0.2545	0.0183	Fair
Doppler					
RI	0.688	≤0.001	0.251	≤0.0002	Fair
PI	0.751	≤0.001	0.123	≤0.716	Slight
V max	0.675	≤0.001	0.406	≤0.0012	Fair
Flow signals	0.810	≤0.001	0.465	≤0.001	Moderate

Abbreviations: r; Correlation coefficient, k; kappa, RI; Resistivity Index, PI; Pulsatility Index, V max; Maximum Flow Velocity.

**Table 5:** Prediction of complete histological response (Comparison of clinical and doppler response).

Modality	Sensitivity (%)	Specificity (%)	PPV (%)	NPV (%)
Clinical	44.44	93.75	80	75
Color Doppler	88.88	75	66.6	92.3

Abbreviations: PPV: Positive Predictive Value, NPV: Negative Predictive Value.

## DISCUSSION

The impact of breast cancer on women’s health continues to assume greater importance in developing countries. The often advanced stage of the disease at the time of presentation necessitates the use of neoadjuvant chemotherapy as the primary treatment modality. The role of neoadjuvant chemotherapy is important for downstaging the tumor and making definitive surgery feasible. This therapeutic approach however requires an accurate assessment of response to chemotherapy. The response assessment helps in distinguishing responders from non-responders, that reflects the survival rate. Response assessment may also help to identify a subgroup of women in whom intensification of treatment might be expected to treat micrometastases more effectively. The extent of downstaging of the tumor can be estimated on the basis of chemotherapeutic response. This in turn helps in identifying a subset of patients in whom conservative, less mutilating surgery can be performed without increasing the rate of local recurrence<sup>15</sup>. Finally, response assessment can be used as a surrogate parameter of treatment efficacy and may allow early termination of ineffective regimens.<sup>8</sup>

Feldman et al. made an observation that 45% of patients with clinically complete response after treatment had gross macroscopic tumor while 60% of patients with no gross macroscopic tumor were judged incorrectly at clinical examination to have residual tumor<sup>16</sup>. In the present study also, 40% of patients with complete clinical response had residual tumor on histology, while 55% of patients with complete pathological response had palpable tumor on clinical examination. Such observations are attributed to the presence of residual fibrosis and indistinct tumor margins that is sequelae of tumor response to chemotherapy. The present study thus emphasizes the inadequacy of clinical criteria alone for response assessment. Based on these observations the use of various imaging modalities for this purpose has been explored, the common ones being mammography and B-mode sonography. Cocconi et al. showed that clinical assessment of response should be supported by mammography<sup>17</sup>. However, these methods are purely anatomical and have limitations as they are unable to assess the extent of viable tumor cells. Keeping in mind this limitation and the strong relationship between the tumor growth and blood flow, a method capable of evaluating the angiogenic activity of the tumor should provide more functional evidence of viable tumor cells. Dynamic MR Mammography has been reported to be of value for the estimation of residual disease after induction chemotherapy<sup>18</sup>. However, this modality lacks applicability, particularly in the developing countries, due to limited availability and lesser cost effectiveness.

In the search for a cost effective, easily accessible functional method for response assessment, the role of Color Doppler sonography has been evaluated. Lagalla et al. evaluated the potential role of Color Doppler in various malignancies, including hepatocellular carcinoma and breast carcinoma, and found the results to conform with the histopathological observations<sup>19</sup>. Kedar et al. recorded a reduction in Doppler flow signals during neoadjuvant treatment in 77% of patients with partial or complete remission<sup>20</sup>. In this study, tumor vascularity was evaluated by the method of vessel counting. Huber et al. used a semi- quantitative computerized scoring system for analysis of changes in tumor vascularity during therapy. They classified the response as no response, partial response or complete response based on clinical examination and Color Doppler observations and compared the results with those from histological evaluation. Using this approach they were able to demonstrate a significantly higher concordance between Doppler and histology results compared to that of clinical evaluation.<sup>9</sup>

In the present study the evaluation of response was done on the basis of clinical size and Color Doppler indices (including RI, PI, Vmax and number of residual intratumoral flow signals). A uniform grading system was adopted for the comparison of clinical, Doppler

and histological response. The study confirmed a greater correlation between Doppler and histological response as compared to clinical response and histological response.

Among the various Doppler parameters the number of residual flow signals was found to be the only independent parameter. All the others were found to be dependent on the presence or absence of residual flow, as these could not be assessed in the cases in which there was complete disappearance of flow signals following chemotherapy. Doppler response was also found to have a higher sensitivity of 88.88% for predicting complete pathological response, compared to 44.44% for clinical response. We can conclude that Color Doppler thus seems to be an additional and independent functional method in the assessment of tumor response to neoadjuvant chemotherapy in locally advanced breast carcinoma.

## REFERENCES

1. Cancer incidence in five continents. Volume VII. IARC Sci Publ 1997(143):i,xxxiv, 1-1240.
2. Newman LA. Management of patients with locally advanced breast cancer. *Curr Oncol Rep* 2004 Jan;6(1):53-61.
3. Dixon JM, Senbanjo RO, Anderson TJ, Forrest AP, Elton RA. Clinical assessment of tumour size in primary breast carcinoma. *Clin Oncol* 1984 Jun;10(2):117-21.
4. Frouhi P, Walsh JS, Anderson TJ, Chetty U. Ultrasonography as a method of measuring breast tumour size and monitoring response to primary systemic treatment. *Br J Surg* 1994 Feb;81(2):223-5.
5. Fornage BD, Toubas O, Morel M. Clinical, mammographic, and sonographic determination of preoperative breast cancer size. *Cancer* 1987 Aug 15;60(4):765-71.
6. Hayward JL, Rubens RD, Carbone PP, Heuson JC, Kumaoka S, Segaloff A. Assessment of response to therapy in advanced breast cancer. A project of the programme on clinical oncology of the International Union against Cancer, Geneva, Switzerland. *Eur J Cancer* 1978 Nov;14(11):1291-2.
7. Warr D, McKinney S, Tannock I. Influence of measurement error on assessment of response to anticancer chemotherapy: proposal for new criteria of tumor response. *J Clin Oncol* 1984 Sep;2(9):1040-6.
8. Fiorentino C, Berruti A, Bottini A, Bodini M, Brizzi MP, Brunelli A, et al. Accuracy of mammography and echography versus clinical palpation in the assessment of response to primary chemotherapy in breast cancer patients with operable disease. *Breast Cancer Res Treat* 2001 Sep;69(2):143-51.
9. Huber S, Medl M, Helbich T, Taucher S, Wagner T, Rudas M, et al. Locally advanced breast carcinoma: Computer assisted semiquantitative analysis of color Doppler ultrasonography in the evaluation of tumor response to neoadjuvant chemotherapy (work in progress). *J Ultrasound Med* 2000 Sep;19(9):601-7.
10. Adler LP, Crowe JP, al Kaisi NK, Sunshine JL. Evaluation of breast masses and axillary lymph nodes with [F-18] 2-deoxy-2-fluoro-D-glucose PET. *Radiology* 1993 Jun;187(3):743-50.
11. Nieweg OE, Kim EE, Wong WH, Broussard WF, Singletary SE, Hortobagyi GN, et al. Positron emission tomography with fluorine-18-deoxyglucose in the detection and staging of breast cancer. *Cancer* 1993 Jun 15;71(12):3920-5.
12. Wahl RL, Zasadny K, Helvie M, Hutchins GD, Weber B, Cody R. Metabolic monitoring of breast cancer chemohormonotherapy using positron emission tomography: Initial evaluation. *J Clin Oncol* 1993 Nov;11(11):2101-11.
13. Jansson T, Westlin JE, Ahlstrom H, Lilja A, Langstrom B, Bergh J. Positron emission tomography studies in patients with locally advanced and/or metastatic breast cancer: A method for early therapy evaluation? *J Clin Oncol* 1995 Jun;13(6):1470-7.
14. Landis JR, Koch GG. The measurement of observer agreement for categorical data. *Biometrics* 1977 Mar;33(1):159-74.
15. Mansi JL, Smith IE, Walsh G, A'Hern RP, Harmer CL, Sinnott HD, et al. Primary medical therapy for operable breast cancer. *Eur J Cancer Clin Oncol* 1989 Nov;25(11):1623-7.
16. Feldman LD, Hortobagyi GN, Buzdar AU, Ames FC, Blumenschein GR. Pathological assessment of response to induction chemotherapy in breast cancer. *Cancer Res* 1986 May;46(5):2578-81.
17. Cocconi G, Di Blasio B, Alberti G, Bisagni G, Botti E, Peracchia G. Problems in evaluating response of primary breast cancer to systemic therapy. *Breast Cancer Res Treat* 1984;4(4):309-13.
18. Knopp MV, Brix G, Junkermann HJ, Sinn HP. MR mammography with pharmacokinetic mapping for monitoring of breast cancer treatment during neoadjuvant therapy. *Magn Reson Imaging Clin N Am* 1994 Nov;2(4):633-58.
19. Lagalla R, Caruso G, Finazzo M. Monitoring treatment response with color and power Doppler. *Eur J Radiol* 1998 May;27(Suppl 2):S149-56.
20. Kedar RP, Cosgrove DO, Bamber JC, Bell DS. Automated quantification of color Doppler signals: A preliminary study in breast tumors. *Radiology* 1995 Oct;197(1):39-43.