

## ORIGINAL ARTICLE

### LIMITED EXCISION AND PRIMARY CLOSURE FOR PILONIDAL SINUS

By

Wagih Ghnam, Hosam Ghazy, Basem Saed, Mohamed Farid

Department of General Surgery, Faculty of Medicine, Mansoura University, Egypt

Correspondence to: Hosam Ghazy, Email: hosamelbanna@hotmail.com

**Aim:** Pilonidal disease is a common disorder of the sacrococcygeal region. Various techniques have been used but no method provides the ideal treatment. This study was done to establish to what degree pilonidal sinus could be treated with limited excision and primary closure.

**Methods:** 39 patients with chronic pilonidal sinus were treated by limited excision and primary closure between July 2005 and January 2008 by the authors at general surgery department Mansoura University Hospital. They were followed up in the early postoperative period and thereafter for 12 to 30 months.

**Results:** One patient had mild seroma, another one developed irregular scar with accepted healing outcome. All patients were discharged from hospital in the 2nd postoperative day. Operative wounds healed in a period ranged from 12-22 days. The postoperative follow-up now ranges from 12 to 30months, and no recurrences have been recorded so far.

**Conclusion:** Limited excision of Pilonidal Sinus represents a good therapeutic option for treatment of pilonidal sinus This method has the advantages of having a low morbidity, short hospital stay, early return to work ,no recurrence and good long-term results.

**Keywords:** Natal cleft, simple excision, primary suture.

## INTRODUCTION

Pilonidal disease is a common disorder of the sacrococcygeal region. It comprises a variety of problems, including infection/abscess and the development of a chronic sinus cavity. Incidence varies across countries and races.<sup>(1)</sup> The cause remains controversial. Both congenital and acquired causes have been postulated. Hair insertion is the essential cause of the disease.<sup>(2)</sup> Although many surgical methods have been proposed, no clear consensus as to optimal treatment has been reported so far in the literature.<sup>(3)</sup> Despite controversy about the best surgical technique for the treatment of pilonidal sinus, an ideal operation should be simple, should not need a prolonged hospital stay, should have a low recurrence rate, and should be associated with minimal postoperative pain and wound care to decrease time off work.<sup>(4)</sup>

Surgical treatment of pilonidal disease is challenging due to the high rates of wound infection, impaired healing and recurrence.<sup>(5)</sup> Sometimes the operation is

worse than the disease itself due to postoperative complications as wound dehiscence.<sup>(6)</sup> Excision with a simple lay-open or performing marsupialization both result in a midline wound that takes several weeks to heal and there was a significant low recurrence rate because of the open portal for hair insertion.<sup>(7)</sup> Primary closure, although associated with a higher rate of recurrence, has been shown to be preferable because of lower dehiscence and infection rates, reduced pain,<sup>(8)</sup> fewer post-operative visits, shorter time off work<sup>(9)</sup> and faster healing time.<sup>(10)</sup> The aim of this prospective non randomized study were to establish, to what degree pilonidal sinus could be treated with limited excision and primary closure, to asses healing results after this procedure, to determine long-term recurrence rate, and, finally, to evaluate the existence of any persistent symptoms or problems related to the procedure in the long term prospective follow up.

## PATIENTS AND METHODS

Limited excision and primary closure was performed on

39 patients with chronic pilonidal sinus without florid infection between July 2005 and January 2008 by the authors at general surgery department mansoura university hospital Egypt. All patients were subjected to careful history taking, clinical and pre-operative routine laboratory investigations. Patients counseled and fully informed in the outpatient clinic and before the operation about the nature of the procedure and possible complications. The cases ranged from simple chronic midline sinuses to long branched and recurrent ones. Preoperative preparation was in the form of shaving the area of the sinus extended to the periphery of the thigh on both sides.

All patients were followed up in the outpatient clinic after the operation till complete wound healing, removal of stitches and suction drain then every three months for the first postoperative twelve months then yearly afterwards unless complaint issued. The follow-up period ranged from 12months to 30 months.

**Surgical procedure:** Shaving of the operative field was done on the morning of the operation in each patient. Prophylactic Antibiotic in the form of one gram third generation cephalosporin was administered sixty minutes preoperatively with induction of anesthesia through a peripheral venous line. All operations were performed under spinal anesthesia with the patient placed in prone position. Buttocks were retracted using adhesive tape in order to obtain a better visualization of the operative field (Fig. 1a). After skin preparation, an elliptical incision is made (Fig. 1b). The skin and subcutaneous layer is excised by using a scalpel, and then the sinus and surrounding tissue is freed down to the sacrococcygeal region using an electrocautery knife. All vessels were meticulously coagulated for adequate hemostasis. Limited mobilization of the skin and subcutaneous tissue was achieved to close the midline scar without tension by the diathermy knife. A 16F

suction drain is positioned along the length of the bottom of the operative cavity, and brought out 2 to 4 cm lateral to the upper end of the wound (Fig. 1c). The tension plasters are removed and, under normal traction, sutures are meticulously applied to close the subcutaneous space in one or more planes using 2/0 Polygalactin sutures after adequate excision of infected tissue then the skin is closed using separate nylon 2/0 vertical mattress sutures with meticulous skin edges apposition (Fig. 1d) and pressure dressing is applied postoperatively the patient is encouraged to lie on his back straightaway, which helps to obliterate any dead space underneath the approximated edges and also helps hemostasis. The patient can move cautiously as early as the evening of the day of surgery but, unless it is necessary, should avoid prolonged standing until day 5 or 6. A light diet should be followed for the first 2 or 3 days, after which no dietary restrictions are required. The dressing applied in the operating theatre is not removed till the 7th day in the first postoperative visit (for good compression of the wound to minimize the underlying dead space). However, before discharge the dressings were inspected for soiling in which case they are replaced under sterile conditions. Nearly all patients were discharged home the next postoperative day and the rest within 48 hours. Patients were asked to return to hospital on the 7th postoperative day for follow up to inspect the wound for healing, to remove the suction drain if 24 hours drainage became 20cc or less and to record complications. The skin stitches are removed on the 12th to 15th day. After removal of stitches regular shaving of hair and improvement of local hygiene was encouraged. The patients were followed up thereafter for about 12-30 months (mean 19.44 ±8.42months) for recurrence, infection and outcome.

**Statistical methods:** Using SPSS version10 and presented as numbers, percentage and mean ± standard deviation.

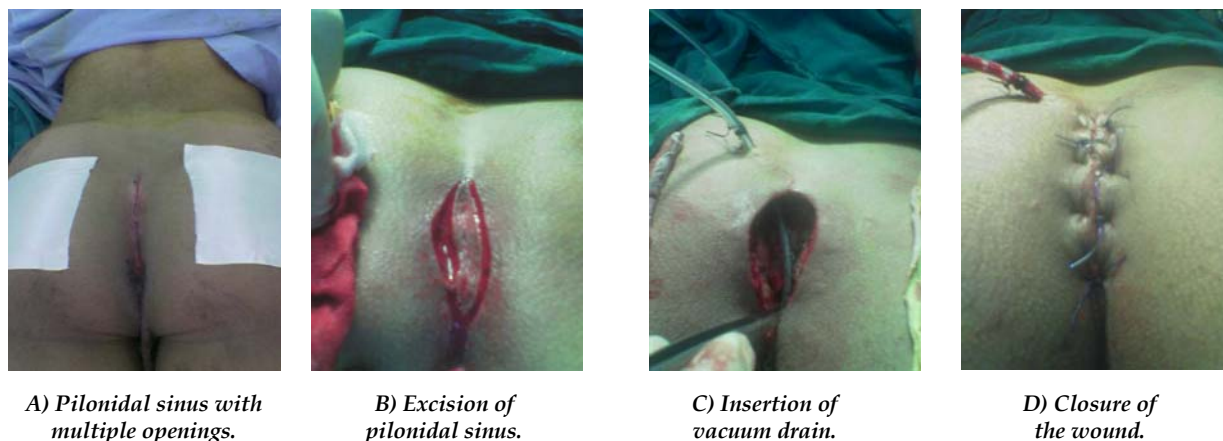


Fig 1. Steps of limited excision and primary closure with suction drain.

## RESULTS

The present study included thirty nine patients with chronic pilonidal sinus 30 males (76.92%) and 9 females (23.07%) their ages ranged from 16-38 years (mean  $24.86 \pm 6.4$  years) they all complaint of pilonidal sinus symptoms Table 1. Six patients (15.38%) had previous operations for pilonidal sinus (recurrent) and 33 patients (84.6%) had chronic non recurrent disease. The duration of symptoms until the day of admission ranged from 3 to 28 months with the mean duration of 9.7 months. Pain was the major complaint in 36 patients (92.3%) recurrent discharge in 31 patients (79.48%). Mean operative time was  $34.65 \pm 8.65$  minutes (ranged from 20-55 minutes). Table 1.

**Table 1. Patient characteristics.**

Patient characteristic	Result
Mean age	$24.86 \pm 6.4$ years
Male/female ratio	25/4 (6.25:1)
Mean duration of symptoms	$9.7 \pm 6.7$ months
Recurrent/non recurrent sinus	6/33 (1: 5.5)

All patients were discharged from hospital in the 2nd postoperative day and keep the compression dressing till the 1st postoperative outpatient clinic visit usually on the 7th day postoperatively. Healing was always by first intention, except two patients, one developed wound infection necessitating removal of one stitch for drainage and wound healed in 19 days by secondary intention and the other patient developed partial wound dehiscence that healed with daily dressing over 22 days. Operative wounds healed in a period ranged from 12-22 days with the mean healing time  $16.41 \pm 2.5$  days. Suction drainage period ranged from 5 to 13 days (mean  $8.5 \pm 2$  days) Table 2.

**Table 2. Postoperative results.**

Parameter	Mean time
Drainage time	$8.5 \pm 2$ days
Healing time	$16.41 \pm 2.5$ days
Return to work	$23.8 \pm 4.6$ days

One patient had mild seroma after drain removal that treated conservatively with antibiotic and resolved spontaneously, another one developed irregular scar with accepted healing outcome and none of the other patients experienced any operative or postoperative complications Table 3.

**Table 3. Postoperative complications.**

Parameter	Result
Seroma	1 (3.4%)
Wound infection	1 (3.4%)
Wound dehiscence	1 (3.4%)
Recurrence	0 (0.0%)
Irregular scar formation	1 (3.4%)

Patients returned to usual daily normal activities immediately after the removal of the cutaneous stitches on days 12 to 15 days, by which time the operative scar was consolidated, although they were advised to avoid excessive physical strain and strenuous sports for the following 3 to 4 weeks. The mean time for return to work was  $23.8 \pm 4.6$  days. The postoperative follow-up now ranges from 12 to 30 months, and no recurrences have been recorded so far.

## DISCUSSION

Pilonidal sinus disease is an acquired condition usually seen in young adults that carries high postoperative morbidity and patient discomfort.<sup>(11)</sup> The most predisposing factors for the development of pilonidal sinus are the existence of a deep natal cleft and the presence of hair within the cleft.<sup>(3)</sup> A deep natal cleft is a favorable environment for sweating, maceration, bacterial contamination, and penetration of hairs. Thus, for treatment and prevention, these causative factors must be eliminated<sup>(12)</sup> Although many surgical and nonsurgical treatment methods have been described, the ideal treatment method has not yet been established.<sup>(13,14)</sup> Complete excision of the sinus is widely practiced, but controversy remains about what to do with the wound after excision.<sup>(15)</sup> Excision and packing, excision and primary closure, marsupialization, and flap techniques such as Limberg flap are surgical procedures that have been developed for treatment of pilonidal sinus.<sup>(16-19)</sup> Despite the controversy about the best surgical technique for the treatment of pilonidal sinus, an ideal operation should minimize financial cost to the community (eg, treatment efficiency) as well as the patient (eg, earlier return to work), simple, should not require a prolonged hospital stay, with acceptable recurrence rate, and should be associated with low complication rate and minimal pain.<sup>(20)</sup>

Excision and primary closure is known to provide quicker healing and return to work compared with open packing and marsupialization. Most of our patients return to work in 3 to 4 weeks the same results as.<sup>(21)</sup> However, a high complication rate has been reported because of tissue tension (wound breakdown, pain), although some surgeons have reported good results after primary closure<sup>(22,23)</sup> that goes in hand with our results we have found hospital stay for 1 to 2 days 3.4%

complication rate (wound dehiscence, infection and seroma). others reported infection rates after local excision and primary closure in the midline of the natal cleft vary from zero to as high as 38% in published series.<sup>(7,22)</sup> The same discrepancies could also be seen regarding early failure and recurrences.<sup>(23)</sup> The results in the present study are considerably more favorable than other recent series of pilonidal sinus surgery with midline closure.<sup>(7)</sup> Our results were comparable to others with no recurrence, short operative time, hospital stay early return to work with minimal complication rate, we consider the reasons for our relatively encouraging outcome would be a good selection criteria ,meticulous standardized excision and closure technique applied and careful follow-up, which was, as we see it, mandatory in order to correctly assess the surgical technique and subsequent results. Recurrence is still the most important late postoperative complication. Evaluating previous studies, the incidence of recurrence varies between 0% and 17%.<sup>(24,25)</sup> In our experience the recurrence rate was zero comparatively very low .In the literature we can observe a progressive lowering of the recurrence rate; ranging from the disastrous results in patients treated by primary closure with wound dehiscence and recurrence rate of 50%, to good results comparable to those obtained with the open treatment.<sup>(26)</sup> Some studies have shown high recurrence rates with midline closure<sup>(27)</sup> but our study has shown that by following basic anatomical principles and good surgical technique, excision and primary midline closure can be adopted as a successful procedure for treating pilonidal sinus. We found in the present study that limited excision of pilonidal sinus represents one of best therapeutic options. The results of this method is comparable with the more aggressive frequently used excisional methods and it has the advantages of having a shorter hospital stay, convalescence ,early return to work ,few and negligible long-term complicating sequels.

## REFERENCES

1. Keighley R, Williams N. Surgery of the Anus, Rectum and Colon. WB Saunders Company Ltd. 2008;13:517-41.
2. Morden P, Drongowski RA, Geiger JD, Hirschl RB, Teitelbaum DH. Comparison of Karydak versus midline excision of pilonidal sinus disease. *Pediatr Surg Int.* 2005;21:793-6.
3. Ertan T, Koc M, Gocmen E, Aslar AK, Keskek M, Kilic M. Does technique alters quality of life after pilonidal sinus surgery? *Am J Surg.* 2005;190:388-92.
4. McGuinness JP, Winter DC, O'Connell PR. Vacuum-assisted closure of a complex pilonidal sinus. *Dis Colon Rectum.* 2003;46:274-6.
5. Topgül K, Özdemir E, Killie K. Long-term results of Limberg flap procedure for treatment of pilonidal sinus: a report of 200 cases.. *Dis Colon Rectum.* 2003;46:1545-8.
6. Akinci OF, Coskun A, Ozgonul A, Terzi A. Surgical treatment of complicated pilonidal disease: limited separate elliptical excision with primary closure. *Colorectal Dis.* 2006;8:704-9.
7. Sendena K, Diab R, Nesvik I. Influence of failure of primary wound healing on subsequent recurrence of pilonidal sinus. Combined prospective study and randomized controlled trial. *Eur J Surg.* 2002;168:614-8.
8. Dalenbäck J, Magnusson O, Wedel N, Rimbäck G. Prospective follow-up after ambulatory plain midline excision of pilonidal sinus and primary suture under local anaesthesia-efficient, sufficient, and persistent. *Colorectal Dis.* 2004;6:488-93.
9. Kareem TS. Surgical treatment of chronic sacrococcygeal pilonidal sinus. Open method versus primary closure. *Saudi Med J.* 2006;27:1534-7.
10. Aldean I, Shankar PJ, Mathew J, Safarani N, Haboubi N Y. Simple excision and primary closure of pilonidal sinus: a simple modification of conventional technique with excellent results *Colorectal Disease.* 2005;7:81-5.
11. Hull TL, Wu J. Pilonidal disease. *Surg Clin North Am.* 2002;82:1169-85.
12. Eryilmaz R, Sahin M, Alimoglu O, Dasiran F. Surgical treatment of sacrococcygeal pilonidal sinus with the Limberg transposition flap. *Surgery.* 2003;134:745-9.
13. Gencosmanoglu R, Inceoglu R. Modified lay-open (Incision,Curettage, Partial lateral wall excision and marsupialization) versus Total Excision with Primary Closure in the treatment of chronic sacro-coccygeal pilonidal sinus. *International Journal of Colorectal Disease.* 2005;20:415-22.
14. Holzer B, Grubner U, Brukner B, Houf M, Kiffner E, Schildberg FW, et al. The EMD study group. Efficacy and tolerance of a new Gentamicin Collagen Fleece (Septocoll) after surgical treatment of a pilonidal sinus. *Colorectal Dis.* 2003;5:222-7.
15. Nessar G, Kayaalp C, Seven, C Elliptical. Rotation flap for pilonidal sinus. *Am J Surg.* 2004;187:300-3.
16. Katsoulis IE, Hibberts F, Carapeti EA. Outcome of treatment of primary and recurrent pilonidal sinuses with the Limberg flap. *Surgeon.* 2006;4:7-10,62.
17. Abdul-Ghani AK, Abdul-Ghani AN, Ingham Clark CL. Day-care surgery for pilonidal sinus. *Ann R Coll Surg Engl.* 2006;88:656-8.
18. Kulacoglu H, Dener C, Tumer H, Aktimur R. Total subcutaneous fistulectomy combined with Karydak flap for sacrococcygeal pilonidal disease with secondary perianal opening. *Colorectal Dis.* 2006;8:120-3.
19. Petersen S, Koch R, Stelzner S, Wendlandt TP, Ludwig K. Primary closure techniques in chronic pilonidal sinus: a survey of the results of different surgical approaches. *Dis Colon Rectum.* 2002;45:1458-67.
20. Da Silva JH. Pilonidal cyst: cause and treatment. *Dis Colon Rectum.* 2000;43:1146-56.

21. Al-Jaberi TM. Excision and simple primary closure of chronic pilonidal sinus. *Eur J Surg.* 2001;167:133-5.
22. Abu Galala KH, Salam IM, Abu Samaan KR. Treatment of pilonidal sinus by primary closure with a transposed rhomboid flap compared with deep suturing: a prospective randomized clinical trial. *Eur J Surg.* 1999;165:468-72.
23. Waleed Omar. Asymmetric excision and primary closure with a lateralized wound for sacrococcygeal pilonidal disease is a simple and effective treatment. 2005;24,179-83.
24. Abu Galala KH, Salam IM, Abu Samaan KR. Treatment of pilonidal sinus by primary closure with a transposed rhomboid flap compared with deep suturing: a prospective randomized clinical trial. *Eur J Surg.* 1999;165:468-72.
25. Mohamed HA, Kadry I, Adly S. Comparison between three therapeutic modalities for non-complicated pilonidal sinus disease. *Surgeon.* 2005;3:73-7.
26. Raffaele Tritapepe Carlo Di Padova. Excision and primary closure of pilonidal sinus using a drain for antiseptic wound flushing. *Am J Surg.* 2002;183:209-11.
27. Kronborg O, Christensen K, Zimmermann-Nielsen C. Chronic pilonidal disease: a randomized trial with a complete 3-year follow-up. *Br J Surg.* 1985;72:303-4.