

Diagnosis of canine hepatic diseases with the aid of different diagnostic modalities

Shimaa, G. Yehia* and Noha, Y. Salem

Dept. of Internal Med. and Infect. dis., Facult. of Vet. Med., Cairo University,
Egypt, Giza, Giza Sq. PO 12211.

Abstract

Liver affections are one of the most challenging conditions in canine medicine practice; the diagnostic workup is exhausting and expensive. The current study designed to investigate selected cases of dog's hepatic affections on basis of clinical, clinic-pathologic, ultrasonographic and laparoscopic findings with special reference to image-guided biopsy. Thirty-nine diseased dogs of different ages, sexes, and breeds were involved in this study. The most consistent clinical signs were anorexia (29/39), emaciation (27/39), abdominal distention caused by hepatomegaly (5/39), ascites (19/39), vomiting (18/39), diarrhea (24/39), jaundice (5/39), and fever (2/39). Marked significant increase in liver enzymes activities (AST, ALT, ALP and GGT), along with marked elevation in Bilirubin values were the most significant clinicopathological alterations. Seven vaccinated apparently normal dogs from the same locality were used as control. Ultrasonographic assessment was performed on thirty-three patients, the ultrasonographic examination showed fatty changes in liver tissue (11/33), hepatic masses (7/33), cirrhosis (12/33) and biliary tract affections (3/33). Laparoscopy was performed in six patients only. Sub-hepatic abscess and enlarged yellowish liver were observed during laparoscopic procedures, in one case tiny abscess in ventral surface of liver along with enlarged slightly dark colored gallbladder wall, which was suspected as hepatic Lipidosis, and the diagnosis was confirmed histopathologically. The findings of this investigation assert the importance of ultrasonography and laparoscopy as investigative tools in diagnosis of canine hepatic affections.

Key words: dog, Liver, ultrasonography, laparoscopy.

Corresponding Author: Shimaa, G. Yehia, Shimaaghanem2013@gmail.com

Introduction

Hepatobiliary diseases are one of the most common affections in small animal practice, which considered a diagnostic challenge (Kumar et al., 2012).

Cardinal signs of liver affections in dogs usually are icterus, ascites, edema, emaciation and gastrointestinal disturbance; which are unclear and inconclusive (Leib and Monro, 1997).

Estimation of liver enzymes activities is well-established diagnostic tool for assessing hepatocellular injuries (Cooper and Webster 2006); systemic affections and numerous medications could lead to

deceptive elevation in serum enzymatic activities (Watson and Bunch 2009). Although, these constellation of clinical and laboratory findings is habitually comprises the justifiable basis of tentative diagnosis, nevertheless the ultimate diagnosis requires additional diagnostic tools (Hall and German, 2005).

In veterinary practice, several diagnostic aids are readily available, of which ultrasonography and laparoscopy are the most common used techniques in small animal clinics.

Ultrasound is an outstanding noninvasive technique to assess hepatic

parenchyma, it is usually indicated in cases of increased liver enzymes activities, presence of abdominal fluids and allow the determination of nature of hepatic affections (Konde and Pugh, 1996, Pastor and Bachs, 2010).

Laparoscopy offers enormous merits over ultrasonography as it permits the direct visualization in three diminish of liver and adjacent structures (Kolata and Freeman 1999). Laparoscopy is minimally invasive and less disturbing in dogs (Yanmaz et al. 2007), Laparoscopy was instigated to aid and provide alternative to or proceeding to laparotomy when the medical circumstances according such minor invasive process (Wildt 1980).

Liver biopsy either guided by ultrasonography or laparoscopy are considered a revolt for diagnosis of hepatobiliary disorders (Richter, 2006). Image-guided needle biopsy is widely accepted as precise and secure method for obtaining tissues for cytologic and histopathologic examination (Ho et al., 2003).

The combinations of information acquired by ultrasonography or laparoscopy with histopathology provide the definitive diagnosis in most patients (Jalan et al. 1995).

The current study designed to investigate selected cases of dogs' hepatic affections on basis of clinical, clinic-pathologic, ultrasonographic and laparoscopic findings with special reference to image-guided biopsy.

Material and Methods

Thirty-nine diseased dogs of different ages, sexes, and breeds were used in this study. The dogs were referred to Small Animal Medicine Teaching Hospital, Faculty

of Veterinary Medicine, Cairo University. At admission, thorough physical examination was performed and clinical signs were recorded, Serum samples were analyzed for liver enzymes activities and total bilirubin using respective test kits (Stanbio® Inc., USA). Seven vaccinated apparently normal dogs from the same locality were used as control.

Ultrasonographic examination of the liver and gallbladder was performed on un-sedated thirty-three dogs. Ultrasonographic images were achieved with the dog in dorsal recumbency using a ventral subcostal and right-sided intercostal approach according to Nyland and Hager (1985). The hepatic echogenicity was compared with splenic and renal cortex echogenicity according to Nyland and Matton (1995).

Liver laparoscopy was performed on six dogs, the inclusion criteria include ability of animal to sustain general anesthesia, coagulation profile test (BMBT, PT and PTT), cardiopulmonary status, and dog body weight (Kolata and Freeman 1999). The viewing telescope was used to direct tru-cut needle into liver, only biopsy tissue was attained when clear view of organ and site of biopsy were acquired, (Willard 2002).

Biopsy samples were instantly placed in 10% formalin solution and tagged. The specimens were then processed for histological examination, fixed in paraffin and sliced into 8 μ m thick sections. The slides then stained with Hematoxylin and Eosin by the standard histological techniques and inspected under the light microscopy (De Reycke *et al.*, 1999).

Student's t-test (STATISTICA for Windows, version 5.1, StatSoft, Inc.) was used.

Results

The most consistent clinical signs (Fig. 1) were anorexia (29/39), emaciation (27/39), abdominal distention caused by hepatic masses (5/39), ascites (19/39), vomiting (18/39), diarrhea (24/39) jaundice (5/39), and fever (2/39). Marked significant increase in liver enzymes activities (AST, ALT, ALP and GGT), along with marked elevation in bilirubin values compared to control group were observed, results are presented in table (1).

Liver and gall bladder were assessed by ultrasonography in all dogs involved in the study. Ultrasonographic findings were shown in figure 2. Ultrasonographic findings of hepatobiliary system included increase in hepatic size with diffuse increase in hepatic echogenicity suspecting fat accumulation in liver (11/33), focal or multifocal hypoechoic or hyperechoic hepatic lesions which diagnosed as unidentified hepatic masses (7/33) with accumulation of ascitic fluids in two cases of them, microheptia with diffuse increase in hepatic echogenicity and accumulation of ascitic fluids (12/33) which diagnosed as hepatic cirrhosis, accumulation of echogenic materials within gall bladder without acoustic shadowing and increased thickness of the wall (1/33), and common bile duct dilation and enlargement (2/33) which diagnosed as biliary obstruction.

Laparoscopy was performed in six patients only (Figure3). The laparoscopic examination revealed sub-hepatic abscess and enlarged yellowish liver, in one case tiny abscess in ventral surface of liver along with enlarged slightly dark colored gallbladder wall, which was suspected as hepatic Lipidosis (Steatosis, Fatty Change), but the confirmation of the diagnosis was only possible via biopsy sample analysis.

Biopsy samples were taken and referred to histopathology (Fi. 4). Histopathology was able to confirm the diagnosis of fatty changes in liver "Hepatic Lipidosis" (Steatosis), as vacuolation of hepatocytes with kupffer cell activation and pyknosis of hepatocyte nuclei, focal hepatic necrosis associated with leucocytic cells infiltration as well as sinusoidal leucocytosis.

Table (1): Selected serum biochemistry findings in thirty- nine dogs with hepatic ailments.

Parameter	Patient data	Control data
ALT u/l	124.8±18.7*	28.9±7.59
AST u/l	149±23.5*	42.8± 10
ALP u/l	217±24.4*	73.8±12.7
GGT u/l	46±4.15*	10.8±3.94
Total bilirubin mg/dl	1.347±0.357*	0.401±0.069

* statistically significant difference at P<0.05.

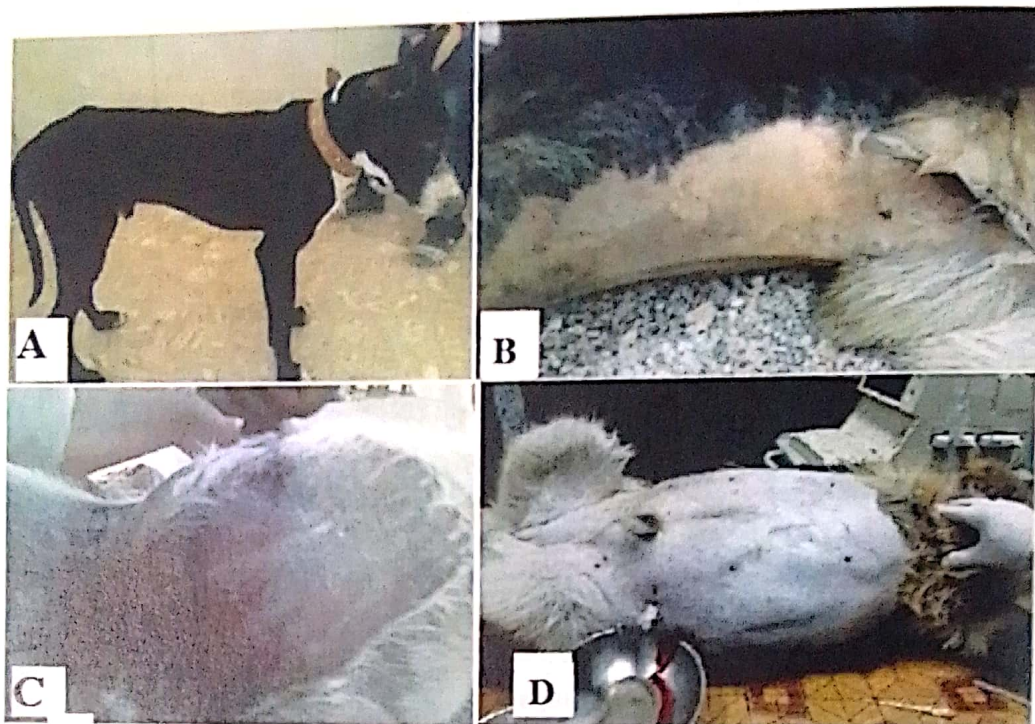

Figure (1): Clinical signs associated with hepatobiliary affections in dogs showing:

- A. One and half -year-Great Dane dog showing marked depression and cachexia.
- B. Three -years- German shepherd dog showing yellowish discoloration of skin of ventral abdomen
- C. Seven-years- White German Shepherd dog showing marked abdominal distention due to accumulation of ascitic fluid.
- D. Four -years- German shepherd dog showing marked abdominal distention and abdominocentesis revealed accumulation of ascitic fluid.

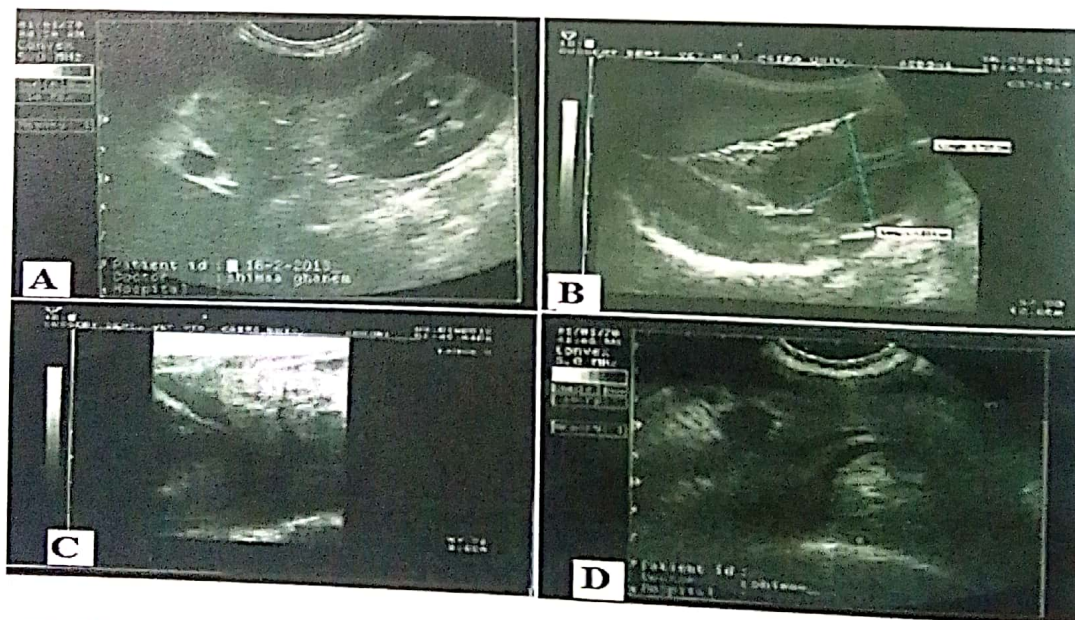


Figure (2): Ultrasonographic findings in case of affected dogs showing:

- A. Sagittal scan of the liver of 3 -years- old Yorkshire bitch with history of inappetence, vomiting showing obvious increasing in hepatic echogenicity as compared with renal cortex of right kidney and right lateral liver lobe overlapping over right kidney. Diagnosis: Fatty liver
- B. Sagittal scan of 12 -years- old mastiff dog with history of anorexia , progressive abdominal distention and lethargy showing grape like hepatic masses measuring (5.727cm) width and (4.884 cm) length with thin hyperechoic margins surrounding multiple hypoechoic lesions. Diagnosis: Hepatic mass.
- C. Sagittal scan of the liver of 11 -years- old Griffon dog with history of lethargy, progressive abdominal enlargement and diarrhea showing small echogenic liver surrounded by anechoic ascitic fluid. Diagnosis: Liver cirrhosis.
- D. Sagittal scan of 8 -years- old Boxer dog with history anorexia, vomiting and jaundice showing marked dilation of bile ducts. Diagnosis: Biliary obstruction.

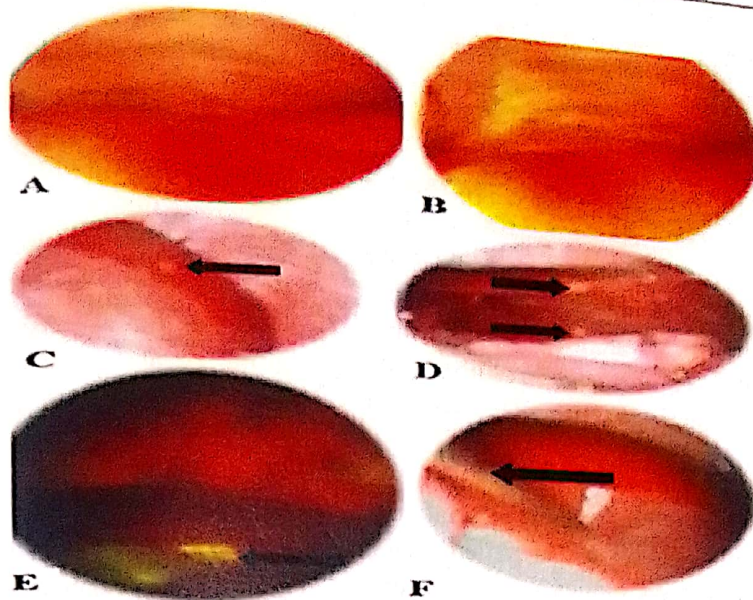


Figure (3): Laparoscopic findings in affected dogs showing:

- A and B) Enlarged yellowish liver surface.
- C) Small liver abscess was found on dorsal surface of liver during exploratory laparoscopy.
- D) Abscesses discovered in ventral surface of the liver during exploratory laparoscopy.
- E) Enlarged slightly dark colored gallbladder wall
- F) Biopsy needle was clearly visible during laparoscopic procedure.

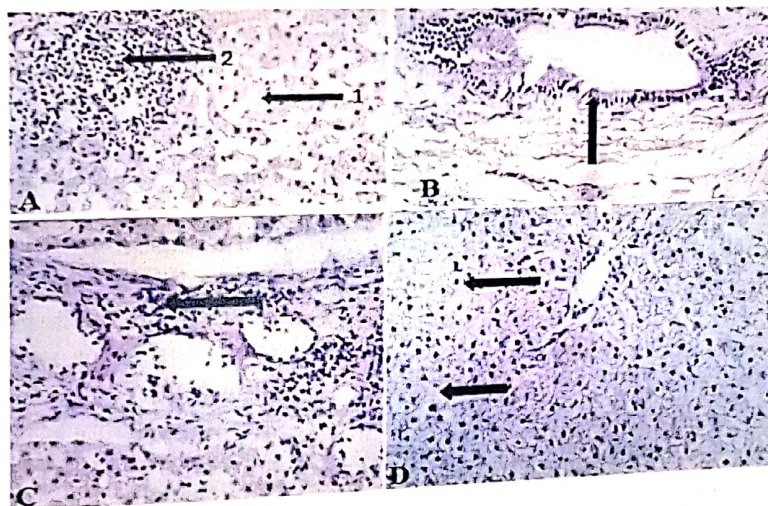


Figure (4) Histopathologic findings obtaining via laparoscopic guidance showing:

- A. Photomicrograph photo showing marked dilatation of hepatic sinusoids ⁽¹⁾ and focal area of hepatic necrosis replaced by leucocytic cells infiltration ⁽²⁾.
- B. Photomicrograph photo showing hyperplasia of epithelial lining bile duct associated with focal necrosis of epithelial and connective tissue proliferation.
- C. Photomicrograph photo showing marked portal infiltration with leucocytes as well as fibrous connective tissue proliferation.
- D. Photomicrograph of liver of dog showing vacuolation of hepatocytes and pyknotic of their nuclei.

Discussion

Canine hepatic affections constitute a challenge for many practitioners to decide the most appropriate diagnostic test to attain the most precise diagnosis (Steiner, 2008).

Variety of clinical signs was observed in the affected dogs; cardinal signs were: different grades of icterus, ascites, emaciation, vomiting and diarrhea (Leib and Monroe, 1997; and Center, 2005).

In this study, the liver functions of dogs showed abnormal elevation, increase in enzymes and bilirubin activities may be suggestive to hepatocellular injury and impaired hepatic function; these elevations should raise the concern for further investigation to detect the underline hepatobiliary disorder (Steiner 2008, Rebar 2008). However, systemic illness and plentiful drugs could lead to unreliable increase in enzymatic activities (Watson and Bunch, 2009).

Diagnostic imaging is an important tool of many diagnostic workups in patient dogs; nevertheless, it always requests practiced eye for interpretation of such images (Vignoli et al., 2007). Ultrasonography was mandatory for this required specification. In case of fatty liver, the ultrasonographic scan revealed a generalized increase in hepatic echogenicity, which attributed to intra-hepatic deposition of fat and liver lateral lobe overlapped the right kidney (Yeager and Mohammed, 1982; Scatarige et al., 1984).

Cirrhosis was very difficult to diagnose clinically. Ultrasonography thoroughly revealed that liver was smaller than normal, hyperechoic with irregular contour and accumulation of ascitic fluid in the abdomen separating the liver lobes. These findings were generally come in accordance with Farrow (2003); contrariwise, Morita et al., (1998) stated that the alteration in echogenicity of the liver may be diffuse or focal with focal changes are being easier to detect because the surrounding hepatic parenchyma will be normal; the diffuse changes are not easily detected and may be artifactual. In hepatic masses, clinical signs were indistinguishable, clinical examination and abdominal palpation showed the presence of palpable hepatic mass, Ultrasonography permitted the determination of extent and size of such masses (Torad, 2005; Kelany, 2006) Though, ultrasonography equipped to determine the presence of hepatic masses; it failed to characterize the type (nature) of masses.

In biliary obstruction, ultrasonographic examination showed visibly dilated bile duct along with thick echogenic wall and anechoic bile. Obstruction of the biliary tract may occur due to obstruction of the major hepatic ducts, the cystic duct or the common bile duct and it may be due to a mural, intraluminal or extramural causes (Paddy, 2006). Ultrasonography can differentiate between intrahepatic and extrahepatic biliary obstruction, where dilated anechoic tubular structure with small gall bladder is indicative for intrahepatic biliary obstruction; whereas enlarged gall bladder with dilation of both intrahepatic and extrahepatic ducts identify extrahepatic obstruction (Nyland and Matton 1995). Laparoscopy is minimally invasive and less traumatic in animals. For laparoscopy, the animal rapidly turns its normal physical condition. Laparoscopy allows safe biopsy in several organs such as kidney, liver, pancreas and intestine (Yanmaz et al. 2007). In this study, laparoscopic findings constitute the legitimate basis for hepatic Lipidosis (Steatosis); the liver was ascribed to be moderately enlarged and pale yellow (van der Linde-Sipman et al., 1990), Hepatic steatosis (lipidosis) may take a diversity of forms, namely, microsteatosis which refers to alteration in which lipid buildup is in the form of small vacuoles, whereas, macrosteatosis, the lipid vacuoles are as big as or larger than the cell nucleus and commence to disfigure other intracellular structures (Burt et al., 2008; Turlin et al., 2009), these findings have been described previously in post mortem studies, however, the notion of actual looking inside the body cavities, which can provide plentiful information to the pathologist can help in making definite diagnosis (Chiu et al., 2008), this merit increase the accuracy of laparoscopy over the diagnostic modalities. The definitive diagnosis was made upon histopathologic results obtained via laparoscopic-guided biopsy, the histopathologic findings agreed with those described in other studies (El-badry et al., 2009; Turlin et al., 2009; Brunt and Tiniakos 2010; Hunt et al., 2013). The direct visual control of the needle and capability of visual

choice of biopsy site (Hernandez-divers et al., 2007; Shettko and Hendrickson, 2008) along with the ability to detect small hepatic lesions, which often missed during regular sonar scan (Weickert et al., 2005).

Conclusion

Thorough and careful clinical examination of dogs suffering from hepatic diseases and further augmentation with laboratory findings cannot replace or skip ultrasonography and all in all must go together in harmony and synchronization to accomplish a definite diagnosis.

Laparoscopy can be used safely and more regularly in diagnosis and biopsy of the liver, Laparoscopy offers few advantages over other diagnostic modalities for biopsies as it allows gross description of liver pathology and referring it to the pathologist, and direct visual observation of organ to be biopsied, but it does not allow evaluation of the anterior of these parenchymatous organs as ultrasonography.

References

- Brunt, E. M. and Tiniakos, D. G. (2010): Histopathology of nonalcoholic fatty liver disease. *World J Gastroenterol*, 16 (42): 5286-5296.
- Burt, A.D., Mutton, A., Day, C.P. (1998): Diagnosis and interpretation of steatosis and steatohepatitis. *Seminars in Diagnostic Pathol.*, 15:246-258.
- Center, S.A. (2005): Hepatopathies and antioxidants: practical application. *Small animal and exotics Proc. of North Amer. Vet. Conf.*, 19: 1468- 1470.
- Chiu, C.C., Lee, W.J., Wang, W., Lee, Y.C., Haung, M.T. (2008): Correlations of laparoscopy with histology and laboratory studies on liver diseases in bariatric patients. *Obes. Surg* 18 (2): 204 - 211.
- Cooper, J. and Webster, C.R.L.(2006): The diagnostic approach to asymptomatic dogs with elevated liver enzyme activities. downloaded at [http:// veterinarymedicine.dvm360.com/vetmed/Medicine/ArticleStandard/Article/detail/325515](http://veterinarymedicine.dvm360.com/vetmed/Medicine/ArticleStandard/Article/detail/325515)
- De Reycke, L.M., Van Bree, H.J., Simoens, P.J. (1999): Ultrasound-guided tissue corebiopsy of liver, spleen and kidney in normal dogs. *Vet. Radiol. and Ultrasound*, 40 (3): 294-299.
- El-Badry, A.M., Breitenstein, S., Jochum, W., Washington, K., Paradis, V., Rubbia-Brandt, L., Puhan, M.A., Slankamenac, K., Graf, R., Clavien, P.A. (2009): Assessment of hepatic steatosis by expert pathologists: the end of a gold standard. *Ann. Surg.*, 250 (5):691-697.
- Farrow, B.R (2003): On the subject of veterinary medicine. *Aust Vet J.* 2003 Jul, 81(7): 396-397.
- Hall, E. J., German, A. J. 2005. Laboratory evaluation of hepatic disease. In *BSAVA Manual of Canine and Feline Clinical Pathology*, E. Villiers and L. Blackwood, Eds., BSAVA, Gloucester, UK, 2nd Ed, p. 184-206.
- Hernandez-divers, S.J., Stahl, S.J., McBride, M., Stedman, N.L.(2007): Evaluation of endoscopic liver biopsy technique in green iguanas. *JAVMA*, 230(12): 1849-1853.
- Ho, L.M., Thomas, J., and Fine, S.T. (2003): Usefulness of sonographic guidance during percutaneous biopsy of mesenteric masses. *Amer. J. of Roentgenol.*, 180: 1563-1566.
- Hunt, G.B., Luff, J.A., Daniel, L., Van den Bergh, R. 2013. Evaluation of hepatic steatosis in dogs with congenital portosystemic shunts using Oil Red O staining. *Vet Pathol*, 50(6):1109-1115.
- Jalan, R., Harrison, D. J., Dillon, J.F., Elton, R.A. Finlayson, N.D., Hayes, P.C. (1995): Laparoscopy and histology in the diagnosis of chronic liver disease. *Q. J. Med.*, 88:559-564.
- Kelany, W.M. (2006): Diagnostic and therapeutic studies on hepatobiliary diseases of dogs. Ph.D., Cairo University, Egypt. pp: 112-165
- Kolata, R.J., Freeman, L.J.(1999): Minimally Invasive Surgery of the Liver and Biliary System. In: Freeman LJ. *Veterinary Endosurgery*, Mosby, ST. Louis, Missouri, pp:151-159.
- Konde, L.J. and Pugh, C.R., 1996. Radiology and sonography of the digestive system. In: *Handbook of Small Animal Gastroenterology*, T. R. Tams, Ed., W. B. Saunders, Philadelphia, pp. 75-135.
- Kumar, V., Kumar, A., Varshney, A. C., Tyagi, S.P., Kanwar, M. S., Sharma, S. K.(2012): Diagnostic Imaging of Canine Hepatobiliary Affections: A Review. *Vet. Med. Internat.*, 2012; 2012: 672107. doi: 10.1155/2012/672107. Epub 2012 Mar 18.

- Leib, M.S., and Monroe, W.E. (1997): Hepatobiliary diseases. Practical small animal internal medicine, 2nd ed. W. B. Saunders, pp. 775-821.
- Morita Y., Yakiguchi, M., Yasuda, J., Kitamura, T., Syakalima, M., Eom, K., Hashimoto, A. (1998): Endoscopic ultrasonography of the pancreas in the dog. Vet. Radiol. Ultrasound, 39: 552.
- Nyland, T.G., and Hager, D.A. (1985): Sonography of the liver, gallbladder and spleen. Vet. Clin. North Amer. Small Anim. Pract. , 15:1123.
- Nyland, T.G., Matton, J.S., and Wisner, E.R.(1995):. Veterinary diagnostic ultrasound, Saunders Co., Philadelphia.pp:300-374
- Paddy, N. (2006): Diagnostic ultrasound in small animal practice. Blackwell Sci., Ltd.pp:60-75.
- Pastor, J. and Bach, M. P. (2010): Liver tumors: diagnosis and treatment. Vet. Focus, 20 (3): 41- 47.
- Richter, K.P. (2006): Liver biopsy/ aspiration methods, Pros. and Cons. NAVC Proceeding, January 2006.
- Rebar, A.H. (2008): A case oriented approach to liver laboratory profiling in dogs and cats. Proc. of 33rd world small animal vet. congress, Dublin, Ireland-2008:551-553.
- Scatarige, J.C., Scott, W.W., and Donovan, P.H. (1984): Fatty infiltration of the liver: ultrasonographic and computed tomographic correlation. J. ultrasound Med, 3:9-14.
- Shettko, D. L., and Hendrickson, D.A.(2008): Education and laparoscope: uses of laparoscopy in teaching. J. of equine vet. sci., 28(1):51-53.
- Steiner, J.M.(2008): Diagnostics for the evaluation of the liver. Proc. of 33rd world small animal vet. congress 2008-Dublin, Ireland: 375-376.
- Torad, F.A.(2005): Comparative studies on abdominal radiology and ultrasonography in pet animals. PhD., Cairo University, Egypt, 268-281.
- Turlin, B., Ramm, G.A., Purdie, D.M., Lainé, F., Perrin, M., Deugnier, Y., and Macdonald, G.A. (2009): Assessment of hepatic steatosis: comparison of quantitative and semiquantitative methods in 108 liver biopsies. Liver international, 29(4): 530-535.
- Van der Linde-Sipman, J.S., van den Ingh, I.S.G.A.M., and van Toor, A.J.(1990): Fatty liver syndrome in puppies. J. of the Amer. Animal Hospital ass., 26:6-12
- Vignoli, M., Gnudi, G., La Ganga, P., Gazzola, M., Rossi, F., Terragni, R., Di Giancamillo, M., Secchiero, B.D., Citi, S., Cantoni, A.M., Corradi, A. (2007): CT-guided fine needle aspiration and tissue-core biopsy of lung lesions in the dog and cat. Eur. J. of Companion Animal Practice 17, 23–28.
- Watson, P.J., Bunch, S.E.(2009): Diagnostic test for the hepatobiliary system. In: Nelson, RW, Couto CG. Small Animal Internal Medicine, ed.4, Mosby, St. Louis, p.496-519.
- Weickert, U., Jakobs, R., Riemann, J.F.(2005): Diagnostic laparoscopy. Endoscopy, 37: 33-37.
- Willard, M.D. (2002): Endoscopy of Body Cavity. In: Fossum, T.W.: Small Animal Surgery. , 2nd Ed., Mosby, Inc., St. louis, Missouri, p. 127-130.
- Wildt, D.E., (1980): Laparoscopy in Dogs and Cats. In: Harrison, R.M and Wildt, D.E.: Animal Laparoscopy. Williams and Wilkins, Baltimore, pp.31-59.
- Yanmaz, L.E.; Okumus, Z.; and Dogan, E., (2007): Laparoscopic surgery in veterinary medicine. Vet. Res., 1(1): 23-39.
- Yeager, A.E, and Mohammed, H. (1992): Accuracy of ultrasonography in the detection of severe hepatic lipidosis in cats. Am. J. Vet. Res.53:342-351

تشخيص امراض الكبد في الكلاب باستخدام طرق التشخيص المختلفة نهى يوسف سالم , شيماء غانم يحيى

اصابات الكبد في الكلاب هي واحده من اكثر الحالات الشائعة التي تواجهها الطبيب البيطري يوميا، التشخيص قد يكون مرهق ومكلف، تم فحص 39 حالة في هذه الدراسة. اوضحت الصورة الاكلينيكية فقدان الشهيه و الاسهال و القيئ والاستسقاء بينما اظهر فحص السيرم ارتفاع في مستوى الانزيمات الكبدية والبيلبيروبين، تم اجراء تقييم باستخدام الموجات فوق الصوتيه في 33 حالة و اظهرت النتائج تشحم الكبد في 11 حالة و تليف كبدى في 12 حالة و وجود اورام في الكبد في 7 حالات. تم عمل منظار البطن في عدد 6 حالات و اظهرت وجود تنكس دهنى وتم تأكيد التشخيص عن طريق اخذ خزعه كبدية وتحليلها باثولوجيا.