

Preliminary results of internal fixation of symphyseal disruption using Assiut Symphyseal Plate: a novel biplanar plate design

Osama Farouk, Mohamed Y. Hassanein, Aly M. Mohamed, Faisal F. Adam

Department of Orthopedics and Traumatology, Faculty of Medicine, Assiut University, Assiut, Egypt

Correspondence to Mohamed Yahya Abdel Azeem, MBCh, Department of Orthopedics and Traumatology, Faculty of Medicine, Assiut University, Assiut, 71526, Egypt
Tel: +20 100 808 4749; Fax: +20 882 333 327; e-mail: myz4ever@yahoo.com

Received 05 July 2017

Accepted 27 September 2017

Journal of Current Medical Research and Practice

September-December 2017, 2:177–182

Introduction

Plate fixation remains the primary method of internal fixation of symphyseal fractures. Literature shows great controversy on ideal plate design for symphyseal fixation. The aim of this study is to evaluate reduction and fixation capabilities of Assiut Symphyseal Plate (ASP).

Patients and methods

Traumatic symphyseal injuries in 14 patients were fixed with ASP between November 2013 and June 2016. The plate is a biplanar titanium locked plate designed in Assiut University Hospital. Radiological and functional outcomes were assessed at 2, 6, and 12 months postoperatively.

Results

Seven patients had fracture pelvis tile type B and seven had fracture pelvis tile type C. Satisfactory reduction was achieved (Dujardin criteria; symphyseal distance <5 mm) in 12 patients. No significant loss of reduction occurred over 1 year postoperatively. Functional outcome (Majeed functional score) was excellent in 11 cases, good in two cases, and fair in one case.

Conclusion

ASP can be used in the fixation of symphyseal injuries safely with good radiological and functional outcome. Further studies are needed to compare results with conventional plates.

Keywords:

Assiut Symphyseal Plate, symphyseal disruptions, symphyseal locked plate

J Curr Med Res Pract 2:177–182

© 2018 Faculty of Medicine, Assiut University
2357-0121

Introduction

The symphysis pubis acts as a strut to prevent collapse of the pelvis. Symphyseal disruption may occur as a part of either tile type B or tile type C pelvic fracture. Adequate reduction and fixation of the symphysis pubis are crucial for restoring stability and alignment of the pelvic ring [1].

There is much controversy regarding the ideal treatment of symphysis diastasis. Most pelvic fracture surgeons employ open reduction and internal fixation with plates; the controversy lies in the type and number of plates. Some authors recommend one plate superiorly for APC type II injuries, with two plates for more unstable APC III type injuries [2–5]. Studies show that the strongest construct is biplanar type fixation with one plate superiorly and one anteriorly [6].

A major drawback of internal fixation of symphyseal injuries is implant failure. Implant failure after symphyseal plating reportedly occurs in 0–21% of patients and is typically associated with recurrent widening of the symphyseal distance [7,8].

This study evaluates the use of a novel locked plate, Assiut Symphyseal Plate (ASP), for fixation of

symphyseal diastasis in type B and type C pelvic fractures. ASP is a biplanar titanium-based plate designed in Assiut University Hospital with options for superior and anterior screw insertion. The plate is designed to allow maximal compression with dynamic compression (DC) screws together with stable fixation with locking screws.

The aim of this study was to analyze the radiological and functional outcome of fixation of symphyseal disruptions using the newly designed ASP.

Patients and methods

From November 2013 to June 2016, 14 patients with symphyseal disruptions were treated by a locked symphyseal plate, 'Assiut Symphyseal Plate (ASP)', in a prospective consecutive series. They were operated upon

This is an open access journal, and articles are distributed under the terms of the Creative Commons Attribution-NonCommercial-ShareAlike 4.0 License, which allows others to remix, tweak, and build upon the work non-commercially, as long as appropriate credit is given and the new creations are licensed under the identical terms.

in the trauma unit in Assiut University Hospital. The study was approved by the medical ethics committee of Assiut University (IRB00008682). The study included cases with rotationally unstable pelvis fractures in the form of symphyseal disruption \pm vertical instability. The study was performed on skeletally mature patients, physiologically stable at the time of surgery with no evidence of severe anterior soft tissue injuries. Patients with obstetric symphyseal disruption, unfit patients, severe soft tissue injury including Morel-Lavallee lesion and those with immature skeleton were excluded.

ASP (ORTHOMED®, Giza, Egypt) is a large set, biplanar, titanium plate which consists of two parts: precontoured horizontal part, which has six holes (two central combi-holes and four lateral locked holes), and a vertical buttress part, which has two nonlocked holes (Fig. 1).

Initial resuscitation was performed according to ATLS protocols. Each patient had initial injury radiographs [standard three views of the pelvis: anteroposterior (AP), inlet, and outlet] as well as computed tomographic scanning. The decision to operate was based on radiographic and clinical evidence according to standard protocols. Surgery consisted of either anterior symphyseal plating alone or in combination with posterior fixation when required. Posterior fixation in the form of 7.3 mm cannulated sacroiliac screws was used in five cases with sacral fractures and/or sacroiliac joint dislocations whereas open reduction and internal fixation of iliac wing fracture was needed in one case.

Classic Pfannenstiel approach was used for all cases. The diastasis is reduced using a large reduction clamp. The clamp tines can be seated on the pubic tubercles, or in the obturator foramina. Once reduced, alignment is verified on both inlet and outlet radiographs, and then screws are inserted in the median combi-holes in the compression mode. At this moment, maximum compression is probably achieved. Compression is then maintained by insertion of lateral locked screws. In the presence of AP displacement, anterior screws are inserted to help in reduction of sagittal displacement (Fig. 2a–f). Patients were instructed to

start weight bearing 2 months after surgery. Patient's age, sex, mode of trauma, and associated injuries were recorded. Symphyseal distance was measured preoperatively, immediately after surgery, and 6 months later. Dujardin's criteria for evaluation of symphyseal reduction were used, where up to 5 mm is considered a satisfactory reduction [9]. At 6 months of follow-up, functional outcome was evaluated using the Majeed functional outcome which is a pelvic injury-specific assessment divided into seven items such as pain, work, sitting, sexual intercourse, standing, gait unaided, and walking distance, with a total score range of 0–100 in the order of decreasing disability [10].

Data entry was done using the MS Excel 2007 (Microsoft Redmond, Washington, United States). Statistical analysis was done using the IBM SPSS program, version 27. Numerical data were presented as median and mean \pm SD, whereas qualitative ones represented as numbers and percentages. χ^2 -test was used to compare between categorical variables, whereas *t*-test was used to compare between continuous variables. A two-tailed *P* value less than 0.05 was considered statistically significant.


Results

Of the 14 cases included in the study, 11 (78.5%) cases were males, whereas three (21.4%) cases were females. Age ranged between 21 and 62 years, with a mean age of 32.9 ± 11.8 years. High-energy trauma was the cause in all cases as expected from the violent nature of pelvic fractures (Table 1).

The time between date of trauma and time of surgery ranged from 2 to 21 days, with a mean time of 8.31 ± 5 days. Reduction was evaluated by the criteria given by Dujardin and colleagues, which define rotational displacement as the gap in the pubic symphysis. Symphyseal diastasis of up to 5 mm is satisfactory, whereas more than 5 mm is unsatisfactory. Satisfactory reduction was achieved in 12 cases, whereas reduction was considered unsatisfactory in two cases (Figs. 3a–f and 4a–f). The distance between the pubic bones at the symphysis is measured immediately postoperatively and 6 months later to detect any subsequent loss of reduction. There was no significant loss of reduction (Table 2). Implant failure did not occur in any case in our series. However, asymptomatic loosening of a nonlocked screw occurred in one case, which was not associated with loss of reduction (Fig. 5a–f).

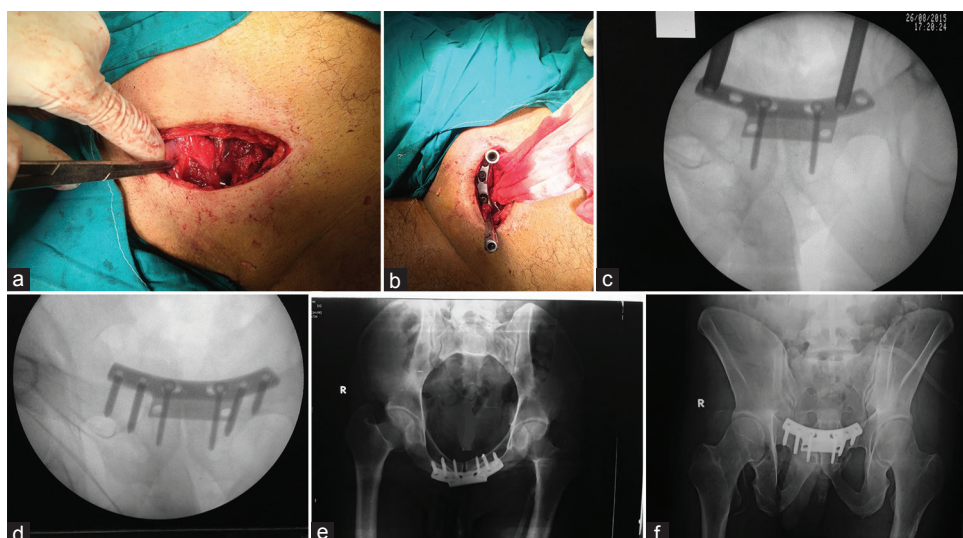
Follow-up in our series ranged from 6 to 12 months, with an average of 9.14 ± 1.30 . Functional outcome was evaluated using the Majeed functional outcome.

Figure 1



Inlet and exit views of Assiut Symphyseal Plate.

Figure 2



(a) Pfannenstiel incision. (b) Insertion of locking screws. (c) Radiologic appearance during insertion of locking screws. (d) After full fixation is achieved. (e) Postoperative inlet view. (f) Postoperative exit view.

Table 1 Demographic data

Patient No.	Sex	Age (years)	Mechanism of injury	Type of fracture (tile)	Associated injuries	Symphyseal diastasis (cm)
1	Female	26	Motor car accident	B	–	2.70
2	Female	43	Motor car accident	B	Fractured tibia and fibula	2.90
3	Male	30	Motor car accident	C	–	3.00
4	Male	23	Fall from height	B	Fractured femur and spine	3.50
5	Male	42	Motor car accident	C	–	2.70
6	Male	21	Motor car accident	B	Fractured distal radius, extradural hemorrhage, and fractured maxilla	3.00
7	Male	32	Motor bike accident	B	Fractured tibial plateau	3.00
8	Male	35	Motor car accident	B	Fractured femur	2.60
9	Male	45	Motor bike accident	B	Fractured ribs	3.50
10	Male	22	Motor car accident	C	Fractured humerus and scapula	2.60
11	Male	20	Motor bike accident	C	–	2.50
12	Male	26	Wall collapse	C	–	2.50
13	Male	62	Motor car accident	C	–	2.80
14	Female	34	Motor car accident	C	–	2.90

Table 2 Preop./Postop. symphyseal distance

Cases	Symphyseal diastasis (cm)	Immediate postoperative (cm)	Follow-up (cm)
Case no. 1	2.70	0.50	0.50
Case no. 2	2.90	0.60	0.60
Case no. 3	3.00	0.30	0.30
Case no. 4	3.50	0.50	0.50
Case no. 5	2.70	0.50	0.50
Case no. 6	3.00	0.40	0.40
Case no. 7	3.00	0.40	0.40
Case no. 8	2.60	0.80	0.90
Case no. 9	3.50	0.30	0.30
Case no. 10	2.60	0.50	0.60
Case no. 11	2.50	0.40	0.40
Case no. 12	2.50	0.40	0.40
Case no. 13	2.80	0.40	0.40
Case no. 14	2.90	0.30	0.30
Mean±SD	2.8±0.31	0.45±0.14	0.46±0.15

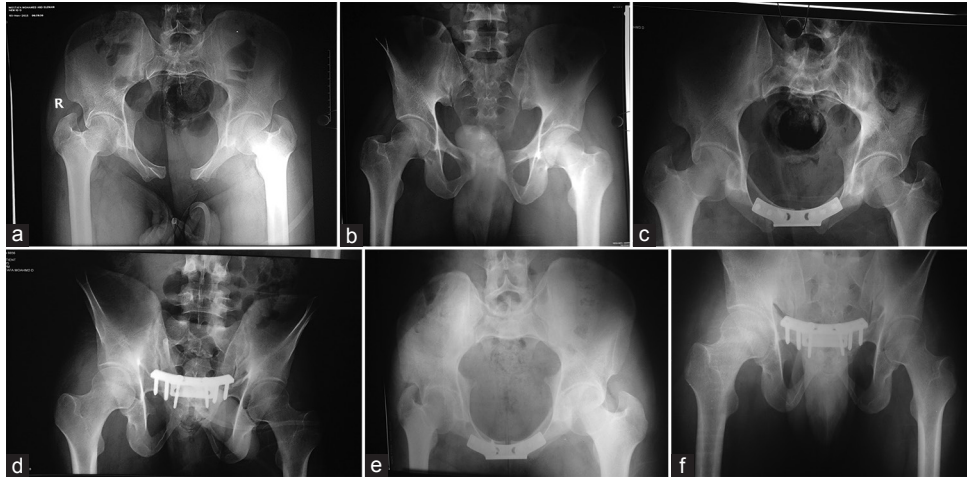
P value=0.984, not significant.

There were 11 patients working before surgery, with nine (81.8%) patients reporting excellent functional outcome, one (9.1%) reporting good result, and one (9.1%) reporting fair outcome. There were three nonworking patients, with two (66.7%) patients having excellent result and one (3.3%) patient having good result.

Discussion

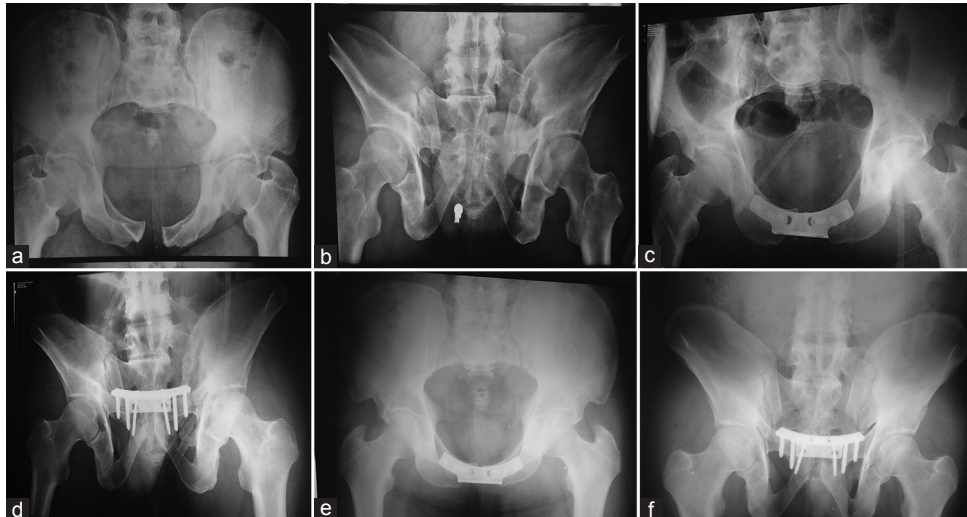
The pelvis is subjected to great forces during standing, sitting, and walking. Failure of implants, symptomatic or not, represents a common problem that is probably underestimated. Anatomical reduction of pelvic fractures should be the goal whenever possible to avoid the complications of chronic pelvic pain,

Figure 3



(a) Preoperative inlet view. (b) Preoperative exit view. (c) Postoperative inlet view. (d) Postoperative exit. (e) 8-month postoperative inlet view (f) 8-month postoperative exit view.

Figure 4



(a) Preoperative inlet view. (b) Preoperative exit view. (c) Postoperative inlet view. (d) Postoperative exit view. (e) 10-month Postoperative inlet view. (f) 10-month Postoperative exit view.

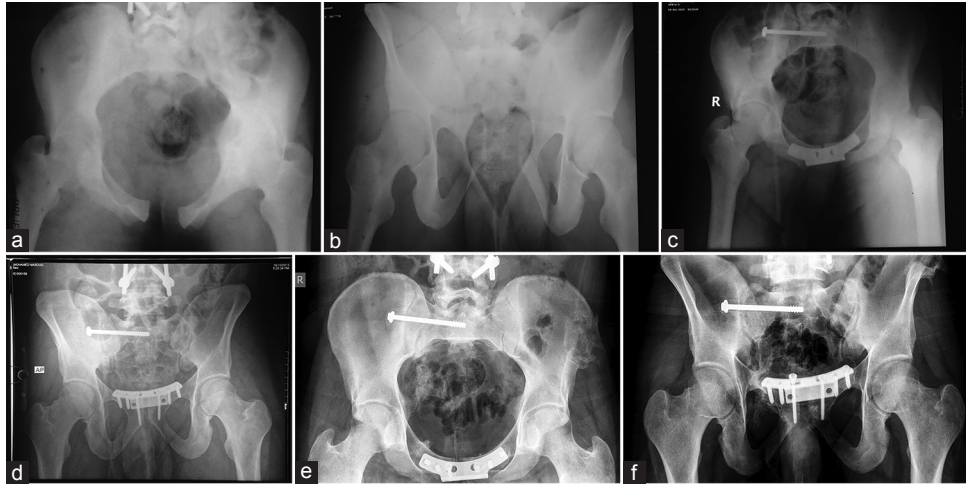
gait abnormalities, and difficulties in sitting, which adversely affects the patient's quality of life.

In our study, we used a new locked biplanar plate, 'Assiut Symphyseal Plate (ASP)', for fixation of symphyseal injuries in 14 cases of pelvis fractures. Fixation was supplemented with iliosacral screws according to the degree of displacement of the posterior injury. The cases include 11 males and three females, with age range between 21 and 62 years. Seven cases had only rotational instability whereas the other seven cases had both vertical and rotational instability. The 'Assiut Symphyseal Plate (ASP)' developed at our institution is a titanium plate composed of two parts: the horizontal part is anatomically precontoured and contains six holes that are distributed as two median combi-holes and four lateral locked holes. Hamada

et al. [11] published a retrospective analysis on 11 cases of symphyseal disruptions fixed by locked plates. They recommended the use of locked plates across the pubic symphysis to be safe with low complication rates despite early weight bearing.

Pizanis *et al.* [12] found that best results regarding compression and increased contact area can be achieved by anatomically contoured plates with combined DC and locking screw capabilities. The combi-holes allow achieving maximal compression with the use of DC screws and this compression is then secured with the use of locked screws. Sagi *et al.* [13] found that the two-hole symphyseal plating technique had a higher implant failure rate and, more importantly, a significantly higher rate of pelvic malunion. They recommended multihole plating of unstable pubic

Figure 5



(a) Preoperative inlet view. (b) Preoperative exit view. (c) Postoperative inlet view. (d) Postoperative exit. (e) 8-month Postoperative inlet view (f) 8-month Postoperative exit view showing screw loosening.

symphyseal disruptions. The vertical part should act as anterior buttress, which allows correction of AP displacement. It has two holes, which can be used to help reduction before definitive fixation is completed. The fixed relationship between the vertical and horizontal parts aims to optimize rotation of the hemipelvis in the sagittal plane. The design of the ASP fulfills all the recommendations of the previous reports. It is biplanar and anatomically shaped, with multiple holes that allow both compression and screws locking, and the fixed relationship between the vertical and horizontal parts serves for better rotational alignment.

In our study, symphyseal distance of 5 mm or less could be achieved in 12 (85.7%) cases, which is considered satisfactory reduction by Dujardin and colleagues. The primary reduction achieved was maintained throughout 6–12 months of follow-up in all but two cases. The functional outcome assessed according to Majeed functional score was excellent in 11 (78.5%) cases, good in two cases, and fair in one case, with an average score of 87.0. Collinge *et al.* [14] reported failure to maintain the initial postoperative symphyseal distance of 4.9 mm achieved in patients treated with conventional plates. They detected an increase in symphyseal distance over time to reach an average of 8.4 mm. Bosch *et al.* [15] measured the Majeed functional score in 37 patients who underwent symphyseal fixation by conventional stainless steel DC plates and found an average score of 79.0. Suzuki *et al.* [16] reported an average Majeed functional score of 79.9 in 57 patients with unstable fracture pelvis fixed by conventional plates.

Implant failure did not occur at any case in our series. However, asymptomatic loosening of nonlocked screw occurred in one case without loss of reduction or increase in symphyseal distance. This may be avoided

by changing the dynamic screws to locked screws after fixation is complete. Premature failure of symphyseal plates is not uncommon. Eastman *et al.* [17] described failure as early as 29 days postoperatively. Although this may not necessarily need revision surgery, careful patient education is important.

We found that fixation of symphyseal disruptions with 'Assiut Symphyseal Plate' gives good results with satisfactory reduction and excellent functional outcome. The plate is a reliable reduction tool, and it produced low failure rates.

The limitation of this study is the small number of patients and the lack of a control group. However, as a first report of the newly designed ASP, the number is adequate, and the very good results achieved will be the stimulus for a bigger prospective controlled trial.

The plate design itself may undergo some future modifications because of the anatomical variation of the pelvis in the population. Replacement of the unidirectional locked screws by multidirectional locked screws should improve plate fitting and allow better purchase for the screws. Although we used screws in the vertical part in some cases to reduce AP displacement, they did not achieve the desired grip so we had to remove them eventually. We believe that modification of this part to have combi-holes may be more advantageous. The combi-holes would allow additional compression that can be secured with locking screws.

Another issue for future investigation is whether anterior fixation with locked biplanar symphyseal plate should be supplemented with posterior fixation or not and the type of posterior fixation needed.

Financial support and sponsorship

Nil.

Conflicts of interest

There are no conflicts of interest.

References

- 1 HC Sagi, NR Ordway, T DiPasquale. Biomechanical analysis of fixation for vertically unstable sacroiliac dislocations with iliosacral screws and symphyseal plating. *J Orthop Trauma* 2004; 18:138–143.
- 2 Tile M. *Fractures of the pelvis and acetabulum*. Baltimore: Williams & Wilkins; 1984.
- 3 Young JWR, Burgess AR. *Radiologic management of pelvic ring fractures*. Baltimore: Urban and Schwarzenberg; 1987:45.
- 4 Letournel E, Judet R, Elson RA. Fractures of the acetabulum. *Reconstruction of the Injured Pelvis: Fixation Techniques*. New York, NY: Springer-Verlag; 1981. p. 125.
- 5 Webb LX, Caldwell K. Disruption of the pelvic ring caused by vertical shear. *South Med J* 1981; 10:1217.
- 6 Simonian PT, Schwappach JR, Routt ML Jr, Agnew SG, Harrington RM, Tencer AF. Evaluation of new plate designs for symphysis pubis internal fixation. *J Trauma* 1996; 41:498–502.
- 7 Sagi HC, Papp S. Comparative radiographic and clinical outcome of two-hole and multi-hole symphyseal plating. *J Orthop Trauma* 2008; 22:373–378.
- 8 Tornetta P3rd, Dickson K, Matta JM. Outcome of rotationally unstable pelvic ring injuries treated operatively. *Clin Orthop Relat Res* 1996; 329:147–151.
- 9 Dujardin FH, Hossenbaccus M, Duparc F, Biga N, Thomine JM. Long-term functional prognosis of posterior injuries in high-energy pelvic disruption. *J Orthop Trauma* 1998; 12:145–150.
- 10 Majeed SA. Grading the outcome of pelvic fracture. *J Bone Joint Surg Br* 1989; 71-B: 304–306.
- 11 A Hamada, G Pavlou, J Dwyer, J Lim. Management of pubic symphysis diastasis with locking plates: a report of 11 cases. *Injury, Int J Care Injured* 2013; 44:947–951.
- 12 A Pizanis, P Garcia, M Santelmann, U Culemann, T Pohlemann. Reduction and fixation capabilities of different plate designs for pubic symphysis disruption: a biomechanical comparison. *Injury* 2013; 44:183–188.
- 13 HC Sagi, S Papp. Comparative radiographic and clinical outcome of two-hole and multi-hole symphyseal plating. *J Orthop Trauma* 2008; 22:373–378.
- 14 C Collinge, MT Archdeacon, E Dulaney-Cripe, BR Moed. Radiographic changes of implant failure after plating for pubic symphysis diastasis: an underappreciated reality? *Clin Orthop Relat Res*. 2012; 470:2148–2153.
- 15 EW van den Bosch, R van der Kleyn, M Hogervorst, AB van Vugt. Functional outcome of internal fixation for pelvic ring fractures. *J Trauma* 1999; 47:365–371.
- 16 Suzuki T, Shindo M, Soma K, Minehara H, Nakamura K, Uchino M, Itoman M. Long-term functional outcome after unstable pelvic ring fracture. *J Trauma* 2007; 63:884–888.
- 17 Eastman Jonathan G, Krieg James C, Routt Milton L. Early failure of symphysis pubis plating. *Injury* 2016; 47:1707–1712