

The avascular necrosis after talar neck fractures. Risk factors and Outcomes

Lokas S. Asham^a, Amr A. Elfadle^b, Mahmoud Badran^b, Aly M. Mohamed^b, Osama A. Farouk^b

^aResident Doctor of Orthopedics and Traumatology Department at Students' Hospital - Assuit University, ^bDepartment of Orthopedics and Traumatology, Assiut University Hospitals, Faculty of Medicine, Assiut University, Assiut, Egypt

Correspondence to Lokas S. Asham, Orthopedics and Traumatology Department, Students' Hospital - Assiut University, Assiut, Egypt.

Postal/Zip Code: 71511;
Tel: +201013918280;
e-mail: lokassamir@gmail.com

Received 23 February 2020

Revised 06 March 2020

Accepted 19 May 2020

Published 30 December 2021

Journal of Current Medical Research and Practice

2021, 6:340–345

Background

The incidence of talar fractures is less than 1.0% of all fractures. Fractures of the talar neck and body are often due to high-energy trauma such as motor vehicle accident or falls from height. The purpose of the present study is to evaluate the effect of different factors, including fracture type, skin condition, surgical delay, quality of fracture reduction, and surgical approach, on the incidence of osteonecrosis after talar neck fractures and to determine the functional outcomes after osteonecrosis.

Patients and methods

This study is a single center prospective case series of 64 patients of talar neck fracture. 50 patients who were included in this study, were evaluated and treated at the Department of orthopedics, Assiut university hospital during 1 / 2016 to 8 /2018. While there were 14 cases were excluded. The final results were assessed using American Orthopaedic Foot and Ankle Society score (AOFAS).

Results

Osteonecrosis was associated with the degree of fracture-dislocation and fracture comminution ($P < 0.001$) and bad skin condition ($P < 0.001$). Osteonecrosis was associated with the quality of fracture reduction ($P = 0.003$). There was a significant correlation between the development of osteonecrosis and the surgical approach ($P = 0.013$). Osteonecrosis statistically affected the final functional outcome according to American Orthopedic Foot and Ankle Society score ($P < 0.001$).

Conclusion

Osteonecrosis was associated with degree of fracture, fracture-dislocation, and bad skin condition, confirming that higher-energy injuries are associated with more complications and a worse prognosis. However, no correlation was found between the timing of fixation and the development of osteonecrosis. Moreover, osteonecrosis was associated with quality of reduction and surgical approach. We recommend urgent reduction of dislocations and soft-tissue care. Proceeding with definitive rigid internal fixation of talar neck fractures after soft-tissue swelling has subsided may minimize complications.

Keywords:

Talar neck fractures, Osteonecrosis, AOFAS

J Curr Med Res Pract 6:340–345
© 2021 Faculty of Medicine, Assiut University
2357-0121

Introduction

The talus has been referred to 'as the universal joint of the foot [1]. The incidence of fractures of the talus ranges from 0.1 to 0.85% of all fractures [2,3]. The talar fractures range from relatively minor chips or fragments that are broken off the edges of the talus to very serious fractures such as complete talar extrusion or major crushing injuries of the talus that can be quite devastating [4].

Talar neck fractures account for ~50% of all talar fractures. Fractures of the talar neck and body are often secondary to high-energy trauma, usually owing to motor vehicle accident or falls from height owing to hyperdorsiflexion of the talus against the anterior of the tibia [5]. Approximately 50% of patients have multiple traumatic injuries. So, general assessment is

mandatory, and life-threatening injuries must take the priority [6].

The most commonly used classification for talar neck fractures is that described by Hawkins [7] (Fig. 1). In the Hawkins classification, type I refers to a fracture without associated joint dislocation, that is, an undisplaced fracture of the talar neck. As noted by Daniels and Smith [8], there is no room for the term 'a minimally displaced type I talar neck fracture.' The Hawkins type II fracture refers to a talar neck fracture with associated

This is an open access journal, and articles are distributed under the terms of the Creative Commons Attribution-NonCommercial-ShareAlike 4.0 License, which allows others to remix, tweak, and build upon the work non-commercially, as long as appropriate credit is given and the new creations are licensed under the identical terms.

subluxation or dislocation of the subtalar joint. This is the most common type of talar neck fracture-dislocation [8]. A Hawkins type III fracture involves a dislocation of the ankle as well as of the subtalar joint [7–10]. The Hawkins type IV fracture was described by Canale and Kelly [9] and implies associated subluxation or dislocation of the talonavicular joint. These injuries (type IV) are relatively uncommon compared to the Hawkins type II and III fracture-dislocations [9].

The current practice is urgent reduction of fracture-dislocation to keep the vascular integrity of the talus, decrease cutaneous tension, and avoid soft-tissue compromise [2,11–14].

Urgent fixation is a matter of controversy. It is thought to be indicated to avoid the complications of osteonecrosis and skin necrosis [4,15]. Anatomical reduction is essential to achieving a good result following talar neck fractures [16–19].

The aim of this study is to determine how different factors, like fracture type, skin condition, surgical delay, quality of fracture reduction, and surgical approach, affect the incidence of osteonecrosis after talar neck fractures and to determine the functional outcomes after osteonecrosis.

Patients and methods

The study was a single-center, prospective case series study of 50 patients of talar neck fracture, who were evaluated and treated at the Department of Orthopedics, Assiut University Hospital, from January 2016 to August 2018.

This study included all skeletally mature patients with any type of fresh talar neck fractures (according

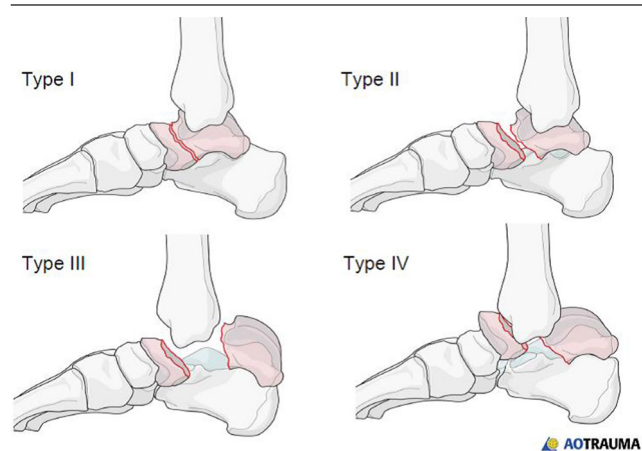
to Hawkins classifications) that occurred since less than 30 days, managed by internal fixation. Other talar fractures, open grade 3 fractures according to the Gustilo and Anderson classification system for open fractures, pediatrics (skeletally immature) fractures, pathological fractures, extruded talus, old talar neck fractures that exceeded the 30-day duration since time of trauma, and those who were managed conservatively were excluded.

A total of 50 patients, comprising 38 males and 12 females, with talar neck fractures were included in our study. Their age ranged from 15 to 76 years. The average follow-up duration was 14 months (range, 8–32 months). Local assessments of skin condition using the Gustilo and Anderson classification system for open fractures [20] and the Tscherne classification for closed fractures [21], deformity, and neurovascular status were done to all cases.

All cases were evaluated radiologically using plain radiograph films (anteroposterior, lateral, mortise, and Canale views) and computed tomographic scan. Hawkins classification system [7] was used to evaluate the talar neck fractures radiologically. All cases were managed by open or closed reduction and internal fixation. Surgical timing was estimated from the time of trauma till the time of surgery. It was divided into three groups within 8 h, between 8 and 24 h, and after 24 h. Open reduction was done using the following surgical approaches for the talar neck fractures: anteromedial including the transmalleolar approach, anterolateral approach, posterior approach, dual approaches, and percutaneous approach. Intraoperative quality of reduction was evaluated using C-arm.

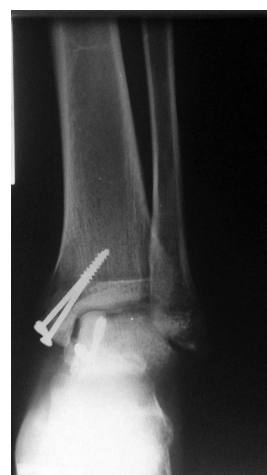Postoperative follow-up visits were arranged at ~1.5, 3, 6, 12, 18, and 24 months and were used to look for

Figure 1



Classification of talar neck fractures (Hawkins classification). AO Trauma, AO Foundation.

Figure 2



Hawkins sign, Assiut University Hospital.

clinical and radiographical assessment of osteonecrosis and final functional outcome. Quality of reduction was evaluated postoperatively according to the criteria of Lindvall *et al.* [22] (Table 1).

Osteonecrosis was defined on plain radiographs as any area of increased density of the talar dome relative to the adjacent structures or the presence of subchondral lucency (Hawkins sign; Fig. 2) [7,17,23].

The final results were assessed using American Orthopedic Foot and Ankle Society (AOFAS) score. Usually the scoring system is divided as follows: excellent: 90 and 100, good: 75–89, fair: 50–74, and poor: less than 50 [24].

The possible predictive variables included the local skin condition (open or closed), fracture type according to Hawkins' classification, surgical timing, surgical approach, and the initial quality of reduction.

All patients signed informed consent and the Institutional Review Board (IRB), Assiut University, approved the study by the Ethical Committee of Faculty of Medicine at Assiut University no. 17101020.

Statistical analysis

Numerical data were explored for normality by checking the distribution of data and using tests of normality (Kolmogorov-Smirnov and Shapiro-Wilk tests). Data were presented as mean, standard deviation (SD) and range values.

For Qualitative data were presented as frequencies and percentages. Chi-square test was used for comparisons regarding qualitative data. For Quantitative data was presented as mean, standard deviation (SD) and range

Table 1 Quality of reduction classification according to the criteria of Lindvall *et al.* [22]

Anatomical reduction	No step-off at the neck or body and no frontal angulation
Nearly anatomical reduction	1-3 mm step-off of any fracture fragment or slight varus angulation ($\leq 5^\circ$)
Poor reduction	An articular or neck mismatch, a step-off or gap of >3 mm, or neck angulation of $>5^\circ$

Table 2 Effect of surgical timing on the incidence of avascular necrosis

Surgical timing	AVN [n (%)]		P
	No (n=18)	Yes (n=32)	
Before 8 h (n=11)	6 (33.3)	5 (15.6)	0.34
Between 8 and 24 h (n=15)	5 (27.8)	10 (31.3)	
After 24 h (n=24)	7 (38.9)	17 (53.1)	

AVN, avascular necrosis. χ^2 test. *Statistically significant difference ($P < 0.05$). **Highly statistically significant difference ($P < 0.01$).

values. One way ANOVA test was used for comparisons regarding quantitative data.

The significance level was set at $P \leq 0.05$. Statistical analysis was performed with IBM SPSS Statistics Version 20 for Windows.

Results

Clinical assessment revealed that 13 cases had medical co-morbidities, 10 cases were patients with polytrauma, and 23 cases had associated foot and ankle fractures. Moreover, 27 cases had isolated talar neck fracture. In addition, seven cases had open talar neck fractures and 43 cases were closed.

Radiological evaluation according to Hawkins classification [7] revealed that type I and type II fractures of the neck of talus were the most common types (60.0%), whereas type IV was the least common (6.0%).

Management was done at Assiut University Hospital. Surgical timing was recorded for every patient. Open reduction using anteromedial approach including the transmalleolar was the most common used in this study (14 cases) followed by the dual approaches and the percutaneous approach (13 cases each), posterior approach (six cases), and finally, the anterolateral approach (four cases). Quality of reduction was assessed using the Lindvall criteria [22] and revealed that reduction was anatomical in 14 cases, near anatomical in 32 cases, and poor reduction in four cases.

Complications in this study were evaluated after at least 8 months of postoperative follow-up. Osteonecrosis [avascular necrosis (AVN)] of the talus was seen in 32 (64.0%) cases. Signs of revascularization were seen in the form of subchondral lucency (Hawkins sign) in 15 (30%) cases.

Our study revealed that there was no statistically significant evidence that surgical timing affected the incidence of osteonecrosis of the talus ($P = 0.34$), as shown in Table 2.

However, the degree of fracture, fracture-dislocation according to Hawkins classification, statistically affected the incidence of osteonecrosis ($P < 0.0001$), as shown in Table 3, because it was 20.0% in Hawkins type I, 80.0% in type II, and 100.0% in types III and IV.

Bad skin condition especially Tscherne grade 2 closed fractures and open fractures had close relationship with the incidence of osteonecrosis ($P = 0.001$) because 20 of 32 cases with osteonecrosis had bad skin condition, as shown in Table 4.

Table 3 Effect of the fracture type according to Hawkins classification on the incidence of osteonecrosis

AVN	Fractures type according to Hawkins classification [n (%)]				P
	Hawkins type I (n=20)	Hawkins type II (n=10)	Hawkins type III (n=17)	Hawkins type IV (n=3)	
No (18)	16 (80.0)	2 (20.0)	0	0	<0.0001**
Yes (32)	4 (20.0)	8 (80.0)	17 (100.0)	3 (100.0)	

AVN, avascular necrosis. χ^2 test. *Statistically significant difference ($P < 0.05$). **Highly statistically significant difference ($P < 0.01$).

Surgical approach statistically affected the incidence of osteonecrosis ($P = 0.013$) because according to numbers available, 37.5% of all osteonecrosis cases were secondary to dual approaches, and it was the highest percentage among all other approaches as shown in Table 5.

The quality of reduction did not statistically affected the incidence of osteonecrosis ($P = 0.003$) because four (28.6%) of 14 patients who had anatomical reduction were complicated with osteonecrosis, whereas it was 75.0% in near anatomical reduction and 100.0% in displaced fractures, as shown in Table 6.

Osteonecrosis of the talus did affected the final functional outcome (AOFAS) ($P < 0.001$), as according to the available numbers, it was good to excellent in the absence of osteonecrosis (94.4%), whereas it was fair to poor in the presence of osteonecrosis (62.5%), as shown in Table 7.

Discussion

Closed fractures were classified according to Tscherne classification [21], and up to our knowledge, no previous reports or literature has used this classification in the talar neck fractures. We found a significant association of open fracture or compromised skin condition (according to Tscherne classification) and osteonecrosis of the talus ($P = 0.001$). It was almost the same as reported by Vallier *et al.* [17] in their study that 9 of 13 patients with an open fracture also had development of osteonecrosis; osteonecrosis occurred significantly more frequently in patients with open fractures than in patients with closed fractures ($P < 0.05$). Moreover, our results were as the same numbers as reported by Lindvall *et al.* [22] that osteonecrosis was a common finding seen after six of the seven open fractures [22].

In our study, fracture type according to Hawkins classification significantly affected the incidence of osteonecrosis (AVN) (<0.0001). Lindvall *et al.* [22] in their study reported the same results as ours that the rate of osteonecrosis was associated with the fracture type according to Hawkins classification. Moreover, this result was noted in other published reports [9,25–28].

However, Vallier *et al.* [17] reported the opposite that neither osteonecrosis nor collapse was associated with

Table 4 Effect of skin condition on the incidence of avascular necrosis

Skin condition	AVN [n (%)]		P
	Yes=32	No=18	
Closed=43			
Grade 0 (n=9)	3 (9.4)	6 (33.3)	0.001**
Grade 1 (n=22>20)	9 (28.1)	11 (61.1)	
Grade 2 (n=16>14)	14 (43.8)	0	
Open (n=7)	6 (18.8)	1 (5.6)	

AVN, avascular necrosis. χ^2 test. *Statistically significant difference ($P < 0.05$). **Highly statistically significant difference ($P < 0.01$).

Table 5 Effect of surgical approaches on the incidence of avascular necrosis

Approach	AVN [n (%)]		P
	No=18	Yes=32	
Anteromedial and transsalleolar=14	4 (22.2)	10 (31.3)	0.013*
Anterolateral=4	1 (5.6)	3 (9.4)	
Percutaneous=13	7 (38.9)	6 (18.8)	
Dual approaches=13	1 (5.6)	12 (37.5)	
Posterior=6	5 (27.8)	1 (3.1)	

AVN, avascular necrosis. χ^2 test. *Statistically significant difference ($P < 0.05$). **Highly statistically significant difference ($P < 0.01$).

Table 6 Effect of quality of reduction on the incidence of avascular necrosis

The quality of reduction	AVN [n (%)]		P
	No=18	Yes=32	
Anatomical (n=14)	10 (55.6)	4 (12.5)	0.003**
Near anatomical (n=32)	8 (44.4)	24 (75.0)	
Displaced (n=4)	0	4 (12.5)	

AVN, avascular necrosis. χ^2 test. *Statistically significant difference ($P < 0.05$). **Highly statistically significant difference ($P < 0.01$).

Hawkins’ classification, or the presence of an associated talar body fracture. However, their data showed a trend toward increased rates of osteonecrosis and collapse in association with greater initial fracture displacement according to Hawkins’ classification [17].

Surgical timing is a controversial issue, and we aimed to determine the effect of time delay from injury to the surgical interference. The classic articles of Hawkins [7], Canale and Kelly [9], Penny and Davis, [29] have recommend emergent treatment of talar neck fractures. The rationale for emergent treatment includes a reduction of osteonecrosis rates related to earlier reduction and decreasing secondary soft-tissue injury.

However, other authors have compared the results of early and delayed treatment and found no difference

Table 7 Effect of avascular necrosis on the functional outcome American Orthopedic Foot and Ankle Society

The American Orthopedic Foot and Ankle Society score	AVN				P
	No=18	Percentage	Yes=32	Percentage	
Excellent=15	12	94.4	3	37.5	<0.001**
Good=14	5		9		
Fair=17	1	5.6	16	62.5	
Poor=4	0		4		

AVN, avascular necrosis. χ^2 test. *Statistically significant difference ($P < 0.05$). **Highly statistically significant difference ($P < 0.01$).

such as Lindvall *et al.* [22], Vallier *et al.* [17], Sanders *et al.* [16], Higgins and Baumgaertner [30], and Patel *et al.* [31]. They reported that there was no correlation between surgical delay and the development of osteonecrosis or collapse. Our study showed the same result, and surgical timing did not have a significant effect on the development of AVN.

In our study, the choice of dual surgical approaches is more associated with AVN: 12 (92.3%) cases of 13 dual-approach cases. Fernandez *et al.* [32] reported the same that potential advantages of percutaneous fixation include less surgical dissection, which may theoretically reduce the rates of osteonecrosis. Moreover, Lindvall *et al.* [22] reported that the numbers were too small to identify any significant differences between surgical approaches regarding osteonecrosis rates. However, osteonecrosis was highest with dual approaches (61.5%) ($P = 0.53$) [22]. Schulze *et al.* [33] also preferred the single anteromedial approach, and this surgical approach avoids talar osteonecrosis. Ohl *et al.* [18] in their experience used no dual approaches, and fractures were treated through a single approach and sometimes in a percutaneously. This would explain the low rate of infection and a low osteonecrosis rate in their study.

Lindvall *et al.* [22] reported that osteonecrosis was not related to the quality of the reduction. However, Tadvil [23], Sanders *et al.* [16], and Schulze *et al.* [33] concluded that treatment should be directed to an anatomic reduction of the talar neck fracture. This will avoid articular surface incongruence and angular deformity in addition to preservation and rapid restoration of talar blood supply. The results of our study found that quality of reduction did significantly affect the incidence of AVN.

Vallier *et al.* [17] and Lindvall *et al.* [22] reported that osteonecrosis did significantly affect the functional outcome. Our study revealed the same results as osteonecrosis of the talus was associated with poorer functional outcome according to AOFAS ($P < 0.001$).

As with all clinical studies, the study has limitations. These include that the radiographic studies were not performed on a regularly prescribed basis like other studies [22] owing to poor compliance. Authors

of recent studies have questioned the value of the AOFAS scoring system, which was the only used tool to measure the final functional outcome [34].

Conclusion

Osteonecrosis was associated with talar neck fracture type according to Hawkins classification, skin condition especially open and bad closed fractures, aggressive approach, and quality of reduction. We recommend urgent treatment of open injuries and reduction of dislocations. The operative treatment of fracture neck of talus seems to require a balance between an aggressive treatment with a strictly anatomical reduction through a dual approach that allows good visualization and essential respect of soft tissues to limit skin complications or osteonecrosis.

Financial support and sponsorship

Nil.

Conflicts of interest

There are no conflicts of interest.

References

- Coltart W. Aviator's astragalus. *J Bone Joint Surg Br* 1952; 34:545–66.
- Fortin PT, Balazsy JE. Talus fractures: evaluation and treatment. *J Am Acad Orthopaedic Surg* 2001; 9:114–127.
- Santavirta S, Seitsalo S, Kiviluoto O, Myllynen P. Fractures of the talus. *J Trauma* 1984; 24:986–989.
- Tornetta III P, Ricci W, McQueen MM. *Rockwood and Green's fractures in adults*. : Lippincott Williams & Wilkins; 2019.
- Kitaoka H. *Master techniques in orthopaedic surgery: the foot and ankle*. : Lippincott Williams & Wilkins; 2013.
- Lorentzen J, Christensen SB, Krogsøe O, Sneppen O. Fractures of the neck of the talus. *Acta Orthop Scand* 1977; 48:115–20.
- Hawkins LG. Fractures of the neck of the talus. *Orthop Trauma Direct* 2010; 8:27–32.
- Daniels TR, Smith JW. Talar neck fractures. *Foot Ankle* 1993; 14:225–234.
- Canale ST, Kelly JF. Fractures of the neck of the talus. Long-term evaluation of seventy-one cases. *J Bone Joint Surg Am* 1978; 60:143–156.
- Grob D, Simpson LA, Weber B, Bray T. Operative treatment of displaced talus fractures. *Clin Orthop Relat Res* 1985; 199:88–96.
- Calhoun JH, Laughlin RT. *Fractures of the foot and ankle: diagnosis and treatment of injury and disease*. Taylor & Francis; 2005.
- Browner BD, Jupiter JB, Levine AM, Trafton PG, Krettek C. Foot injuries. In: Banerjee R, Nickisch F, Easley ME, DiGiovanni CW, editors. *Skeletal*

- trauma: basic science, management, and reconstruction*. 4th ed ed. Gulf Professional Publishing; 2009.
- 13 Boyer MI, Tejwani NC, SooHoo NF. Foot trauma. In: Nirmal C, Tejwani MNFS, MD, editors. *AAOS comprehensive orthopaedic review*. Philadelphia: American Academy of Orthopaedic Surgeons; 2014. 461–464.
 - 14 Egol KA, Koval KJ, Zuckerman JD. *Handbook of fractures*. Philadelphia: Lippincott Williams & Wilkins; 2010.
 - 15 Fulkerson EW, Egol KA. Timing issues in fracture management. *Bull NYU Hosp Jt Dis* 2009; 67:58–67.
 - 16 Sanders DW, Busam M, Hattwick E, Edwards JR, McAndrew MP, *et al.* Functional outcomes following displaced talar neck fractures. *J Orthop Trauma* 2004; 18:265–270.
 - 17 Vallier HA, Nork SE, Barei DP, Benirschke SK, Sangeorzan BJ. Talar neck fractures: results and outcomes. *JBJS* 2004; 86:1616–1624.
 - 18 Ohl X, Harisboure A, Hemery X, Dehoux E. Long-term follow-up after surgical treatment of talar fractures. *Int Orthop* 2011; 35:93–99.
 - 19 Azar FM, Canale ST, Beaty JH. Fractures and dislocations of the foot: talar fractures. In: Ishikawa SN, editor. *Campbell's operative orthopaedics*. Canada: Elsevier Health Sciences; 2016.
 - 20 Gustilo R. Current concepts in the management of open fractures. *Instr Course Lect* 1987; 36:359.
 - 21 Oestern H-J, Tschernig H. *Pathophysiology and classification of soft tissue injuries associated with fractures. Fractures with soft tissue injuries*. Springer; 1984. 1–9.
 - 22 Lindvall EHG, DiPasquale T, Herscovici DJr, Sanders R. Open reduction and stable fixation of isolated, displaced talar neck and body fractures. *J Bone Joint Surg Am* 2004; 86:2229–2234.
 - 23 Tadvi ND. Treatment and evaluation of talus neck fracture. *Int J Res Orthopaedics* 2017; 3:922–928.
 - 24 Rodrigues RC, Masiero D, Mizusaki JM, Imoto AM, Peccin MS, Cohen M, *et al.* Translation, cultural adaptation and validity of the 'American Orthopaedic Foot and Ankle Society (AOFAS) Ankle-Hindfoot Scale'. *Acta Ortopédica Brasil* 2008; 16:107–111.
 - 25 Pennal GF. Fractures of the talus. *Clin Orthopaedics Related Res* 1963; 30:53–63.
 - 26 Pearse M, Fowler J, Bracey D. Fracture of the body of the talus. *Injury* 1991; 22:155–156.
 - 27 Elgafy HEN, Tile M, Stephen D, Kase J. Fractures of the talus: experience of two level 1 trauma centers. *Foot Ankle Int* 2000; 21:1023–1029.
 - 28 Frawley PAHJ, Young DA. Treatment outcome of major fractures of the talus. *Foot & ankle international. Foot Ankle Int* 1995; 16:339–345.
 - 29 Penny JN, Davis LA. Fractures and fracture-dislocations of the neck of the talus. *J Trauma* 1980; 20:1029–1037.
 - 30 Higgins TF, Baumgaertner MR. Diagnosis and treatment of fractures of the talus: a comprehensive review of the literature. *Foot Ankle Int* 1999; 20:595–605.
 - 31 Patel R, Van Bergeyck A, Pinney S. Are displaced talar neck fractures surgical emergencies? A survey of orthopaedic trauma experts. *Foot Ankle Int* 2005; 26:378–381.
 - 32 Fernandez ML, Wade AM, Dabbah M, Juliano PJ. Talar neck fractures treated with closed reduction and percutaneous screw fixation: a case series. *Am J Orthop (Belle Mead, NJ)* 2011; 40:72–77.
 - 33 Schulze W, Richter J, Russe O, Ingelfinger P, Muhr G. Surgical treatment of talus fractures. *Acta Orthop Scand* 2002; 73:344–351.
 - 34 SooHoo NF, Shuler M, Fleming LL. Evaluation of the validity of the AOFAS clinical rating systems by correlation to the SF-36. *Foot Ankle Int* 2003; 24:50–55.