

## The Characteristic MRI Features of Transitional Vertebra

Enas Sweed<sup>a</sup>, Esraa K. Abdel Samad<sup>a</sup>, Mohamed Gouda<sup>b</sup>

<sup>a</sup> Radio Diagnosis Department,  
Faculty of Medicine Benha  
University, Egypt.

<sup>b</sup> Orthopedic Surgery  
Department, Faculty of  
Medicine Benha University,  
Egypt.

### Corresponding to:

Dr. Enas Sweed.  
Radio Diagnosis Department,  
Faculty of Medicine Benha  
University, Egypt.

**Email:** dr.enas.sweed@gmail.com

**Received:** 11 October 2023

**Accepted:** 28 July 2024

### Abstract:

**Background:** Lumbosacral transitional vertebrae (LSTV) is a congenital anomaly of the L5-S1 junction. An LSTV must be identified to avoid surgical mistakes. Although LSTVs can be detected on all imaging modalities, i.e. Ferguson radiographs (AP radiographs tilted cranially at 30°), MR imaging is more frequently recommended. **Aim:** The goal of this study is to determine the superiority of MRI in identifying LSTV and related anomalies as well as to evaluate the contribution of anatomical landmarks to precise lumbar vertebral counting. **Patients and Methods:** This retrospective study included 53 patients, with low back pain, most of patients had done MRI as a first investigation. The cases under study were collected from Benha University Hospitals and radiology Masr scan in the period between September 2022 to October 2023. The study was approved by the ethical committee (MS 9.6.2020). Adult patients between 18 years to 66 years, attending MRI unit and fulfilling the inclusion and exclusion criteria recruited in the study. Sagittal T2, coronal T2, and proper axial T2 sections of the lumbar region using Siemens a 1.5-Tesla MRI. **Results:** This study establishes that MRI is gold standard in assessing LSTV and associated abnormalities. Approximately 28.4% of female patients and 26.4% of male patients had sacralization of the lumbar vertebra, whereas 26.4% of female patients and 18.8% of male patients had lumbarization, according to MRI features of the LSTV.

**Conclusion:** MRI is a dependable and accurate method for identifying LSTV, associated abnormalities and surgical planning. The classification system for LSTV using MRI aids in management and improve the effectiveness of surgical intervention at the correct level.

**Key Words:** MRI, Superiority, Transitional Vertebra

## Introduction

Lumbosacral transitional vertebra (LSTV) is a developmental spinal anomaly. LSTVs are common in the general population, with a reported prevalence of 4%–30%<sup>(1)</sup> in which the lowest lumbar vertebra shows elongation of its transverse process and varying degrees of fusion/failure of segmentation from the sacrum<sup>(2)</sup>.

Definite manifestations are lumbarization of S1 (nonfusion between the first two sacral segments) or sacralization of the fifth lumbar vertebra (fusion between L5 and the first sacral segment).<sup>(3)</sup>

LSTV may present with back pain and must be put into consideration while evaluating MRI images for back pain. MRI also facilitates identification of any other associated pathologies that may related to this anatomical variant<sup>(4)</sup>.

Symptoms can originate from the anomalous articulation itself, the contralateral facet joint (when unilateral), instability and early degeneration of the level cephalad to the transitional vertebrae, and nerve root compression from hypertrophy of the transverse process. The symptoms associated with each of the above processes are treated differently, requiring reliable techniques to not only identify LSTVs but also determine the type and site of the pathology generated by the transitional segment.

Although not always available to the reader of magnetic resonance imaging (MRI), the anteroposterior radiograph of the lumbar spine IT continues to be the important for identifying the aforesaid phenomenon<sup>(5)</sup>

LSTVs can be seen on axial imaging of the lumbosacral junction, which show the pseudo-arthrosis or fusion of the last lumbar vertebra with the sacrum, or on coronal views of the lumbar spine, which highlight the transitional lumbosacral anatomy. While the lumbosacral junction may mistakenly be recognized at the L4-L5 level in sagittal scout pictures of people with LSTV, leading in insufficient axial coverage of the transitional level, lumbar

spine MRI studies typically do not obtain coronal images. LSTVs may thus go unnoticed on an MRI.

It is evident that the contour of the sacral concave surface appears to be convex at lumbarization in that kind of sacralization and lumbarization according to this study, therefore the orientation of the anatomy of that region is useful prior to surgical procedures. The purpose of this hypothesis is to demonstrate a useful technique for determining whether the sacralized L5 or lumbarized S1 vertebral segment makes up the lumbosacral transitional vertebra in order to accurately detect the S1 vertebral body, which is crucial for figuring out sagittal balance, avoid making the wrong measurements, and avoid having the wrong level surgeries<sup>(6)</sup>

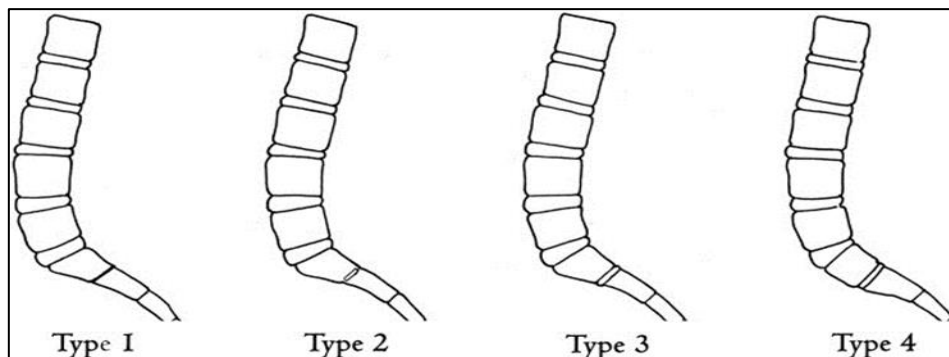
Other morphologic characteristics of transitional vertebrae include squaring of the upper sacral segment when it is lumbarized and wedging of the lowest lumbar segment when it is sacralized<sup>(1)</sup>. Fig.1

Similarly, it has been noted that the disc space between S1 and S2 is larger when a lumbarized S1 is present than the rudimentary disc that is typically found in spines without transitions. By using sagittal MR images, a 4-type categorization system for S1-2 disc morphology based on the presence or absence of disc material and the AP length of the disc. Type 1 individuals lack transitional segments and display no disc material. Type 2 has a little residual disc with an AP length that is shorter than the sacrum. Most of the patients with this kind also lack transitional segments. Type 3 is a well-formed disc that spans the sacrum's AP length<sup>(7)</sup>.Fig.1&2

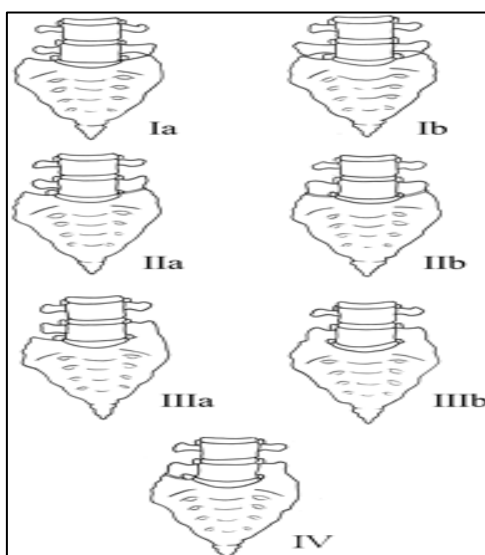
LSTV is divided into 4 categories. Type I consists of dysplastic transverse processes that are 19 millimeters wide (craniocaudal dimension) and can be unilateral (Ia) or bilateral (Ib). Type II describes an expanded transverse process with a diarthrodial joint between it and the sacrum and incomplete unilateral (IIa) or

bilateral (IIb) lumbarization/sacralization. With full osseous fusion of the transverse process (es) to the sacrum, Type III LSTV exhibits unilateral (IIIa) or bilateral (IIIb)

lumbarization/sacralization. When there is a unilateral type II at one side and a type III on the opposite side, the condition is type IV.<sup>(8)</sup>.Fig.2



**Figure 1:** Illustration depicting the O'Driscoll classification system of S1–2 disc morphology.



**Figure 2:** Illustration demonstrating the Castellvi classification of LSTVs.

**Patients and Methods:**

This retrospective study included 53 patients with low back pain. Most of patients had done MRI as a first investigation collected from Benha University Hospitals MRI unit and Radiology Masr scan in the period between September, 2022 to October 2023. The study was approved by the Local Ethical Committee of the Faculty of Medicine, Benha University (MS 9.6.2020). Patients were excluded if there was a history of spinal trauma, fractures,

infection, or previous lumbar spine surgery. Only 12 patients have an X-ray that revealed a suspect lumbosacral vertebra.

MRI performed using Siemens 1.5 Tesla.

**Technique of lumbosacral MRI**

**Sagittal T1&T2**

**Axial T1&T2**

**Coronal T2**

**Sagittal FATSAT**

**Numbering techniques:**

The most precise method for counting the lumbar vertebrae is whole-lumbar MRI.

The tangent sign was tested in LSTV cases where it was found to be able to distinguish between sacralization and lumbarization.

The right renal artery, the aortic bifurcation, and both structures together are accurate anatomical landmarks for identifying the lumbar vertebral segments on an MRI <sup>(9)</sup>

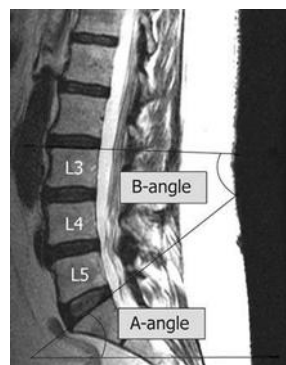
On the sagittal MRI scans, The RRA's ostium is typically visible between the lower third of the L1 vertebra and the upper third of the L2 vertebra, just below the level of the superior mesenteric artery <sup>(9)</sup>

Another technique used to correctly number an LSTV is locating the iliolumbar ligaments, because they reliably arise from the L5 transverse processes to the posteromedial iliac crest <sup>(10)</sup>

The anatomic importance of AB in finding the lumbar vertebral segments was examined in 210 cases. The L4 vertebra was the location of AB most frequently <sup>(11)</sup> In lumbar spine MRI investigations of patients with and without LSTVs, we utilized two specific angle assessments.

Because the transitional lumbosacral architecture is linked to changes in the lumbosacral curvature. A-angle, formed by a line perpendicular to the axis of the scan table and a line parallel to the superior surface of the sacrum; B-angle, formed by a line perpendicular to the superior endplate of the L3 vertebra and a line parallel to the superior surface of the sacrum. The radiologist was alerted to the possibility of an LSTV by an excessive lumbar lordosis, an A-angle greater than 40°, a B-angle greater than 36°, a substantial sacral tilt with respect to the scan table's axis. Fig.3.

**Statistical analysis:** The statistical software for social science (IBM SPSS) version 26.0 was used to arrange, tabulate, and statistically analyze the acquired data. Mean and standard deviation (SD) were used to express quantitative data. Relative frequency and percentage were used to depict qualitative data. Data were displayed using graphs, tables, and numerical presentations. P-values of 0.05 or lower were regarded as statistically significant.



**Fig.3:** Proposed A-angle and B-angle from Chalian et al. <sup>(5)</sup> Midsagittal T2-weighted image of the lumbar spine. First, a line is drawn parallel to the superior sacral surface. The A angle is determined by the intersection of this line and a line perpendicular to the axis of the scan table. The B angle is determined by the intersection between the first line and a line parallel to the superior surface of L3. Reused with permission from Chalian et al. <sup>(5)</sup>

## Results:

Fifty-three individuals with transitional vertebra were enrolled in this study, with 24 men (45, 3%) and 29 women (45, 7%) being females. As can be seen in (Table 1),

their ages ranged from 18 to 66 years. All patients have (100%) lower back pain.

Approximately 28.4% of female patients and 26.4% of male patients had sacralization of the lumbar vertebra, whereas 26.4% of female patients and

18.8% of male patients had lumbarization, according to MRI features of the transitional lumbosacral vertebra.

Proper distribution of the level of the aortic bifurcation in sacralized L5 and lumbarized S1 (Table 2). In patients with a sacralized L5, the level of the aortic bifurcation is approximately 0.5–1 level higher cranially. 22 (41.5%) individuals had aortic bifurcation in the L3-L4 region, with L5 (28.3%) having sacralization and 7 (13.2%) having lumbarization. Fig.4.

At L4 level 20 (37.7%) patients 11(20.8%) in sacralization and 9 (17%) of lumbarization.

At L4-L5 11(20.8%) patients 3 (5.6%) in sacralization and 8(15.1%) in lumbarization.

The right renal artery is seen at L1 level in 16 (30.2%) patients 7(13.2%) in sacralization and 9(17%) in lumbarization.(Table 3).

At level L2, 4 (7.5%) 0 in sacralization and 4(7.5%) in lumbarization.

L1-L2 in 32(60.4%), 22(41.5%) in sacralization and 10(18.9%) in lumbarization.

D12-L1 1(1.9%), 0 in sacralization and 1(1.9%) in lumbarization.

Superior mesenteric artery is seen in L1 20(37.7%), 3(5.6%) in sacralization and 17(32.1%) in lumbarization.( Table 4)

At level of D12 11(20.8%), 9(17%) in sacralization and 2(3.7%) in lumbarization.

At D12-L1, 17(32.1%) in sacralization and 5(9.4%) in lumbarization.

At D11-D12: 5(9.4%), 5 (9.4%) in sacralization and 0 on lumbarization as shown in (Fig.4)

**Iliolumbar ligament**

At level L4, 20 (37.7%), 15(28.3%) in sacralization and 6(11.3%) in lumbarization

At L5, 11(20.8%), 6(11.3%) in sacralization and 14(26.4%) in lumbarization.

L4-L5, 17 (32.1%), 8(15.1%) in sacralization and 2(3.7%) in lumbarization

At L5 -S1, 5(9.4%), 0 in sacralization and 2(3.7%) in lumbarization as shown in (Table 5)

Only 27 patients out of 53 subjects had the tangent iliac crest cross the lumbar spine above the lower fourth of the L4-vertebral body (Table 6), where it occurred most frequently. In other words, only 27 out of 53 individuals (12%) had more than 11/4 vertebra below the tangent iliac crest.

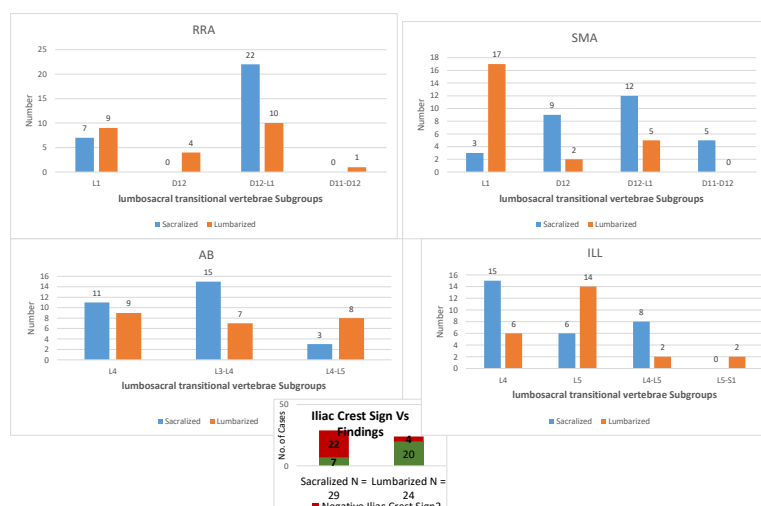


Fig.4: Different anatomical landmarks in lumbosacral transitional vertebrae Subgroups

**Table (1):** Comparison between sacralization and lumbarization regarding personal demographic data of the studied subjects

Demographic data	No. (%)	Sacralized No = 29	Lumbarized No = 24	P-value	Sig.
Age	< 30 Y	6 (11.3%)	6 (11.3%)	0.028*	HS
	30 – 50 Y	22 (41.5%)	12 (22.6%)		
	> 50 Y	25 (47.2%)	11 (20.8%)		
	Mean $\pm$ SD	45.81 $\pm$ 19.78	41.00 $\pm$ 20.14		
Gender	Female	29 (54.7%)	15 (28.4%)	0.638*	NS
	Male	24 (45.3%)	14 (26.4%)		

**Table 2:** Aortic bifurcation at sacralization and lumbarization groups.

Aortic bifurcation	Total No. (%)	Sacralized No = 29	Lumbarized No = 24	P-value	Sig.
L4	20 (37.7%)	11 (20.8%)	9 (17 %)	0.840	NS
L3-L4	22 (41.5%)	15 (28.3%)	7 (13.2%)		
L4-L5	11 (20.8%)	3 (5.6%)	8 (15.1%)		

**Table 3:** Right renal artery in lumbarization and sacralization.

Right renal artery	Total No. (%)	Sacralized No = 29	Lumbarized No = 24	P-value	Sig.
L1	16 (30.2%)	7 (13.2 %)	9 (17 %)	0.025	HS
L2	4 (7.5%)	0	4 (7.5%)		
L1-L2	32 (60.4%)	22 (41.5%)	10 (18.9%)		
D12-L1	1 (1.9%)	0	1 (1.9%)		

**Table 4:** Superior mesenteric artery in lumbarization and sacralization.

Superior mesenteric artery	Total No. (%)	Sacralized No = 29	Lumbarized No = 24	P-value	Sig.
L1	20 (37.7%)	3 (5.6 %)	17 (32.1 %)	0.000	HS
D12	11 (20.8%)	9 (17 %)	2 (3.7%)		
D12-L1	17(32.1%)	12 (22.6%)	5 (9.4%)		
D11-D12	5 (9.4%)	5 (9.4%)	0		

**Table 5:** Iliolumbar ligament in lumbarization and sacralization.

Iliolumbar ligament	Total No. (%)	Sacralized No = 29	Lumbarized No = 24	P-value	Sig.
L4	20 (37.7%)	15 (28.3%)	6 (11.3 %)	0.006	HS
L5	11 (20.8%)	6 (11.3 %)	14 (26.4%)		
L4-L5	17(32.1%)	8 (15.1%)	2 (3.7%)		
L5-S1	5 (9.4%)	0	2 (3.7%)		

## Discussion

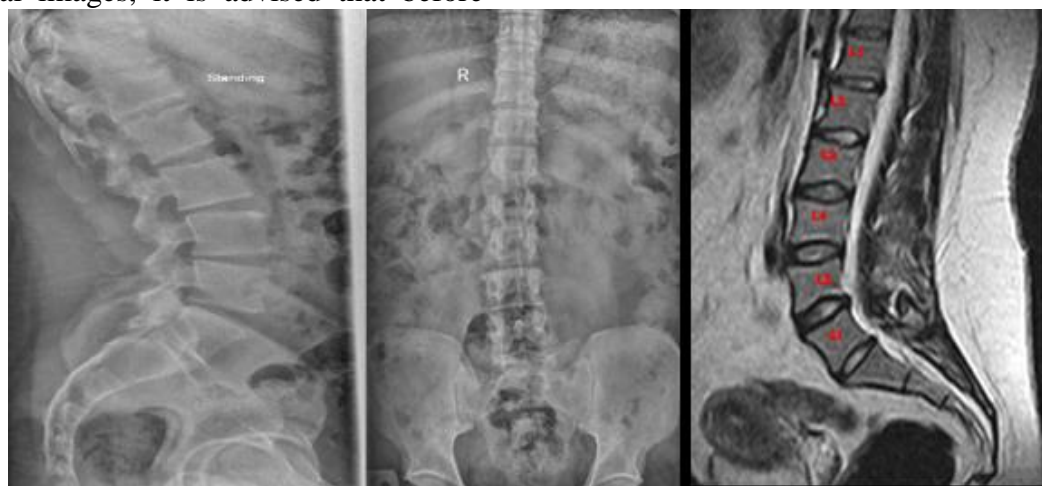Lumbosacral transitional vertebrae (LSTV) are congenital spinal deformities in which the "first" sacral segment and the extended transverse process of the last spinal lumbar vertebra fuse to varying degrees.

As a morphological orientation, the L5's sacralization ranges from partial to complete, while its lumbarization ranges from partial to complete S1. Fig.5<sup>(12)</sup>

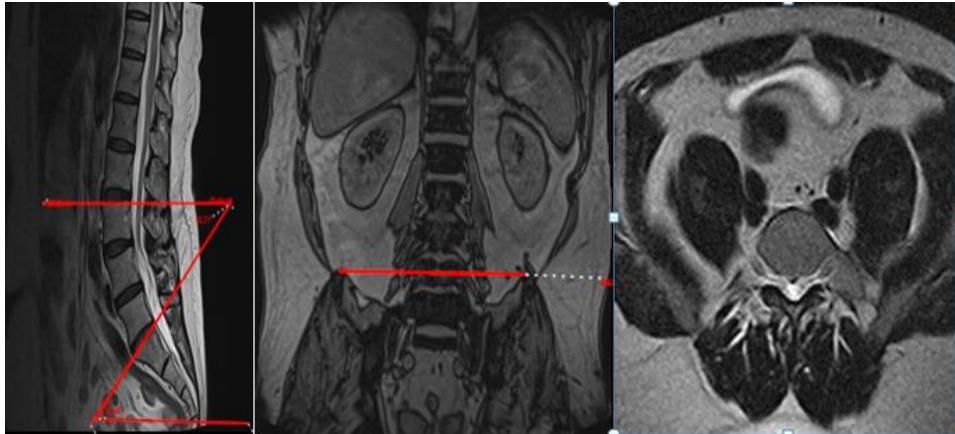
There is no connection between transitional vertebrae and low back discomfort, contrary to this study, that patients with LSTV did not have a higher incidence of structural pathology (disc pathology, spinal and foraminal stenosis, etc.) than patients without transitional vertebrae.<sup>(1)</sup>

Both angles considerably increased in persons with LSTV compared to controls, supporting our data. The sensitivity of the two angles was comparable, while the A-angle showed more specificity. Since the majority of radiologists begin their evaluation of lumbar spine MRIs from the sagittal images, it is advised that before

moving on to the detailed study assessment, an A-angle or B-angle measurement, or at the very least a gross assessment of the sacral inclination and lumbar lordosis, should be carried out. The radiologist should be alerted to the possibility of an LSTV by an A-angle more than 40° and B-angle more than 36°, a significant sacral curvature with respect to the scan table's axis, or an extreme lumbar lordosis. The B-angle is more difficult to visually evaluate and may have difficulties to measure than the A-angle (the forming lines may overlap beyond of the image, for example). Of course, substantial degenerative disc disease, advancing age, or higher levels of listhesis may also contribute to increased lumbar lordosis. The findings of this study indicate that to prevent missing an LSTV, this finding should be carefully examined in young participants. When a complete spine MRI scan is unavailable, we think counting down from C2 or T1 is the most accurate method for determining the vertebral numbers<sup>(5)</sup> Fig 6.



**Fig.5:** 40 years male patient with low back pain and ipsilateral sciatica Lateral (a) and AP (b) lumbosacral X-ray show suspected transitional vertebra and (c) Mid-sagittal T2-weighted fast spin-echo image of the lumbar spine illustrates the morphological changes at transitional vertebra (wedging shape of S1).



**Fig.6:** 55 years female patient complain from back pain

(a)Mid-sagittal T2-weighted fast spin-echo image of the lumbar spine illustrates the A and B angle measurements which were performed in the study (b) coronal T2-weighted fast spin-echo image of the lumbar spine illustrates the positive iliac crest sign in lumbarization of S1 and (c) axial T2-weighted fast spin-echo image of the lumbar spine illustrates the level of ILL at L5 level so the transitional vertebra will be S1

This finding agrees with others

A whole-spine localizer is also advised to make it practicable to identify and count LSTV by counting caudad from C2<sup>(13)</sup>

Therefore, the limitation of our study is absence of radiographic correlation and the dependency on MRI for the identification of the transitional anatomy.

To assess the anatomic importance of the AB, RRA, and conus medullaris in finding the lumbar vertebral segments, 210 cases analyzed. The L4 vertebra and, separately, the L1-L2 vertebra were where AB and RRA were most frequently found. The conus medullaris' location was inconsistent, with L1 (56% of the time) being the most frequent location, which was proven to be an unreliable landmark. They came to the conclusion that the lumbar vertebral segments might be identified on an MRI or CT scan using the landmarks AB and RRA<sup>(11)</sup>.

The conclusion that L5 was always the origin of ILL, which was evident on axial lumbar spine MRI, was claimed. The study proposed that, like our observation, its position may be utilized to confidently assign lumbar levels in patients with LSTV.<sup>(11)</sup>

In a previous study<sup>(14)</sup>, 55 people and 71 cases of LSTV were investigated. They discovered that in 95% of the controls, ILL exclusively emerged from the L5 vertebra, identifying the L5 vertebra. On the other hand, in patients with LSTV, only 25% to 38% of ILL instances were entirely from L5. They came to the conclusion that, as we also discovered in our investigation, the level of the origin of ILL is unreliable for the identification of the L5 vertebra in the presence of an LSTV or other segmentation anomalies<sup>(14)</sup>

In 500 patients, including 67 LSTVs, were investigated. L5 was where the ILL was found<sup>(2)</sup>.

### Conclusion:

In cases when LSTV is suspected, whole spine MRI imaging and numeration caudally, beginning at C2, is the gold standard for vertebral segment numeration. The method of iliac crest tangent sign obtained on coronal magnetic resonance imaging (MRI) has effective findings beside morphological changes at L5/S1 level, for correct numeration of LSTV and discriminate its subtypes, in the absence of whole spine MRI imaging. Also A and b angle in a sagittal magnetic resonance



image is a useful tool for prediction of transitional vertebra. When identifying and counting spinal vertebral segments, anatomical landmarks including the right renal artery's origin, the superior mesenteric artery, iliolumbar ligament and the aortic bifurcation may be helpful

**Limitation:**

The coronal sequence is not done routinely for magnetic resonance lumbosacral spine

**Sources of finding**

No specific grant was given to this research by funding organizations in the public, private, or not-for-profit sectors.

**Author contribution:**

The study's authors all contributed equally. No specific grant was given to this research by funding organizations in the public, private, or not-for-profit sectors.

**Conflicts of interest:**

No conflicts of interest.

---

**References:**

1. Konin GP, Walz DM. Lumbosacral transitional vertebrae: classification, imaging findings, and clinical relevance. *AJNR Am J Neuroradiol*;2010. 31(10):1778–1786
2. Hughes RJ, Saifuddin A. Imaging of lumbosacral transitional vertebrae. *Clin Radiol*;2004. 59(11):984–991.
3. Apazidis A, Ricart PA, Diefenbach CM, Spivak JM. The prevalence of transitional vertebrae in the lumbar spine. *Spine J. Sep*;2011.11(9):858-62. doi: 10.1016/j.spinee.2011.08.005. PMID: 21951610.
4. Gamze TÜRK1,\* , Mustafa BİLGİLİ1 , Ahmet Emrah AÇAN2 , Ali KOÇ1 Lumbosacral transitional vertebrae: An overlooked cause of back pain on MRI; 2023
5. Chalian M, Soldatos T, Carrino JA, Belzberg AJ, Khanna J, Chhabra A. Prediction of transitional lumbosacral anatomy on magnetic resonance imaging of the lumbar spine. *World J Radiol*;2012 Mar 28;4(3):97-101. doi: 10.4329/wjr.v4.i3.97. PMID: 22468190; PMCID: PMC3314934.
6. Cem ATABEY1,Ahmet GUNAYDIN1,Ahmet

- EROGLU1,Meltem OZDEMİR1,Ahmet Metin SANLIA New Method for Lumbosacral Transitional Vertebra and Anatomic Orientation of Sacrum that could be applied as a Peroperative Indicator for Lumbosacral Surgery:Anterior Transitional Arch (ATA1) - Anterior Transitional Angle (ATA2) 2022.
7. O'Driscoll CM, Irwin A, Saifuddin A. Variations in morphology of the lumbosacral junction on sagittal MRI: correlation with plain radiography. *Skeletal Radiol* ;1996;25:225–30.
8. Castellvi AE, Goldstein LA, Chan DP Lumbosacral transitional vertebrae and their relationship with lumbar extradural defects. *Spine*;1984.9(5):493–495.
9. Bhagchandani C, Murugan C, Jakkepally S, Shetty AP, Kanna RM, Rajasekaran S. A Whole Spine MRI Based Study of the Prevalence, Associated Disc Degeneration and Anatomical Correlations of Lumbosacral Transitional Vertebra. *Global Spine Journal*. 2023;0(0). doi:10.1177/21925682231161559.
10. Hughes RJ, Saifuddin A Numbering of lumbosacral transitional vertebrae on MRI: role of the iliolumbar ligaments. *AJR Am J Roentgenol*;2006.187:59–65. doi:10.2214/AJR.05.0415.
11. Jagannathan D, Indiran V, Hithaya F, Alamelu M, Padmanaban S. Role of Anatomical Landmarks in Identifying Normal and Transitional Vertebra in Lumbar Spine Magnetic Resonance Imaging. *Asian Spine J*. 2017 Jun;11(3):365-379. doi: 10.4184/asj.2017.11.3.365. Epub 2017 Jun 15. PMID: 28670404; PMCID: PMC5481591.
12. Jancuska JM, Spivak JM, Bendo JA. A Review of Symptomatic Lumbosacral Transitional Vertebrae: Bertolotti's Syndrome. *Int J Spine Surg*; 2015 Jul 29;9:42. doi: 10.14444/2042. PMID: 26484005; PMCID: PMC4603258.
13. Hahn PY, Strobel JJ, Hahn FJ. Verification of lumbosacral segments on MR images: identification of transitional vertebrae. *Radiology*; 1992; 182:580–581
14. Farshad-Amacker NA, Lurie B, Herzog RJ, Farshad M Is the iliolumbar ligament a reliable identifier of the L5 vertebra in lumbosacral transitional anomalies? *EurRadiol*; 2014.doi:10.1007/s00330-014-3277-8

**To cite this article:** Enas Sweed a, Esraa K. Abdel Samad a, Mohamed Gouda. The Characteristic MRI Features of Transitional Vertebra. *BMFJ* 2024;41(5):352-360.