

## ORIGINAL ARTICLE

# SCLEROTHERAPY VERSUS SURGERY IN THE TREATMENT OF VARICOCELE: A RANDOMIZED STUDY

By

Tarek Ahmed, Hany Ali, Mohamed Korany

General Surgery Department, Assiut University, Egypt

Correspondence to: Tarek Ahmed, Email: tarektalha@yahoo.com

**Aim:** To evaluate the differences between surgical and seminological results observed in two groups of patients with primary varicocele who underwent, respectively, open surgery or antegrade sclerotherapy.

**Methods:** From Jan. 2005 to Jan. 2006, we recruited 60 patients with left sided varicocele for this study. Before treatment all patients were evaluated by a physical examination, color Doppler ultrasonography of the spermatic cord, and abdominal and scrotal ultrasonography and semen analysis. These patients were randomized to two groups; group A: 30 patients (open surgery) and B: 30 patients (antegrade sclerotherapy).

At the current follow up, it is possible to evaluate all the patients for whom we have preoperative and postoperative Doppler imaging and semen analysis.

**Results:** A satisfactory significant improvement of the rate of fast progressive spermatozoa and reduction in immotile spermatozoa in those patients who underwent sclerotherapy compared to the patients who underwent open surgery. The outcomes of all other parameters (number and morphology) are fully comparable. Operating time is decidedly shorter for antegrade sclerotherapy, but there are no significant differences in terms of early or late postoperative complications.

**Conclusion:** Our results demonstrate that sclerotherapy combines shorter surgical time and faster recovery of normal daily activities with significant improvement in sperm motility.

**Keywords:** Ethanolamine, intraoperative injection, subfertility.

## INTRODUCTION

Varicocele is a condition of varicosity and tortuosity of pampiniform plexus, caused by retrograde blood flow through the internal spermatic vein. The percentage of clinically evidenced varicocele in young adult subjects varies from 9% to 23%.<sup>(1)</sup> as reported by the most recent case studies. Furthermore, varicocele can be observed in over 40% of infertile males. In fact, many studies have been

conducted to examine the etiology and patho-physiology of varicocele as well as the influence it can have on spermatogenesis. Nevertheless, it is very questionable today how much the varicocele really damages the reproductive system and the mechanisms through which this occurs, and it is not completely clear which are the most appropriate diagnostic techniques and the most effective treatments.<sup>(2)</sup>

## PATIENTS AND METHODS

From January 2005 to January 2006 we evaluated 60 patients with left primary varicocele; exclusion criteria were recurrent varicocele, bilateral varicocele, and normal semen analysis without testicular volume reduction. All patients were clinically assessed by physical examination, color Doppler ultrasound (for scrotal imaging), and semen analysis, performed preoperatively and repeatedly (at least twice) 6 months postoperatively. We prefer to perform the first follow up visit 6 months postoperatively because we think this is a reasonable period of time in which to resume a regular spermatogenesis, and we anticipate it represents a complete post-surgical recovery. The varicocele was graded according to the system of Dubin and Amelar.<sup>(3)</sup> grade 1, detected only during a Valsalva maneuver; grade 2, palpable in basal conditions with no Valsalva maneuver; and grade 3, visible on a physical examination. Spermatic reflux was classified using a four-grade Doppler classification; grade 0, slight and brief reflux during a Valsalva maneuver; grade 1, moderate reflux ending before the Valsalva maneuver was completed; grade 2, severe reflux lasting throughout a Valsalva maneuver; grade 3, severe reflux already present with the patient supine in basal conditions.<sup>(3)</sup>

Semen samples were collected by masturbation, after 3 to 4 days of abstinence, and examined in the same lab; the examination evaluated total volume, sperm density, motility, and morphology. Basic requirements for semen analysis are standardized according to the World Health Organization (WHO) guidelines. We do not routinely perform endocrinology tests preoperatively.

In all cases, we classified varicocele on physical examination according to Dubin and Amelar classification.<sup>(4)</sup> We performed scrotal color Doppler ultrasound on all patients while they were in supine and upright position, using the same instrument, to obtain a more accurate varicocele grading.

Based on randomized, and after informed consent was obtained, the patients were admitted for the day surgery and underwent open surgery with inguinal approach (group A) or antegrade sclerotherapy (group B). The patients were assigned to different treatments according to a balanced randomized block design.

**Surgical Techniques:** The patients were pre-anesthetized with 0.5 mg atropine and IM diazepam, and given antibiotic prophylaxis before surgery of 200 mg intravenous ciprofloxacin. Open varicocelectomy was performed under spinal or even general anesthesia, with

short (4-5cm) oblique incision made over the internal ring. After incision of the muscular layer, the spermatic cord was carefully exposed. We identified the elements of the spermatic cord and spermatic veins using magnifying lenses (3.5 xs) to obtain magnification and preserve the spermatic artery. The spermatic veins were closed and ligated in the upper part of the cord, where they usually flow together in 2 to 3 major branches. At the end of these procedures we performed a careful inspection of the inguinal channel, looking for extrafunicular vessels.

Ante grade sclerotherapy was also performed under local anesthesia with a very short (2 cm) longitudinal incision at the base of the scrotum to catch funiculum (Fig. 4). The most enlarged vein was isolated and suspended between 2 lag sutures; we performed a little incision of the vein to insert a 23 gauge needle (Fig. 5). The right position of the needle was controlled by washing the vein with saline solution. When the vein is cannulated antegrade phlebography is undertaken by infusing 4-5 ml of contrast medium; this allows an assessment of the correct positioning of the cannula into the pampiniform plexus of veins, and the flow of contrast medium towards the renal vein on the left side (Figs. 1,2,3). Finally, during a Valsalva maneuver, we injected 3 ml of ethanolamine and 1 ml of air mixed together (Fig 6). After infusing the sclerosant, the cannula is immediately removed and the vein also ligated below the point of injection.

Finally, the spermatic cord fascia and the skin are closed with 4/0 chromic catgut. All patients were clinically assessed at 1 month after treatment for any late complications, the patients' satisfaction with the treatment and the recovery time. Patients were reassessed 6 months after treatment by color Doppler ultrasonography of the spermatic vein. Semen analysis was scheduled 6 months after treatment.

## RESULTS

We evaluated all 60 patients with complete Doppler imaging and semen analysis pre-operatively, post-operatively, and 6 months post-operatively. In pre-operative data analysis, no significant differences were found among the variables of the two groups in study.

As envisaged in our randomized study, all patients presented primary idiopathic left varicocele; none of the patients presented bilateral varicocele.

In the group of patients who underwent open surgery (group A), mean age was 25.8 years (range: 19-43). Three

patients presented grade I varicocele, 10 presented grade II, and 17 presented grade III. Table 1. In this group, 18 patients presented with asthenospermia, 10 presented with oligoasthenospermia, and 2 were oligospermic. Table 2.

**Table 1. Grades of varicocele presented in each groups.**

Grade/group	Group A	Group B
Grade I	3	4
Grade II	10	10
Grade III	17	16

**Table 2. Preoperative semen analysis in each group.**

Semen/group	Group A	Group B
Asthenospermia	18	19
Oligoasthenospermiza	10	8
oligospermia	2	3

The patients who underwent sclerotherapy (group B) had a mean age of 26.2 years (range: 18-45 years). Three patients presented grade I varicocele, 10 presented grade II, and 14 patients presented grade III. Table 1. Nineteen patients in this group had asthenospermia and 8 had oligoasthenospermia, while 3 were oligospermic. Table 2.

Concerning operating time, open surgery with inguinal approach procedures had an average time of 37 minutes (range: 28-58 minutes), whereas antegrade sclerotherapy required an average time of only 23 minutes (range: 16-29 minutes). The complications observed Table 3. In the antegrade sclerotherapy group occurred in 3 patients (9.9% of this group): 2 patients (6.6%) had scrotal edema, pain and indurations. One patient (3.3%)

presented moderate scrotal haematoma in the immediate postoperative period. We had no hydrocele in group B. in group A hydrocele were observed in 4 (13.4%) patients. Most of the patients who underwent sclerotherapy returned to their normal activity in the next day (except those complicated patients), while those patients underwent open surgery did this after 3 to 5 days.

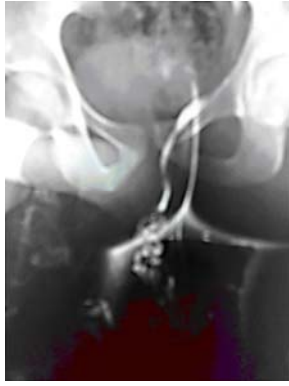**Table 3. Complications of each procedure.**

Complications/group	Group A	Group B
Scrotal edema & pain	1 (3.3 %)	2 (6.6%)
Haematoma	0	1 (3.3%)
Hydrocele	4 (13.4 %)	0
Clinical recurrence	2 (6.6%)	2 (6.6%)
Sub-clinical recurrence	1 (3.3%)	0

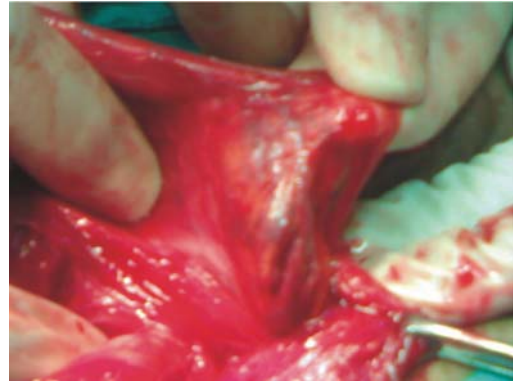
As far as recurrences are concerned, in group A we had 2 patients with clinical recurrence (6.6%) and 1 patient (3.3%) with subclinical recurrence, and in group B we had 2 patients with clinical recurrence (6.6%). Patients with recurrences in the open surgery group subsequently underwent sclerotherapy, whereas recurrences in group B patients were treated with open surgery.

Semen data were analyzed 6 months after surgery and were compared with preoperative data. This comparison yielded 2 extremely interesting results: a marked reduction of immotile sperms only in the group of the patients who underwent antegrade sclerotherapy, and also an increase in the fast progressive sperms, which was statistically marked in the group of patients who underwent sclerotherapy.

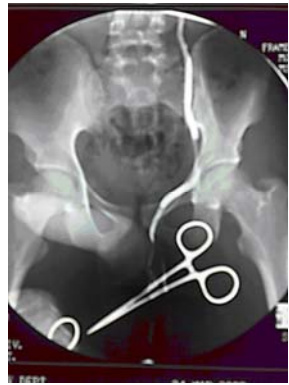As regards the other parameters of semen analysis (morphology and number), there is no obvious improvement observed in the 2 groups.



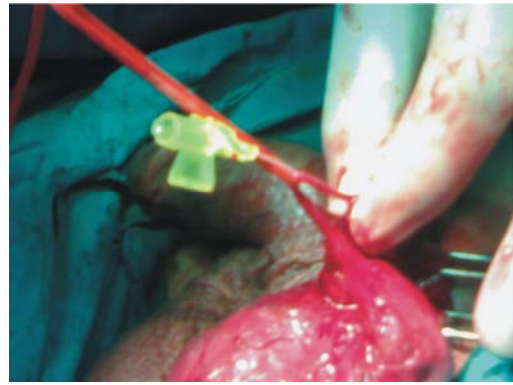
*Fig 1. Image showing the contrast medium in the pampiniform plexus and the start of testicular vein.*



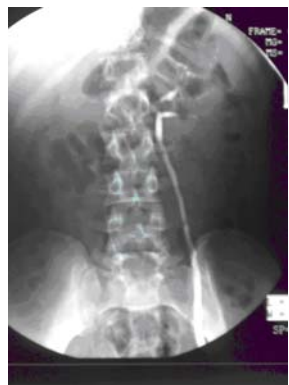*Fig 4. Exploration of the spermatic cord and dissection of pampiniform plexus of veins.*



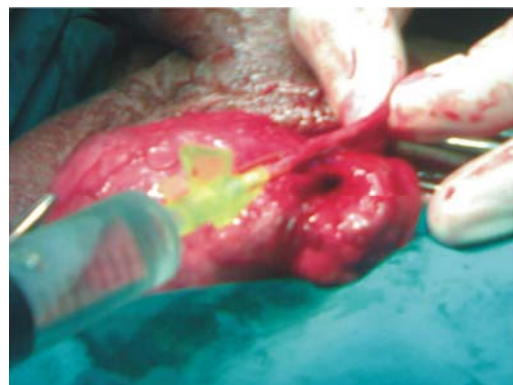
*Fig 2. Continuation of testicular vein.*



*Fig 5. Cannulation of the largest vein of the plexus.*



*Fig 3. The end of testicular vein into the renal vein.*



*Fig 6. Antegrade injection sclerotherapy.*

## DISCUSSION

It is widely known that varicocele is a pathological condition presented in a noteworthy percentage of the male population worldwide and that this percentage increases significantly when infertile subjects are analyzed. Many reports beginning with the first study conducted by Macleod in 1965<sup>(5)</sup> have widely demonstrated the correlation between varicocele and infertility. Likewise, the literature published over the past 45 years has extensively shown that both sperm parameters and pregnancy rates improve in the patients affected by varicocele once this pathology has been corrected.<sup>(6,7)</sup> Therefore, it is generally accepted that treatment of varicocele improves semen parameters, with recovery rates ranging between 60% and 80%. Schlesinger et al,<sup>(6)</sup> reviewed 16 studies that assessed the effect of varicolectomy on sperm density and reported that postoperative significant improvements were demonstrated in 12 studies and sperm motility was noted in 5 of these<sup>(6,8,9)</sup> Furthermore, although several studies report that a high grade of varicocele is associated with better recovery of semen parameters following treatment of varicocele.<sup>(10,11)</sup> we did not observe this.

The ideal treatment for primary varicocele is still discussed today: many procedures, such as open spermatic vein ligation and retrograde sclerotherapy.<sup>(11-13)</sup> and more recently, methods such as laparoscopy, microsurgery, and antegrade sclerotherapy, have been used. The antegrade scrotal sclerotherapy of spermatic vein was described for the first time in 1994 by Tauber and Johnsen.<sup>(14)</sup> and it is an easy technique, rapid to perform, effective, and carries a low complication rate. Technical failure caused by an inability to catheterize a vein of pampiniform plexus was reported in <1% of procedures.<sup>(14,15)</sup>

In the experience of Goldstein<sup>(16)</sup> and Marmar and Kim.<sup>(17)</sup> the microsurgical approach decreases the incidence of hydrocele and recurrent varicocele resulting from venous collaterals, and to the small veins, immediately adjacent to testicular artery, that are often not identified; furthermore, microdissection ensures preservation of the testicular artery, reducing the risk of testicular atrophy.

Homonnai et al.<sup>(18)</sup> observe that traditional surgical methods of ligating the spermatic vein (not microsurgical) at various levels along its course give a rate of persistent reflux of 5-15%. These procedures are associated with a postoperative hydrocele rate of 5-33 %<sup>(19)</sup> A serious complication is testicular atrophy caused by spermatic artery ligation.<sup>(14)</sup>

Each technique obviously presents advantages and disadvantages, and numerous studies have yielded contrasting results; however, in the case of recovery procedure used, the surgical exposure does not provide a

rapid restoration of sperm vitality before a period of 6 months postoperatively. Many comparative studies, which evaluate results obtained with the different methods used to treat varicocele, have reported results with a low level of significance.<sup>(5,11,15,16)</sup>

Our results demonstrate that sclerotherapy promotes significant improvement of the seminological parameters in terms of sperm motility. In fact, if we closely analyze the data, it becomes evident that in group A (open surgery); there is no obvious changes in all seminal parameters, such as for immotile (56.5% preoperative vs 49.4% postoperative). Instead, the reduction in immotile sperms is marked (59.6% preoperative vs 44.7%) in group B: and is associated with a sensible increase in the group of fast sperms presenting clear evidence of an early recovery of sperm motility.

A possible but as yet theoretical explanation may be the lower invasiveness of the antegrade sclerotherapy procedure and faster recovery of testicular function following surgical exposure; instead, in retrograde sclerotherapy, only a single vein is selected and isolated to perform the procedure, thereby sparing all the structures near it. Moreover, sclerotherapy clearly shortens operating times, thus promoting faster recovery and a quicker return to normal everyday activities.

In open surgery group we had 6.6% rate of clinical recurrence, which is likely due to the sparing of small venules surrounding the testicular artery (we did not use a microscope); we prefer to correct recurrence in the patient with subclinical varicocele as well, because the seminal parameters did not improve. In the group B (antegrade sclerotherapy), the recurrence rate was 6.6% according to this research, and this is probably due some venous anatomical variation or to the venous spasm that occur during the operation.

**In Conclusion:** The question of which is the best surgical procedure for treating varicocele continues to be widely debated. However, treatment of this pathology cannot solve the clinical symptoms that are sometimes associated with it, but it can also block ongoing damage in terms of spermatogenesis, potentially improving fertility. Antegrade sclerotherapy could be considered a valid alternative to surgical techniques that are commonly used to correct varicocele.

Our randomized study has undoubtedly confirmed what has recently been a common opinion, albeit one never supported by result data: antegrade sclerotherapy is a rapid, effective, and low-cost procedure characterized by its low invasiveness. Our results also demonstrates that antegrade sclerotherapy is associated with shorter surgical

time and an earlier return to normal daily activities, as well as good improvement in semen parameters with regard to sperm motility.

## REFERENCES

1. Segenreich E, Israilov SR, Shmueli J, Niv E, Baniel J, Livne P. Evaluation of the relationship between semen parameters, pregnancy rate of wives of infertile men with varicocele, and gonadotropin-releasing hormone test before and after varicocelectomy. *Urology*. 1998;52:853-7.
2. Onozawa M, Endo F, Suetomi T, Takeshima H, Akaza H. Clinical study varicocele: statistical analysis and the results of long term follow-up. *Int J Urol*. 2002;9:455-61.
3. Dubin L, Amelar R. Varicocele size and results of varicocelectomy in selected subfertile men with varicocele. *Fertil Steril*. 1970;21:606-9.
4. Dubin L, and Amelar R. Varicocelectomy: 986 cases in a two-year study. *Urology*. 1977;10:446-9.
5. Macleod J. Seminal cytology in the presence of varicocele. *Fertile Steril*. 1965;16:735-57.
6. Schlesinger MH, Wilets IF, Nagler HM. Treatment outcome after varicocelectomy. A critical analysis. *Urol Clin N Am*. 1994;21:517-29.
7. Segenreich E, Israilov SR, Shmueli J, Niv E, Servadio C. Correlation between semen parameters and retrograde flow into the pampiniform plexus before and after varicocelectomy. *Eur Urol*. 1997;32:310-14.
8. Mordel N, Nor-Yosef S, Magalioth EJ, Simon A, Menashe M, Berger M. Spermatic vein ligation as treatment for male infertility. Justification by post operative semen improvement and pregnancy rates. *J Reprod Med*. 1990;35:123-7.
9. Iaven JSE, Haans LC, Mali WP, de Velde ER, Wensing CJ, Eimers JM. effects of varicocele treatment in adolescents: a randomized study. *Fertile Steril*. 1992;58:756-62.
10. Steckel J, Dicker A, Goldstein M. Relationship between varicocele size and response to varicocelectomy. *J Urol*. 1993;149:769-71.
11. Abdulmaaboud MR, Shokeir AA, Farage Y, El-Rahman AA, El-Rakhawy MM, Mutabagani H. Treatment of varicocele: a comparative study of conventional open surgery, percutaneous retrograde sclerotherapy and laparoscopy. *Urology*. 1998;52:294-300.
12. Porst H, Bahren W, Lenz M, Altwein JE. Percutaneous sclerotherapy of varicoceles-an alternative to conventional surgical methods. *Br J Urol*. 1984;56:73-8.
13. Lenz M, Hof N, Kersting-Sommerhoff N, Bautz W. Anatomic variants of spermatic vein: importance for percutaneous sclerotherapy of idiopathic varicocele. *Radiology*. 1996;198:425-31.
14. Tauber R and Johnsen N. Antegrade scrotal sclerotherapy for the treatment of varicocele: technique and late results. *J Urol*. 1994;151:386-90.
15. Tauber R and Pfiffer D. Antegrade sclerotherapy for varicocele testis-possible and avoidable complications. *Urol A*. 2003;42:1238-43.
16. Goldstein M. Microsurgical inguinal varicocelectomy with delivery of testis: an artery and lymphatic sparing technique. 1992;148:1808-11.
17. Marmar JL, and Kim Y. Subinguinal microsurgical varicocelectomy: a technical critique and statistical analysis of semen and pregnancy data. *J Urol*. 1994;152:1127-32.
18. Homonnai ZT, Fainman N, Engelhard Y, Rudberg Z, David MP, Paz G. Varicocelectomy and male infertility: comparison of semen quality and recurrence of varicocele following varicocelectomy by two techniques. *J Androl*. 1980;3:447-58.
19. Szabo R and Kessler R. Hydrocele following internal spermatic vein ligation: a retrospective study and review of the literature. *J Urol*. 1984;132:924-25.