

SURGICAL PHOTO QUIZ

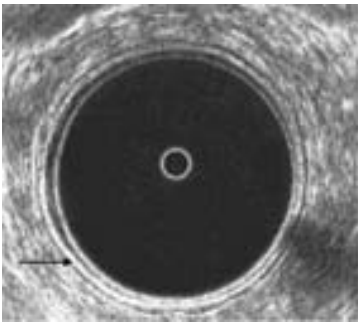
By

Egyptian Group for Colorectal Surgeons

Ahmed A Abou-Zeid

Professor of Surgery Ain Shams University

Email: ahabaz@hotmail.com



This is an ultrasound of the normal rectum, the arrow is pointing to:

1. Probe / mucosa interface
2. Mucosa
3. Submucosa
4. Rectal muscle
5. Perirectal fat

Send your answer to ejs@ess-eg.org

The correct answer and a short comment on the condition will be presented in the next issue of the journal.

The correct answer for previous Photo Quiz (Vol 26, No 4, October, 2007)

The right answer is: Internal sphincter.

Endoanal ultrasound is a recent diagnostic modality that is commonly used to investigate anal canal pathology. It clearly shows the anal canal mucosa, the internal anal sphincter and the external anal sphincter. The intact internal sphincter appears as a complete hypoechoic ring while the intact external sphincter appears as a complete ring of different echogenicity outside the internal sphincter. Defects in either sphincter are also clearly shown by endoanal ultrasound. In the present photograph, the arrow is pointing to an intact internal sphincter.

