



ORIGINAL ARTICLE

VOICE DYSFUNCTION FOLLOWING THYROIDECTOMY

By

Nabil Ali,¹ Hamed Rashad,¹ Mohamed Mitkees,¹ Mohamed Kamal,¹ Gamal Al-Habaa,¹ Ahmed Badawy,² Abdallah Ali,³ Mohamed Al-Sabbagh⁴

¹ Surgery Department, Faculty of Medicine, Benha University, ² General Surgery, Ministry of Health, ³ Hearing & Speech Institute, Cairo, ⁴ Neurophysiology Unit, Poliomyelitis Institute, Cairo, Egypt

Correspondence to: Nabil Ali, Email: ahmednabil13@hotmail.com

Aim: Voice dysfunction after thyroidectomy is not rare, and is generally reported in terms of recurrent laryngeal nerve (RLN) or superior laryngeal nerve (SLN) injuries. However, voice dysfunction can occur without laryngeal nerves injuries. Prompt recognition of causes of dysphonia is essential so that relevant therapeutic decision allows early management.

The aim is to analyze voice change after thyroidectomy for patients with normal pre-operative voice.

Methods: The study included 30 patients who had developed voice changes within 6 months after thyroidectomy. They were subjected to voice evaluation, indirect laryngoscopy, videostroboscopy and electromyography (EMG).

Results: It was found that dysphonia after thyroid surgery was caused by neurogenic causes (RLN and SLN injuries) in 23 patients (76.7%), non-neurogenic causes in 5 patients (16.7%) and combined causes in 2 patients (6.6%). EMG studies revealed complete denervation in 6 patients (20%) and incomplete denervation (paresis) in 19 patients (63.3%).

Conclusion: Post-thyroidectomy dysphonias are not rare. Injuries of the RLN constitute the main cause. Non-neurogenic injury is another contributing factor. Diagnosis is essential for early management through videostroboscopy and EMG which is specific to differentiate between neurogenic and traumatic injuries and to detect complete or incomplete denervation.

Keywords: Dysphonia, laryngeal nerves, Vocal folds dysfunction.

INTRODUCTION

Voice dysfunction in patients with thyroid pathology has been poorly documented, and its dysfunction after thyroid surgery is not rare and is generally reported in terms of recurrent laryngeal nerve or external laryngeal nerve palsy. But voice dysfunction is more complex than simply nerve integrity.⁽¹⁾ Along with laryngeal nerve palsy, 30% of cases may be due to non-neurological reasons.⁽²⁾

Non neurological causes attributed to voice changes might be as frequent as simple intubation alone with benign lesion to vocal folds or difficult intubation with resultant

arytenoid trauma and subluxation. Lesions to the strap muscles with laryngo-tracheal movement impairment or surgical trauma from rebost maneuver with trauma to cricothyroid muscle might cause voice changes.^(3,4)

Injury to the recurrent laryngeal nerves is rarely appreciated during surgery. Even in the immediate postoperative period, unilateral vocal fold paralysis may not be clinically evident. If the paralyzed cord lies in the paramedian position, the patient may not complain of voice change or aspiration.⁽⁵⁾ Occasionally, even with bilateral vocal fold paralysis, the voice may be normal and the patient may not have signs or symptoms of airway

compromise. The onset of paralysis can be delayed and develops over the first few post-operative days.⁽⁶⁾

Routine examination of the vocal fold mobility is controversial, as indirect laryngoscopy may miss subtle paresis⁽⁵⁾ to routine flexible fiber optic laryngoscopy at the first postoperative visit to diagnose vocal fold mobility abnormalities not detected clinically.⁽⁶⁾ However, proper diagnosis is essential for prognostic information and proper management; many modalities are utilized e.g. laryngeal stroboscopy and laryngeal electromyography (EMG). The first is to image the high speed vibratory movements of the vocal folds during phonation and the second is to objectively differentiate mechanical from neuromuscular causes of vocal fold immobility.

PATIENTS AND METHODS

The present study included 30 patients who had developed voice changes within 6 months after performing thyroidectomy for mass lesion or toxicity in the period from February 2002 to February 2005 in Benha University Hospital (BUH). Patients with a history of previous neck surgery, pre-operative voice disturbance, previous or on radiotherapy and underwent thyroidectomy for cancer or those patients with intra-operative complications are not included in the study. All patients were consented for inclusion in the study and the study obtained the ethical committee approval of the BUH.

Methods: In the Surgical and ENT departments BUH, every patient fulfilled the following criteria:

- Detailed history including indications for surgery, type of thyroidectomy, postoperative voice changes, onset, character, course associated symptoms e.g. dysphagia, cough, choking, aspiration and sense of foreign body in the larynx.
- Voice evaluation to demonstrate vocal limitations:
 1. Speaking voice, where attention paid to the character of voice at the beginning and near the end of conversation.
 2. Projected voice, as if speaking to a crowd. This helps to unmask the paralytic dysphonia.
 3. Forceful cough for ineffective glottic closure where expiratory pseudo-wheezing may be heard.
 4. Maximum phonation time, after maximal breath the patient is asked to phonate continuously at a given pitch. It measures the glottic efficiency.
- Indirect mirror laryngoscope allows examination of vocal folds, position, mobility and any pathology or trauma.
- Laryngeal videostroboscopy (Kay's digital strobe) done in Hearing & Speech Institute Cairo: The strobe

includes light source, camera, recording system, microphone and printer. All patients were subjected to this examination where the tongue is held gently with a piece of gauze, and a long thin camera is placed in the mouth, sets on the tongue and only goes as far back as the molar teeth. The examination takes around 15 minutes. There is a special lens on the end of the camera that can see down into the voice box while the patient produces an "eeee" sound. This allows direct visualization of the symmetry of the vocal folds, position, amplitude and regularity of vocal folds vibration, the traveling (mucosal) wave characteristics as well as glottic closure and configuration.

- Electromyography (EMG) done in Poliomyelitis Institute Cairo: It is a mean of studying electrical activity in muscles. It can separate between neurogenic and mechanical limitation of the vocal folds mobility. In addition, it can point to the site of lesion and differentiate between incomplete neural injury or synkinesis. A percutaneous monopolar needle technique (Medtomic) was used. The examination included cricothyroid and thyroarytenoid muscles to investigate superior and recurrent laryngeal nerve integrity on each side. No local anesthesia is used so it is mildly uncomfortable. The patient is placed in a recumbent position with neck extended. A ground electrode is placed over the sternum, and the reference lead is placed over the cheek. The needle is passed through the skin overlying the cricothyroid membrane just off the midline and then directed along the outsider of the cricoid cartilage superiorly and laterally until electrical activity of the crico-thyroid muscle is achieved. The thyroarytenoid muscle complex is reached by passing the needle through the skin and the cricothyroid membrane in the middle where it enters the air column in the laryngeal lumen. Then, it is advanced superiorly and laterally until it pierces the muscle complex. Gentle manipulation of the needle allows sampling at multiple sites within the muscle. The electrical activity received through oscilloscope or a digital trace and coupled to a speaker to produce audible output. The patient is asked to voluntary contract the muscle in which the electrode rests through voicing or a valsalva maneuver for the thyroarytenoid, or high-pitched phonation for the cricothyroid. Contraction results in the appearance of the motor unit action potential (MUAP), (Fig. 1).

The findings and results of laryngeal mirror, stroboscopy and EMG examination of the vocal folds were collected for all patients and were analyzed at BUH and were classified according to the following scale:

- Morphology of the vocal folds and cricoarytenoid joint component.
- Vertical mismatch between vocal folds.




Fig 1. EMG of thyroarytenoid muscle complex supplied by RLN
Normal MUAPs, Paresis and paralysis

- Position of the vocal folds at rest [median (0-1.5 mm) from midline, paramedian (1.5-2.5 mm) and lateral position (≥ 2.5 mm)].
- Mobility of the vocal folds in respiration and during phonation (mobile, sluggish, immobile).
- Efficacy of glottic closure during maximal phonation (complete - deficient).
- Mucosal wave in both vocal folds (symmetrical or asymmetrical).
- EMG findings for the thyroarytenoid and cricothyroid muscles (normal or abnormal).

RESULTS

Thirty patients developed voice change within 6 months after thyroidectomy were included in the study. They were 17 females and 13 males, their age ranged from 21 to 65 years. All operations were done under general endotracheal anesthesia.

Thyroidectomy was indicated for toxicity in 9 patients and for mass lesion in 21 patients.

Near total thyroidectomy performed for 5 patients, subtotal

thyroidectomy for 9 patients and hemithyroidectomy for 16 patients.

Voice dysfunction was found due to recurrent laryngeal nerve (RLN) or superior laryngeal nerve (SLN) injuries in 23/30 patients (76.7%) i.e. neurogenic causes of voice dysfunction. Non-neurogenic causes were found in 5/30 patients (16.7%) due to intubation injuries or rebost manipulation during surgery.

On the other hand, combined lesions (neurogenic and non-neurogenic) had been found in 2/30 patients (6.6%). The neurogenic causes were divided into RLN injury in 16/30 patients (53.3%), SLN injury in 5/30 patients (16.7%) and combined RLN and SLN injuries in 2 patients.

The RLN injury was found bilateral in one patient and unilateral in 15 patients. The SLN injury was found bilateral in one patient and unilateral in 4 patients. On the other hand, the non neurogenic causes detected were arytenoid dysfunction, cysts of the vocal folds and bilateral vocal nodules. Two patients (combined neurogenic and non-neurogenic) had RLN injuries associated with arytenoid dysfunction Table 1.

Neurogenic causes (23 patients):

A. **RLN injuries (16 patients):** The chief complaint was weak voice, and phonation requires a considerable amount of effort. Easy fatigability, inspiratory stridor during effort, aspiration especially to liquids and foreign body sensation in the larynx were also noticed. RLN injuries were unilateral in 15 patients and bilateral in one patient.

1. Stroboscopy studies revealed asymmetrical vibration during phonation and the mobility ranged from completely immobile to sluggish mobility. Glottic closure during maximal phonation was always deficient.

- In the bilateral RLN injury patient, the vocal folds were found to lie in the median position at rest. During extubation, the patient failed to gain patent airway. Retubation was done immediately followed by tracheostomy.

- The vocal folds in the paramedian position (8 patients) (Fig. 2): The defect was found to affect the membranous portion of the vocal folds and the defect is elliptical with no posterior gaps. The voice was found to be less affected.

- The vocal folds in the intermediate positions (5 patients): A triangular gap involving both the membranous vocal folds and the posterior glottis was found and the voice was greatly affected.

- The vocal folds in the lateral positions (2 patients): In addition to the triangular gap, the patients were found aphonic and complaining of difficulty to cough.
 - Mucosal wave was found to be asymmetrical in unilateral RLN injuries. In the affected side, it is always deficient; absent in 3 patients and of low amplitude in 13 patients. The mucosal wave was with delayed initiation and slower period in different phonatory cycle.
2. EMG studies of the thyroarytenoid complex revealed bilateral incomplete denervation in one patient, unilateral complete denervation in 3 patients with absence of spontaneous electrical activity (complete silence) at rest as well as during effort. In the rest (12 patients), there was only reduction in the amplitude of the MUAPs indicating incomplete denervation.
- B. *SLN injuries (5 patients):* The main complaint was reduction of vocal range and lowering speaking pitch, monotony of voice, varying degrees of breathlessness, dysphagia and tickling sensation in the throat. SLN injuries were found unilateral in 4 patients and bilateral in one patient. Laryngoscopic examination revealed that the larynx was symmetrical in shape during rest, while in high pitch voice, there was asymmetry in the laryngeal configuration in patients with the unilateral injuries. On the other hand, the laryngeal configuration was symmetrical but the vocal folds were found bowing (Fig. 3) and without lengthening in the patient with bilateral injury.
1. Stroboscopy studies revealed the following:
- *In all patients:*
Mobility of the folds was sluggish during the high pitch phonation.

Mucosal wave was impaired in the form of slow initiation and low amplitude.
 - *Glottic closure was found to be impaired in 4 patients (unilateral SLN injuries).*
 - *Vertical mismatch of the vocal folds was found in 2 patients (unilateral SLN injuries).*
2. EMG studies of the cricothyroid muscle were abnormal in all cases. Three patients showed

unilateral complete paralysis and two patients showed marked reduction in the wave amplitude (paresis); one of them was bilateral.

- C. *Combined RLN and SLN injuries (2 patients):* The injury was unilateral in the same side. The larynx was found asymmetrical and there was hoarseness of voice and loss of high pitch voice in addition to voice fatigue and inspiratory stridor during effort. Stroboscopy revealed asymmetrical vibration during phonation and sluggish mobility with deficient glottic closure. EMG showed incomplete innervation in both muscles.

Non neurogenic (5 patients):

- Arytenoids malfunction developed in two patients. Their complaint was hoarseness, breathlessness, dysphagia, sore throat, dyspnea, vocal fatigue and loss of voice control. Vocal folds mobility was sluggish. Glottic gap always was present at rest and during phonation. Arytenoid cartilage was dislocated posterolaterally in the left side. The vocal folds lie in a different horizontal plane and the mucosal wave was impaired.
- Cysts of vocal folds were seen in two patients (Fig. 4). Their complaint was hoarseness with pain during speaking. Mucosal wave significantly decreased throughout the affected side and absent over the cyst itself. Glottic closure was compromised leaving gaps anterior and posterior to the lesion in maximal closure. Vibratory pattern is asymmetrical.
- Bilateral vocal nodules were seen in one patient (Fig. 5). Patient suffered of hoarseness after thyroidectomy. Examination revealed bilateral smooth swellings on vocal folds with normal mobility. Stroboscopic examination showed decrease of mucosal wave and vibratory amplitude.

EMG revealed normal pattern of innervation in all patients with non-neurogenic injuries. All patients were improved under conservative treatment (anti-biotic, corticosteroid)

Combined neurogenic and non-neurogenic injuries (2 patients):

- Two patients with arytenoid malfunctions were associated with unilateral RNL injuries. In the affected side, the fold was of restricted mobility with incomplete glottic closure during phonation.
- EMG showed incomplete nerve injury (paresis).

Table 1. Neurogenic and non-neurogenic causes of voice dysfunction following thyroidectomy.

No. of the patients	Causes		Distribution
30	23 Neurogenic (76.7%)	16 RLN (53.3%)	1 Bilateral (tracheostomy) 15 Unilateral
		5 SLN (16.7%)	1 Bilateral 4 Unilateral
		2 Combined (6.7%)	RLN and SLN (Unilateral on the same side)
Patients	5 Non-neurogenic (16.7%)	2	Arytenoid dysfunction
		2 2 1	Cysts of the vocal folds Bilateral vocal nodules
	2 Combined (6.6%)	Neurogenic and non-neurogenic	RLN injuries (unilateral) Associated with arytenoid dysfunction

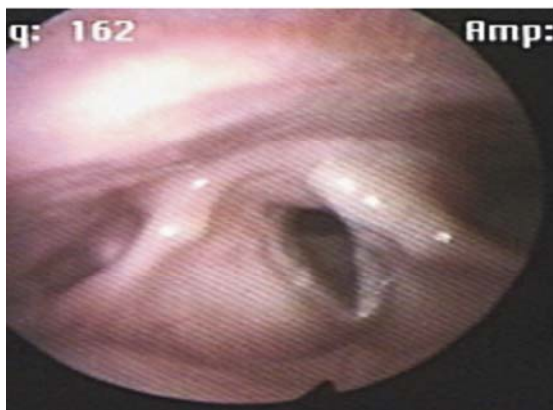


Fig 2. Unilateral paralysis of vocal folds. RLN injury(stroboscopic photo) Patient no. 4

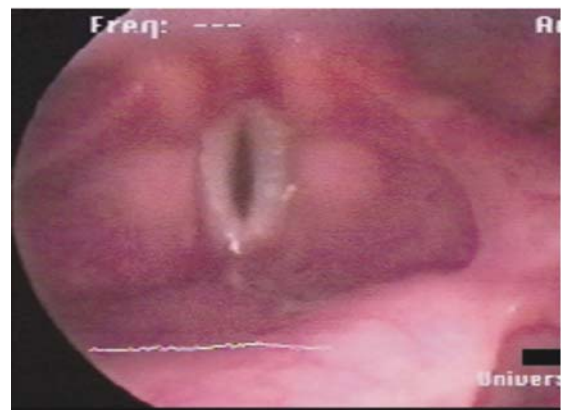


Fig 3. Bowing of the vocal folds. Bilateral SLN injury Patient no.9

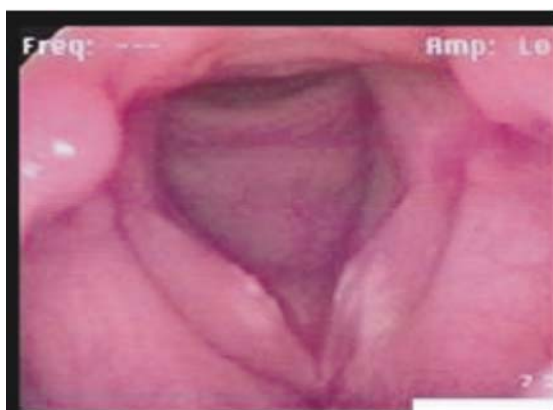

Fig 4. Cysts of the vocal folds. Intubation (non-neurogenic) injury Patient no. 20

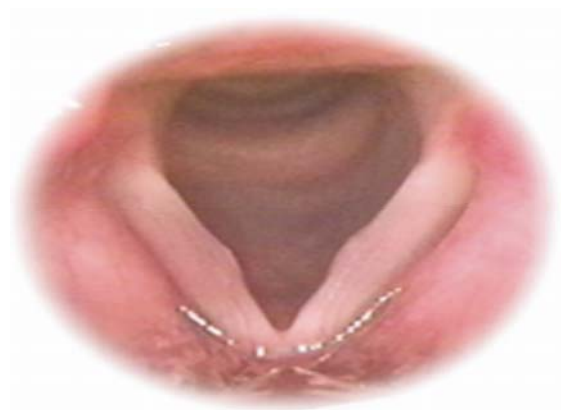

Fig 5. Nodules of the vocal folds. Intubation (non-neurogenic) injury Patient no.25

DISCUSSION

In the thyroid surgery, postoperative dysphonia is not rare and in some cases, it is a life threatening complication. The main reason is the lesion of recurrent laryngeal nerve. Along with this, 30% of cases dysphonic complaints may owe to non-neurological reason.⁽²⁾

The recurrent laryngeal nerve innervates all of the intrinsic muscle of the larynx with the exception of the cricothyroid muscle, which is innervated by the superior laryngeal nerve. Mechanisms of injury to the nerve include complete or partial transection, traction, contusion, crush, burn, misplaced ligature and compromised blood supply i.e. iatrogenic injuries during surgery. The consequence of recurrent laryngeal nerve is true vocal fold paresis or paralysis.⁽⁷⁾

Injury to recurrent laryngeal nerve even may not be appreciated during surgery. Even in the immediate postoperative period, unilateral vocal fold paralysis may not be clinically evident. If the paralyzed fold lies in the paramedian position, the patient may not complain of voice changes or aspiration.⁽⁵⁾ Occasionally, even with bilateral vocal cord paralysis, the voice may be normal and the patient may not have signs or symptoms of airway compromise. The onset of the paralysis can be delayed and develops over the first few postoperative days. This is believed to be a result of edema or hematoma of the recurrent laryngeal nerve. In both situations, routine laryngoscopy at the first postoperative visit will reveal the diagnosis.⁽⁶⁾ In the present study, few patients ignored their voice changes and presented late in a condition with advanced pathological lesions. Early detection of their lesions might allow proper management.

Indirect laryngoscopy does not allow adequate viewing of the entire larynx, may miss subtle paresis, and it doesn't allow examination of vocal folds vibration during speech. Flexible fiber-optic laryngoscopy can be fed after local anaesthetic spray through the nose or mouth. When fed through the nose, evaluation of speaking and singing techniques in their normal, unaltered state can be done.⁽⁸⁾ New advances in management of altered voice have been achieved over the last few years. Stroboscopy, laryngeal electromyography and computerized analysis of the voice help guide diagnosis, allow differentiation between recurrent nerve paralysis and glottis traumata due to intubation, and further follow-up of recovery with relevant therapeutic decisions. Early management of those complications by teams of specialists should allow appropriate and less invasive surgery.⁽⁹⁾ This what happened in 5 patients with non-neurogenic laryngeal lesions.

Videostroboscopy has evolved as one of the most practical

and useful techniques for the clinical evaluation of vocal fold vibration.⁽¹⁰⁾ The vocal folds mucosal wave produced by the vocal fold's mucous membrane flowing over its muscle, is only visualized with the stroboscopy light, high speed photography or possible digital photography. It is the only tool for observing many functions of the vocal folds, including symmetry, amplitude, periodicity, glottic closure and the diagnostically important mucosal wave.⁽⁸⁾ Electromyography (EMG) is a mean of studying electrical activity in muscle and, as such, is uniquely suited to address several questions that arise during the evaluation of immobile vocal folds. Chief among these, for both patients and their physicians, is prognosis of return of functions. Second, EMG can also be used to separate neurogenic vocal fold immobility from that resulting from mechanical limitations, such as cricoarytenoid dislocation or posterior glottic scarring. Third, comparison of findings from different laryngeal muscles can point to the site of neurological lesion. Finally, laryngeal EMG can identify incomplete neural injury or synkinesis.⁽¹¹⁾

Intubation injury to the larynx may be acute e.g. arytenoid dislocation, injury to recurrent laryngeal nerve which may be due to anterior displacement of thyroid cartilage relative to the cricoid cartilage, hyper-extension of the neck that stretches the vagus nerve, laryngeal mask airway, or excessive cuff pressure that compresses the recurrent laryngeal nerve as it enters the larynx. Other injuries include laceration or bleeding of the vocal fold, damage to intrinsic muscle, perforation of the airway, or infection of the soft tissue.⁽¹²⁾ Surgical damage to extrinsic laryngeal muscles and rebost manipulation, and thyroid hypofunction after extirpation of the gland are other injuries.⁽¹³⁾

Endotracheal intubation accounted for 7.1% to 11% of recurrent laryngeal nerve paralysis in several series. Most patients recovered spontaneously within 6 months.⁽¹⁴⁾ In the present study, the incidence of non-neurogenic causes (anesthetic iatrogenic injuries) of post thyroidectomy voice change was 16.7% with normal EMG and 6.6% were combined neurogenic and non-neurogenic causes (anesthetic and surgical iatrogenic injuries) proved by EMG to have incomplete nerve injury. All patients improved on conservative management (anti-biotic and corticosteroid) within several weeks including those patients with combined lesions. This means that the nerve injury was of the neuropraxia type, due to nerve compression or excessive stretching. This ratio is less than that reported in the literature.⁽²⁾ Some differences may be present according to the degree of skill of anaesthesia and surgical staff.

Identification and preservation of the recurrent laryngeal nerve and the external laryngeal nerve during thyroidectomy has decreased the incidence of permanent

voice changes to only 5%; this was similar to the incidence of 3% in controls after endotracheal intubation alone.⁽¹⁵⁾ However, this was not the rule in the present study, where identification of the nerve was done in a selective basis and a matter of preference of surgeons.

In the current study, EMG findings revealed complete denervation in 6 patients (20%) with bad prognosis and incomplete denervation (paresis) in 19 patients (63.3%), that matched with Eckley et al.⁽¹⁶⁾ Mostafa et al.⁽¹⁷⁾ concluded that the specificity of EMG was 100%, while the sensitivity was 86.6% in predicting recovery of patients with immobile vocal folds. EMG is an efficient and objective test in the study of patients with immobile vocal folds.

In conclusion, voice changes post-thyroidectomy are not rare and laryngeal nerve injuries are the commonest causes. Traumatic non-neurogenic causes include arytenoid dislocation, vocal folds injuries (e.g., hematoma, cyst, nodule and granuloma) and injury to strap muscles with laryngo-tracheal fixation. Prevention can be achieved by wide exposure, muscle cutting, gentle handling and possibly by identifying and saving the nerves during surgery. Every effort should be done to investigate and diagnose properly cases with voice changes post-thyroidectomy. Intense visual laryngeal observation using laryngoscope and stroboscopy can diagnose causes of voice changes. EMG is to be looked for only where there is no scarring or dislocation and when neurological findings are expected or be present. EMG is specific and sensitive in differentiating between true immobility (neurogenic) or pseudoparalysis of the vocal folds and predicting the prognosis. Voice dysfunction after thyroidectomy requires multidisciplinary team (MDT) management

REFERENCES

1. McIvor NP, Flint DJ, Gillibrand J, Morton RP. Thyroid and voice related outcomes. *ANZ J Surg.* 2001;71:611.
2. Sechanov T, Pandev R, Stoinov IU. The diagnostic and clinical aspects of postoperative dysphonias following operation on the thyroid. *Kirurgiia (Sofiia).* 1997;50:26-8.(English abstract).
3. Alexender S, Ashok RS, Aviram N. Voice problems following thyroid surgery occur without damage to the laryngeal nerves. Annual Meeting of the American Head and Neck Society. 2002;11.
4. Sinagra DL, Montesinos MR, Tacchi VA, Moreno JC, Falco JE, Mezzadri NA et al. Voice changes after thyroidectomy without recurrent laryngeal nerve injury. *J Am Coll Surg.* 2005;200:813.
5. Steurer M, Passler C, Denk DM. Advantages of recurrent laryngeal nerve identification in thyroidectomy and parathyroidectomy and the importance of preoperative and postoperative laryngoscopic examination in more than 1000 nerves at risk. *Laryngoscope.* 2002;112:124-33.
6. Fewins J, Simpson CB, Miller FR. Complications of thyroid and parathyroid surgery. *Otolaryngologic Clinics of North America.* WB Saunders Company. 2003;36:1).
7. Myssiorek, D. Recurrent laryngeal nerve paralysis: Anatomy and etiology. *Otolaryngologic Clinics of North America;* WB Saunders Company. 2004;37(1).
8. Richardson BE and Bastin RW. Clinical evaluation of vocal fold paralysis. *Otolaryngologic Clinics of North America.* WB Saunders Company. 2004;37(1).
9. Baujat B, Delbove H, Wagner I, Fugain C, de Corbiere S, Chabolle F. Laryngeal immobility after thyroidectomy. *Ann Chir.* 2001;126:104-10.
10. Simpson CD and Fleming DJ. Medical and vocal history in evaluation of dysphonia. *Otolaryngologic Clinics of North America.* 2000;33:719-29.
11. Sulica L and Blitzer A. Electromyography and the immobile vocal fold. *Otolaryngologic Clinics of North America.* WB Saunders Company. 2004;36(1).
12. Quinin FB Jr, Stroud RH, Rassekh CH. Laryngeal injury as a result of endotracheal intubation. Grand Rounds Presentation; UTMB, Department of Otolaryngology. 1999.
13. Hong KH and Kim YK. Phonatory characteristics of patients undergoing thyroidectomy without laryngeal nerve injury. *Otolaryngol Head Neck Surg.* 1997;336-404.
14. Ramadan HH, Wax MK, Avery S. Outcome and changing cause of unilateral vocal cord paralysis. *Otolaryngol Head Neck Surg.* 1998;118:199-202.
15. Kark RD, Kissen MW, Auerbach R. Voice changes after thyroidectomy: Role of the external laryngeal nerve. *BMJ.* 1984;289:1412-5.
16. Eckley CA, Sataloff RT, Hawkshaw M, Spiegel JR, Mandel S. Voice range in superior laryngeal nerve paresis and paralysis. *J Voice.* 1998;12:340-8.
17. Mostafa BE, Gadallah NA, Nassar NM, Al-Ibiary HM, Fahmy H, Fouad MN. The role of laryngeal electromyography in vocal fold immobility. *ORL J Otorhinolaryngol Relat Spec.* 2004;66:5-10.